

## RETINAL MICROANEURYSMS IN LEUKAEMIA\*†

BY

JAMES R. DUKE, CHARLES P. WILKINSON, AND SYLVIA SIGELMAN

*The Wilmer Ophthalmological Institute, Johns Hopkins University School of Medicine and Hospital,  
Baltimore, Maryland*

THE purpose of this report is to describe the presence of microaneurysms in the retinae of patients who died with leukaemia. Although this type of lesion is most frequently observed in association with diabetes mellitus, it has, during recent years, been described clinically and/or histologically in association with a diverse variety of apparently unrelated entities.

In a few instances the lesion appears in relation to conditions localized within the eye. Microaneurysms are frequently observed after thrombosis of the central retinal vein or one of its branches (Loewenstein and Garrow, 1945; Ashton, 1951), and they have also been described in association with retinoblastoma (Ashton, 1951; Wolter, 1961), Eales's disease (Wise, 1957), Coats's disease (Lorentzen, 1959), loa-loa (Toussaint and Danis, 1965), and chorioretinitis (Ashton, 1951; Wise, 1957). They have also been observed in association with a variety of systemic diseases: hypertension (Friedenwald, 1950), the haemoglobinopathies (Edington and Sarkies, 1952; Goodman, von Sallmann, and Holland, 1957), the dysproteinaemias (Ashton, Kok, and Foulds, 1963; Carr and Henkind, 1963), cyanotic disease states (Oliviera, 1966), primary and secondary polycythaemia (Ashton and others, 1963), severe anaemias (Friedenwald, 1950; Becker, Allen, Winter, Maengwyn-Davies, and Friedenwald, 1954), pulseless disease (Dowling and Smith, 1960), and even as a component of the process of ageing (Kuwabara and Cogan, 1960).

Two recent clinico-pathological reports by Allen and Straatsma (1961) and by Mahneke and Videbaeh (1964) have stressed the high incidence of retinal lesions in patients with leukaemia. Commonly observed are dilated tortuous veins, leukaemic infiltrates, haemorrhages, and exudates. Papilloedema and retinal oedema are less frequently seen. Neither of these recent reports cited retinal microaneurysms as a feature of leukaemic retinopathy. Similarly, in a review of the recent literature concerning retinal vascular pathology, we were unable to find reports of these lesions in association with leukaemia.

### Material and Methods

The posterior segments of eyes were obtained from all patients who died of leukaemia at the Johns Hopkins Hospital and who had complete *post mortem* examinations between November, 1961, and October, 1966. Clinical records and autopsy findings on each patient were reviewed, and those cases of leukaemia which were accompanied by local or systemic diseases known to be associated with retinal microaneurysms were excluded from the study. The eyes of forty leukaemic patients met the criteria for inclusion in the study.

Flat mounts of the retina were prepared, using the method of trypsin digestion described by Kuwabara and Cogan (1960) and these preparations were stained with PAS-haematoxylin. Utilizing this technique, one complete retina from each case was examined microscopically.

---

\* Received for publication May 15, 1967.

† Address for reprints: Dr. J. R. Duke, 14 West Mount Vernon Place, Baltimore, Maryland 21201, U.S.A.

In order to ascertain that any changes observed were not related to changes induced by the processes of ageing or senility *per se*, a group of control eyes was studied. These had previously been collected as part of another and unrelated study undertaken to evaluate retinal changes in patients who had a reduced pulmonary capacity; thus, the retinae of this control group were from elderly patients with clinically severe bronchiectasis or emphysema, but who had none of the known clinical entities associated with retinal microaneurysms. The findings in the retinae of these individuals had been unremarkable, and they served as a suitable control group, with respect to age, for the leukaemia cases. There were 45 cases in the control group. The retina of one eye of each patient was studied by the technique described above.

**Results**

**Control Group.**—The 45 patients varied in age at time of death from 52 to 88 years (average 66). In 38 of these eyes no aneurysms at all were noted. In six eyes, one to five small aneurysms were seen. In one eye there were eight small aneurysms widely distributed. These rare aneurysms found in seven of the control group were attributed, in the absence of other known factors, to the process of ageing. Thus, for the leukaemia study, it was arbitrarily decided to consider as positive only those eyes which contained more than ten microaneurysms per retina.

**Leukaemia Group.**—Of the forty cases, 21 died with acute and nineteen with chronic leukaemia. In the acute forms of the disease the patients varied in age at time of death from 2 to 81 years (average 24). No retinal aneurysms at all were found in these patients with acute leukaemia.

The chronic leukaemias (Table) may be divided into the lymphoid group (10 cases) and

TABLE  
INCIDENCE OF RETINAL MICROANEURYSMS IN CHRONIC LYMPHOID AND MYELOID LEUKAEMIA

Chronic Leukaemia	Autopsy No.	Age* (yrs)	Race	Sex	Duration of Disease (yrs)	Haematocrit*	WBC*	Globulin†	Aneurysms‡
Lymphoid	31221	64	W	M	4	40	62150	2.3	neg.
	31318	49	W	M	10	32	204000	1.3	neg.
	33025	66	N	F	4	34	45000	1.5	neg.
	33382	67	W	M	10	21	861000	3.8	neg.
	34004	68	N	M	10	38	30000	2.2	neg.
	34050	66	W	M	11	41	34000	3.2	neg.
	34363	52	N	M	2	39	106000	3.4	1+
	34629	42	W	M	4	25	78000	—	1+
	34704	66	N	M	4	29	140000	2.8	neg.
	34918	57	N	M	5	22	143000	1.7	3+
Myeloid	31101	60	N	M	1	34	216000	1.5	2+
	31455	41	W	F	4	31	23350	2.3	neg.
	32543	55	W	M	1	17	254000	3.6	2+
	32610	55	N	F	1-3	25 §	454000	3.5	3+
	33677	80	W	F	1.5	17	44000	—	3+
	34180	50	N	M	0.5-1	21	400000	2.9	1+
	34187	63	N	M	1.5	33	190000	3.0	3+
	34807	16	W	F	4	22	110000	1.7	2+
	35003	50	N	M	0.5	22	143500	2.7	neg.

\* On final admission to Johns Hopkins Hospital  
 † On final admission or last recording prior to that time  
 § Admitted with 4-day history of severe gastrointestinal bleeding  
 ‡ Number aneurysms per retina  
 0-10 neg. 11-25 1+ 26-50 2+ over 50 3+

the myeloid group (9 cases). The ten patients with chronic lymphoid leukaemia varied in age at time of death from 42 to 68 years (average 67). Three of the ten retinae had aneurysms present in significant numbers. As stated, the presence of ten aneurysms or less per retina was considered a negative finding. If the lesions numbered between 11 and 25 they were graded as 1+, between 26 and 50 as 2+, and over 50 as 3+.

The nine patients with chronic myeloid leukaemia varied in age from 16 to 80 years (average 52). Seven of the nine retinae contained aneurysms in significant numbers, six being in the 2+ or 3+ category.

The majority of the aneurysms were found in the periphery of the retina, although occasional lesions were noted at the posterior pole. Aneurysms were observed in various stages of development. Initially, there was an outpouching on one side of the capillary wall (Fig. 1), a process not necessarily accompanied by loss of the intramural pericyte at this site (Fig. 2).

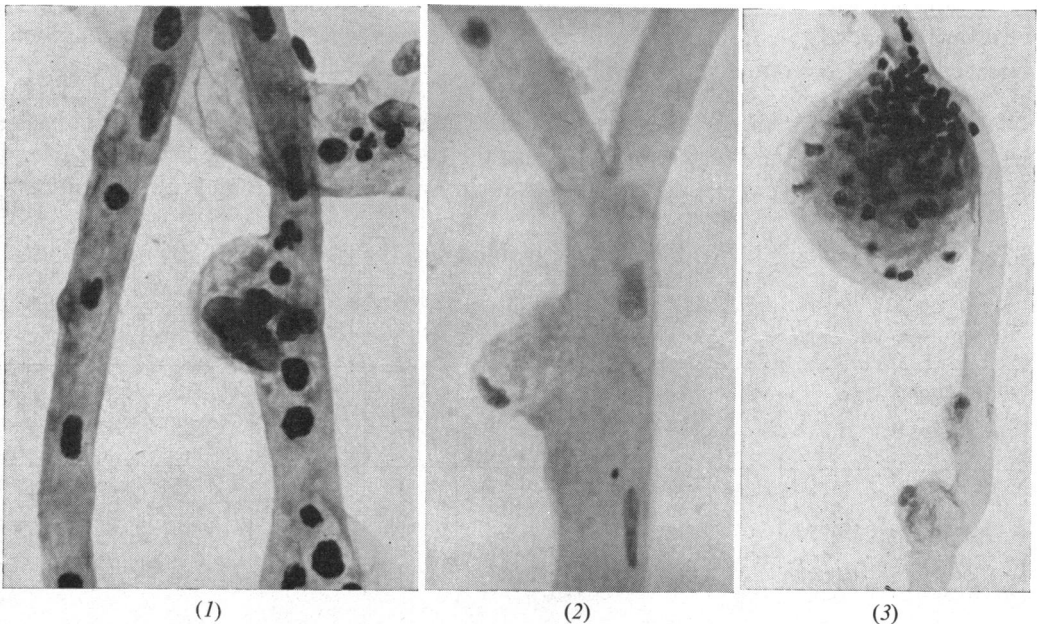


FIG. 1.—Early stage in development of capillary microaneurysm in 16 year old white female with chronic myeloid leukaemia. Periodic acid-Schiff—haematoxylin.  $\times 170$ .

FIG. 2.—Preservation of intramural pericyte at site of outpouching during early stage of development. Periodic acid-Schiff—haematoxylin.  $\times 170$ .

FIG. 3.—Fully developed microaneurysm on a capillary which also shows two lesions in very early stages of development. Periodic acid-Schiff—haematoxylin.  $\times 170$ .

As the aneurysm increased in size it tended to assume a globular configuration (Figs 3 and 4). Aneurysms of fusiform shape were rare. The lesions usually contained many white blood cells. In a few instances, PAS-positive material was deposited within the wall or lumen of the aneurysm (Fig. 5, opposite); and, rarely, aneurysms were virtually filled with this material (Fig. 6, opposite).

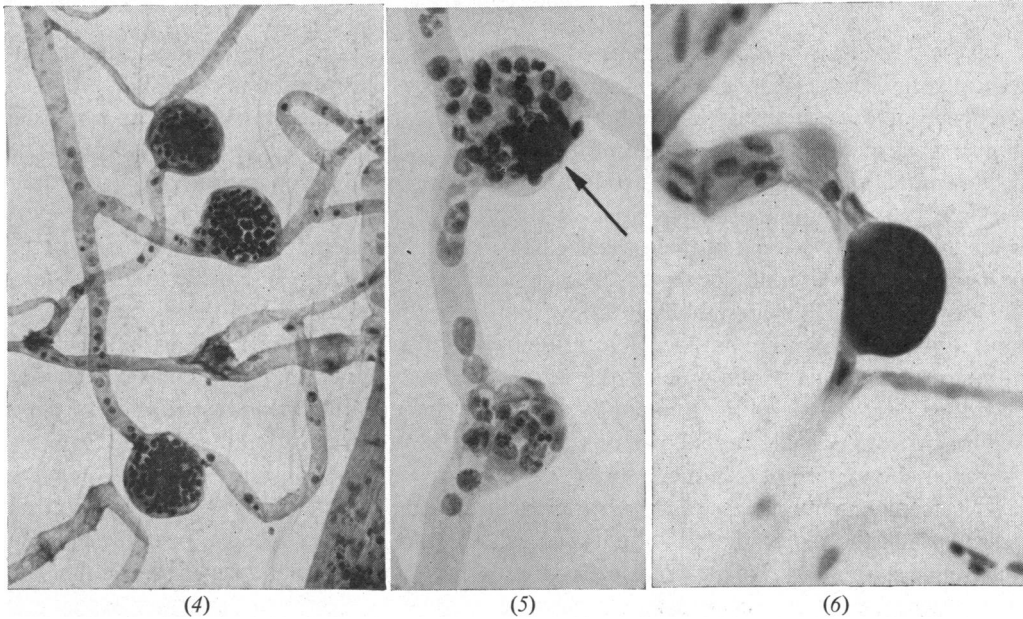


FIG. 4.—Several microaneurysms of typical globular shape. Periodic acid-Schiff—haematoxylin.  $\times 40$ .

FIG. 5.—Early deposition of Periodic acid-Schiff—positive material (arrow) in wall or lumen of microaneurysm. Periodic acid-Schiff—haematoxylin.  $\times 107$ .

FIG. 6.—Obliteration of lumen of microaneurysm by Periodic acid-Schiff—positive material. Periodic acid-Schiff—haematoxylin.  $\times 137$ .

In general, there appeared to be no greater loss of intramural pericytes on the affected capillaries than might have been expected in this peripheral location in the retina in these older individuals. The loss of endothelial cells in the periphery was greater than the loss of intramural pericytes and was also compatible with the age of the patient. Aneurysms were present on both the arteriolar and venous sides of the capillaries (Fig. 7), being more frequent in the latter location. Affected capillaries were not found in association with collapsed acellular capillaries, suggesting that there had been no predilection for an abnormal shunting of blood flow through the involved vessels.

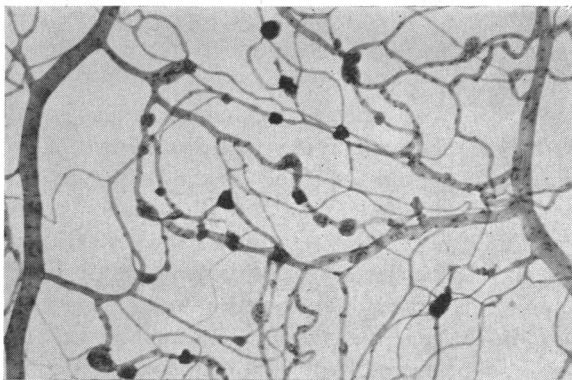


FIG. 7.—Arrangement of microaneurysms on capillaries between arteriole (large dark-staining vessel on left) and venule (large light-staining vessel on right) Periodic acid-Schiff—haematoxylin.  $\times 17$ .

### Discussion

In the patients with chronic forms of leukaemia, aneurysms were demonstrated histologically in approximately half the retinae studied. This represents a relatively high incidence of occurrence of this lesion, and one can only speculate why it has not been described as a clinical manifestation of these diseases. The location at the periphery of the retina would make it unlikely that the lesion would be seen in the course of routine ophthalmological examination. In addition, it is quite probable that these small lesions, even when occasionally present at the posterior pole, would be obscured by other features of the retinopathy so commonly observed, *i.e.* haemorrhages, exudates, leukaemic infiltrates, etc.

How does this lesion resemble or differ from the retinal aneurysm in the diabetic? The most apparent difference is one of location. In diabetes the aneurysms are much more numerous at the posterior pole of the retina than at the periphery, whereas the lesions described here are found predominantly at the periphery. The lack of association of these aneurysms with occluded capillaries or with shunts also serves to differentiate them from the characteristic pattern of diabetic lesions (Cogan, Toussaint, and Kuwabara, 1961). Finally, if one accepts the hypothesis of Cogan and his group that the selective loss of the intramural pericytes and the replacement by "mural cell ghosts" are changes specific for diabetes, then the frequent preservation of these cells in association with aneurysms in the leukaemic retina is an additional differentiating feature. Oliviera (1966), on the other hand, has observed that the selective degeneration of the intramural pericyte is not peculiar to diabetes, nor could he find any significant relationship between "ghost cells" and microaneurysm formation. Non-specific features of similarity between these aneurysms and those in the diabetic include the globular shape of the lesion, its location predominantly on the venous side of the capillary, and the presence of PAS-positive deposits within the wall or lumen of the aneurysm.

Factors which may possibly play a role in the formation of retinal aneurysms include increased venous pressure (*e.g.* after central retinal vein thrombosis), increased blood viscosity with a resulting secondary increase in venous pressure (*e.g.* the dysproteinaemias), and anoxia (*e.g.* cyanotic disease states, pulseless disease, severe anaemias, etc.).

Regarding the role of anoxia, Foulds (1963) has observed in patients with pernicious anaemia that retinopathy was present in all cases with a haemoglobin of less than 5 g. per cent., and was absent when the haemoglobin was higher than 6 g. per cent. In the leukaemic retinae under consideration here, anoxia may, in specific cases, have played a contributory role; in six of the ten patients with positive findings the haematocrit was severely lowered at the time of the last admission to hospital. But the haematocrit in the other four positive patients was relatively normal, and anoxia may be ruled out as the factor of primary importance (see Table).

An increase in the venous pressure would be a more probable mechanism. This could develop in several ways. Leukaemic infiltrates in the retina, in the optic disc, or within the nerve itself could serve mechanically to impede the return of blood *via* the central retinal vein. Also, it is probable that the viscosity of the blood in most of these patients was increased. Behrman (1962) has postulated that a high "flow resistance" already exists at the lamina cribrosa, and that a significant increase in serum viscosity would result in an increased resistance to blood flow at this point. This would lead, in turn, to an increase in venous pressure in the retina. In our group of patients, it is unlikely that increased blood viscosity is due to an increase in the serum globulins, for no significant increase in this com-

ponent of the blood was demonstrated. However, an increase in viscosity could well have resulted from the massive increase in circulating white blood cells. Stephens (1936) observed that a significant increase in blood viscosity occurred only when the white blood cell count exceeded 50,000, and that beyond this point the increase in viscosity was directly related to the number of white cells. Regarding this, of the nine negative cases, four had white blood cell counts of less than 50,000; and three of the four negative cases with white counts exceeding 100,000 were of the lymphoid type. The possible significance of these negative findings in those cases of the lymphoid group which had a marked elevation of the white count will be mentioned below. Of the ten positive cases, on the other hand, eight patients had white counts of over 100,000 (see Table).

It is true that these white blood cell counts represent only those obtained at the time of the last admission to hospital, and do not necessarily depict the status of the white count during the course of the disease. Nevertheless, in each case, when the values of the white counts taken at the onset of the disease, approximately half-way through the course of the disease, and at the terminal stage of the disease, were averaged, this value was found to be very close to the white count at the final admission. However, these findings are not definitive, and serve only to suggest that there may be a relationship between a marked elevation of the white count and the development of aneurysms, the proposed mechanism being that the elevation in white cell elements leads to an increase in blood viscosity which causes an increase in venous pressure.

As pointed out above, anoxia, resulting from a decreased haematocrit reading, was not thought to be the factor of primary importance in the genesis of the aneurysms in these cases. However, anoxia may develop through another mechanism. The increased viscosity of the blood will result not only in an increased venous pressure but in a decreased rate of blood flow, especially in the venous system. The resulting stasis of blood flow will be accompanied by a relative degree of anoxia which again will be most pronounced on the venous side of the capillaries. Thus, anoxia and increased venous pressure, each a sequel of increased blood viscosity, may play conjunctive roles in the development of these lesions; the relative importance of each, however, is impossible to evaluate.

From this study, one is unable to state whether retinal aneurysms are more likely to develop in one type of chronic leukaemia than another; in the present series the number of positive cases is insufficient for detailed analysis. However, it is perhaps worthwhile to point out that only three of the ten cases of lymphatic leukaemia had aneurysms, compared with seven of the nine cases of myeloid leukaemia.

There are two related reasons for this apparent predisposition to the development of aneurysms in patients with the myeloid form of the disease. Firstly, there was in general a greater elevation of the white count in the myeloid cases. Secondly, for increased blood viscosity to occur in lymphatic leukaemia, the elevation of the white count must be even greater than in myeloid leukaemia, because in the former condition the volume occupied by a comparative number of cells is correspondingly less (Stephens, 1936).

The age of the patient at death was apparently unrelated to the incidence of the lesion. The average age at death in the ten positive cases was 53 years, while that in the negative cases was 60 years. Significant was the finding of the lesions in a girl with chronic myeloid leukaemia who died at the age of 16 years.

Nor did the duration of the disease appear to be a significant factor. The chronic lymphoid leukaemias tended to run a much more prolonged clinical course than the chronic

myeloid group. Four patients in the lymphoid group who had had the disease for 10 years or more had no retinal aneurysms, but six of the positive cases in the chronic myeloid group died within 2 years of onset of the disease.

Why was the lesion present in ten out of nineteen cases of the chronic leukaemias, and yet absent in all of the 21 cases of the acute leukaemias? One significant factor may be the lower white count (and hence lower blood viscosity) observed in the acute group. In only two cases was it over 30,000 at the time of the final admission to hospital. If anoxia were the prime responsible factor, one might have expected to encounter the lesion in this group of acute cases, since several of the patients had extremely low haematocrit readings.

### Summary

The occurrence of microaneurysms in the retinae of patients with chronic leukaemia is described. Significant numbers of retinal aneurysms were found in seven of nine patients with chronic myeloid leukaemia, in three of ten with chronic lymphoid leukaemia, in none of 21 with acute leukaemia, and in none of 45 controls, comparable in age to those in the chronic leukaemia groups.

Possible causes of these lesions are enumerated, and the probable role of increased blood viscosity in the chronic forms of leukaemia is discussed.

### ADDENDUM

Since the submission of this manuscript attention has been called to the report of Danis, Farnir and Toussaint (1966), who demonstrated microaneurysms at the posterior pole in the retinae of two patients with leukaemia, and related the occurrence of these lesions to steroid therapy. Also, Toussaint and Farnir (1966) described peripheral microaneurysms in the retinae of 20 to 30 per cent. of a group of control cases, but the number of such lesions per retina were not cited.

### REFERENCES

- ALLEN, R. A., and STRAATSMA, B. R. (1961). *Arch. Ophthalm. (Chicago)*, **66**, 490.  
 ASHTON, N. (1951). *Brit. J. Ophthalm.*, **35**, 189.  
 ———, KOK, D'A., and FOULDS, W. S. (1963). *J. Path. Bact.*, **86**, 453.  
 BECKER, B., ALLEN, R., WINTER, F. C., MAENGWYN-DAVIES, G., and FRIEDENWALD, J. S. (1954). *Amer. J. Ophthalm.*, **38**, no. 1, pt. 2, p. 53.  
 BEHRMAN, S. (1962). *Brit. J. Ophthalm.*, **46**, 336.  
 CARR, R. E., and HENKIND, P. (1963). *Amer. J. Ophthalm.*, **56**, 23.  
 COGAN, D. G., TOUSSAINT, D., and KUWABARA, T. (1961). *Arch. Ophthalm. (Chicago)*, **66**, 366.  
 DANIS, P., FARNIR, A., and TOUSSAINT, D. (1966). *Bull. Soc. belge Ophthalm.*, **142**, 439.  
 DOWLING, J. L. Jr., and SMITH, T. R. (1960). *Arch. Ophthalm. (Chicago)*, **64**, 236.  
 EDINGTON, G. M., and SARKIES, J. W. R. (1952). *Trans. roy. Soc. trop. Med. Hyg.*, **46**, 59.  
 FOULDS, W. S. (1963). *Trans. ophthalm. Soc. U.K.*, **83**, 345.  
 FRIEDENWALD, J. S. (1950). *Amer. J. Ophthalm.*, **33**, 1187.  
 GOODMAN, G., VON SALLMANN, L., and HOLLAND, M. G., (1957). *A.M.A. Arch. Ophthalm.*, **58**, 655.  
 KUWABARA, T., and COGAN, D. G. (1960). *Arch. Ophthalm. (Chicago)*, **64**, 904.  
 LOEWENSTEIN, A., and GARROW, A. (1945). *Amer. J. Ophthalm.*, **28**, 840.  
 LORENTZEN, S. E. (1959). *Acta ophthalm. (Kbh.)*, **37**, 279.  
 MAHNEKE, A., and VIDEBAEK, A. (1964). *Ibid.*, **42**, 201.  
 OLIVEIRA, F. DE (1966). *Brit. J. Ophthalm.*, **50**, 134.  
 STEPHENS, D. J. (1936). *Proc. Soc. exp. Biol. (N.Y.)*, **35**, 251.  
 TOUSSAINT, D., and DANIS, P. (1965). *Arch. Ophthalm. (Chicago)*, **74**, 470.  
 ——— and FARNIR, A. (1966). *Bull. Soc. belge Ophthalm.*, **143**, 568.  
 WISE, G. N. (1957). *A.M.A. Arch. Ophthalm.*, **57**, 151.  
 WOLTER, J. R. (1961). *Arch. Ophthalm. (Chicago)*, **66**, 545.