

PROGRESSIVE BIFOCAL CHORIO-RETINAL ATROPHY*† **A RARE FAMILIAL DISEASE OF THE EYES**

BY

A. A. DOUGLAS, I. WAHEED, AND C. T. WYSE

Department of Ophthalmology, University of St. Andrews

THE proband, an intelligent and rather talkative woman aged 63 years, was seen by one of us (A.A.D.) for blind certification. The fundus appearances were highly unusual. She stated that she was a member of a large kinship living in Dundee, many members of which were affected by a disease of the eyes similar to her own. Her knowledge of the family history was so accurate and extensive and her interest so obvious that it was decided to undertake a detailed study of the disease and its inheritance.

The first known affected member had worked as a milk-roundsman in Dundee in the middle of the 19th century. We were able to trace 91 members of the kinship, 33 of whom were affected. Our task was greatly simplified by the fact that the family is exceptionally closely-knit and its members intelligent and most co-operative.

THE EARLY APPEARANCES AND THEIR EVOLUTION THROUGHOUT THE LIVES OF THE AFFECTED INDIVIDUALS

The youngest affected individual was 3 weeks old at the time of examination and the oldest 67 years, the numbers at intermediate ages being sufficiently large to enable a composite picture to be built up of the evolution of the disease from birth to old age. It is convenient to describe three stages corresponding to different age groups:

- Stage 1 Birth to 14 years
- Stage 2 15-45 years
- Stage 3 46+ years

STAGE 1—THE TEMPORAL FOCUS

At 3 weeks of age retinal and choroidal tissues are already absent from the central part of the fundus corresponding roughly to the area normally occupied by the macula. The floor of this area (the temporal focus) is uniformly white; it shows little pigment and only a few vessels. While the nasal, upper, and lower edges are clear-cut, the temporal edge is irregularly serrated, small tongue-like processes of atrophy appearing to invade the chorio-retinal tissue in a temporal direction. In this transition zone some of the larger choroidal vessels are visible. As time passes the focus enlarges in all directions, the upper and lower margins nearly reaching but never passing the superior and inferior temporal vessels. The temporal margin retains its special characters. Towards the end of this stage, a band of pigmentary degeneration (not shown in the diagram), similar to that seen in ageing and myopic eyes, appears at the equator. The rest of the fundus remains normal (Fig. 1, opposite).

* Received for publication December 7, 1967.

† Address for reprints: Department of Ophthalmology, 10 Dudhope Terrace, Dundee.

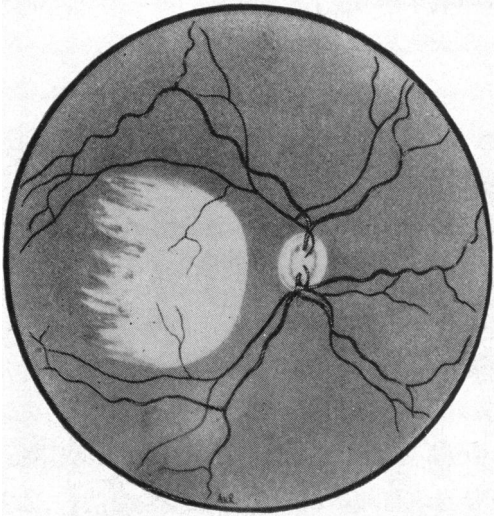


FIG. 1.—Stage 1, temporal focus (diagrammatic).

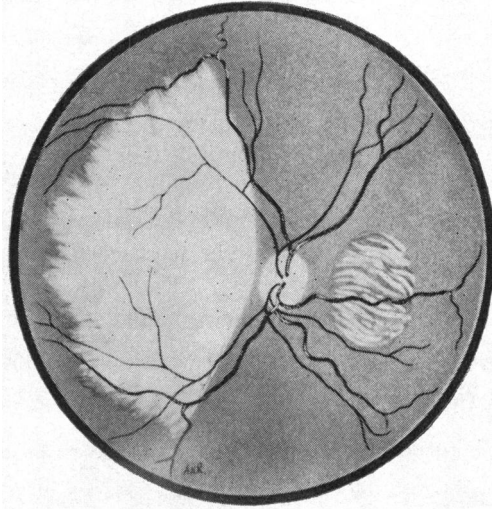


FIG. 2.—Stage 2, showing well-developed temporal focus and beginning of nasal focus (diagrammatic).

STAGE 2—APPEARANCE OF THE NASAL FOCUS

During this stage the temporal focus enlarges still further. Its temporal edge, which retains an irregular serrated appearance, extends nearly to the equator. The nasal edge reaches nearly to the disc while the upper and lower edges extend past the superior and inferior temporal vessels which may be seen, somewhat attenuated, on a background of sclera.

Later a second focus of atrophy (the nasal focus) appears to the nasal side of the disc. At the beginning it takes the form of small round areas of degeneration which gradually become confluent resulting in a roughly circular lesion, the edges of which have a ragged serrated appearance. Some attenuated vessels and strips of degenerating chorio-retinal tissue can be seen to cross its floor. Its diameter at the end of this stage amounts to that of three optic discs. The zone of pigmentary degeneration at the equator becomes wider and more intense, while the remainder of the fundus between the lesions loses the strictly normal appearance of the previous stage and shows some patchy depigmentation and choroidal sclerosis (Figs 2 and 3).

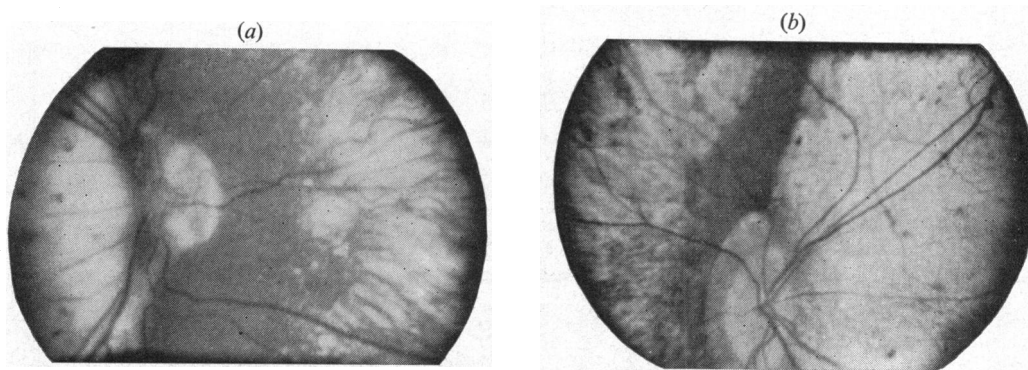


FIG. 3.—Stage 2, fundus photographs of neighbourhood of optic disc. The disease is more advanced in Fig. 3b.

STAGE 3—FURTHER EXTENSION OF THE FOCI

During Stage 3 the nasal and temporal foci enlarge still further so that the state of affairs seen in the proband is reached, narrow isthmuses of comparatively normal retina stretching from a circumpapillary mainland to join a zone of retina round the equator. In the most advanced cases the isthmuses themselves disappear so that only an island of retina round the disc remains; rather curiously the peripheral band of retina which shows more or less pigmentary degeneration tends to persist. The intervening area is apparently simply sclera upon which a few scattered patches of pigment remain and over which some rather attenuated retinal vessels pass. The optic disc becomes slightly pale but never completely atrophic. Sight is never completely lost (Figs 4 and 5).

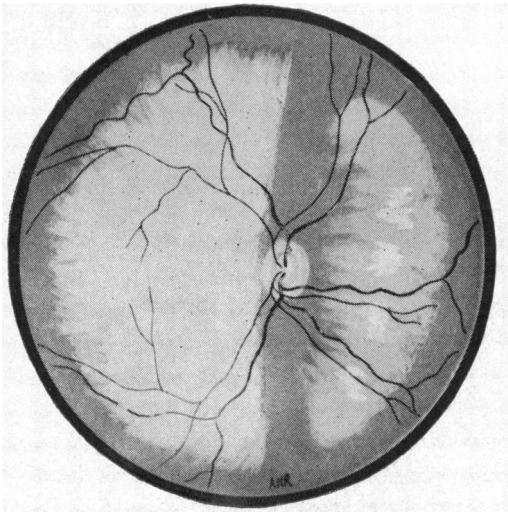


FIG. 4.—Stage 3. A large temporal and a smaller nasal focus are seen. Narrow bands of comparatively normal fundus connect the circumpapillary area to the periphery (diagrammatic).

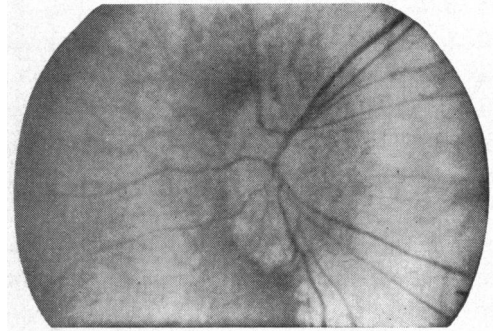


FIG. 5.—Stage 3. Fundus photograph of disc and its neighbourhood. Very little normal fundus remains above and below the disc.

THE FIELDS OF VISION

None of the patients was able to maintain fixation. Their eyes undergo constant coarse nystagmoid movements when attempting to fix with the more normal retinal areas to the nasal side of the disc. Formal field testing is thus impossible and it can only be said that on testing by confrontation it would appear that the field corresponds roughly to the areas of healthy retina remaining.

REFRACTIVE STATE

26 affected members of the kinship are alive, and information about the refractive state of nineteen of them is available (Table I, opposite). Accurate refraction is not possible because of the constant rapid and coarse nystagmoid movement of the eyes. Generally it may be said that the young are nearly emmetropic; myopia becomes usual in the second decennium and increases slightly throughout life. Only one affected member over the age of 40 is not myopic. The unaffected members of the family are emmetropic or hypermetropic. None is myopic.

TABLE I
REFRACTIVE STATE OF NINETEEN AFFECTED PERSONS

Age (yrs)	Hypermetropia	Myopia	
		up to -5D	over -5D
0-10	3		
11-25		5	3
26-40			3
41+	1		4

VISUAL ACUITY

Of the 22 examined, two had acuities of 6/36 and five of 6/60. The remainder were able to count fingers at one metre, except one woman, affected by lens sclerosis, whose vision was limited to hand movements.

OCULAR MOTILITY

A rapid searching type of nystagmus with a large amplitude of excursion is characteristic of the persons affected, all of whom have an alternating convergent squint and use the nasal retina of the convergent eye for "fixation". As the nasal retina becomes reduced in extent, the nystagmoid movements become coarser.

COLOUR VISION

The affected persons assert that their ability to recognize colours is as good as that of their normal brothers, sisters, or cousins.

For testing colour vision Holmgren's "wool test" seemed an obvious choice for individuals whose ability to distinguish colours depends on a mass cone response and whose poor visual acuity virtually rules out tests with pseudo-isochromatic plates. Seven patients had the wool test and all gave very good performances.

INHERITANCE

From the pedigree chart, which includes 91 individuals (Fig. 6), the following conclusions may be drawn:

- (1) The disease is inherited only from affected individuals. There is no carrier state.

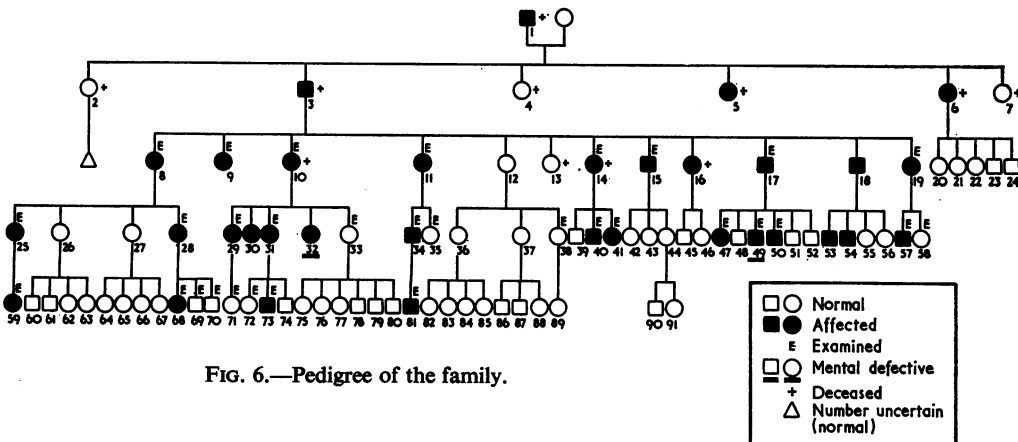


FIG. 6.—Pedigree of the family.

(2) In each generation the offspring of affected individuals is normal or affected in a ratio of 1 : 1 or nearly (Table II),

(3) The mode of inheritance is clearly autosomal dominant.

(4) There are no consanguineous marriages.

(5) There is a curious numerical predominance of female over male which applies not only to the affected persons but also to the unaffected and to the whole kinship (Table III).

TABLE II
DISTRIBUTION OF AFFECTED AND UN-AFFECTED INDIVIDUALS AMONG THE OFFSPRING OF AFFECTED INDIVIDUALS IN FOUR GENERATIONS

Generation	Affected	Unaffected
II	3	3
III	10	7
IV	15	16
V	4	5
Total	32	31

TABLE III
SEX DISTRIBUTION IN THE KINSHIP

Sex	Female	Male	Total	Ratio
Affected persons	19	14	33	1.4 : 1
Unaffected persons	40	18	58	2.2 : 1
Whole kinship	59	32	91	1.8 : 1

These figures were submitted to Mr. J. Pearson of the Department of Public Health and Social Medicine, Queen's College, Dundee, who confirmed that the observed sex ratio in the family is abnormal. Comparison with population figures in Scotland produced a χ^2 of 9.41 including a significant difference at the 0.005 level. There was no significant difference in sex ratios between the affected and unaffected groups.

DARK ADAPTATION

The instrument used was an adaptometer developed in the Department of Physiology of the University of St. Andrews by Dr. A. Chaloner.

The light source is a 12 volt lamp controlled and kept constant by a rheostat. The brightness of the test area, which is glazed by white translucent perspex, is altered by two discs bearing neutral density filters, combinations of which can be used to test with 0.5 log. unit of brightness in gradations of 0.25 unit.

In testing, after bleaching, filters of increasing density are placed in front of the light source between it and the test patch. The time taken to see each gradation is charted. It will be appreciated that the test as carried out in the affected individual is perforce one of mass cone and rod response since no fixation is possible. Fig. 7 (opposite) shows curves from a normal subject and from patients in different stages of the disease. It will be seen that in the early stages there is a well-marked α point with indications of diminished rod function in most cases. In the later stages there is no α point and rod function is further reduced.

Only patients in Stage 3 admit to serious difficulty in conditions of reduced illumination.

ELECTRORETINOGRAPHY

Two subjects, both female, aged 27 and 32, and both in Stage 2 of the disease agreed to be investigated. The contact lens used was that of Henkes. It was impossible for the patients

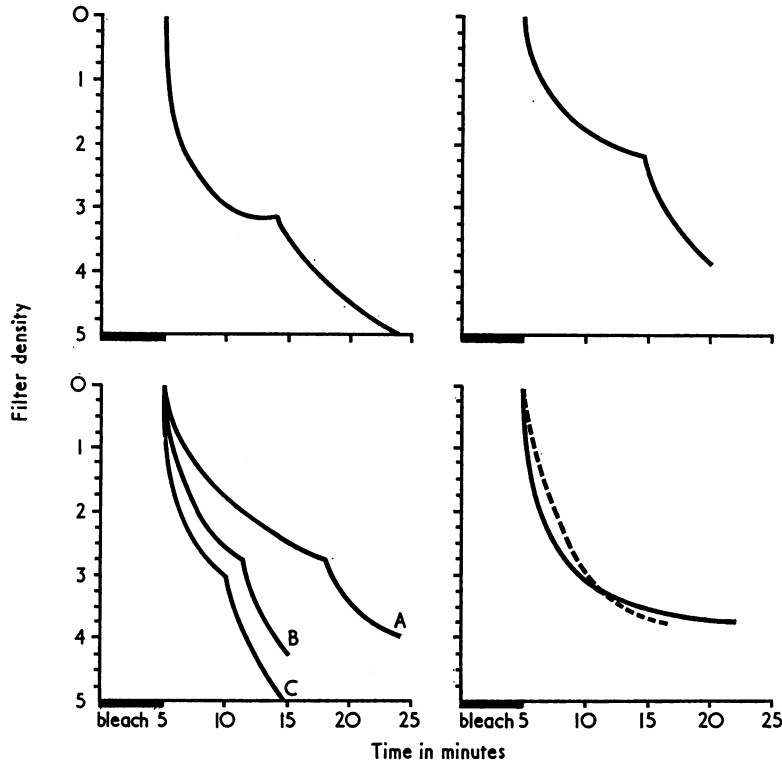


FIG. 7.—Above left, normal subject.
 Above right, a patient aged 5 years.
 Below left, curves from three affected individuals in Stage 2.
 Below right, curves from two affected individuals in Stage 3.

to maintain fixation in the true sense; they were told to relax as much as possible so that the involuntary ocular movements might be minimized.

Flicker ERG

Tracings at 30 flashes per second were obtained. The potentials in the patients' cases were 30 and 40 μ V compared with 80 μ V in a normal control.

Scotopic ERG

In spite of the impossibility of suppressing the restless movements of the patients' eyes, reasonably good tracings were obtained. Both showed well-marked *a*-waves and rather short peaked *b*-waves, the potential of which is considerably reduced by comparison with a normal control (Fig. 8).



FIG. 8.—Scale drawing of a single electroretinogram (left) and a normal control (right). The amplitudes of the *b*-waves are 110 and 400 μ V respectively.

Such findings are what might be expected in a disease in which the comparatively normal appearance of the remaining chorio-retinal tissue, the good colour discrimination, and ability to adapt to darkness combine to suggest reduction in quantity rather than quality of receptor function.

DIFFERENTIAL DIAGNOSIS

While diagnosis presents no difficulty to the initiated, experience has taught us that there are possibilities of confusion with other abiotrophies in the course of which massive disappearance of chorio-retinal tissue may take place. These are (1) degenerative myopia, (2) generalized choroidal sclerosis, (3) choroideremia, (4) gyrate atrophy of the choroid and retina. In this connexion it is worth noting that as recently as 1935 Usher found it necessary to give reasons for believing that the last two, which had been described at the turn of the century, were distinct clinical entities. It has seemed useful to us to review all four briefly, pointing out differences and resemblances to the condition described above.

(1) *Degenerative myopia* is usually inherited as a dominant character (Waardenburg, 1963), as is progressive bifocal chorio-retinal atrophy (PBCRA). In the latter, however, (a) the myopic crescent is poorly developed (Figs 3 and 5), and (b) the temporal focus is larger, with a clear-cut nasal edge, and a characteristically frayed-looking temporal edge. Pigmentation, so characteristic of the myopic degenerative focus, is not marked, and haemorrhages, which Fuchs (1901) found common in myopia, are not seen. (c) The nasal focus also is large and not split into the discrete disseminated areas described in myopia by Salzmann (1902) and Behse (1908). There is nothing characteristic about the peripheral pigmentary changes of PBCRA. Similar alterations are seen in myopia and have their counterpart in the ageing eye (Vogt, 1924; Bücklers, 1929) and also in other chorio-retinal abiotrophies

(2) *Primary choroidal sclerosis*. Sorsby, Mason, and Gardener (1949), Sorsby and Crick (1953), and Sorsby and Davey (1955) sub-divide this disease into central and generalized forms. Of these only the second need be considered. It is inherited as a dominant character but differs from PBCRA in the age at onset (middle life), the absence of distinct temporal and nasal foci, and the characteristic ophthalmoscopic appearance of the choroidal vessels which are likened to white streaks.

(3) *Choroideremia*. Very full accounts of choroideremia in which the older literature is reviewed have been given by Bedell (1937), Waardenburg (1942), Goedbloed (1942), McCulloch and McCulloch (1948), Friedenwald, Wilder, Maumenee, Sanders, Keyes, Hogan, Owens, and Owens (1952), Sorsby, Franceschetti, Joseph, and Davey (1952), and Pameyer, Waardenburg, and Henkes (1960). It resembles PBCRA only very superficially, the two diseases having in common only extensive chorio-retinal atrophy. Choroideremia is a progressive disorder affecting males, female relatives (the carriers) having a non-progressive pigmentary retinopathy. It is transmitted as an intermediate sex-linked character. In the later stages there is very extensive atrophy spreading from the mid-periphery, the macula being spared (Werkle, 1931).

(4) *Gyrate atrophy of the choroid and retina*. This rare disease was described in detail some 70 years ago by Cutler (1895), Fuchs (1896), and Bednarski (1900). The disease is often familial and consanguinity of parents has frequently been noted. Waardenburg (1961) considered that it behaved as an autosomally recessive character. Nightblindness and poor colour discrimination are noticed first at from 6 to 30 years of age. The retinal lesions illustrated in the papers by Bednarski (1900), Davis and Sheppard (1940), and McGuire and McGuire (1941) show large atrophic areas with irregularly curved edges forming fantastic scalloped shapes quite unlike the roundish temporal and nasal foci of PBCRA. The macula is spared (Werkle, 1931).

DISCUSSION

Ophthalmology is such a venerable specialty, with such a vast literature, that he would be a bold man indeed who claimed that a nosological entity, however unusual it seemed, had never been described before. All that can be said in the present instance is that perusal of the more comprehensive texts failed to discover any description of a condition exactly like this or even resembling it closely. The works consulted have included the relevant volume of the Graefe-Saemisch-Hess Handbuch (Leber, 1916), and the text books by Schieck and Brückner (1930), Waardenburg, Franceschetti, and Klein (1961, 1963), Ballantyne and Michaelson (1962), Thiel (1963), Sorsby (1964), and Duke-Elder (1964, 1966). In addition, a number of original papers has been consulted, some of which are referred to above.

The discovery of a well-developed temporal focus in a 3-weeks-old infant leads to the conclusion that PBCRA is congenital in the strict sense while its progressive nature allows it to be classified with the abiotrophies. In any case, as Sorsby (1966) said, no clear distinction need be made between the ocular congenital abnormalities and abiotrophies. Many of the former are progressive while the latter impose themselves upon tissues healthy only in appearance, functional impairment being frequently demonstrable before morphological or ophthalmoscopic change.

If it can be accepted that PBCRA is a nosological entity, very interesting questions arise concerning the layer primarily affected and the nature of the pathological processes that lead to such dramatic and extensive disappearance of the retino-choroidal tissue-complex including the retinal pigment epithelium. Unfortunately up to the present it has not proved possible to obtain an eye for pathological examination. Nevertheless some evidence is at our disposal from which it is legitimate to draw inferences though of course these must be very largely conjectural.

In the first place there was no ophthalmoscopic evidence of scleral ectasias such as are known to occur in pathological myopia and the sclera can probably be ruled out as actively concerned in the disease.

A very noteworthy feature of PBCRA is the persistence of good photopic and scotopic function (though not of course of visual acuity) until an advanced stage of the disease. In this it differs from gyrate atrophy and choroideremia and resembles choroidal sclerosis and myopic degeneration. Possibly, as in the case of choroidal sclerosis, this suggests a primary choroidal rather than a retinal disorder (Sorsby and others (1949)). The partial conservation of the electroretinogram is against widespread involvement of the sensory epithelium of the areas of normal-seeming retina which remain near the disc even in the most advanced cases. Among the more puzzling features are:

- (1) The comparative absence of pigment either in the floor of the foci or surrounding them. The earliest stage of the temporal focus has never been observed. Presumably it occurs during intra-uterine life; but during the later stages there is only a fine pigment dusting of the exposed sclera and no pigment surround (Figs 3 and 5), while the nasal focus, which has been observed from its commencement, shows very little pigment (Figs 2, 3, and 4). These appearances may be contrasted with those of the atrophic patches seen in degenerative myopia in and around which pigment is prominent, and which gave rise to the idea, shown to be erroneous by Salzmann (1902), that they were inflammatory.

- (2) The rapidity with which traces of the choroidal vessels disappear from the floor of the foci is also striking and characteristic and suggests that the atrophic process, whatever its

nature, extends in depth almost contemporaneously with length and breadth. The position of the foci corresponds to no arterial or venous distribution.

(3) The presence of alternating convergent squint in all the affected persons is presumably due to the presence of the temporal focus which prevents the development of normal fixation. As a substitute indirect vision with the then unaffected nasal retina is adopted, the image of the observed object probably falling upon a functionless area in the fundus of the fellow eye.

SUMMARY

An account is given of a very rare and possibly unique degenerative disease of the fundus oculi which affects 33 members of a kinship of 91 individuals. The mode of inheritance is autosomal dominant. Clinically it is characterized by two distinct foci of atrophy, a nasal and a temporal. The temporal focus is probably connatal while the nasal focus appears early in life. The disease progresses to a stage when all that remain of the chorio-retinal tissue are narrow strips above and below the disc and a narrow zone at the periphery. Vision is never entirely lost. Other features are myopia, convergent squint, and some pigmentary changes at the retinal periphery. Good colour vision and the ability to see in reduced illumination are preserved until a late stage. Both the photopic and scotopic ERG are partially conserved. The patients are of normal intelligence. Progressive bifocal chorio-retinal atrophy is suggested as a suitable name for the disease. Generalized choroidal sclerosis, choroideremia, gyrate atrophy, and degenerative myopia all have certain resemblances to this condition but all differ from it in various ways and can be rejected as alternative diagnoses.

Most of the clinical work for this publication was carried out by one of us (I.W.) who at the time was a registrar in the Ophthalmic Department at Dundee Royal Infirmary. We should like to thank Mr. I. M. Strachan for help with electroretinography, Mr. Anthony Rollason, medical artist, and Mr. F. M. Duncan, photographic technician, and Mrs. I. C. Gates, secretary, both of the Department of Ophthalmology, University of St. Andrews. A retinal camera donated by the W. H. Ross Foundation (Scotland) for the Study and Prevention of Blindness was used to take a large number of coloured photographs. Many of these proved unsuitable for reproduction in black and white but could be made available on request.

REFERENCES

- BALLANTYNE, A. J., and MICHAELSON, I. C. (1962). "Textbook of the Fundus of the Eye". Livingstone, Edinburgh.
- BEDELL, A. J. (1937). *Arch. Ophthalm. (Chicago)*, **17**, 444.
- BEDNARSKI, A. (1900). *Arch. Augenheilk.*, **40**, 420.
- BEHSE, E. (1908). *v. Graefes Arch. Ophthalm.*, **67**, 379.
- BÜCKLERS, M. (1929). *Ibid.*, **121**, 243.
- CUTLER, C. W. (1895). *Arch. Ophthalm. (Chicago)*, **24**, 334.
- DAVIS, W. T., and SHEPPARD, E. (1940). *Ibid.*, **23**, 1252.
- DUKE-ELDER, S. (1964). "System of Ophthalmology", vol. 3, pt 2, p. 619. Kimpton, London.
- (1966). *Idem*, vol. 9, p. 699.
- FRIEDENWALD, J. S., WILDER, H. C., MAUMENEE, A. E., SANDERS, J. E., KEYES, J. E. L., HOGAN, M. L., OWENS, W. C., and OWENS, E. U. (1952). "Ophthalmic Pathology", p. 380. Saunders, Philadelphia.
- FUCHS, E. (1896). *Arch. Augenheilk.*, **32**, 111.
- (1901). *Z. Augenheilk.*, **5**, 171.
- GOEDBLOED, J. (1942). *Ophthalmologica (Basel)*, **104**, 308.
- LEBER, T. (1916). "Die Pigment degeneration der Netzhaut" in "Die Krankheiten der Netzhaut", "Graefes-Saemisch-Hess Handbuch der gesamten Augenheilkunde", 2nd ed., bd. 7, p. 1076. Engelmann, Leipzig.

- McCULLOCH, C., and McCULLOCH, R. P. J. (1948). *Trans. Amer. Acad. Ophthal. Otolaryng.*, **52**, 160.
- McGUIRE, H. H., and McGUIRE, W. P. (1941). *Amer. J. Ophthal.*, **24**, 657.
- PAMEYER, J. K., WAARDENBURG, P. J., and HENKES, H. E. (1960). *Brit. J. Ophthal.*, **44**, 724.
- SALZMANN, M. (1902). *v. Graefes Arch. Ophthal.*, **54**, 337.
- SCHIECK, E., and BRÜCKNER, A. (1930). "Kurzes Handbuch der Ophthalmologie". Springer, Berlin.
- SORSBY, A. (1964). "Modern Ophthalmology", vol. 3, p. 287. Butterworths, London.
- (1966). *Trans. ophthal. Soc. U.K.*, **86**, 417.
- and CRICK, R. (1953). *Brit. J. Ophthal.*, **37**, 129.
- and DAVEY, J. B. (1955). *Ibid.*, **39**, 257.
- , FRANCESCHETTI, A., JOSEPH, R., and DAVEY, J. B. (1952). *Ibid.*, **36**, 547.
- , MASON, M. E. J., and GARDENER, N. (1949). *Ibid.*, **33**, 67.
- THIEL, R. (1963). "Atlas of Diseases of the Eye", vol. 2. Elsevier, Amsterdam.
- USHER, C. H. (1935). *Trans. ophthal. Soc. U.K.*, **55**, 164.
- VOGT, A. (1924). *Klin. Mbl. Augenheilk.*, **72**, 212.
- WAARDENBURG, P. J. (1942). *Acta ophthal. (Kbh.)*, **20**, 235.
- (1961). In "Genetics and Ophthalmology", by P. J. WAARDENBURG, A. FRANCESCHETTI, and D. KLEIN, vol. 1, p. 797. Blackwell Scientific Publications, London.
- (1963). *Idem*, vol. 2, p. 1250.
- WERKLE, F. C. (1931). *Klin. Mbl. Augenheilk.*, **87**, 173.