

FLUORESCIN PHOTOGRAPHY OF GENERALIZED DOMINANT FUNDUS DYSTROPHY*†

BY

E. S. ROSEN AND D. LEIGHTON

Department of Ophthalmology, University of Manchester

SORSBY, Mason, and Gardener (1949) described five families with a generalized type of fundus dystrophy which they concluded to be an autosomal dominant abiotrophy. In these families the affected members all suffered a deterioration of vision with onset in the early to mid-forties. The dystrophy was particularly characterized by massive pigmentary changes and choroidal sclerosis of the posterior pole of the eye. With the progression of the degeneration some changes were also recognized more peripherally.

We have examined a family, several members of which were affected by a fundus dystrophy of the type described by Sorsby; our purposes in investigating this family by the technique of fluorescein fundus photography were: to illustrate the fundus changes in the affected members, to investigate the possibility of anticipating the later onset of the dystrophy in the younger, unaffected members of the family, and to demonstrate some diagnostic features of the dystrophy—namely the changes in the retinal pigment epithelium and choroid and their extent. The fundus appearances in the propositus are shown in Figs 1 and 2.

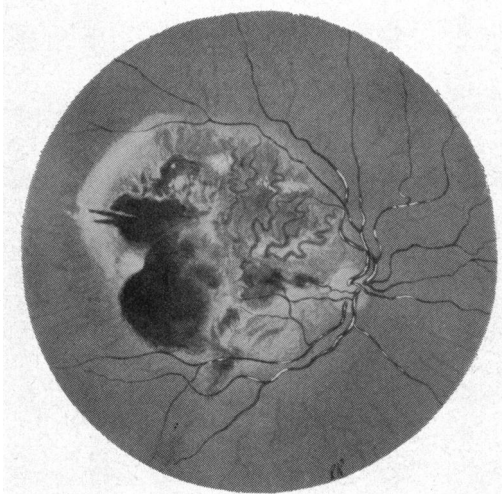


FIG. 1.—Case 1. Fundus painting of right eye.

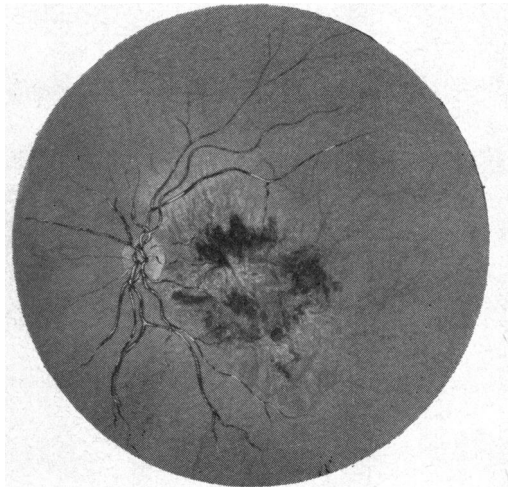


FIG. 2.—Case 1. Fundus painting of left eye.

Material

In the family investigated three siblings were affected and their mother and her sister, now deceased, had become blind in middle life. Eleven members of the family were examined and six of them, including two affected ones, were available for the photographic investigation. The significant features of these eleven members of the family are summarized in the Table (opposite).

* Received for publication January 8, 1968.

† Address for reprints: Dr. E. S. Rosen, Manchester Royal Eye Hospital, Oxford Rd., Manchester, 13.

TABLE
PARTICULARS OF TWELVE CASES

Patient	Sex	Relationship	Age (yrs)	Age at Onset (yrs)	Visual Acuity		Ophthalmoscopy Right and Left		Photo-graphic Studies	Fluorescein Features	
					Right	Left	Posterior Pole	Periphery		Posterior Pole	Periphery
1	F	Propositus	60	43	HM	HM	Pigment clumping and choroidal vessel atrophy	Some colloid bodies	+	Massive pigmentary and vascular disturbances (Figs 1 to 6)	
2	F	Sister	64	44	HM	HM	Pigment clumping and choroidal vessel atrophy	Mild pigmentary mottling	+	As above	
3	M	Brother	62	42	HM	HM	Pigment clumping and choroidal vessel atrophy	Scattered clumps of pigment	-		
4	F	Sister	58	—	6/6	6/6	Colloid bodies	Equatorial pigment clumping	+	Normal vascular pattern Patchy disturbance of pigment epithelium	
5	F	Daughter of Propositus	32	—	6/6	6/6	Colloid bodies	Normal except for isolated healed chorio-retinal lesion supero-nasally (L)	+	Generalized fine mottling of pigment epithelia (Fig. 7)	
6	F	Daughter of Propositus	29	—	6/6	6/6	Normal	Normal	+	Normal appearance	
7	F	Niece (Daughter of 4)	25	—	6/6	6/6	Colloid bodies	Normal	+	Normal appearance	
8	M	Nephew (Son of 4)	29	—	6/6	6/6	Normal	Normal	-		
9	F	Sister of Propositus	44	—	6/6	6/6	Colloid bodies	Normal	-		
10	F	Niece (Daughter of 9)	13	—	6/6	6/6	Normal	Normal	-		
11	M	Nephew (Son of 9)	16	—	6/6	6/6	Normal	Normal	-		
12	F	Sister of Propositus	55	—	6/6	6/6	Not available for examination Asymptomatic				

Methods

Those members of the family who were available for photographic studies had both fundi photographed after pupillary dilatation by homatropine 5 per cent. and cocaine 2 per cent. drops. Colour photographs on Kodachrome II film of the posterior pole and periphery of each eye were taken with a Zeiss fundus camera. The patient then received an intravenous injection of 3 ml. 25 per cent. sodium fluorescein in the ante-cubital vein. Fluorescence photographs were then taken, the Zeiss camera being modified for fluorescence photography on Ilford FP3 film by E.S.R. Exposures were made during the vascular phase of fluorescence in one eye and for several minutes afterwards in both eyes. Views of the posterior pole and the periphery of the fundi were taken.

Full details of the technique have been described elsewhere (Rosen, 1967).

Results

The fluorescein photographs clearly demonstrated the integrity of, or the faults in, the retinal pigment epithelium, likewise the abnormalities in the vascular arrangements at the posterior pole in affected eyes were well illustrated. The results in the individual cases are described in the Table and illustrated in Figs 3-7 (overleaf).

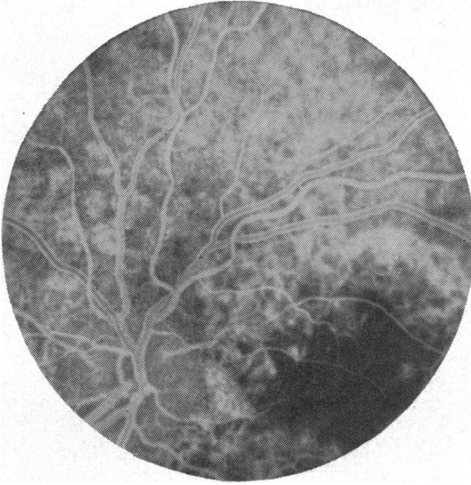

FIG. 3.—Case 1, left eye. Fluorescence photograph—early venous phase—showing defects in retinal pigment epithelium above disc.

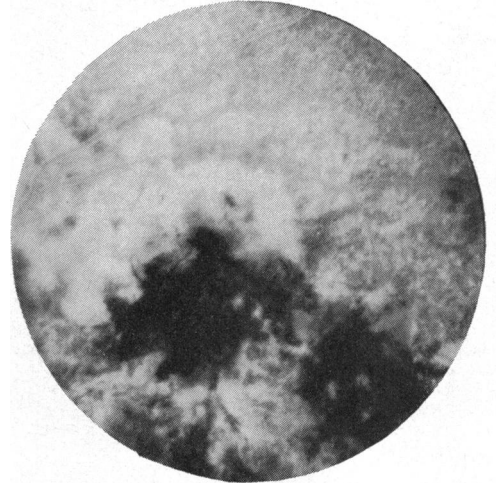


FIG. 4.—Case 1, left eye. Fluorescence photograph—late venous phase.

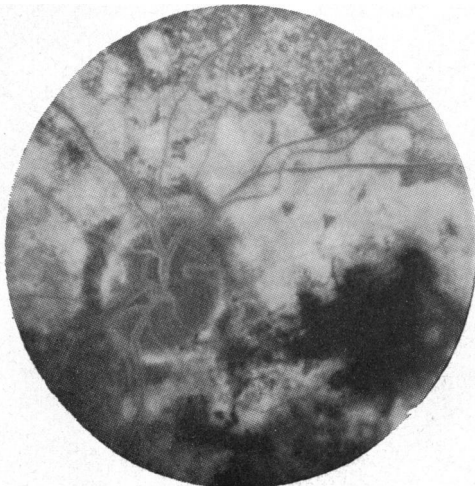

FIG. 5.—Case 1, left eye. Fluorescence photograph 3 min. after injection. Persistent fluorescence of choroid and sclera demonstrates extent of pigmentary defect.

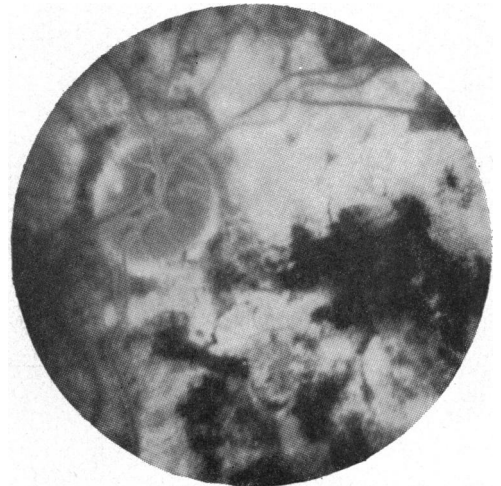

FIG. 6.—Case 1, left eye. Fluorescence photograph 10 min. after injection. Fluorescence intensity is maximal.

The changes at the posterior pole in the affected eyes are dramatic (Figs 3–6), but more peripherally the appearance of rosette and fine mottling of the pigment epithelium were very evident, when clinically they were much less obvious.

Of the asymptomatic members of the family, Case 4 had some scattered and some confluent small areas of rarefaction of the pigment epithelium at the posterior poles. She also had some clumping of pigment at the equatorial regions of the fundi.

In Case 5, the 32-year-old daughter of the propositus, a generalized abnormality of the pigment epithelium was revealed by fluorescence photography. This took the form of generalized fine mottling (Fig. 7).

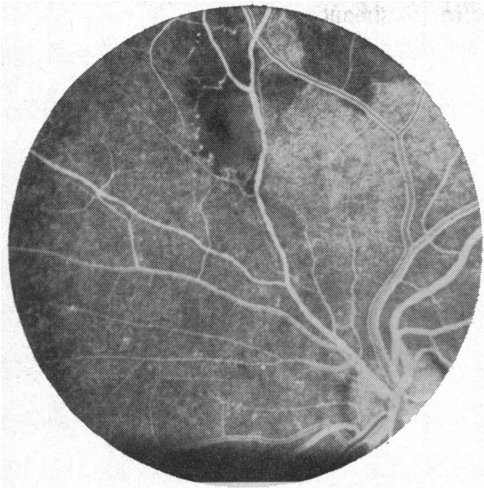


FIG. 7.—Case 5, left eye. Fluorescence photograph—early venous phase—note fine mottling of retinal pigment epithelium, irregular calibre of superonasal artery and non-fluorescent lesion associated with it.

Changes of this nature but coarser in texture were seen in the peripheral retinal pigment epithelia of the affected members of the family. The left supero-nasal retinal artery of Case 5 showed a generalized irregularity of calibre, and microaneurysmal dilatations of capillaries associated with this artery were seen adjacent to an avascular lesion on its course which clinically had the grey-white appearance of scar tissue.

Discussion

Clinically the affected members of the family described satisfied the diagnostic criteria for the generalized fundus dystrophy of Sorsby and others (1949), *i.e.* an abiotrophic fundus lesion that is a dominant affection, becoming manifest at about the age of 40 years, beginning as a central lesion and progressing to extreme choroidal atrophy with pigmentation. Burn (1950) documented a further affected family. Duke-Elder and Perkins (1966) referred to the condition as the "pseudo-inflammatory macular dystrophy of Sorsby".

The dystrophy commences with oedema, haemorrhages, and exudates in the central area of the fundus and progresses to gross scarring and pigmentation. The main histological findings of both Ashton and Sorsby (1951) and Babel (1958) are of gross atrophic changes in the choroid, fibrous mural degeneration of remaining choroidal vessels, and widespread degeneration of the elastic lamina of Bruch's membrane. Neovascularization of the retina from choroidal sources occurs through breaks in Bruch's membrane. Widespread disturbance of the retinal pigment epithelium was also described.

Fluorescence photography of the fundus is well suited to the investigation of fundus dystrophies for changes in the retinal pigment epithelium are well demonstrated by the silhouetting of this layer against choroidal and scleral fluorescence. Thus these pigmentary abnormalities are seen clearly in the vascular phase of fluorescence (Figs 3 and 4), and the appearances persist for many minutes (Figs 5 and 6). Persistence of choroido-scleral fluorescence is a normal phenomenon but it will not be observed when the retinal pigment epithelium is intact (Rosen, 1968).

Of the asymptomatic members of the family, Case 4 had a definite but minor abnormality of the pigment epithelium possibly indicating incomplete penetrance of the gene. Case 5, too young yet to be affected, revealed two abnormalities: the healed inflammatory lesion

and the mottled pigment epithelium. It is interesting to speculate whether the abnormality of the pigment epithelium demonstrated may be an anticipation of gross changes which will appear later in the manifest dystrophy.

The family tree is shown in Fig. 8.

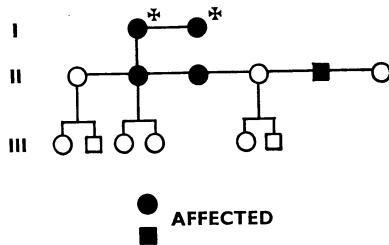


FIG. 8.—Pedigree, showing three generations.

Summary

A family with generalized fundus dystrophy was examined by ophthalmoscopy and fluorescein fundus photography. The features of the dystrophy revealed by both methods of examination are described. The fluorescein photographs reveal abnormalities of the pigmentation of the fundus which are not seen ophthalmoscopically. Abnormalities of the fundi of two asymptomatic members of the family were demonstrated by fluorescein photography.

We wish to thank Mr. Richard Neave of the Department of Medical Art, the University of Manchester, for the fundus paintings Figs 1 and 2.

REFERENCES

- ASHTON, N., and SORSBY, A. (1951). *Brit. J. Ophthalm.*, **35**, 751.
 BABEL, J. (1958). *Bull. Soc. franç. Ophtal.*, **71**, 389.
 BURN, R. A. (1950). *Brit. J. Ophthalm.*, **34**, 393.
 DUKE-ELDER, S., and PERKINS, E. S. (1966). "System of Ophthalmology", vol. 9, p. 715. Kimpton, London.
 ROSEN, E. S. (1967). *Manchester med. Gaz.*, **47**, No. 1, p. 8.
 ——— (1968). *Ibid.*, **47**, No. 2, p. 22.
 SORSBY, A., MASON, M. E. J., and GARDENER, N. (1959). *Brit. J. Ophthalm.*, **33**, 67.