

Histochemistry of corneal granular dystrophy

ALEC GARNER

Department of Pathology, Institute of Ophthalmology, University of London

Since the introduction by Jones and Zimmerman (1959, 1961) of a reliable histological scheme for the separate recognition of each of the three major categories of corneal stromal dystrophy, the way has been open for precise characterization of the nature of the lesions in each of these conditions. This has been largely accomplished for the macular and lattice dystrophies, the former having been shown to be an acid polysaccharide complex (Klintworth and Vogel, 1964; Morgan, 1966; Garner, 1969b), and the latter to consist largely of amyloid (Seitelberger and Nemetz, 1961; Klintworth, 1967; Garner, 1969a). Relatively little is known, however, about granular dystrophy, and the several electron microscopical studies which have been reported in recent years have, on account of the widely differing descriptions, not been conspicuously successful in resolving the problem. Thus McTigue (1965, 1967) described dense homogeneous masses which could not be resolved at magnifications of up to 71,000; workers in Japan (Kuwahara, Akiya, and Obazawa, 1967; Matsuo, Fujiwara, and Ofuchi, 1967) described rod-shaped structures; Sornson (1965) found both granular and fibrillar material; and Teng (1967) observed fine banded filamentous structures which he regarded as representing precollagen. Apart from the study of two cases of probable granular dystrophy, which were unusual in that the lesions were limited to the subepithelial region, by Goslar and Seitz (1961) and Seitz and Goslar (1963, 1965), there is a dearth of detailed histochemical information in this condition and it was for this reason that the present investigation was undertaken.

Material and methods

Nine full-thickness and two partial-thickness corneal discs removed at keratoplasty from patients with corneal granular dystrophy (Groenouw Type 1) and one from a patient in whom the lesion was confined to the space between the epithelium and Bowman's membrane were available for study.

The tissues were fixed in formol saline, embedded in paraffin wax, and sectioned at a thickness of 5 μ . In addition to haematoxylin and eosin, Masson trichrome, Van Gieson, and Wilder silver staining procedures, the following histochemical reactions were performed:

POLYSACCHARIDE

Periodic acid-Schiff

Alcian blue (pH 2.5)

Colloidal iron

Toluidine blue.

AMYLOID

Congo red

Crystal and methyl violet

Thioflavine T.

PROTEIN

Coupled tetrazonium

Ninhydrin-Schiff reaction for α -amino protein groups.

3-Hydroxy-2-naphthaldehyde method for protein-bound amino groups.

Mixed anhydride method for protein-bound carboxyl groups.

Dihydroxy-dinaphthyl-disulphide (DDD) reaction for sulphhydryl groups.

Thioglycollate-DDD method for combined sulphhydryl and disulphide groups.

Performic acid-Alcian blue method for disulphide groups.

Diazotisation-coupling (DC) method for tyrosine.

p-Dimethylaminobenzaldehyde (DMAB) reaction for tryptophan.

Sakaguchi reaction for arginine.

The protein and amino-acid reactions were performed according to the techniques described by Pearse (1968).

Results

All eleven corneae with stromal lesions contained eosinophilic granular deposits which were not birefringent and which gave an intense red colour with Masson's trichrome stain (Fig. 1), but no reaction with the periodic acid-Schiff (Fig. 2) or acid polysaccharide methods. They thus satisfied the criteria laid down by Jones and Zimmerman (1961) for the histological diagnosis of granular dystrophy. The deposits also showed the characteristic meshwork of branching argyrophilic fibres in sections stained by Wilder's method.

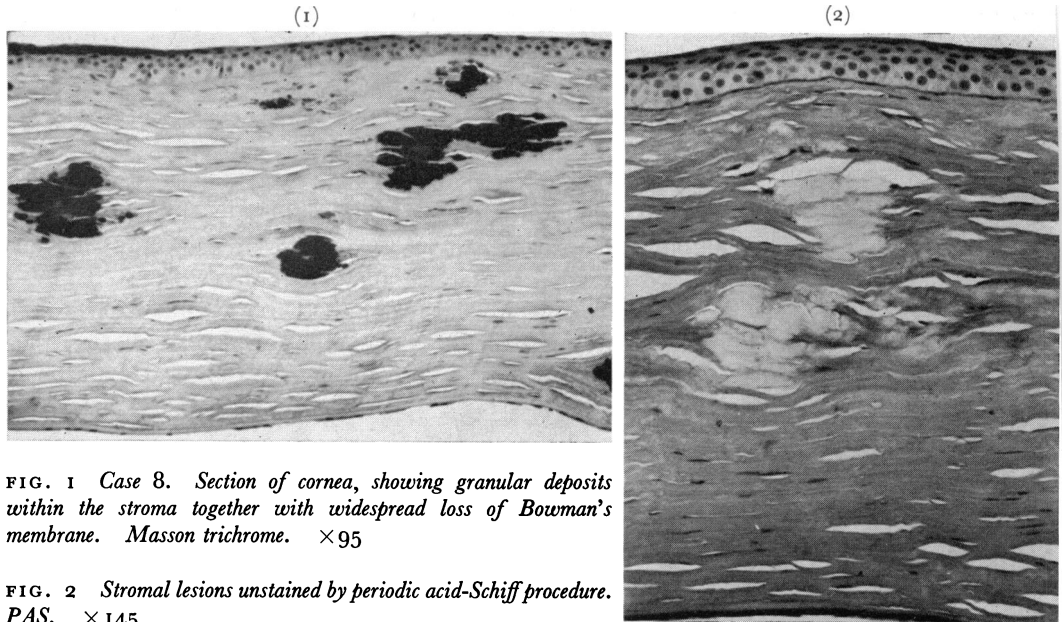


FIG. 1 Case 8. Section of cornea, showing granular deposits within the stroma together with widespread loss of Bowman's membrane. Masson trichrome. $\times 95$

FIG. 2 Stromal lesions unstained by periodic acid-Schiff procedure. PAS. $\times 145$

In three instances (Cases 8, 9, and 12) some of the deposits apparently included amyloid material. Thus they showed foci which stained positively with Congo red (Fig. 3), with green dichroism in polarized light, which were metachromatic with crystal violet in contradistinction to the orthochromasia of the surrounding granular material and which showed intense yellow fluorescence in ultra violet light after staining with Thioflavine T (Fig. 4). One of these corneae (Case 12), as well as including amyloid within the granular deposits, also showed lesions in the deep stroma which were morphologically and tincorially characteristic of lattice dystrophy.

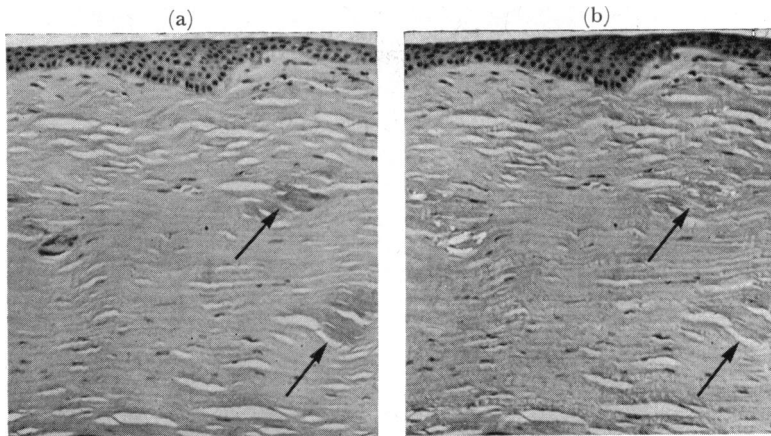


FIG. 3 Case 9. (a) While some deposits are unstained (arrows), others include foci of congophilic material (b) Viewed between crossed polarizing screens, the congophilic foci are birefringent and exhibit green dichroism. Congo red and haematoxylin. $\times 95$

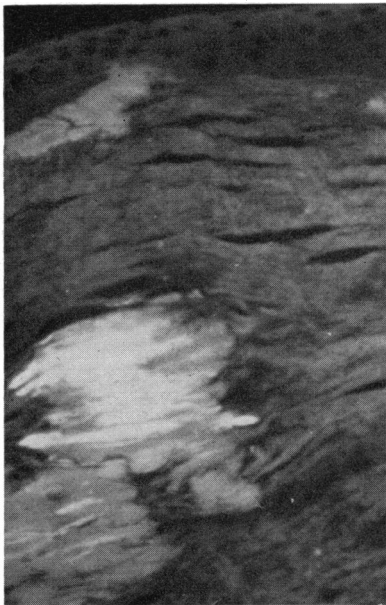


FIG. 4 Case 8. Some granular deposits exhibit areas of marked yellow-green fluorescence in ultraviolet light in contrast to the weak background fluorescence of the remaining deposits. Thioflavine T. $\times 195$

There was partial destruction of Bowman's membrane with subepithelial accumulation of granular material in all twelve cases and in some the deposits had spread into the potential space between the membrane and the epithelium. Case 11, which had presented a clinical diagnostic problem as well, was unusual in that, while there were widespread deposits within and immediately deep to the epithelium, there was a total absence of granular material in the substantia propria (Fig. 5).

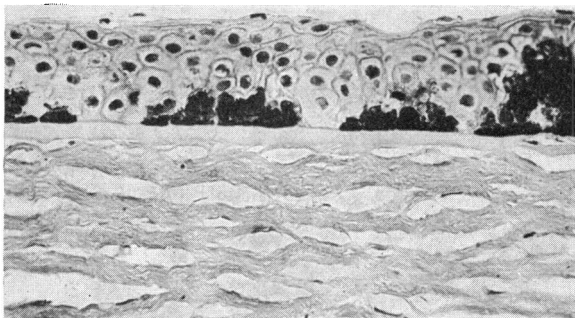


FIG. 5 Deposition of granular material is confined to the epithelial layer and separated from the substantia propria by a largely intact Bowman's membrane. Masson trichrome. $\times 235$

Staining for protein by the coupled tetrazonium method gave a uniformly strong reaction in all cases (Fig. 6). Reactions for protein-bound amino-groups were generally weak or absent by the ninhydrin-Schiff method (Fig. 7) and only moderately positive using the 3-hydroxy-2-naphthaldehyde method, a failure which could in part be attributable to

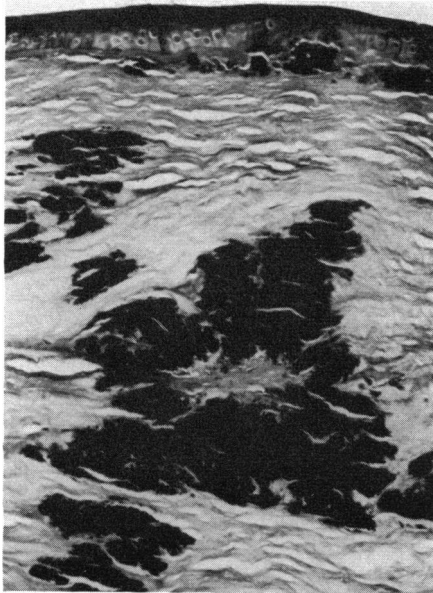


FIG. 6 Case 8. Granular lesions give an intense reaction for protein. Coupled tetrazonium reaction. $\times 115$

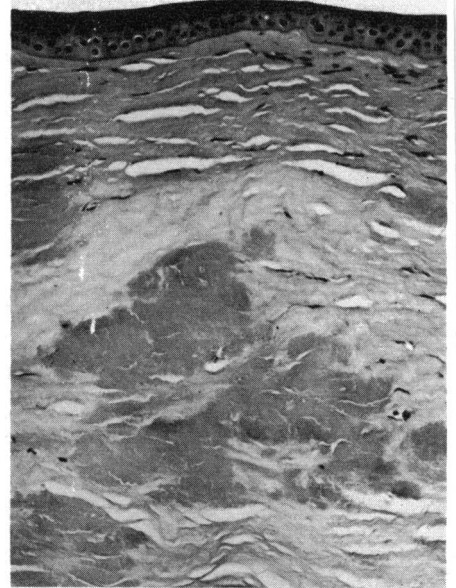


FIG. 7 Case 8. Lesions show a moderate reaction for free amino groups. Ninhydrin-Schiff. $\times 115$

formalin fixation (Pearse, 1968). Protein-bound carboxyl groups were by contrast readily demonstrable (Fig. 8). Sulphydryl groups were present in moderate amounts

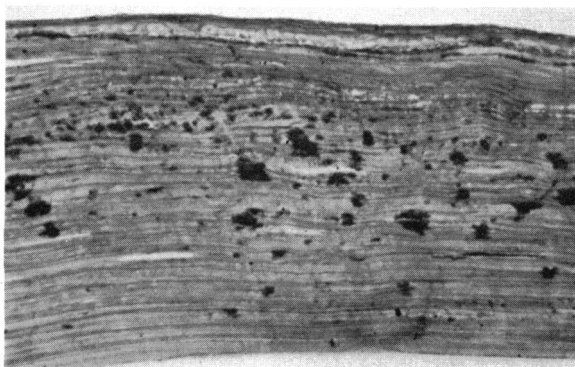


FIG. 8 Case 2. Stroma contains numerous small deposits which give a strong reaction for protein-bound carboxyl groups. Mixed anhydride reaction. $\times 145$

(Fig. 9), while sections pretreated with thioglycollate to reduce any disulphide groups to sulphydryl radicles gave a yet more intense response to the DDD reaction (Fig. 10). The performic acid-Alcian blue method for disulphide groups was, however, generally weak or negative, though assessment was made difficult by the acid polysaccharide-induced Alcianophilia of the surrounding stroma.

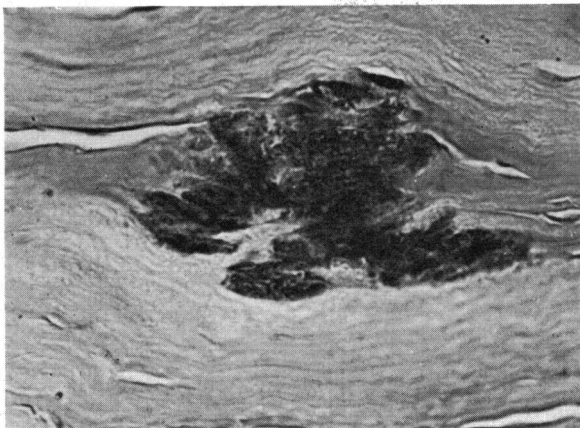


FIG. 9 Case 1. Granular lesions show a moderate reaction for sulphhydryl groups. DDD reaction. $\times 500$

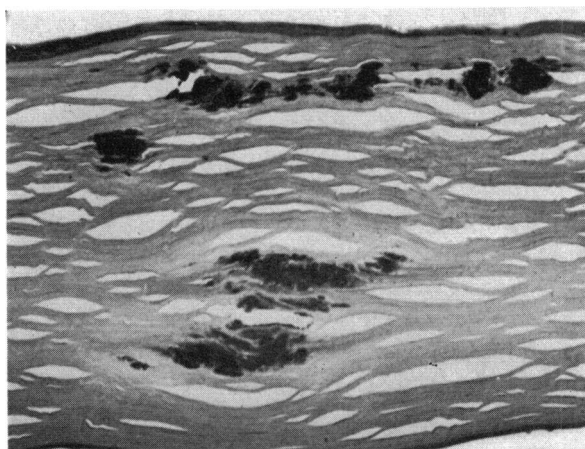


FIG. 10 Case 9. Deposits give a strong reaction for combined sulphhydryl and disulphide groups. Thioglycollate-DDD reaction. $\times 95$

Histochemical procedures for specific amino-acids indicated that the granular deposits were rich in tyrosine (Fig. 11, overleaf) and arginine (Fig. 12, overleaf), and that they contained moderate to slight amounts of tryptophan.

Individual results are presented in Tables I and II (overleaf).

Discussion

In the past it has been customary to regard the eosinophilic lesions in corneal granular dystrophy as foci of hyaline degeneration, a designation which, though it may be adequate on purely descriptive grounds, sheds little light on the pathogenesis of the disorder. Thus, hyaline is not a specific biochemical entity, its composition depending largely on the anatomical site involved and the nature of the predisposing disturbance (Wagner, 1967), although in the context of avascular connective tissue it is usually considered to be a product of some unspecified alteration in the collagenous matrix. Correspondingly, granular dystrophy has been regarded as a primary degeneration of the corneal stroma (Franceschetti and Babel, 1951; Jones and Zimmerman, 1961). Recently, however, the concept has been advanced that the disorder is not so much one of collagenous degeneration as one of a failure of newly-formed precollagenous filaments to aggregate into mature forms (Teng, 1967). In a combined histological and electron microscopical study, Teng described the extracellular accumulation of fine banded filaments measuring 40 to 80 Å

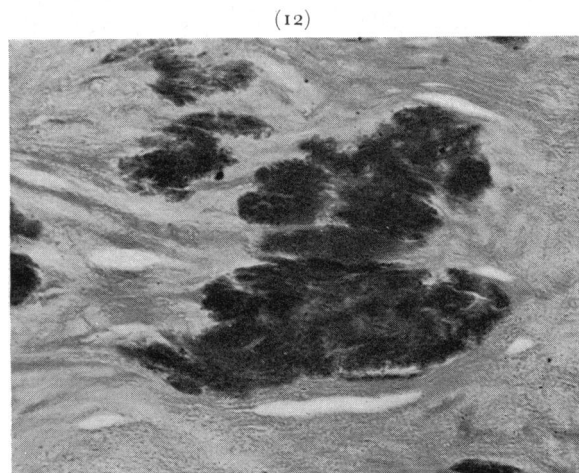
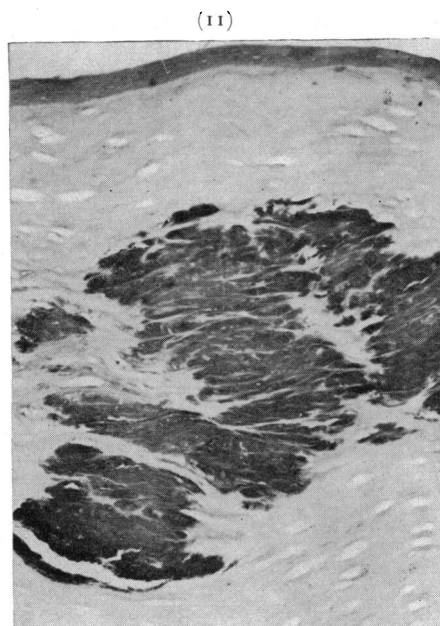


FIG. 11 Case 8. Marked reaction for tyrosine in granular lesions contrasts with weak response of stroma. DC reaction. $\times 115$

FIG. 12 Case 8. Deposits give a strong reaction for arginine. Sakaguchi reaction. $\times 235$

in diameter apparently formed within keratocytes which also showed degenerate Golgi systems. The latter finding was taken to reflect impaired synthesis of the acid polysaccharide required for the lateral aggregation of the supposed precollagen elements to form mature collagen. The histological demonstration of abundant argyrophilic reticulin fibres and the absence of stainable polysaccharide was thought to support this hypothesis.

Table I Histological staining reactions of the deposits in corneal granular dystrophy

Case no.	Age (yrs)	Sex	H.E. (Eosinophilia)	Wilder silver method	PAS	Alcian blue	Toluidine blue metachromasia	Colloidal iron	Van Gieson	Masson	Congo red ¹	Dichroism ²	Crystal violet metachromasia	Thioflavine T ³	Comments
1	35	M	+	+	-	-	-	-	Yellow	Red	-	-	-	±	
2	43	F	+	+	-	-	-	-	Yellow	Red	-	-	-	±	
3	50	F	+	+	-	-	-	-	Yellow	Red	-	-	-	±	Previous lamellar graft Deposits limited to host tissue
4	17	F	+	+	-	-	-	-	Yellow	Red	-	-	-	±	
5	33	M	+	+	-	-	-	-	Yellow	Red	-	-	-	±	
6	24	F	+	+	-	-	-	-	Yellow	Red	-	-	-	±	Deposits limited to superficial stroma Bowman's membrane destroyed
7	17	F	+	+	-	-	-	-	Yellow	Red	-	-	-	-	Deposits principally subepithelial
8	66	F	+	+	-	-	-	-	Yellow	Red	+	+	±	+	
9	51	M	+	+	-	-	-	-	Yellow	Red	+	+	±	+	
10	41	M	+	+	-	-	-	-	Yellow	Red	-	-	-	-	Deposits entirely superficial
11	23	M	+	+	-	-	-	-	Yellow	Red	-	-	-	-	Deposits confined to epithelial layer Bowman's membrane intact
12	69	F	+	+	-	-	-	-	Yellow	Red	+	+	±	+	Granular deposits all superficial

Notes: 1. Refers to the presence of positive staining foci within granular lesions which were otherwise non-reactive

2. Refers to appearance of Congo red stained sections in polarized light

3. Cases 8, 9, and 12 showed foci of strong fluorescence which contrasted with the weak background fluorescence of the granular areas.

Table II Protein and amino-acid staining reactions of the granular deposits

Case no.	Coupled Tetrazonium for protein	Ninhydrin-Schiff for amino groups	Hydroxy-naphth-aldehyde for amino groups	Mixed anhydride for carboxyl groups	DDD for sulphydryl groups	Thioglycollate- DDD for sulphydryl and disulphide groups	Performic acid-Alcian blue for disulphide groups	DC for tyrosine	DMAB-nitrite for tryptophan	Sakaguchi for arginine
1	++	±	+	++	+	++	-	++	+	++
2	++	-	+	++	±	+	-	++	±	++
3	++	±	+	+	+	++	-	++	±	+
4	++	-	±	++	+	++	-	++	±	
5	++	-	±	++	+	++	-	++	+	+
6	++	-	+	++	+	++	-	++	±	
7	++	±	±	++	+	++	-	++	±	
8	++	+	+	++	+	++	-	++	+	++
9	++	±	+	++	+	++	-	++	+	
10	++	-	±	+	+	++	-	++	+	
11	++	-	±	++	+	++	-	++	±	++
12	++	±	±	++	+	++	-	++	±	

This attractive concept, which has much to commend it, is not, however, supported either by the findings in the present study or by the virtually identical findings of Seitz and Goslar (1965). For, while the lesions undeniably included reticulin fibres as evidenced by silver staining, there would seem good reason to postulate the additional presence of a non-collagenous protein or polypeptide complex. Thus tyrosine, which was prominent in the granular deposits, is present in only trace amounts in collagen; sulphur containing amino-acids, apart from a little methionine, do not occur in collagen although they were clearly demonstrable in the lesions of granular dystrophy; and tryptophan, which was present in amounts varying from a trace to moderate, is completely absent from collagen.

In view of the constant finding of protein deposits in the immediate subepithelial region and the observation that in one case deposition was entirely limited to this location, it is interesting that Bücklers (1938) should have likened the lesions to keratin or keratohyaline. Keratin is, however, very rich in sulphur-containing amino-acids, particularly cystine, and though such components were demonstrable in the lesions of granular dystrophy, the amounts were by comparison rather small. Nevertheless, arginine, which was readily demonstrated in all twelve cases, is also prominent in keratin and, while there was no real histological evidence that the abnormal protein was emanating from diseased epithelial cells, it does suggest that the epithelium in this condition should receive rather more attention than it has done hitherto.

Another possibility is suggested by the observation that components satisfying all the histological criteria for amyloid were present within the dystrophic foci in three of the twelve cases. Moreover, lesions indistinguishable from those of lattice dystrophy, a condition recently shown to be a familial form of localized amyloidosis (Seitelberger and Nemetz, 1961; Klintworth, 1967), were seen to coexist in one of these cases with the deposits of non-birefringent material typical of granular dystrophy. This raises the question whether the granular lesions are in some way related to amyloid. Certainly the protein histochemistry does not contradict this suggestion, all of the protein groups and amino-acids present in granular dystrophy having also been demonstrated in amyloid (McAlpine and Fuller, 1964), while a recent study has shown that all these components are similarly present in the amyloidotic nodules of lattice dystrophy (Garner, unpublished observations). Although the presence of amyloid in granular dystrophy has not been commented on previously, Smith and Zimmerman (1968) reported weak to moderate metachromasia with crystal violet in each of seven cases examined and equivocal Thio-

flavine T fluorescence in one, and Matsuo and others (1967) quoted dubious evidence for its presence in the study of a single case. Recently a plasma-derived component or precursor of amyloid has been described (Bladen, Nylen, and Glenner, 1966; Cathcart, Shirahama, and Cohen, 1967) which can be resolved only at electron microscope magnifications of over 200,000, and it would be of great interest to study the deposits of granular dystrophy at comparable magnifications.

It is tempting to speculate on the relationship, if any, between granular and lattice dystrophies. Both are attributable to dominant autosomal genetic defects and, despite several clinical and histopathological differences, the apparent overlap that exists between these two disorders may support those who, as Duke-Elder and Leigh (1965) point out, have felt that the individual stromal dystrophies are not independent pathological entities but variable expressions of the same morbid gene.

Finally, there is the further possibility that the granular deposits are accumulated by diffusion from extracorneal sources, especially as electrophoretic studies have demonstrated proteins in the human cornea which travel with the same mobility as serum albumin and each of the serum globulin fractions (Watanabe and Tsutsui, 1961). While the histochemical findings are compatible with this suggestion, it is to be noted that no defect is usually discernible in either the corneal endothelium or Descemet's membrane, although the possibility that protein derived from plasma might diffuse into the cornea from the limbal region cannot be entirely discounted.

Conclusions and Summary

The problem of the nature of the granular deposits in Groenouw's type 1 corneal dystrophy remains unsolved, largely because of the limited range of amino-acids and protein groups that can be identified by histochemical techniques, and partly because of the difficulties encountered in interpreting the results of electron microscopy. Nevertheless the deposits have been shown to consist principally of a non-collagenous protein containing tyrosine, tryptophan, arginine, and sulphur-containing amino-acids.

The possible origin of the abnormal protein is thought to include the epithelium and extracorneal sources as well as the keratocyte, although the evidence for each of these suggestions is entirely circumstantial. The implication of the demonstration of amyloid foci in a minority of the cases examined is discussed with regard to the possibility that the lesions of granular dystrophy are in some way related.

My thanks are due to Prof. Norman Ashton for his constructive criticism and encouragement, to Mrs. M. Kulczyk and Mr. A. McNeil for expert technical assistance, and to Miss A. Martyn for secretarial help.

References

- BLADEN, H. A., NYLEN, M. U., and GLENNER, G. G. (1966) *J. Ultrastruct. Res.*, **14**, 449
 BÜCKLERS, M. (1938) *Ber. dtsh. ophthal. Ges.*, **52**, 441
 CATHCART, E. S., SHIRAHAMA, T., and COHEN, A. S. (1967) *Biochim. biophys. Acta*, **147**, 392
 DUKE-ELDER, S., and LEIGH, A. G. (1965) "System of Ophthalmology", vol. 8, pt 2, p. 927. Kimpton, London
 FRANCESCHETTI, A., and BABEL, J. (1951) "XVI Concilium Ophthalmologicum, 1950, Britannia Acta", vol. 1, p. 245. B.M.A., London
 GARNER, A. (1969a) *Brit. J. Ophthal.*, **53**, 73
 ——— (1969b) *Invest. Ophthal.*, **8**, 475
 GOSLAR, H. G., and SEITZ, R. (1961) *Acta histochem.*, **12**, 289

- JONES, S. T., and ZIMMERMAN, L. E. (1959) *Amer. J. Ophthalm.*, **47**, 1
——— (1961) *Ibid.*, **51**, 394
- KLINTWORTH, G. K. (1967) *Amer. J. Path.*, **50**, 371
——— and VOGEL, F. S. (1964) *Ibid.*, **45**, 565
- KUWAHARA, Y., AKIYA, S., and OBAZAWA, H. (1967) *Folia ophthalm. Jap.*, **18**, 434
- MCALPINE, J. C., and FULLER, A. P. (1964) *J. Path. Bact.*, **88**, 455
- MCTIGUE, J. W. (1965) In "The Cornea World Congress, Washington, D.C., 1964", ed. J. H. King, Jr., and J. W. McTigue, p. 49. Butterworth, Washington
——— (1967) *Trans. Amer. ophthalm. Soc.*, **65**, 591
- MATSUO, N., FUJIWARA, H., and OFUCHI, Y. (1967) *Folia ophthalm. Jap.*, **18**, 436
- MORGAN, G. (1966) *Brit. J. Ophthalm.*, **50**, 57
- PEARSE, A. G. E. (1968) "Histochemistry, Theoretical and Applied", 3rd ed., vol. 1, pp. 606-629. Churchill, London
- SEITELBERGER, F., and NEMETZ, U. R. (1961) *v. Graefes Arch. Ophthalm.*, **164**, 102
- SEITZ, R., and GOSLAR, H. G. (1963) *Klin. Mbl. Augenheilk.*, **142**, 943
——— (1965) *Ibid.*, **147**, 673
- SMITH, M. E., and ZIMMERMAN, L. E. (1968) *Arch. Ophthalm. (Chicago)*, **79**, 407
- SORNSON, E. T. (1965) *Amer. J. Ophthalm.*, **59**, 1001
- TENG, C. C. (1967) *Ibid.*, **63**, 772
- WAGNER, B. M. (1967) In "The Connective Tissue", ed. B. M. Wagner and D. E. Smith, p. 68. Williams and Wilkins, Baltimore
- WATANABE, S., and TSUTSUI, J. (1961) *Amer. J. Ophthalm.*, **51**, 314