

Therapeutic Effect of the Anti-Fas Antibody on Arthritis in HTLV-I *tax* Transgenic Mice

Koushi Fujisawa,* Hiroshi Asahara,* Kazuyoshi Okamoto,* Hiroyuki Aono,* Tomoko Hasunuma,* Tetsuji Kobata,* Yoichiro Iwakura,† Shin Yonehara,§ Takayuki Sumida,* and Kusuki Nishioka*

*Division of Rheumatology and Immunology, Institute of Medical Science, St. Marianna University School of Medicine, 2-16-1 Sugao, Miyamae-ku, Kawasaki, Japan 216; †Institute of Medical Science, University of Tokyo, Tokyo, Japan; and §Institute for Virus Research, Kyoto University, Kyoto, Japan

Abstract

We have recently demonstrated Fas-mediated apoptosis in the synovium of patients with rheumatoid arthritis (RA) and suggested that it may be one factor responsible for the regression of RA. To examine whether the induction of apoptosis caused by anti-Fas mAb may play a potential role as a new therapeutic strategy for RA, we investigated the effect of anti-Fas mAb (RK-8) on synovitis in an animal model of RA, the human T cell leukemia virus type I (HTLV-I) *tax* transgenic mice. We report here that administration of anti-Fas mAb into mice intra-articularly improved the paw swelling and arthritis within 48 h. Immunohistochemical study and in vitro culture studies showed that 35% of synovial fibroblasts, 75% of mononuclear cells, and some of polymorphonuclear leukocytes infiltrating in synovium underwent apoptosis by anti-Fas mAb. In situ nick end labeling analysis and electron microscope analysis clearly showed that many cells in synovium were induced apoptosis by anti-Fas mAb administration. However, local administration of anti-Fas mAb did not produce systemic side effects. Results demonstrated that administration of anti-Fas mAb in arthritic joints of the HTLV-I *tax* transgenic mice produced improvement of arthritis. These findings suggest that local administration of anti-Fas mAb may represent a useful therapeutic strategy for proliferative synovitis such as RA. (*J. Clin. Invest.* 1996. 98:271–278.) Key words: apoptosis • Fas • anti-Fas mAb • HTLV-I *tax* • rheumatoid arthritis

Introduction

The early phase of rheumatoid arthritis (RA) is characterized by proliferation of the synovium and infiltration of various inflammatory cells (1). However, at the developed stage, the

process involving synovial cell hyperplasia, bone and joint destruction regresses and is gradually replaced with fibrotic tissue formation. We have reported recently that apoptotic synovial cells and infiltrating lymphocytes are found in RA (2–4). Thus, it is possible that the regression of RA may be due to the induction of apoptosis in the rheumatoid synovium.

Fas/Apo-1 (CD95) molecule is a cell surface receptor belonging to the tumor necrosis factor receptor (TNF-R)/nerve growth factor receptor (NGF-R) family (5). This molecule is expressed on various normal and neoplastic cells (6–8), including the rheumatoid synovial cells (2, 4). Furthermore, stimulation of the Fas antigen by Fas ligand or anti-Fas monoclonal antibodies (mAbs) induces apoptosis of cells from various lineages (2, 4, 8–10). We also demonstrated that both synovial fibroblasts and mononuclear cells in the rheumatoid synovium express the functional Fas antigen and that these cells are able to undergo apoptosis by anti-Fas mAb (2, 4). The latter phenomenon is thought to be specific to the rheumatoid synovium since neither peripheral blood lymphocytes (PBL) of RA patients nor synovial fibroblasts of patients with osteoarthritis showed any apoptosis after treatment with anti-Fas mAb. This observation shows that apoptosis through Fas molecule have a preference for RA synovium.

In the present study, we investigated whether induction of apoptosis by anti-Fas mAb in the rheumatoid synovium is involved in the regression of RA. This approach also represents a potentially useful therapy for RA. We administered anti-Fas mAb (RK-8) to human T cell leukemia virus type I (HTLV-I)¹ *tax* transgenic mice. HTLV-I *tax* transgenic mice is considered to be one of the most suitable models for human RA, since these animals develop chronic synovitis and an immunological disorder resembling human RA (11–13). Our results demonstrated that intra-articular administration of anti-Fas mAb in these mice improved the paw swelling and histologic features of arthritis. This improvement was due to the induction of apoptosis in both synovial fibroblasts and mononuclear cells in the inflamed synovium. Furthermore, treatment did not produce systemic side effects. We believe that the local administration of anti-Fas mAb may represent a new therapeutic modality for RA in humans.

Address correspondence to Prof. Kusuki Nishioka, M.D., Division of Rheumatology and Immunology, Institute of Medical Science, St. Marianna University School of Medicine, 2-16-1 Sugao, Miyamae-ku, Kawasaki, Japan 216. Phone: 44-977-8111 ext. 4106; FAX: 81-44-977-9165.

Received for publication 18 December 1995 and accepted in revised form 15 May 1996.

J. Clin. Invest.

© The American Society for Clinical Investigation, Inc.

0021-9738/96/07/0271/08 \$2.00

Volume 98, Number 2, July 1996, 271–278

1. Abbreviations used in this paper: HTLV-I, human T cell leukemia virus type I; TUNEL, terminal deoxynucleotidyl transferase-mediated dUTP nick end labeling.

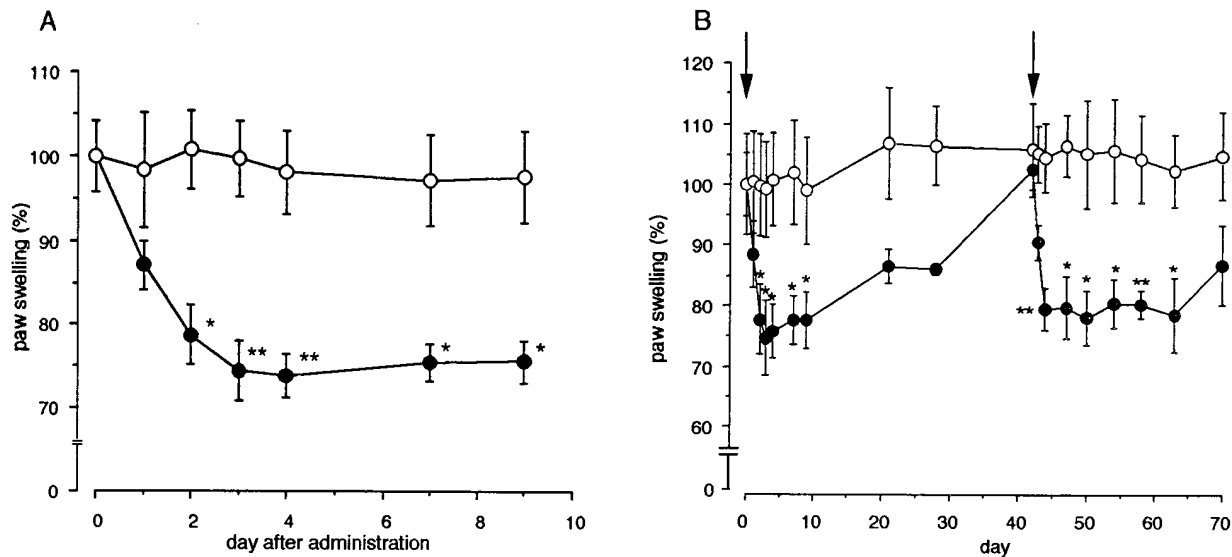


Figure 1. (A) Selective decrease of paw swelling by anti-Fas mAb. Five and four HTLV-I *tax* transgenic mice were intra-articularly injected with 5 μ g of RK-8 (●) and control hamster IgG (○) at day 0, respectively. Results are expressed as the percentage reduction in paw thickness. * $P < 0.05$, ** $P < 0.01$, compared with control mice. (B) Effect of the second injection of anti-Fas mAb. Three HTLV-I *tax* transgenic mice for each group were intra-articularly injected with 5 μ g of RK-8 (●) and control hamster IgG (○) at day 42 after the first injection, respectively. The arrows indicate the day when anti-Fas mAb was administered. * $P < 0.05$, ** $P < 0.01$, compared with control mice.

Methods

Mice and mAb. Transgenic mice (8–12 wk old) carrying HTLV-I *tax* and demonstrating signs of chronic arthritis, which were backcrossed to BALB/c mice, were used in this study. Anti-Fas mAb (RK-8; IgG, MBL Co., Nagoya, Japan), or control hamster IgG Ab (PharMingen, San Diego, CA) was injected intra-articularly into the ankle joint at a dose of 5 μ g using a micro syringe. In the first experiment, five and four mice were used for injection of anti-Fas mAb and control IgG, respectively. In the second experiment, three mice for each group were used. In some experiments, the same amount of anti-Fas mAb was injected intra-articularly into four BALB/c mice.

Measurement of paw swelling. The thickness of hind paw was monitored using calipers. The values were represented as the percentage diminution in paw thickness compared to before the onset.

DNA nick end labeling and immunohistochemistry. The synovial tissue dissected from the ankle joint of mice was snap-frozen in TIS-SUE-TEC O.C.T. compound (Miles Inc., Elkhart, IN). Then, the tissue specimens were cut into 5–7- μ m sections, mounted onto glass slides, and used for further experiments. Fragmented DNA was detected by terminal deoxynucleotidyl transferase (TdT)-mediated dUTP nick end labeling (TUNEL) method described previously (14). Briefly, the sections were immersed in TdT buffer (30 mM Tris-HCl, pH 7.2, 140 mM sodium cacodylate, 1 mM cobalt chloride), and TdT (GIBCO BRL, Grand Island, NY) and biotinylated dUTP (Boehringer Mannheim, Indianapolis, IN) were added to the samples. The reaction was terminated by immersing in TB buffer (300 mM sodium chloride, 30 mM sodium citrate). Then, samples were treated with peroxidase-labeled streptavidin and visualized by VECTASTAIN ABC kit (Vector Laboratories Inc., Burlingame, CA). For immunohistochemistry, the sections were blocked with 4% skim milk for 30 min at room temperature and incubated with biotinylated mAbs specific for CD3, B220 (PharMingen) or Fas (RK-8), respectively. Visualization was performed as described above.

Histopathology. The hind paw including ankle joint and other organs were fixed in 10% formalin neutral buffer solution. The joint tissue was decalcified in EDTA/formalin solution. The tissue was then embedded in paraffin, sectioned and stained with hematoxylin and eosin (H-E). For transmission electronmicroscopic analysis, the

synovial tissue dissected from the ankle joint of HTLV-I *tax* transgenic mice was fixed with 2.5% glutaraldehyde and then examined by electronmicroscopy.

Cell culture and induction of apoptosis in vitro by anti-Fas mAb. Synovial cells were obtained from HTLV-I *tax* transgenic mice as follows. Briefly, the synovium was minced into small pieces and cell debris was removed using a nylon mesh. A single-cell suspension was incubated overnight in Dulbecco's MEM (DMEM) (GIBCO BRL) supplemented with 10% fetal calf serum (FCS). Floating cells were collected as nonadherent infiltrating cells. Adherent cells were cultured in dishes until examination. Cultured synovial cells, both adherent and nonadherent cells, were treated with anti-Fas mAb. Cells (1×10^6 cells) were cultured in DMEM supplemented with 10% FCS, and then were incubated with anti-Fas mAb at various concentrations for 0–48 h. The cells were then stained with trypan blue and the viable cells were quantified under microscopy.

Biochemical analysis. Blood samples were collected from mice on day 0, 3, 4, 5 after intra-articular administration of anti-Fas mAb. The serum levels of glutamic oxaloacetic transaminase (GOT), glutamic pyruvic transaminase (GPT) and alkaline phosphatase (ALP) were measured using a standard clinical automatic analyzer.

Results

Selective decrease of paw swelling by anti-Fas mAb. Five HTLV-I *tax* transgenic mice showing marked arthritis were treated with anti-Fas mAb (RK-8) intra-articularly. Another group of four mice were administered hamster IgG as a control. As shown in Fig. 1 A, the paw swelling in HTLV-I *tax* transgenic mice diminished gradually after treatment with anti-Fas mAb, and the swelling decreased to $\sim 30\%$ on day 4, to reach a plateau. Improvement of paw swelling after treatment with anti-Fas mAb was statistically significant compared with the control mice from day 2 to day 9 ($P < 0.05$ and $P < 0.01$, respectively). In the next experiment, to clarify the duration of the effect of anti-Fas mAb, we monitored the change of paw swelling for long term. As shown in Fig. 1 B, anti-Fas mAb reduced the

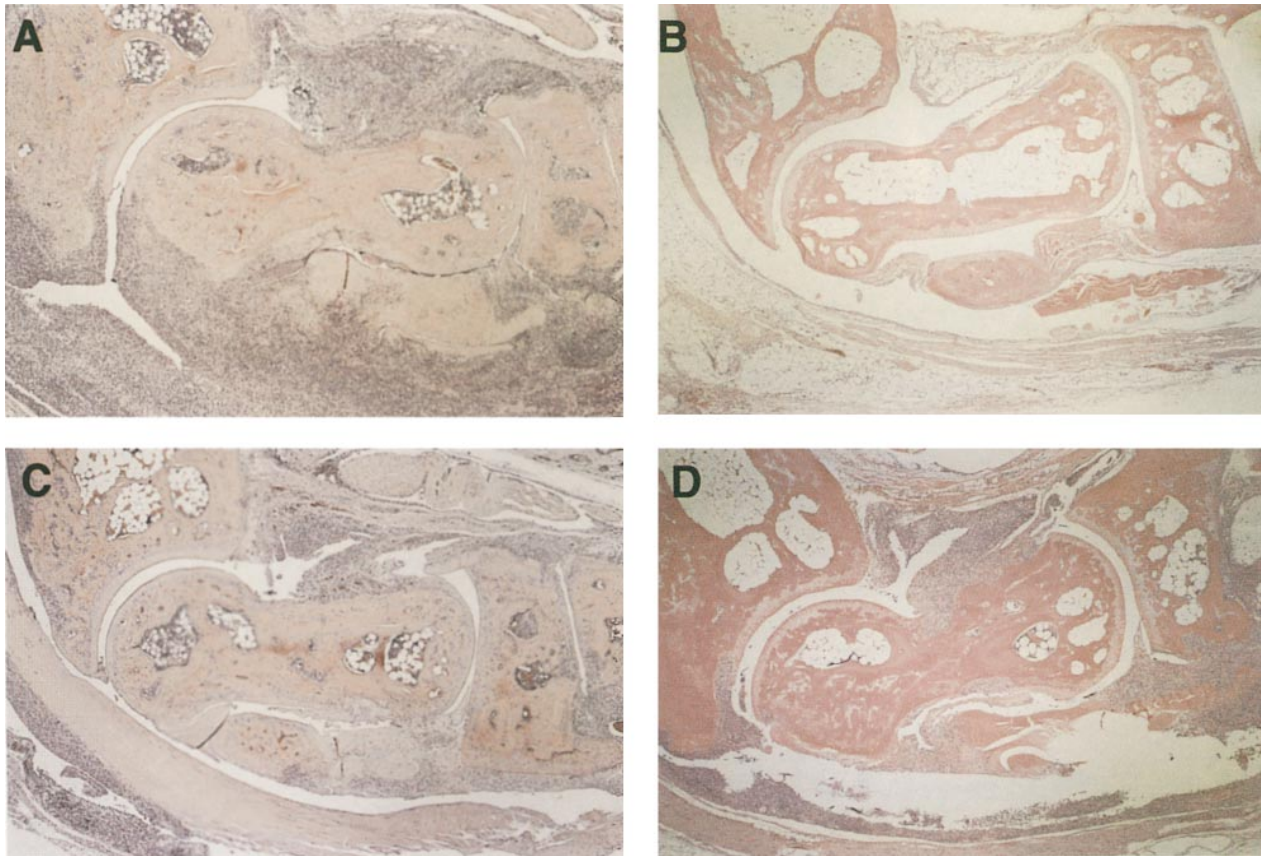


Figure 2. Histological examination of the synovium demonstrating a remarkable improvement of arthritis. (A) Severe arthritis in HTLV-I *tax* transgenic mice with control IgG Ab for 3 d. Note the formation of pannus-like granulation tissue, proliferation of synovial fibroblasts, and infiltration of mononuclear cells ($\times 25$). (B) Effect of intra-articular administration of anti-Fas mAb on normal BALB/c mice. No remarkable histological changes were observed ($\times 25$). (C and D) Drastic improvement of arthritis in mice treated with anti-Fas mAb for 3 d. In all four mice examined, the remarkable improvement of arthritis was observed. Note the disappearance of most fibroblasts, reduction in the number of mononuclear cells, and replacement of pannus-like tissue by fibrosis. C and D showed synovial tissues from anti-Fas mAb treated mice in experiment 1 and experiment 2, respectively ($\times 25$).

paw swelling during day 2 to day 9 and the effect continued to 2 wk. However, joints swelled gradually and at day 42 they reached to the same range of swelling at day 0. These results suggested that the duration of effect on paw swelling by one injection of anti-Fas mAb intra-articularly is about 2 wk. To examine the effect of the second injection of anti-Fas mAb, we injected the same amount of anti-Fas mAb intra-articularly in the re-swollen ankle joints. The second injection of anti-Fas mAb resulted in 30% of reducing of paw swelling as well as the first injection. This effect was also statistically significant compared with control mice from day 44 to day 63 ($P < 0.05$ and $P < 0.01$, respectively).

Remarkable improvement of arthritis. To examine the effect of anti-Fas mAb on the histological features of arthritis, we examined the ankle joints of HTLV-I *tax* transgenic mice treated with anti-Fas mAb or control Ab. The joint of mice with control Ab showed marked arthritis including erosion of bone and cartilage, and formation of pannus-like granulation tissue with proliferation of fibroblasts and infiltrating mononuclear cells (Fig. 2 A). In contrast, joints treated with anti-Fas mAb showed the remarkable improvement of arthritis at day 3 after administration. In all four mice examined, administration of anti-Fas mAb resulted in the disappearance of most fibroblasts, a reduction in the number of mononuclear cells, and re-

placement of pannus-like tissue with fibrotic tissue (Fig. 2, C and D). These findings strongly suggest that anti-Fas mAb delete mainly mononuclear cells and synovial fibroblasts, resulting in the improvement of arthritis. On the other hand, intra-articular administration of anti-Fas mAb did not show any remarkable histological changes on ankle joint of normal BALB/c mice (Fig. 2 B).

Both synovial fibroblasts and mononuclear cells were eliminated by intra-articular administration of anti-Fas mAb in vivo. Histological analysis (H-E staining) on synovium in HTLV-I *tax* transgenic mice showed that arthritis was composed of three different cells such as proliferative synovial fibroblasts, infiltrating mononuclear cells, and polymorphonuclear leukocytes. Immunohistochemical study demonstrated that the majority of mononuclear cells in synovium was mainly CD3 positive T cells and a few numbers of B220 positive B cells (Fig. 3, A and B). Most of mononuclear cells, synovial fibroblasts, and polymorphonuclear leukocytes strongly expressed Fas antigen (Fig. 3 C). After treatment with anti-Fas mAb for 3 days, neither CD3 positive cells nor B220 positive cells were observed and only a few numbers of fibroblasts and polymorphonuclear leukocytes were observed (Fig. 3, D and E). Fas positive cells were eliminated by anti-Fas mAb (Fig. 3 F).

Anti-Fas mAb induces apoptosis in vivo. To examine anti-

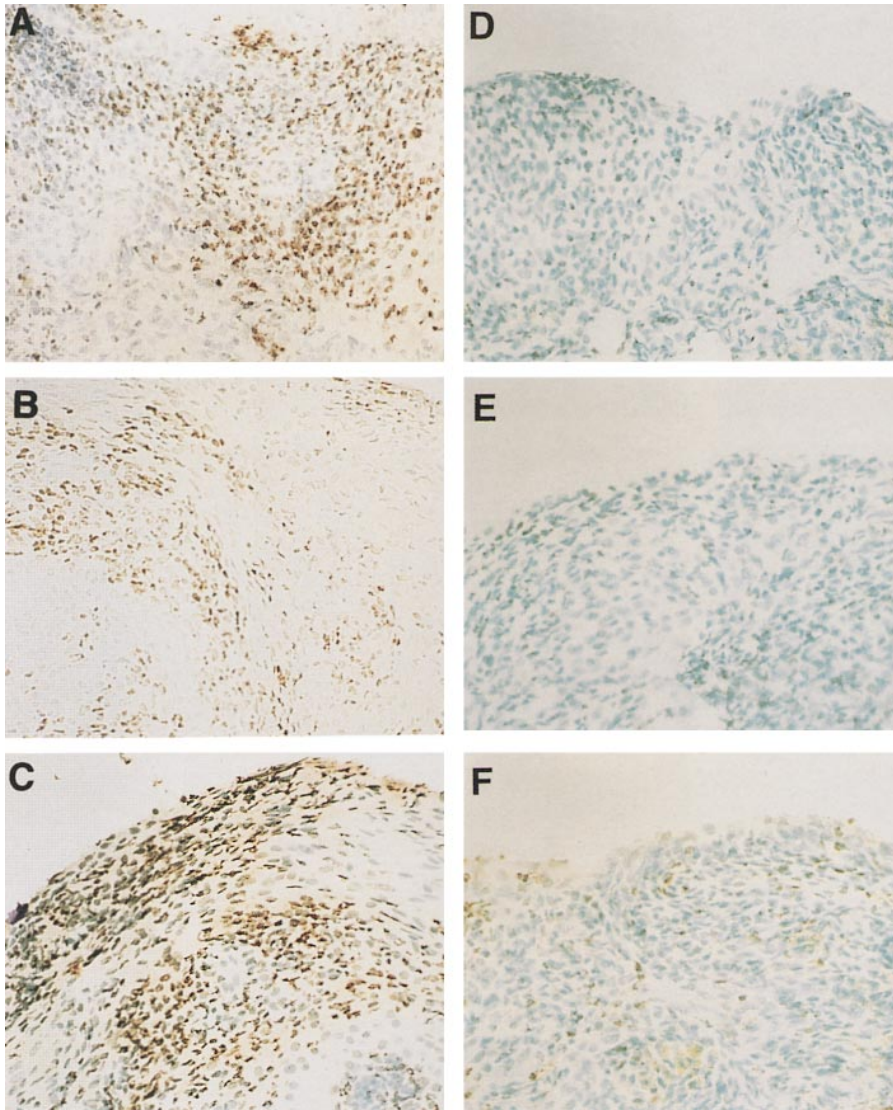


Figure 3. Immunohistochemical analysis of synovial cells in HTLV-I *tax* transgenic mice. Synovial tissues derived from HTLV-I *tax* transgenic mice treated with control IgG (A–C) and with anti-Fas mAb for 3 d (D–F). Each panel showed immunohistochemical studies, using mAbs against CD3 (A and D), B220 (B and E), and Fas (C and F), respectively (original magnification $\times 200$). The number of CD3⁺, B220⁺, and Fas⁺ cells were clearly reduced in synovium from anti-Fas mAb treated mice in comparison to control mice.

Fas mAb-induced apoptosis in the joint of HTLV-I *tax* transgenic mice, we examined the DNA fragmentation by TUNEL method. As shown in Fig. 4 *Ab*, many TUNEL positive cells were observed in synovium treated with anti-Fas mAb for 48 h. On the contrary, only a few numbers of TUNEL positive cells were observed in the joint synovium treated with control IgG (Fig. 4 *Aa*). To confirm the apoptosis of the cells, electron microscopic analysis on the joint lesions was carried out. Typical apoptotic cells with chromatin condensation and nuclear fragmentation were detected in specimens from joints treated with anti-Fas mAb (Fig. 4 *B*). In contrast, no changes were observed in joints treated with control hamster IgG (data not shown). The apoptotic cells were detected only within the initial 24–48 h after the administration of anti-Fas mAb, and no such cells were detected after 9 d of treatment.

Apoptosis of synoviocytes and mononuclear cells in vitro. To elucidate the cell type in anti-Fas mAb-induced apoptosis, we separated synovial cells into adherent and nonadherent cells and examined the effect of anti-Fas mAb. Adherent cells consisted mainly of fibroblasts, while nonadherent cells were

mainly composed of infiltrating lymphocytes. Adherent cells decreased in number following administration of anti-Fas mAb in a dose- and time-dependent manner, and > 35% of cells died within 48 h of incubation with 1.0 $\mu\text{g/ml}$ of anti-Fas mAb (Fig. 5 *A*). In contrast, 20% of nonadherent cells died within 24 h and 75% of cells were eliminated by anti-Fas mAb (Fig. 5 *B*). These results clearly showed that both adherent cells and nonadherent cells could undergo apoptosis through the Fas-mediated signal.

Effect of intra-articular administration of anti-Fas mAb on liver function. To examine the side-effects of intra-articular administration of anti-Fas mAb, we compared liver function before and after administration of anti-Fas mAb. The biochemical study of serum hepatic enzymes clearly demonstrated a lack of effect of anti-Fas mAb on liver function within the observation period extending from the day of injection to day 5 after injection (Fig. 6 *A*). Furthermore, histochemical analysis failed to demonstrate changes specific to treatment (Fig. 6 *B*). Moreover, treatment did not produce changes in the bone marrow, brain and cardiac muscle (data not shown).

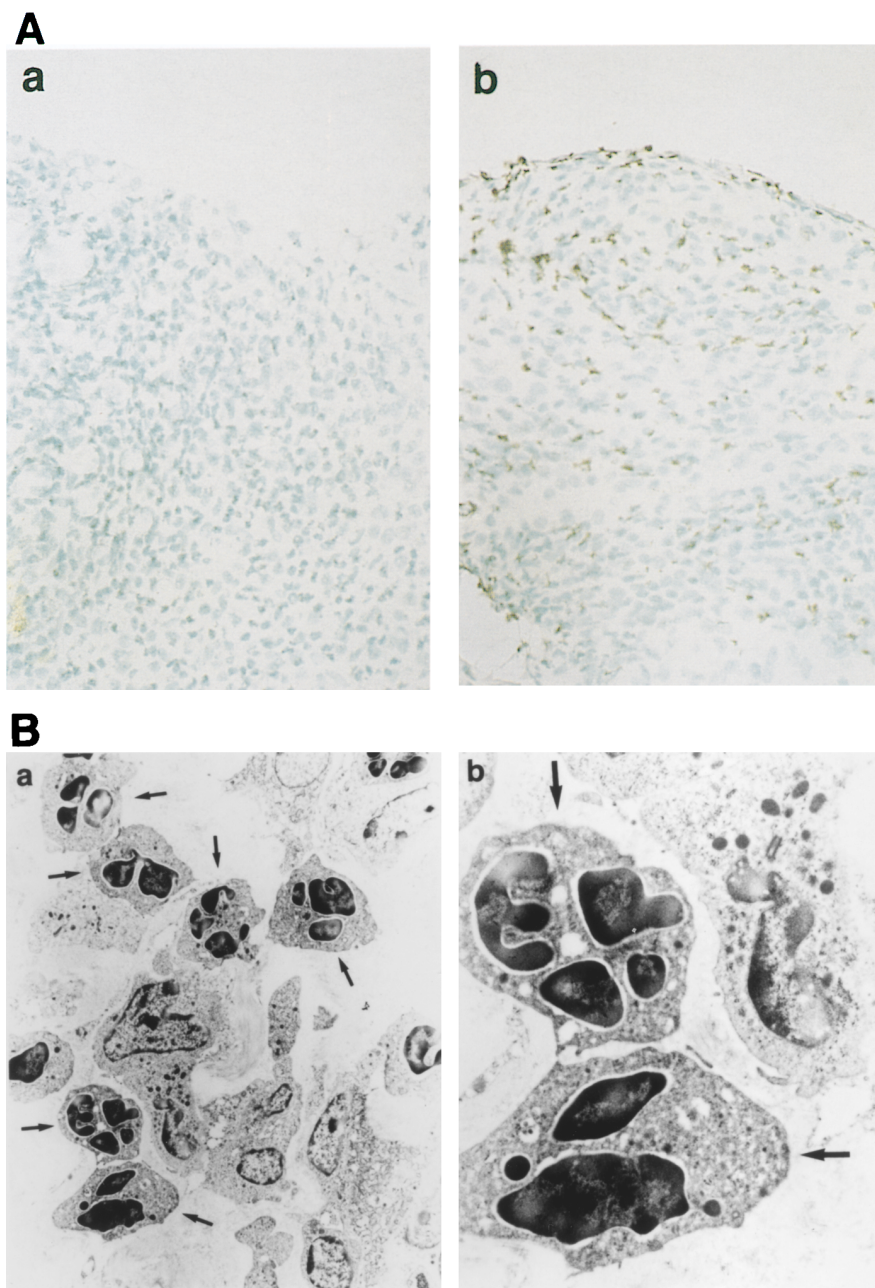


Figure 4. Anti-Fas mAb induces apoptosis in vivo. (A) TUNEL analysis of synovial tissues from HTLV-I *tax* transgenic mice. (a) Synovial tissues from HTLV-I *tax* transgenic mice treated with control IgG. (b) Synovial tissues from HTLV-I *tax* transgenic mice treated with anti-Fas mAb for 2 d (original magnification $\times 200$). A number of TUNEL positive cells were observed in the specimen from mice treated with anti-Fas mAb compared with control IgG. (B) Electron microscopic analysis of synovial tissue from HTLV-I *tax* transgenic mice treated with anti-Fas mAb (a, original magnification $\times 1000$; b, $\times 5000$). Arrows indicate typical apoptotic cells in the joint synovium.

Discussion

The features of RA synovium is expressed as paradoxical cell growth phase; one is proliferation of synovial cells and the other is withdrawal or regression of hyperplastic synovium (1). Recent studies from our laboratory demonstrated that the synoviocytes and mononuclear cells undergo apoptosis in the rheumatoid synovium (2). Our study also demonstrated over-expression of Fas antigen on synoviocytes and synovial lymphocytes (2, 4). Moreover, Fas ligand (Fas-L) is expressed on CD4, CD8, and CD56 positive cells in the rheumatoid synovium and these cells are close to Fas positive synoviocytes (Asahara et al. manuscript submitted for publication). These observations indicate that both synoviocytes and lymphocytes undergo apoptosis via a Fas/Fas-L interaction. Thus, it is possible that the induction of apoptosis in rheumatoid synovial cells

may cause a regression of the pathological process of RA. Intriguingly, we have also demonstrated that functional Fas antigen is expressed preferentially on synoviocytes and lymphocytes in the synovium (2, 4). When these observations were considered together, we predicted that administration of anti-Fas mAb in RA patients may produce a beneficial effect on arthritis through the induction of apoptosis, which may in turn cause regression of the pathological process.

In our first step of examining our hypothesis, we investigated the effect of intra-articular injection of anti-Fas mAb (RK-8; IgG) on arthritis in the HTLV-I *tax* transgenic mice, a well-recognized animal model of human RA. We obtained reproducible evidence that local administration of RK-8 produces a remarkable improvement of arthritis in these animals. The present study also demonstrated that the improvement of arthritis was due to a direct effect of RK-8 on both synovial fi-

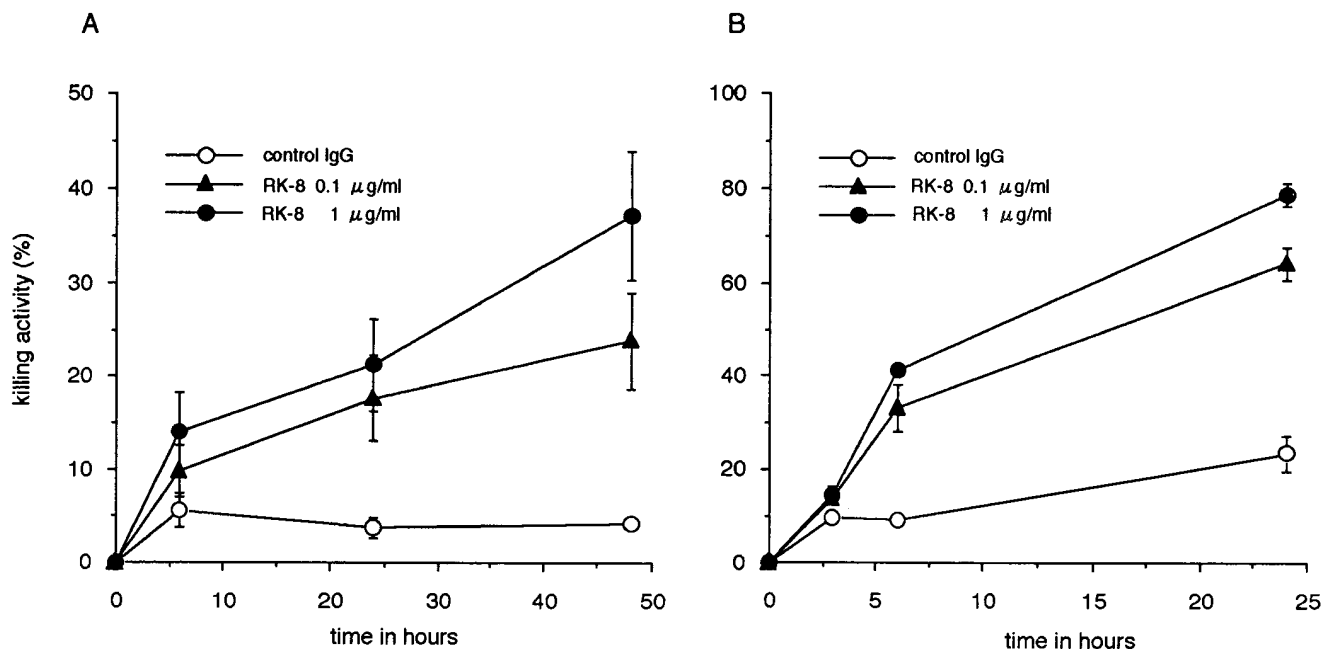


Figure 5. Induction of apoptosis in synovial cells by anti-Fas mAb in vitro. (A) Effect of anti-Fas mAb (RK-8) on synoviocytes. Synoviocytes from HTLV-I *tax* transgenic mice were cultured with RK-8 (\blacktriangle ; 0.1 μ g/ml RK-8, \bullet ; 1.0 μ g/ml RK-8) or control IgG (\circ ; 1.0 μ g/ml control IgG) as described in Methods. (B) Effect of RK-8 on infiltrating mononuclear cells. Mononuclear cells infiltrating the synovium were treated with RK-8 (\blacktriangle ; 0.1 μ g/ml RK-8, \bullet ; 1.0 μ g/ml RK-8) or control IgG (\circ ; 1.0 μ g/ml control IgG). Data represent the mean \pm SEM of four separate experiments.

broblasts and mononuclear cells such as CD3 positive T cells and B220 positive B cells by induction of apoptosis in these cells. Histological examinations demonstrated that the drastic improvement of arthritis was observed in the joint treated with anti-Fas mAb for 3 d. However, at day 9 after injection of anti-Fas mAb, some synovial fibroblasts and mononuclear cells generated in synovium (data not shown). These results suggested that histological improvement of arthritis by anti-Fas mAb continued until day 9 at least. Afterwards, synovial fibroblasts and mononuclear cells gradually regenerated and paw swelling was completely relapsed at day 42. Moreover, we confirmed that the second injection of RK-8 was effective on the relapse of arthritis. In contrast, local injection of RK-8 in BALB/c mice showed no obvious injury, but the further studies including TUNEL staining should be performed to clarify whether there are no effect of anti-Fas mAb against normal synovium.

The use of the HTLV-I *tax* transgenic mice in our studies was based on the characteristics of arthritis in this animal. HTLV-I is an etiologic agent of adult T cell leukemia (ATL) (15) and is also associated with several inflammatory diseases such as chronic myelopathy (HAM/TSP) (16, 17), chronic arthritis (HTLV-I associated arthropathy; HAAP) (18, 19), uveitis (20), and Sjögren's syndrome (21, 22). A viral gene HTLV-I pX encodes for p40^{tax}. This protein transactivates not only the viral long terminal repeat but also a variety of cellular genes, including interleukin-2 (IL-2), IL-2 receptor (IL-2 R), or other lymphokines (23–25). Thus, the transgenic mice carrying the HTLV-I *tax* genomes show chronic arthritis including erosive destruction of the bone, pannus formation, and lymphocytes infiltration resembling RA (11,12). Moreover, recent studies by Iwakura et al. (13) demonstrated that the transgenic mice carrying HTLV-I *env-tax* region not only produce high levels

of antibodies against IgG, collagen type II (IIC), heat shock protein (Hsp), and DNA, but also provide T cell proliferation to IIC and Hsp. This suggests that HTLV-I *tax* gene induces the immunological disorders in these animals. Thus, the histological features of arthritis and immunological abnormalities in these mice are similar to those of RA, making these HTLV-I *tax* transgenic mice the most suitable animal model for human RA. In this study, we used BALB/c background HTLV-I *tax* transgenic mice in our experiments due to the high incidence of arthritis (60%) and reactivity of anti-Fas mAb (RK-8) in these species.

Yamada et al. (26) reported that HTLV-I *tax*-transformed Rat-1 cells underwent apoptosis by serum deprivation. Chlichia et al. (27) also demonstrated that apoptosis occurred in cells subjected to short term activation of the *tax* fusion proteins and the CD3 complex. These findings suggest that the HTLV-I *tax* may itself facilitate apoptosis. The present results support such possibility, based on the following two reasons. First, in vitro examination clearly showed increased susceptibility of synovial cells to anti-Fas mAb in *tax* transgenic mice. Second, the expression of HTLV-I gene in the synovium enhanced the susceptibility to Fas signal in vivo and induced apoptotic cell death similar to human RA, although different expressions of Fas antigen were not detected between HTLV-I *tax* transgenic and nontransgenic littermate mice (data not shown). HTLV-I *tax*-induced apoptosis may be due to a modification of the Fas signal pathway by *tax* expression and/or overexpression of Fas ligand.

Mice carrying the lymphoproliferation (*lpr*) (28) mutation or generalized lymphoproliferative disease (*gld*) (29) mutation develop lymphadenopathy and suffer from autoimmune diseases such as systemic lupus erythematosus (SLE). Recently, these two mutations have been confirmed to be the defect of

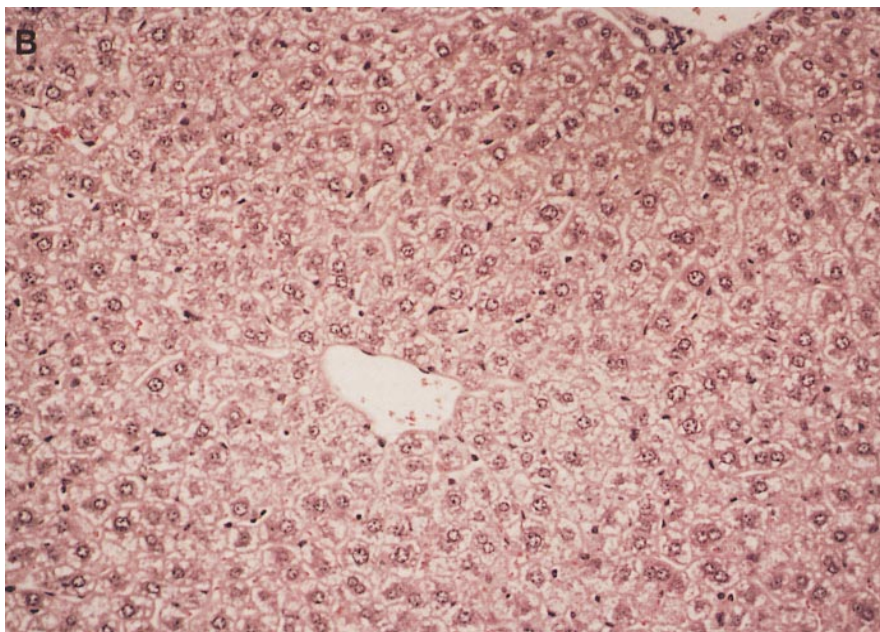
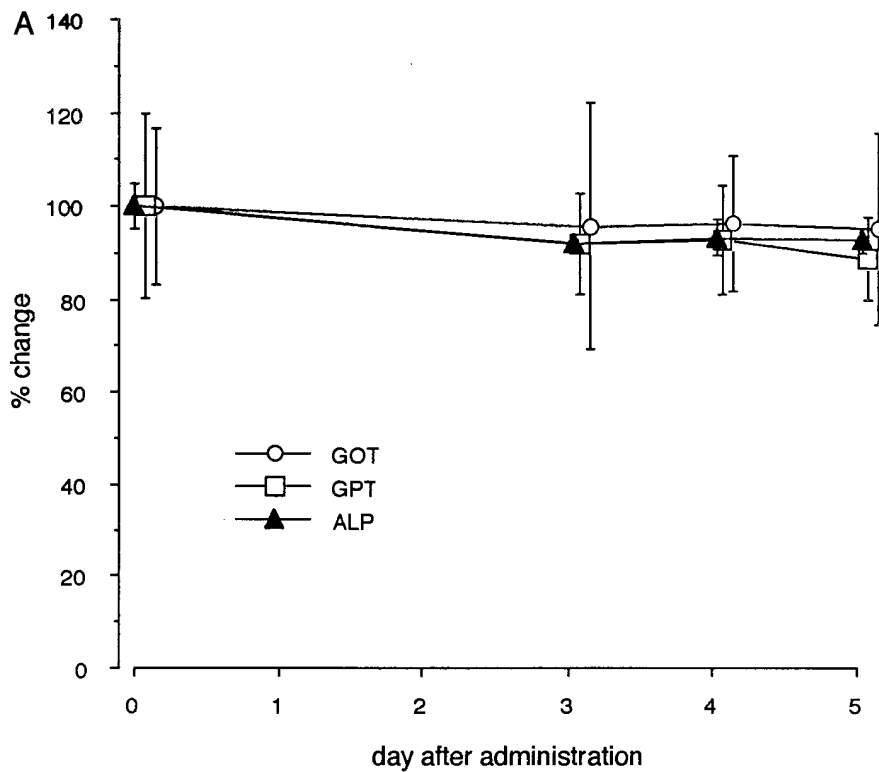


Figure 6. Effect of intra-articular administration of anti-Fas mAb on the liver. (A) Biochemical analysis of serum enzymes. Serum samples were collected from mice treated with anti-Fas mAb. Note lack of effect of treatment on GOT (○), GPT (□), and ALP (▲). (B) Histological examination of the liver. The liver of anti-Fas treated mice was prepared as described in the Methods. No remarkable changes were observed in the liver ($\times 50$).

Fas antigen (28) and Fas-L (29), respectively. MRL-*gld/gld* mice develop RA-like arthritis as well as SLE-like manifestations. Yonehara et al. treated MRL-*gld/gld* mice with administration of RK-8 intra-peritoneally and was successful in improving arthritis and lymphadenopathy in these mice (submitted). These results indicate that the therapeutic effects of RK-8 on arthritis is not a specific phenomenon in HTLV-I *tax* transgenic mice but rather the antibody has general effects in autoimmune arthritis.

Ogasawara et al. (30) reported that intra-peritoneal administration of anti-Fas mAb (Jo-2; IgG) was lethal to mice due to

severe liver damage. In contrast, our study demonstrated that intra-articular administration of RK-8 did not cause serious side-effects as evident by a lack of change of serum enzymes. The different reaction to the antibody in these two studies may be due to different epitopes on Fas antigen recognized by the mAbs (31) or the different mode of injection. It is likely that the difference is due to the latter since intra-peritoneal administration of RK-8 produced a lethal effect in HTLV-I *tax* transgenic mice (unpublished observation). However, it is necessary to do further experiments on the epitopes of Fas antigen recognized by these two distinct anti-Fas mAbs.

In conclusion, we demonstrated that local administration of anti-Fas mAb represents a new strategy and specific treatment for an animal model of RA. Exploitation of human type anti-Fas mAb and its application to human may help in the treatment of incurable autoimmune diseases such as RA.

Acknowledgments

We thank Drs. Keiichiro Nishida and Hajime Inoue for the electron microscopic analysis and Akihiko Okahara for histopathologic study. We also thank Miss Ritsuko Sato for her technical assistance.

This study was supported by grants from the Ministry of Education, Science, Sports and Culture of Japan, and the Ministry of Health and Welfare of Japan, and Santen Grant.

References

- Harris, E.D.J. 1990. Rheumatoid arthritis. Pathophysiology and implications for therapy. *N. Engl. J. Med.* 322:1277-1289.
- Nakajima, T., H. Aono, T. Hasunuma, K. Yamamoto, T. Shirai, K. Hirohata, and K. Nishioka. 1995. Apoptosis and functional Fas antigen in rheumatoid arthritis synoviocytes. *Arthritis Rheum.* 38:485-491.
- Firestein, G.S., M. Yeo, and N.J. Zvaifler. 1995. Apoptosis in rheumatoid arthritis synovium. *J. Clin. Invest.* 96:1631-1638.
- Hoa, T.T.M., T. Hasunuma, H. Aono, K. Masuko, T. Kobata, K. Yamamoto, T. Sumida, and K. Nishioka. Novel mechanisms of selective apoptosis in synovial T cells of patients with rheumatoid arthritis. *J. Rheumatol.* In press.
- Itoh, N., S. Yonehara, A. Ishii, M. Yonehara, S.I. Mizushima, M. Sameshima, A. Hase, Y. Seto, and S. Nagata. 1991. The polypeptide encoded by the cDNA for human cell surface antigen Fas can mediate apoptosis. *Cell.* 66:233-243.
- Watanabe-Fukunaga, R., C.I. Brannan, N. Itoh, S. Yonehara, N.G. Copeland, N.A. Jenkins, and S. Nagata. 1992. The cDNA structure, expression, and chromosomal assignment of the mouse Fas antigen. *J. Immunol.* 148:1274-1279.
- Oehm, A., I. Behrmann, W. Falk, M. Pawlita, G. Maier, C. Klas, M. Li-Weber, S. Richards, J. Dhein, B.C. Trauth, H. Ponsting, and P.H. Krammer. 1992. Purification and molecular cloning of the APO-1 cell surface antigen, a member of the tumor necrosis factor/nerve growth factor receptor superfamily. Sequence similarity with the Fas antigen. *J. Biol. Chem.* 267:10709-10715.
- Yonehara, S., A. Ishii, and M. Yonehara. 1989. A cell-killing monoclonal antibody (anti-Fas) to a cell surface antigen codownregulated with the receptor of tumor necrosis factor. *J. Exp. Med.* 169:1747-1756.
- Suda, T., T. Takahashi, P. Golstein, and S. Nagata. 1993. Molecular cloning and expression of the Fas ligand, a novel member of the tumor necrosis factor family. *Cell.* 75:1169-1178.
- Trauth, B.C., C. Klas, A.M.J. Peters, S. Matzku, P. Möller, W. Falk, K. Debatin, and P.H. Krammer. 1989. Monoclonal antibody-mediated tumor regression by induction of apoptosis. *Science (Wash. DC)*. 245:301-305.
- Iwakura, Y., M. Tosu, E. Yoshida, M. Takiguchi, K. Sato, I. Kitajima, K. Nishioka, K. Yamamoto, T. Takeda, M. Hatanaka, H. Yamamoto, and T. Sekiguchi. 1991. Induction of inflammatory arthropathy resembling rheumatoid arthritis in mice transgenic for HTLV-I. *Science (Wash. DC)*. 253:1026-1028.
- Yamamoto, H., T. Sekiguchi, K. Itagaki, S. Saijo, and Y. Iwakura. 1993. Inflammatory polyarthritis in mice transgenic for human T cell leukemia virus type I. *Arthritis Rheum.* 36:1612-1620.
- Iwakura, Y., S. Saijo, Y. Kioka, J. Nakayama-Yamada, K. Inagaki, M. Tosu, M. Asano, Y. Kanai, and K. Kakimoto. 1995. Autoimmunity induction by human T cell leukemia virus type I in transgenic mice that develop chronic inflammatory arthropathy resembling rheumatoid arthritis in humans. *J. Immunol.* 155:1588-1598.
- Gavrich, Y., Y. Sherman, and S.A. Ben-Sasson. 1992. Identification of programmed cell death in situ via specific labeling of nuclear DNA fragmentation. *J. Cell Biol.* 119:493-501.
- Hinuma, Y., K. Nagata, M. Hanaoka, M. Nakai, T. Matsumoto, K. Kinoshita, S. Shirakawa, and I. Miyoshi. 1981. Adult T-cell leukemia: antigen in an ATL cell line and detection of antibodies to the antigen in the human sera. *Proc. Natl. Acad. Sci. USA.* 78:6476-6480.
- Gessain, A., F. Barin, J.C. Vernant, O. Gout, L. Maurs, and G. Calender. 1985. Antibodies to human T-lymphotropic virus type-I in patients with tropical spastic paraparesis. *Lancet.* ii:407-410.
- Osame, M., K. Usuku, S. Izumo, N. Ijichi, H. Amitani, A. Igata, M. Matsumoto, and M. Tara. 1986. HTLV-I associated myelopathy, a new clinical entity. *Lancet.* i:1031-1032.
- Kitajima, I., I. Maruyama, S. Maruyama, S. Ijichi, N. Eiraku, Y. Miura, and M. Osame. 1989. Polyarthritis in human T lymphotropic virus type I-associated myelopathy. *Arthritis Rheum.* 32:1342-1344.
- Nishioka, K., I. Maruyama, K. Sato, I. Kitajima, T. Nakajima, and M. Osame. 1989. Chronic inflammatory arthropathy associated with HTLV-I. *Lancet.* i:441.
- Sagawa, K., M. Mochizuki, K. Masuoka, K. Katagiri, T. Katayama, T. Maeda, A. Tanimoto, S. Sugita, T. Watanabe, and K. Itoh. 1995. Immunopathological mechanisms of human T cell lymphotropic virus type I (HTLV-I) uveitis. Detection of HTLV-I-infected T cell in the eye and their constitutive cytokine production. *J. Clin. Invest.* 95:852-858.
- Green, J.E., S.H. Hinrich, J. Vogel, and G. Jay. 1989. Endocrinopathy resembling Sjögren's syndrome in HTLV-I tax transgenic mice. *Nature (Lond.)*. 341:72-74.
- Terada, K., S. Katamine, K. Eguchi, R. Moriuchi, M. Kita, H. Shimada, I. Yamashita, K. Iwata, Y. Tsuji, S. Nagataki, and T. Miyamoto. 1994. Prevalence of serum and salivary antibodies to HTLV-I in Sjögren's syndrome. *Lancet.* 344:1116-1119.
- Maruyama, M., H. Shibuya, H. Harada, M. Hatakeyama, M. Seiki, T. Fujita, J. Inoue, M. Yoshida, and T. Taniguchi. 1987. Evidence for aberrant activation of the interleukin-2 autocrine loop by HTLV-I encoded p40x and T3/Ti complex triggering. *Cell.* 48:343-350.
- Cross, S.L., M.B. Feinberg, J.B. Wolf, N.J. Holbrook, F. Wong-Staal, and W.J. Leonard. 1987. Regulation of the human interleukin-2 receptor alpha chain promoter: activation of a nonfunctional promoter by the transactivator gene of HTLV-I. *Cell.* 49:47-56.
- Arai, N., D. Nomura, D. Villaret, R.D. Malefijt, M. Seiki, M. Yoshida, M. Fukuyama, M. Maekawa, J. Kudoh, N. Shimizu et al. 1989. Complete nucleotide sequence of the chromosomal gene for human IL-4 and its expression. *J. Immunol.* 142:274-282.
- Yamada, T., S. Yamaoka, T. Goto, M. Nakai, Y. Tsujimoto, and M. Hatanaka. 1994. The human T-cell leukemia virus type I Tax protein induces apoptosis which is blocked by the Bcl-2 protein. *J. Virology.* 68:3374-3379.
- Chlichlia, K., G. Moldenhauer, P. Daniel, M. Busslinger, L. Gazzolo, V. Schirmacher, and K. Khazaie. 1995. Immediate effects of reversible HTLV-I tax function: T-cell activation and apoptosis. *Oncogene.* 10:269-277.
- Watanabe-Fukunaga, R., C.I. Brannan, N.G. Copeland, N.A. Jenkins, and S. Nagata. 1992. Lymphoproliferation disorder in mice explained by defects in Fas antigen that mediates apoptosis. *Nature (Lond.)*. 356:314-317.
- Takahashi, T., M. Tanaka, C.I. Brannan, N.A. Jenkins, N.G. Copeland, T. Suda, and S. Nagata. 1994. Generalized lymphoproliferative disease in mice, caused by a point mutation in the Fas ligand. *Cell.* 76:969-976.
- Ogasawara, J., R. Watanabe-Fukunaga, M. Adachi, A. Matsuzawa, T. Kasugai, Y. Kitamura, N. Itoh, T. Suda, and S. Nagata. 1993. Lethal effect of the anti-Fas antibody in mice. *Nature (Lond.)*. 364:806-809.
- Nishimura, Y., A. Ishi, Y. Kobayashi, Y. Yamazaki, and S. Yonehara. 1995. Expression and function of mouse Fas antigen on immature and mature T cells. *J. Immunol.* 154:4395-4403.