

Hyperexpression of Mitogen-activated Protein Kinase in Human Breast Cancer

Vimala S. Sivaraman,* Hsien-yu Wang,† Gerard J. Nuovo,§ and Craig C. Malbon^{||}*Department of Surgery, †Department of Physiology and Biophysics, §Department of Pathology, and ^{||}Department of Molecular Pharmacology, University Medical Center, SUNY/Stony Brook, Stony Brook, New York 11794

Abstract

Mitogen-activated protein (MAP) kinases act as transducers of extracellular signaling via tyrosine kinase–growth factor receptors and G-protein–linked receptors to elements regulating transcription. The activity, abundance, and localization of MAP kinase was investigated in normal and malignant neoplasia of the breast. In carcinoma of the breast, MAP kinase was heavily phosphorylated on tyrosyl residues and its activity elevated 5–10-fold over benign conditions, such as fibroadenoma and fibrocystic disease. By *in situ* reverse transcription-polymerase chain reaction, hyperexpression of MAP kinase mRNA can be localized to malignant, epithelial cells. Metastatic cells within involved lymph nodes of patients with breast cancer also display hyperexpression of MAP kinase. In spite of persistent activation via phosphorylation, MAP kinase expression is upregulated 5–20-fold and this hyperexpression may be a critical element to initiation as well as the metastatic potential of various forms of human breast cancer. (*J. Clin. Invest.* 1997. 99:1478–1483.)

Key words: MAP kinase • breast • carcinoma • *in situ* polymerase chain reaction • hyperexpression

Introduction

Breast cancer is one of the most common malignancies affecting women (1). The etiology and pathogenesis of breast carcinoma remain unclear, but several observations suggest a prominent role for the mitogen-activated protein (MAP)¹ kinase regulatory network (2). Regulation of MAP kinase is relegated to a cascade of protein kinases, culminating in dual-specificity kinases that phosphorylate MAP kinase on threonyl and tyrosyl residues (3, 4). Upstream regulators of MAP kinase, such as the small molecular weight G-protein oncogene product *ras* (5) and *Raf-1* (6), as well as protein kinase C (7)

have been associated with breast cancer. To what extent MAP kinase represents a common point of activation by agents promoting breast cell proliferation or whether MAP kinase is itself a critical element in the etiology or pathogenesis of breast carcinoma was investigated directly in human tissues obtained from patients undergoing surgery for both benign and malignant conditions of the breast.

Methods

Assurances. The protocol and patient consent forms for these studies were reviewed and approved by the Institutional Review Board (Committee on Research Involving Human Subjects) of the State University of New York at Stony Brook.

Tissue preparation. Tissue was excised, sectioned, frozen, stored temporarily at -80°C , and placed in liquid nitrogen. Frozen samples were placed in liquid nitrogen while mechanically pulverized. The resultant powder was reconstituted into a lysis buffer [70 mM β -glycerophosphate (pH 7.2), 0.1 mM sodium vanadate, 2 mM MgCl_2 , 1 mM EGTA, 1 mM dithiothreitol, 0.5% (vol/vol) Triton X-100, 0.2 mM phenylmethylsulfonyl fluoride, 5 $\mu\text{g}/\text{ml}$ Leupeptin, and 2 $\mu\text{g}/\text{ml}$ aprotinin] and the MAP kinase activity was measured using EGF receptor peptide as the substrate (8). MAP kinase activity of human breast tissue stored, maintained, and assayed under these conditions was stable for at least 2 mo.

MAP kinase assay. MAP kinase activity was measured using EGF receptor peptide as the substrate, as described (8).

Immunoblotting and immunohistochemistry. Tissue was excised, sectioned, frozen, and prepared as described above. Samples were processed further in one of two manners. The samples (50 μg protein/lane) to be used in direct immunoblotting were subjected to SDS-PAGE on 10% acrylamide separating gels. The samples to be subjected to immunoprecipitation followed by immunoblotting were immunoprecipitated from whole cell extracts (0.6 mg protein) with a murine monoclonal antibody to MAP kinase (Zymed Laboratories, Inc., South San Francisco, CA) and the immunoprecipitate was subjected to SDS-PAGE on 10% acrylamide separating gels. The resolved proteins from direct SDS-PAGE (see Figs. 2 and 7) or from the immunoprecipitation (see Fig. 6) were transferred to nitrocellulose blots and stained either with an antibody specific for human MAP kinase or with an antiphosphotyrosine antibody (Transduction Laboratories, Lexington, KY), made visible by alkaline phosphatase-conjugated second antibody staining of the immune complexes (9). Briefly, the blots were prepared, stained with primary antibodies, washed, stained with the second antibody, and then incubated at 22°C with substrate solution [5.0 ml of 50 mM glycine (pH 9.6), 0.17 mg/ml *p*-nitro blue tetrazolium chloride, 7 mM MgCl_2 , and 0.08 mg/ml 5-bromo-4-chloro-3-indoyl phosphate] until bands were visible (usually 30 s). The reaction was terminated by washing free the substrate solution and rinsing with distilled water. Immunostaining of the dually phosphorylated “active” form of MAP kinase was performed with rabbit polyclonal antibodies (Promega, Madison, WI). The mobility of MAP kinase was established by protein markers. For immunohistochemical analysis of MAP kinase, a mouse monoclonal antibody raised against the human MAP kinase was used. Immune complexes

Address correspondence to Craig C. Malbon, Department of Molecular Pharmacology, Diabetes and Metabolic Diseases Research Program, University Medical Center, SUNY/Stony Brook, Stony Brook, NY 11794-8651. Phone: 516-444-7873; FAX: 516-444-7696; E-mail: craig@pharm.som.sunysb.edu

Received for publication 8 August 1996 and accepted in revised form 17 January 1997.

1. *Abbreviations used in this paper:* MAP, mitogen-activated protein; RT-PCR, reverse transcription-polymerase chain reaction.

J. Clin. Invest.

© The American Society for Clinical Investigation, Inc.

0021-9738/97/04/1478/06 \$2.00

Volume 99, Number 7, April 1997, 1478–1483

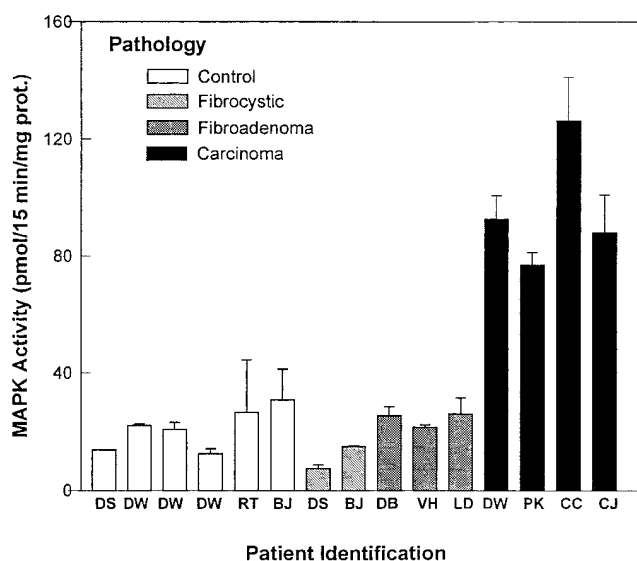


Figure 1. MAP kinase activity is increased markedly in extracts of breast tissue from patients with carcinoma as compared with normal, benign fibroadenoma, and fibrocystic disease. 30 tissue samples were analyzed, each in triplicate, each on more than one occasion. Representative results are displayed for each of the four groups defined by pathological analysis of the tissue.

in immunohistochemical staining were made visible by use of a second, biotinylated antibody, followed by alkaline phosphatase-conjugated Streptavidin and a fast red substrate (10).

In situ polymerase chain reaction. Thin (4- μ m) sections of paraffin blocks of primary breast carcinoma tissue were subjected to in situ reverse transcription-polymerase chain reaction (RT-PCR) (11, 12). Tissue was stained with eosin and hematoxylin. Negative controls used PCR primers for an unrelated hepatitis C viral RNA (sense orientation, TCCGCGGCCGCACTCCACCATGAATCACTCCCC; antisense orientation, AGTCTTGCGGCCGACGCGCCAAATC) after DNase digestion. Positive controls used PCR primers for MAP kinase (sense orientation, GCAGGTGTTTCGACGTGGG; antisense orientation, GTGCAGAACGTTAGCTGAAT) and genomic DNA in the absence of pretreatment with DNase. For analysis of MAP kinase mRNA in situ, samples were treated with DNase, subjected to reverse transcription, and then PCR. Digoxigenin (in the form of dUTP) was used as the reporter molecule for PCR and an antidigoxigenin antibody coupled to alkaline phosphatase was used with a chromogen to make the PCR products visible (blue staining).

Results and Discussion

MAP kinase activity was assayed in 37 breast tissue samples from the following patients: five with normal breast tissue, one

with gynecomastia, four with benign fibroadenoma, five with fibrocystic disease, one with fibrocystic disease and fibroadenoma, two with chronic inflammatory disease, eleven subsequently identified to have primary breast carcinoma, and one patient with carcinosarcoma. The activity of MAP kinase, assayed in extracts using the EGF receptor peptide as substrate, was markedly elevated in all 11 patients with breast cancer. Three are shown in Fig. 1. Four samples of malignant and normal tissue from one patient (DW) with cancer of the breast were analyzed. The pathology identified carcinoma in one sample from DW, the one displaying elevated MAP kinase activity. The three samples from DW that were negative for malignancy displayed four- to fivefold lower activity. MAP kinase activity (pmol/min/mg protein) was 1.40 ± 0.19 (mean \pm SEM, $n = 6$) for tissue from the control study group as compared with 6.39 ± 0.71 ($P \leq 0.05$ for the difference) for the tissue from patients with primary breast carcinoma.

Since enhanced activity may reflect activation of MAP kinase via upstream signaling elements, the amount of MAP kinase was determined in breast tissue extracts from patients with fibrocystic disease, benign fibroadenoma, and carcinoma of the breast. Equal amounts of cellular protein were subjected to SDS-PAGE, immunoblotting, and staining with an antibody to human MAP kinase (Fig. 2). Immunostaining of the blots displays marked hyperexpression of MAP kinase in breast cancer samples specifically. Tissue samples of benign fibroadenoma and fibrocystic disease displayed little if any staining of MAP kinase under these same conditions.

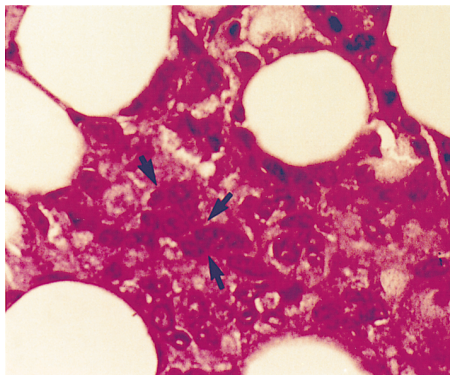
Breast tissue is heterogeneous with respect to cell type and therefore it was critical to identify the cell type(s) responsible for the elevated expression of MAP kinase. In view of the limited amounts of tissue available and the need for high sensitivity, RT-PCR was adapted in situ for the studies (Fig. 3). Tissue sections from the primary breast carcinomas analyzed for MAP kinase activity and expression were stained with hematoxylin and eosin (Fig. 3 A); representative cancer cells are highlighted by arrows. Analysis using PCR primers for an unrelated hepatitis C RNA that would not be present in breast tissue provides a negative control (Fig. 3 B). In the absence of the treatment with DNase, amplifying genomic DNA with the primers for MAP kinase demonstrates nuclear staining and provides a positive control (Fig. 3 C). Digestion with DNase followed by in situ RT-PCR provided the first evidence (blue staining) for high levels of MAP kinase mRNA in the cytoplasm of cancerous epithelial cells (arrows), but not in surrounding stromal and adipose cells (Fig. 3, D and F). In addition, samples from the same patient, one normal specimen (Fig. 3 E), the other harboring malignancy (Fig. 3 F), were analyzed by in situ RT-PCR using the primers for MAP kinase. Intense staining indicates expression of MAP kinase mRNA in



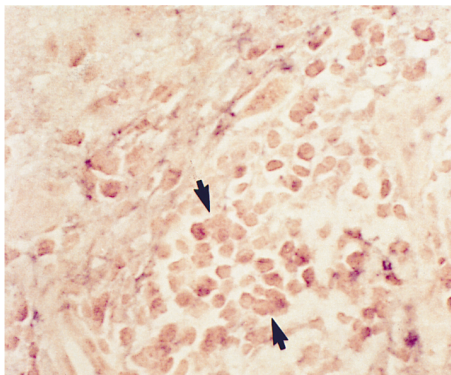
Figure 2. MAP kinase expression is markedly elevated in extracts of breast tissue from patients with carcinoma (CA) as compared with benign fibroadenoma (FA), and fibrocystic disease (FC). Tissue was excised, sectioned, frozen, and prepared as described in the legend to Fig. 1. Samples (50 μ g protein/lane) were subjected to SDS-PAGE. The separated proteins were

transferred to nitrocellulose blots and stained with an antibody specific for human MAP kinase (GIBCO BRL, Gaithersburg, MD), made visible by alkaline phosphatase-conjugated second antibody staining of the immune complexes (9).

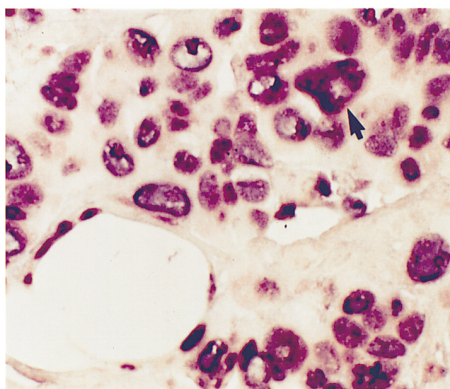
A EOSIN + HEMATOXYLIN STAIN



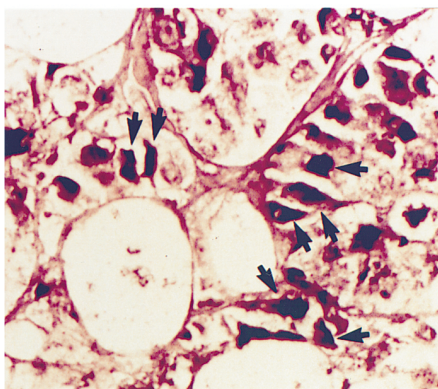
B NEGATIVE CONTROL *IN SITU* RT-PCR



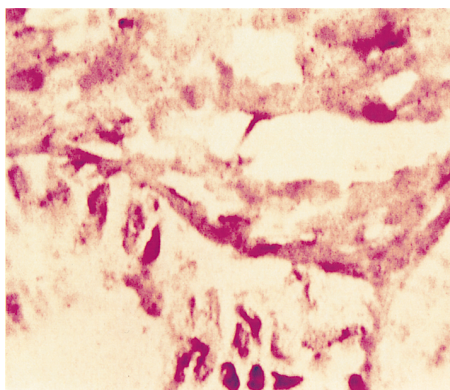
C POSITIVE CONTROL (-DNASE)



D PATIENT DW *IN SITU* RT-PCR



E PATIENT DW *IN SITU* RT-PCR



F PATIENT DW *IN SITU* RT-PCR

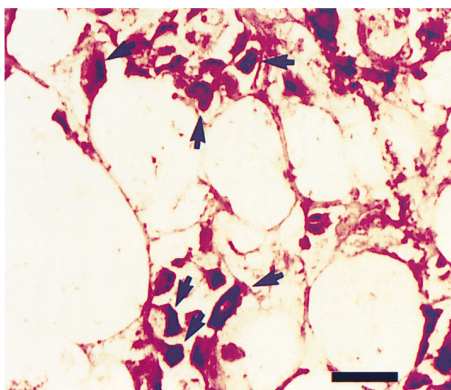


Figure 3. MAP kinase mRNA is highly expressed in epithelial cells of primary breast carcinoma: analysis by *in situ* RT-PCR. Thin (4- μ m) sections of paraffin blocks of primary breast carcinoma tissue were subjected to *in situ* RT-PCR (11, 12). Tissue was stained with eosin and hematoxylin. Histopathology reveals invasive cancer cells, as indicated with arrows (A). A negative control using PCR primers for an unrelated hepatitis C viral RNA (sense orientation, TCCGCGGCCGCACTCCACCATGAATCACTCCCC; antisense orientation, AGTCTTGCGGCGCAGCGCCAAATC) after DNase digestion (B), a positive control using PCR primers for MAP kinase (sense orientation, GCAGGTGTTTCGACGTGGG; antisense orientation, GTGCAGAACGTTAGCTGAAT) and genomic DNA in the absence of pretreatment with DNase (C), and the test using PCR primers for MAP kinase after treatment with DNase, followed by RT-PCR (D). *In situ* RT-PCR of MAP kinase mRNA in benign (E) and malignant (F) samples from one patient (DW) are displayed. Digoxigenin (in the form of dUTP) was used as the reporter molecule for PCR and an antidigoxigenin antibody coupled to alkaline phosphatase used with a chromogen to make the PCR products visible (blue staining). Arrows identify cancer cells. Bar, 5.0 μ m.

the cytoplasm of malignant cells. For benign fibroadenomatous tissue, only a weak signal was observed on occasion in the epithelial cells (not shown).

Regional lymph node metastasis of breast carcinoma is a frequent event. Examination of tissue from lymph nodes provided an opportunity to determine whether hyperexpression of MAP kinase persists in the metastatic cells of involved lymph nodes (Fig. 4). Hematoxylin and eosin staining of tissue sections obtained from lymph node metastases of primary breast carcinoma reveals cancer cells (Fig. 4 A, arrow). Performing RT-PCR with primers for hepatitis C RNA after prior digestion of the samples with DNase provided a negative con-

control for *in situ* analysis, displaying no signal (Fig. 4 B). In the absence of DNase treatment, amplification of genomic DNA with PCR primers for MAP kinase displayed intense nuclear staining (blue) of all cells, providing the positive control (Fig. 4 C). When *in situ* RT-PCR was performed using primers for MAP kinase after DNase digestion, intense staining was observed in the metastatic cancer cells, but not in the surrounding stromal cells within the lymph node (Fig. 4 D). Although not quantitative, results from the *in situ* RT-PCR showed prominent signal from the cancerous epithelial cells and virtually no signal from surrounding stromal cells, reflecting hyperexpression of MAP kinase mRNA in the cancer cells.

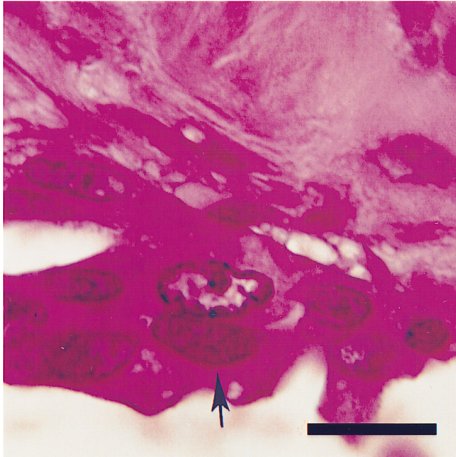
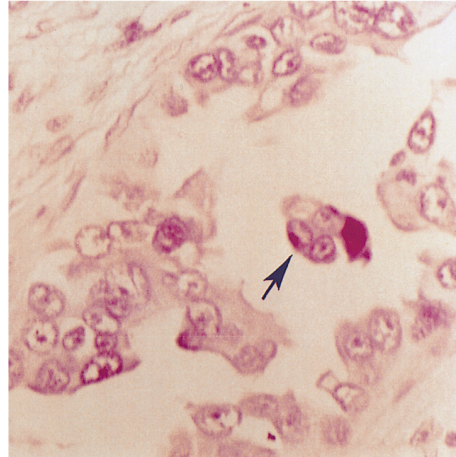
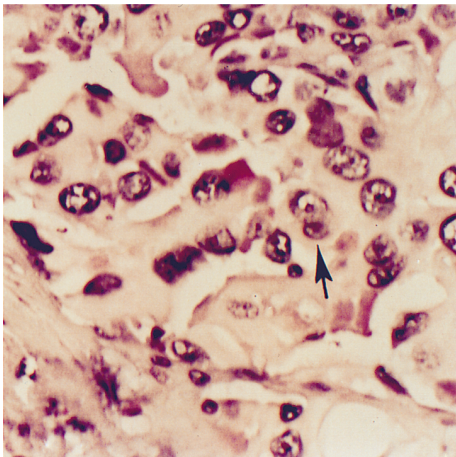
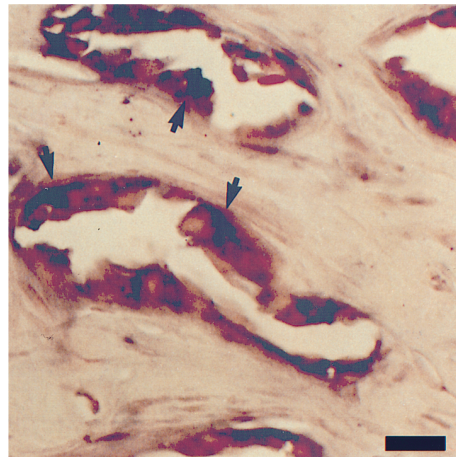
A EOSIN + HEMATOXYLIN STAIN**B NEGATIVE CONTROL IN SITU RT-PCR****C POSITIVE CONTROL (-DNASE)****D IN SITU RT-PCR**

Figure 4. MAP kinase mRNA is highly expressed in lymph node metastasis of primary breast carcinoma: analysis by in situ RT-PCR. Thin (4- μm) sections of paraffin blocks of lymph node metastasis of primary breast carcinoma tissue were subjected to in situ RT-PCR. Tissue was stained with eosin and hematoxylin. Histopathology reveals metastatic cancer cells, as indicated with an arrow (A). A negative control using PCR primers for an unrelated hepatitis C viral RNA after DNase digestion (B), a positive control using PCR primers for MAP kinase and genomic DNA without prior DNase treatment (C), and the test using PCR primers for MAP kinase after treatment with DNase, followed by RT-PCR (D). Digoxigenin (in the form of dUTP) was used as the reporter molecule for PCR and an anti-digoxigenin antibody coupled to alkaline phosphatase used with a chromogen to make the PCR products visible (blue staining). In all panels, arrows identify representative cancer cells. Bar, 5.0 μm .

Tissues from primary breast cancer and lymph node metastases were subjected to immunohistochemical analysis. Antibodies specific for MAP kinase were used to stain the tissue and a fast red substrate for the secondary, alkaline phosphatase-conjugated antibody made visible MAP kinase in primary and metastatic breast cancer (Fig. 5, A and B, respec-

tively). Intense red staining was observed in the cytoplasm of cancerous epithelial cells at both the primary and metastatic sites. By criteria of enzyme activity, immunoblotting, in situ PCR, and immunohistochemical localization, MAP kinase clearly is overexpressed in the epithelial cells of primary breast cancer as well as at a distant metastatic site. Thus, overexpres-

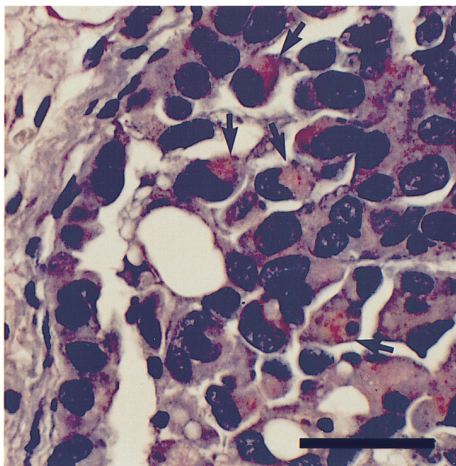
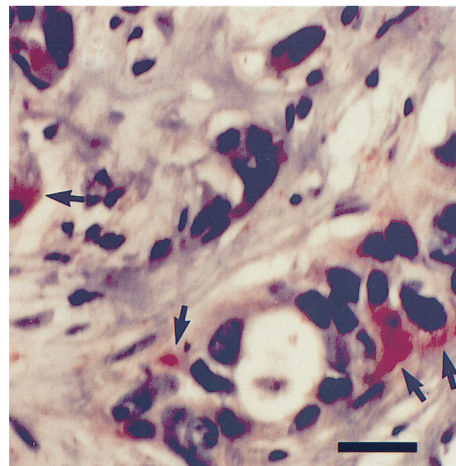
A PRIMARY BREAST CANCER**B INVOLVED LYMPH NODE**

Figure 5. MAP kinase is hyperexpressed in primary breast cancer and metastasis to the lymph node: immunohistochemical analysis. Tissue sections from paraffin blocks of primary breast carcinoma and of metastasis to the lymph node were subjected to immunohistochemical analysis. The sections were stained with eosin and hematoxylin. Fast red staining indicates immune complexes with primary antibody to MAP kinase. For both primary breast cancer (A) and metastatic breast cancer to the lymph node (B), intense staining of MAP kinase was observed in the cytoplasm of cancer cells only. Arrows identify typical cancer cells. Bar, 5.0 μm .

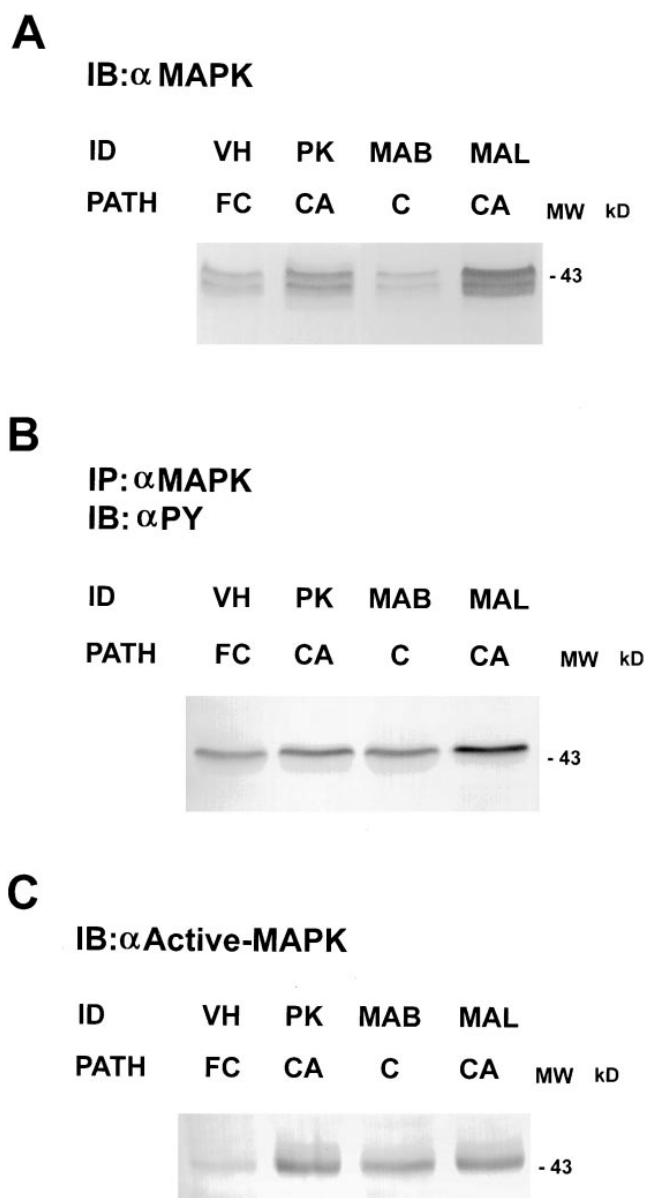


Figure 6. MAP kinase is overexpressed in primary breast cancer. Samples were prepared as described in the legend to Fig. 2. Samples were immunoprecipitated (IP, B) and/or directly subjected to SDS-PAGE (50 μ g/lane) and the resolved proteins were transferred electrophoretically to nitrocellulose blots for immunoblot staining (IB, A and C). For A, immunoblots (IB) were stained for MAP kinase protein with a murine monoclonal antibody against MAP kinase. For B, samples were immunoprecipitated with a rabbit polyclonal anti-MAP kinase antisera (IP) and the immunoprecipitates were subjected to SDS-PAGE and immunostaining with an antiphosphotyrosine antibody (IB). For C, immunoblots (IB) were stained with a rabbit polyclonal antibody specific for the dually phosphorylated (serine and tyrosine), active form of MAP kinase.

sion of MAP kinase occurs in human breast cancer cells, at primary and metastatic sites, i.e., an involved lymph node.

Immunoblotting of MAP kinase reveals overexpression in tissue samples of patients with primary breast cancer (Fig. 6 A). Both the 42,000- M_r and 44,000- M_r forms of MAP kinase were detected in the samples, although in many cases the two

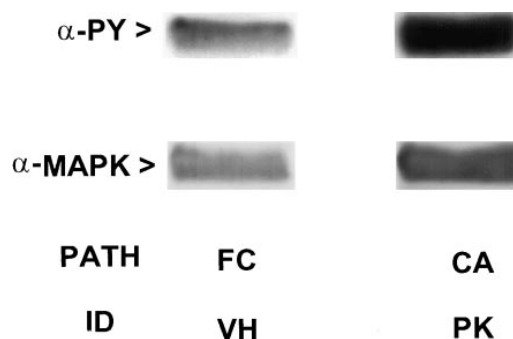


Figure 7. Phosphorylation on tyrosyl residues is elevated in MAP kinase overexpressed in primary breast carcinoma. Samples of whole cell extracts were prepared for SDS-PAGE and immunoblotting as described in the legend to Fig. 2, and then were stained with antibodies against either MAP kinase (MAPK) or phosphotyrosine (PY). Protein loading (50 μ g/lane) was equivalent for samples from a patient with fibrocystic disease (FC) and primary breast carcinoma (CA).

forms are not readily apparent, perhaps owing to comigration after differential phosphorylation (Fig. 2). In many instances, for samples from patients with fibrocystic disease as well as from normal patients, MAP kinase expression was not readily detected (Fig. 2), whereas in samples from other patients (Fig. 6 A) MAP kinase was detected. The samples from primary breast cancer, when subjected to immunoprecipitation and then to immunoblotting with an antibody to phosphotyrosine, display increased phosphotyrosine staining (Fig. 6 B). Staining of immunoblots with antibodies specific for the dually phosphorylated, "active" form of MAP kinase also reveal increased staining in those samples from primary breast cancer patients compared with normal controls and patients with fibrocystic disease (Fig. 6 C). Further immunoblotting analysis of samples from patient VH with fibrocystic disease as compared with that of patient PK with primary breast cancer confirms that not only is the amount of MAP kinase increased, but also its phosphorylation state is increased in primary breast cancer (Fig. 7).

MAP kinase plays a pivotal role in cell proliferation and its activity is regulated by diverse extracellular signals and by products of several protooncogenes (3-6). Reversible protein phosphorylation is the established mechanism of regulation of MAP kinase (3), an activity controlled by a family of dual specificity protein kinases and a complex upstream cascade from tyrosine kinase-linked and G-protein-linked receptors (4). Attenuation in response to chronic stimulation, a paradigm in cell signaling (13), would be expected to dampen MAP kinase activation and expression. Activation of MAP kinase is intimately associated with cell proliferation (14) and constitutively active MAP kinase induces oncogenicity when MAP kinase is expressed in fibroblasts (15). The first in vivo analysis of MAP kinase activity in human breast cancer, reported herein, reveals sharply elevated activities of this key protein kinase. The activation of MAP kinase observed in primary breast carcinoma cannot be ascribed solely to phosphorylation of the protein. Immunoblotting, in fact, revealed a marked increase in the amount of MAP kinase in primary breast cancer when compared with normal tissue as well as to tissue from patients suffering from nonmalignant diseases of the breast. Analysis by in situ RT-PCR confirms these data

and clearly establishes the malignant epithelial cells as overexpressing MAP kinase mRNA. In addition, expression of MAP kinase in the metastatic cells within the involved lymph node was markedly elevated. Hyperexpression of MAP kinase may be a critical event in the initiation/progression of human breast carcinoma and derivative metastases.

Acknowledgments

We acknowledge the invaluable assistance of Dr. Alan Heimann in tissue procurement and of Dr. Roger Grimson for statistical analysis of the data.

This work was supported in part by a grant from the American Cancer Society (to C.C. Malbon), by an award (to V.S. Sivaraman) from the William and Florence Catacosinos Cancer Fund, and by institutional support from the Department of Surgery, University Medical Center-SUNY/Stony Brook, the Diabetes and Metabolic Disease Research Program at Stony Brook, and the Center for Advanced Technology (Biotechnology) of the State of New York. This work could not have been accomplished without the generous support from the Department of Pathology and the University Hospital-SUNY/Stony Brook.

References

1. Wingo, P.A., T. Tong, and S. Bolden. 1995. Cancer statistics 1995. *CA Cancer J. Clin.* 45:8-30.
2. Dickson, R.B., D.S. Salomon, and M.E. Lippman. 1992. Tyrosine kinase-receptor protooncogene interactions in breast cancer. *Cancer Treat. Res.* 61: 249-273.
3. Blenis, J. 1994. Signal transduction via MAP kinase: proceed at your own RSK. *Proc. Natl. Acad. Sci. USA.* 90:5889-5892.
4. Cobb, M.H., and E.J. Goldsmith. 1995. How MAP kinases are regulated. *J. Biol. Chem.* 270:14843-14846.
5. Janes, P.W., R.J. Daly, A. Defazio, and R.J. Sutherland. 1994. Activation of the Ras pathway in breast cancer cells. *Oncogene.* 9:3601-3608.
6. Callans, L.S., H. Naama, M. Khandelwal, R. Plotkin, and L. Jardin. 1995. Raf-1 expression in human breast cancer cells. *Ann. Surg. Oncol.* 2:38-42.
7. Arteaga, C.L., M.D. Johnson, G. Todderud, R.J. Coffey, G. Carpenter, and D.L. Page. 1991. Elevated content of tyrosine kinase substrate phospholipase C-gamma in human breast carcinomas. *Proc. Natl. Acad. Sci. USA.* 88: 10435-10439.
8. Gupta, S.K., C. Gallego, G.L. Johnson, and L.E. Heasley. 1992. MAP kinase is constitutively active in *gip2* and *src* transformed rat 1a cells. *J. Biol. Chem.* 267:7987-7990.
9. Moxham, C.P., S.T. George, M.P. Graziano, H.J. Brandwein, and C.C. Malbon. 1986. Mammalian beta1- and beta2-adrenergic receptors, immunological and structural comparisons. *J. Biol. Chem.* 261:14562-14570.
10. Nuovo, G.J., A. Forde, P. MacConnell, and R. Farhenwald. 1993. In situ detection of PCR-amplified HIV-1 nucleic acids and tumor necrosis factor cDNA in cervical tissues. *Am. J. Pathol.* 143:40-48.
11. Nuovo, G.J., P.B. MacConnell, A. Sinsir, F. Valea, and D.L. French. 1995. Correlation of the in situ detection of polymerase chain reaction-amplified metalloproteinase complementary DNAs and their inhibitors with prognosis in cervical carcinoma. *Cancer Res.* 55:267-275.
12. Nuovo, G.J. 1994. In Situ Hybridization. Protocols and Applications. 2nd Ed. Raven Press, New York.
13. Hadcock, J.H., and C.C. Malbon. 1993. Agonist regulation of gene expression of adrenergic receptors and G-proteins. *J. Neurochem.* 60:1-9.
14. Brunet, A., J.M. Brondello, G. L'Allemain, P. Lenormand, F. McKenzie, G. Pages, and J. Pouyssegur. 1995. MAP kinase module: role in the control of cell proliferation. *Comptes Rendus Sci. Soc. Biol.* 189:43-57.
15. Brunet, A., G. Pages, and J. Pouyssegur. 1994. Constitutively active mutants of MAP kinase induce growth factor-relaxation and oncogenicity when expressed in fibroblasts. *Oncogene.* 9:3379-3387.