

Received: 2016.05.04  
Accepted: 2016.07.07  
Published: 2016.10.26

## A Case of Birt-Hogg-Dubé (BHD) Syndrome Harboring a Novel Folliculin (*FLCN*) Gene Mutation

Authors' Contribution:  
Study Design A  
Data Collection B  
Statistical Analysis C  
Data Interpretation D  
Manuscript Preparation E  
Literature Search F  
Funds Collection G

F 1 **Takuro Yukawa**  
E 1 **Takuya Fukazawa**  
F 1 **Masakazu Yoshida**  
F 1 **Ichiro Morita**  
C 2 **Katsuya Kato**  
C 3 **Yasumasa Monobe**  
C 4 **Mitsuko Furuya**  
F 1 **Yoshio Naomoto**

1 Department of General Surgery, Kawasaki Medical School, Okayama, Japan  
2 Department of Diagnostic Radiology 2, Kawasaki Medical School, Okayama, Japan  
3 Department of Pathology 1, Kawasaki Medical School, Okayama, Japan  
4 Department of Molecular Pathology, Yokohama City University Graduate School of Medicine, Kanagawa, Japan

**Corresponding Author:** Takuya Fukazawa, e-mail: [FukazawaT@aol.com](mailto:FukazawaT@aol.com)  
**Conflict of interest:** None declared

**Patient:** Female, 56  
**Final Diagnosis:** Birt-Hogg-Dubé syndrome  
**Symptoms:** Dyspnea  
**Medication:** —  
**Clinical Procedure:** —  
**Specialty:** Pulmonology

**Objective:** Rare disease

**Background:** Birt-Hogg-Dubé (BHD) syndrome is an autosomal dominant disorder clinically characterized by pulmonary cysts, spontaneous pneumothorax, renal cell cancer, and skin fibrofolliculomas. The disorder is caused by germline mutations in the *FLCN* gene.

**Case Report:** A 56-year-old female was admitted to our hospital with a diagnosis of bilateral spontaneous pneumothorax. A computed tomography (CT) scan of the chest revealed bilateral multiple bullae predominantly located in the subpleural and mediastinal areas in the bilateral upper and lower lobes. Although she was cured by thoracic cavity drainage, she underwent resection of bilateral lung bullae because she had a prior history of right pneumothorax at 37- and 45-years of age. She had no signs of renal tumor but had fibrofolliculoma in her face and a family history of pneumothorax, we therefore suspected BHD syndrome. DNA sequence analyses determined that there was a two base pair deletion in exon 4 of the *FLCN* gene, confirming the diagnosis of BHD syndrome.

**Conclusions:** Here we report a case of BHD syndrome with a previously unreported *FLCN* mutation.

**MeSH Keywords:** Birt-Hogg-Dube Syndrome • Carcinoma, Renal Cell • Pneumothorax

**Full-text PDF:** <http://www.amjcaserep.com/abstract/index/idArt/899407>



1177



—



4



23



## Background

Birt-Hogg-Dubé (BHD) syndrome is a rare autosomal dominant disease originally reported in 1977 [1]. The syndrome is characterized by lung cysts, spontaneous pneumothorax, renal cell cancer, and skin fibrofolliculomas [2,3]. Some patients also may suffer from colorectal polyps and other cancers [4,5]. The gene responsible for BHD syndrome has been mapped on chromosome 17p11.2 and encodes *FLCN*, which is currently regarded as a tumor suppressor gene [6]. Since the first discovery of a mutation in the *FLCN* gene, genetic research has further advanced and various different *FLCN* germline mutations have been identified in Caucasian and Asian families [3,7–9]. Recently, we encountered a Japanese family with a lineage of BHD syndrome and documented histories of pneumothorax in family members. Genetic analysis of one of the family members and a computed tomographic (CT) scan of the chest were performed. Here we report the finding of a patient with BHD syndrome in which mutation analysis subsequently revealed a novel mutation in exon 4 of the *FLCN* gene.

## Case Report

A 56-year-old female non-smoker presented with a sudden onset of dyspnea. Clinical examination and chest X-ray confirmed bilateral pneumothorax (Figure 1A). An intercostal drain was inserted in the left side with complete resolution. Right pneumothorax was reversed without thoracic cavity drainage. She had a past history of right pneumothorax occurring at the ages of 37 years and 45 years. A computed tomography (CT) scan revealed bilateral multiple bullae predominantly located in the subpleural areas in the bilateral lower lobes (Figure 1B), however, no tomographic finding was observed in the abdomen. Physical examination revealed multiple smooth dome shaped skin-colored papules ranging from 0.5 to several mm in diameter spanning the nose and cheek; however, the skin manifestation was inconspicuous and she had not consulted a dermatologist. A detailed history suggested that there was no known inherited or connective tissue disease among the extended family; however, other members of her family, including her mother, younger brother, and her elder, second, and third sons had also suffered spontaneous pneumothorax and undergone surgery (Figure 2). The patient underwent bilateral sequential bullectomy by video-assisted thoracoscopic surgery (Figure 3). Unfortunately, left spontaneous pneumothorax recurred 5 weeks and 8 weeks after the surgery; for which she was treated with thoracic cavity drainage with pleurodesis and cured. The resected lung specimen showed multiple cysts distributed predominantly in subpleural and mediastinal space, and the air leakage site was not clear. The specimen did not show characteristic findings of lymphangioleiomyomatosis (LAM) and Sjogren's syndrome, which are

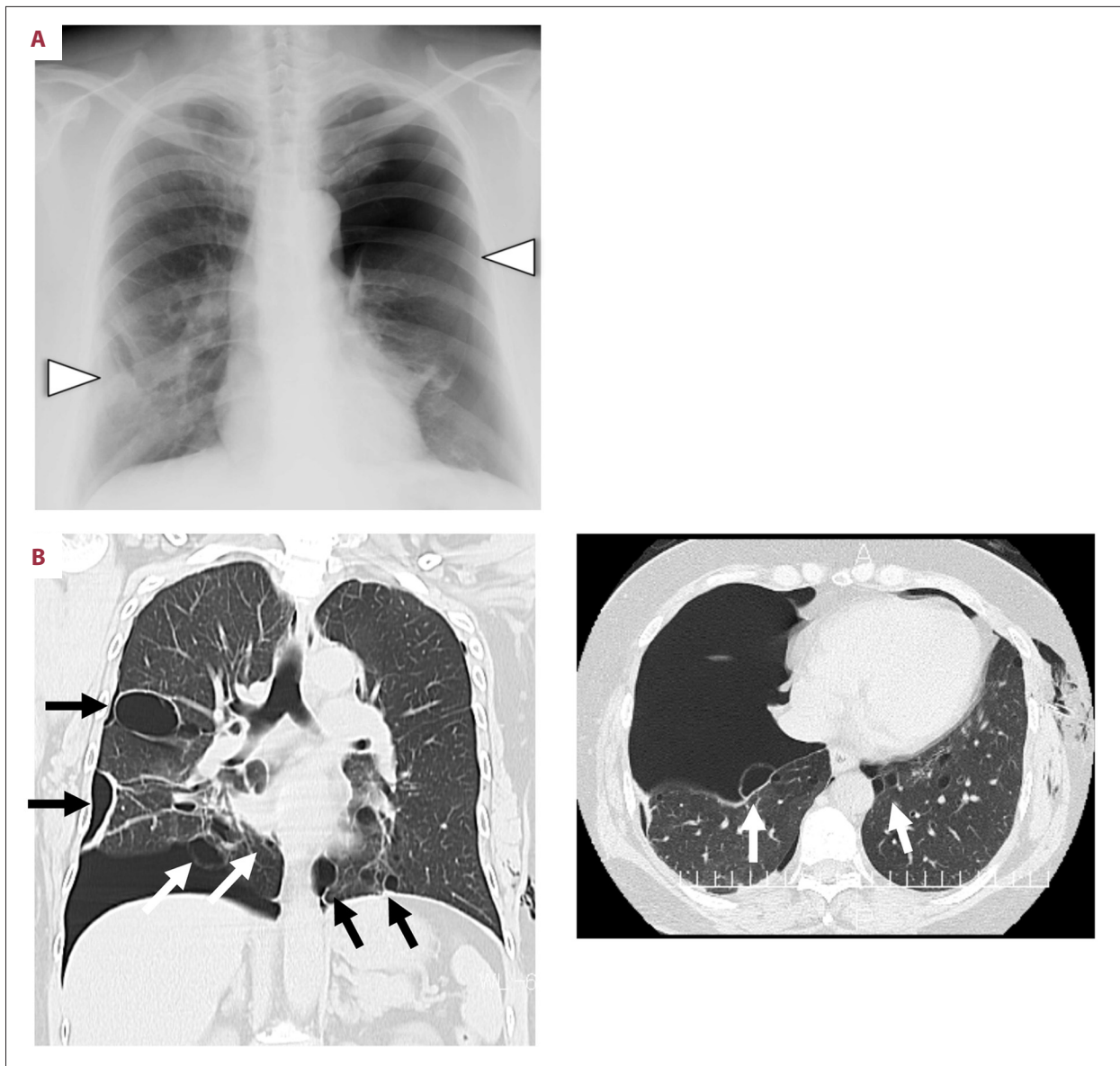pre-disposing factors of pneumothorax in women with multiple lung cysts. Molecular analysis of the *FLCN* gene was performed after informed consent from the patient and the family. Genomic DNA was extracted from peripheral blood leukocytes and subjected to mutation analysis. The coding region of the *FLCN* gene consisting of exon 4 to 14 was amplified with polymerase chain reaction (PCR) with oligonucleotide primers and was sequenced by the Sanger method. The sequence analysis revealed a novel deletion mutation (c.57\_58delCT) in exon 4 of the *FLCN* gene of this patient (Figure 4) [10].

## Discussion

Nickerson et al. determined in 2002 that the gene responsible for BHD syndrome lies within chromosomal band 17p11.2 and termed this gene *BHD* [6]. At present, the official symbol for this gene is *FLCN*. The gene encodes a deduced 579-amino acid protein, which is involved in cell growth [11] and is considered to be a tumor suppressor in the kidney [12]. It has been reported that there are various kinds of germline *FLCN* mutations in Caucasian and Asian patients with BHD syndrome. The *FLCN* gene is composed of 14 exons and mutations have been identified in all translated exons. Notably, C insertion or deletion in exon 11 is frequently detected in affected patients [12,13].

In this report, we described a novel mutation found in exon 4. Until now at least nine *FLCN* germline mutations have been identified in exon 4. Painter et al. reported a 4-bp deletion in the first coding exon (c.235\_238delTCGG) predicted to result in a TGA termination codon 50 missense amino acids downstream. This mutation was found in a large Finnish family with a dominantly inherited tendency for primary pneumothorax [13]. Bessis et al. reported a case with sporadic BHD syndrome harboring a novel germline mutation in the initiation codon of the *FLCN* gene (c.3delG) [14]. The patient had no lung cysts, no renal tumors, and no colon polyps but developed fibrofolliculomas. Although the proband's son suffered a spontaneous pneumothorax at the age of 4, the patient's family history was inconspicuous. The other exon 4 mutation (c.59delT) reported by Schmidt et al. was predicted to truncate the protein 34 missense amino acids downstream. Families that had this type of mutation developed fibrofolliculomas without other types of features [2]. In addition to these mutations, Toro et al. have also reported other types of mutations (c.147delA) [3]. In our case study, genetic analysis revealed a unique deletion mutation (c.57\_58delCT) in exon 4 that has not been previously described.

It has been reported that more than 80% of patients with BHD syndrome have lung cysts as determined by CT scans of the chest [3]. Pulmonary cysts (of primary spontaneous

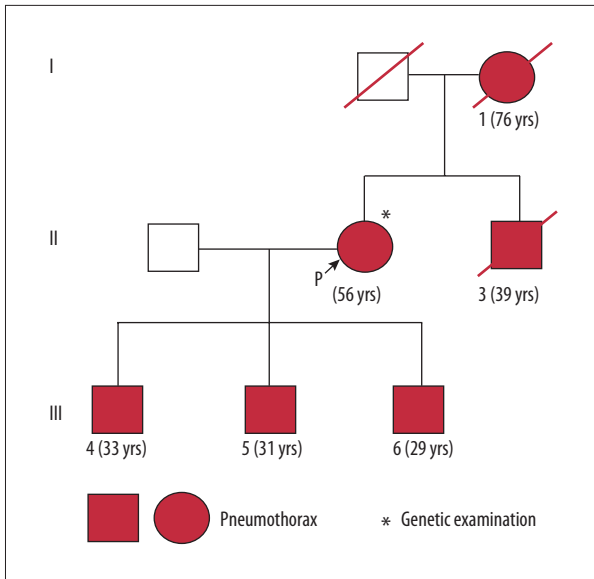


**Figure 1.** (A) Chest X-ray showing bilateral pneumothorax. Arrowheads indicate vanishing lungs. (B) Chest computed tomography scan from a case of BHD syndrome demonstrating multiple bilateral thin-walled cysts, predominantly distributed in the basilar regions of the lung. Arrows indicate lung cysts.

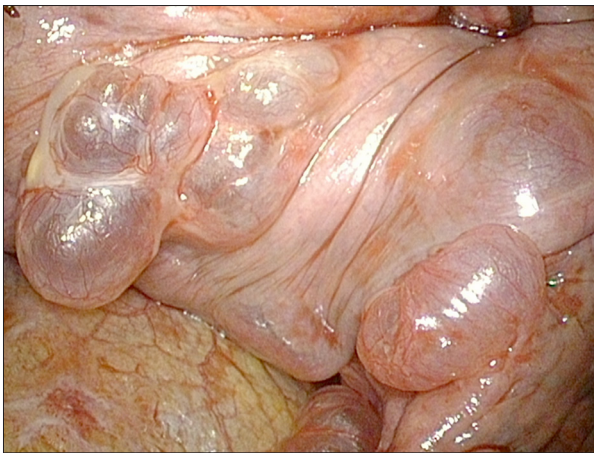
pneumothorax) are typically located in the apex of the lungs, however, the lung cysts in BHD syndrome are mostly found in the basilar region of the lung [15,16]. Moreover, the characteristic pathological findings of the lung cysts in BHD syndrome are radiologically round and contain blood vessels [17–19]. We confirmed these findings in the case of our patient. In addition to the fact that she was a non-smoker, clinical episodes and radiographic and histopathological findings eliminated the possibility of our patient having pulmonary Langerhans' cell histiocytosis (PLCH), lymphangioleiomyomatosis (LAM), tuberous sclerosis complex (TSC), lymphoid interstitial pneumonia

(LIP), and Sjogren's syndrome, which can also be causes of multiple lung cysts [20].

Although genetic analysis was performed only on this patient, we are planning to perform genetic analysis of family members of the patient. We consider annual screening for renal tumor to also be important for the patient and her family, so abdominal ultrasonography and magnetic resonance imaging (MRI) of the abdomen should be performed. We have explained to the patient and family that air travel carries a risk of pneumothorax in patients with BHD syndrome [21].



**Figure 2.** Simplified pedigree of the patient's family with spontaneous pneumothorax. Arrow indicates the proband (P). Video-assisted thoracoscopic bullectomy was performed in individuals 1, 2, 3, 4, 5, and 6. The ages of the patients who developed pneumothoraxes are shown.

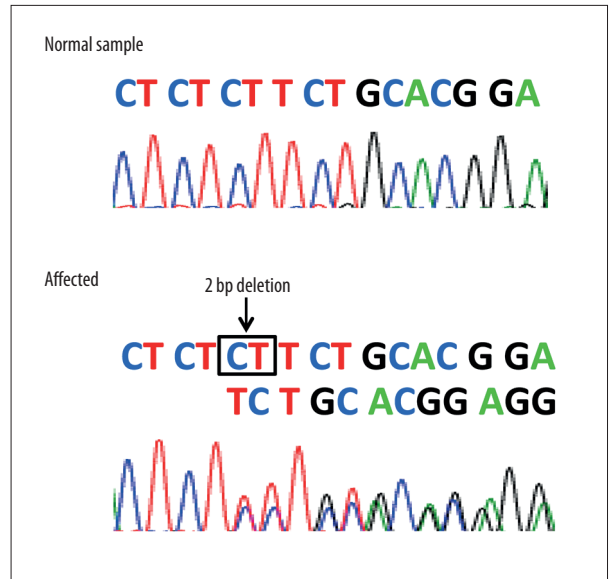


**Figure 3.** Thoracoscopic view shows the lung cyst in the right lower lobe.

Currently, there are few effective therapies for BHD syndrome of the lung; however, pleural covering combined with resection of cysts is expected to be a safe and effective therapy for BHD patients with intractable pneumothorax [22].

## References:

1. Birt AR, Hogg GR, Dube WJ: Hereditary multiple fibrofolliculomas with trichodiscomas and acrochordons. *Arch Dermatol*, 1977; 113: 1674-77
2. Schmidt LS, Nickerson ML, Warren MB et al: Germline BHD-mutation spectrum and phenotype analysis of a large cohort of families with Birt-Hogg-Dube syndrome. *Am J Hum Genet*, 2005; 76: 1023-33



**Figure 4.** The sequence analysis showed a deletion mutation (c.57\_58delCT) in exon 4 of the *FLCN* gene. The novel deletion mutation (c.57\_58delCT) caused a frame shift and changed the 20<sup>th</sup> amino acid: phenylalanine to leucine and the 16<sup>th</sup> reading frame from the leucine change to a premature stop codon (p.Phe20LeufsX16).

## Conclusions

Based on our observations, one should consider the possibility of BHD syndrome in patients with multiple lung cysts that present with discriminative findings on a CT scan of the lungs, as well as patients with familial pneumothorax. Patients suspected of BHD syndrome should be offered molecular analysis, which will not only verify the diagnosis but also inform recommendations for presymptomatic testing of at-risk family members [23].

## Acknowledgements

The authors thank M. Durbin (University of California, Irvine) for discussions.

## Conflict of interest

None of the authors has any conflict of interest directly relevant to the content of this article.

4. Shin JH, Shin YK, Ku JL et al: Mutations of the Birt-Hogg-Dube (BHD) gene in sporadic colorectal carcinomas and colorectal carcinoma cell lines with microsatellite instability. *J Med Genet*, 2003; 40: 364–67
5. Kahnoski K, Khoo SK, Nassif NT et al: Alterations of the Birt-Hogg-Dube gene (BHD) in sporadic colorectal tumours. *J Med Genet*, 2003; 40: 511–15
6. Nickerson ML, Warren MB, Toro JR et al: Mutations in a novel gene lead to kidney tumors, lung wall defects, and benign tumors of the hair follicle in patients with the Birt-Hogg-Dube syndrome. *Cancer Cell*, 2002; 2: 157–64
7. Ishii H, Oka H, Amemiya Y et al: A Japanese family with multiple lung cysts and recurrent pneumothorax: A possibility of Birt-Hogg-Dube syndrome. *Intern Med*, 2009; 48: 1413–17
8. Kim J, Yoo JH, Kang DY et al: Novel in-frame deletion mutation in *FLCN* gene in a Korean family with recurrent primary spontaneous pneumothorax. *Gene*, 2012; 499: 339–42
9. Ding Y, Zhu C, Zou W et al: *FLCN* intragenic deletions in Chinese familial primary spontaneous pneumothorax. *Am J Med Genet A*, 2015; 167a: 1125–33
10. Tomassetti S, Carloni A, Chilosi M et al: Pulmonary features of Birt-Hogg-Dube syndrome: Cystic lesions and pulmonary histiocytoma. *Respir Med*, 2011; 105: 768–74
11. Baba M, Hong SB, Sharma N et al: Folliculin encoded by the BHD gene interacts with a binding protein, FNIP1, and AMPK, and is involved in AMPK and mTOR signaling. *Proc Natl Acad Sci USA*, 2006; 103: 15552–57
12. Hudon V, Sabourin S, Dydensborg AB et al: Renal tumour suppressor function of the Birt-Hogg-Dube syndrome gene product folliculin. *J Med Genet*, 2010; 47: 182–89
13. Painter JN, Tapanainen H, Somer M et al: A 4-bp deletion in the Birt-Hogg-Dube gene (*FLCN*) causes dominantly inherited spontaneous pneumothorax. *Am J Hum Genet*, 2005; 76: 522–27
14. Bessis D, Giraud S, Richard S: A novel familial germline mutation in the initiator codon of the BHD gene in a patient with Birt-Hogg-Dube syndrome. *Br J Dermatol*, 2006; 155: 1067–69
15. Toro JR, Pautler SE, Stewart L et al: Lung cysts, spontaneous pneumothorax, and genetic associations in 89 families with Birt-Hogg-Dube syndrome. *Am J Respir Crit Care Med*, 2007; 175: 1044–53
16. Grant LA, Babar J, Griffin N: Cysts, cavities, and honeycombing in multisystem disorders: Differential diagnosis and findings on thin-section CT. *Clin Radiol*, 2009; 64: 439–48
17. Gunji Y, Akiyoshi T, Sato T et al: Mutations of the Birt Hogg Dube gene in patients with multiple lung cysts and recurrent pneumothorax. *J Med Genet*, 2007; 44: 588–93
18. Tobino K, Gunji Y, Kurihara M et al: Characteristics of pulmonary cysts in Birt-Hogg-Dube syndrome: Thin-section CT findings of the chest in 12 patients. *Eur J Radiol*, 2011; 77: 403–9
19. Hayashi M, Takayanagi N, Ishiguro T et al: Birt-Hogg-Dube syndrome with multiple cysts and recurrent pneumothorax: pathological findings. *Intern Med*, 2010; 49: 2137–42
20. Raouf S, Bondalapati P, Vidyula R et al: Cystic lung diseases: Algorithmic approach. *Chest*, 2016 [Epub ahead of print]
21. Hu X, Cowl CT, Baqir M, Ryu JH: Air travel and pneumothorax. *Chest*, 2014; 145: 688–94
22. Okada A, Hirono T, Watanabe T et al: Partial pleural covering for intractable pneumothorax in patients with Birt-Hogg-Dube Syndrome. *Clin Respir J*, 2015 [Epub ahead of print]
23. Menko FH, van Steensel MA, Giraud S et al: Birt-Hogg-Dube syndrome: Diagnosis and management. *Lancet Oncol*, 2009; 10: 1199–206