

CASE REPORT

Bone marrow sarcoidosis associated with long-term interferon- β treatment for multiple sclerosis

Angela Teh¹, Patrick Russell¹, Jordan Li² & Udul Hewage²

¹Department of General Medicine, Royal Adelaide Hospital, Adelaide, South Australia, Australia

²Department of General Medicine, Flinders Medical Centre, Bedford Park, South Australia, Australia

Correspondence

Angela Teh, Department of General Medicine, Royal Adelaide Hospital, North Terrace, Adelaide 5000, SA, Australia.
Tel: +61 8 8222 5213;
Fax: +61 8 8222 0722;
E-mail: angela.teh@sa.gov.au

Funding Information

No sources of funding were declared for this study.

Received: 10 March 2016; Revised: 24 April 2016; Accepted: 6 July 2016

Clinical Case Reports 2016; 4(11): 1038–1040

doi: 10.1002/ccr3.701

Introduction

Sarcoidosis is a rare condition with a prevalence of 4.4–6.3 patients per 100,000 person-years in Australia, a figure similar to that of the United State [1, 2]. It is a multisystem granulomatous disorder of unknown etiology predominantly affecting young and middle-aged adults [3, 4]. Diagnostic criteria are based on a compatible clinical and radiological features supported by the histological evidence of noncaseating granulomas in the affected tissues, and the exclusion of other known causes of granulomatous inflammation [3, 4]. Pulmonary infiltration and hilar lymphadenopathy are the most common findings in more than 90% of cases, and transbronchial lung biopsy has been the recommended diagnostic procedure [3, 4]. Other organs' involvement includes skin, eyes, liver, spleen, heart, musculoskeletal system, gastrointestinal tract, bone marrow, and the central nervous system. Anemia has been reported in cases of sarcoidosis with the frequency ranging from 3.4% to 31% with a variety of explanations. These include hypersplenism, burden of chronic disease, autoimmunity, and bone marrow infiltration [5]. Histological evaluation of extrapulmonary sarcoidosis depends

Key Clinical Message

Sarcoidosis is a diagnosis that should be considered in patients receiving interferon therapy, who present with anemia and multiorgan dysfunction regardless of the duration of their treatment. When sarcoidosis is suspected, bone marrow biopsy should be considered especially for cases predominant by extrapulmonary features.

Keywords

Anemia, bone marrow, granuloma, interferon, sarcoidosis.

on the site of involvement, but its diagnosis is rarely made via bone marrow biopsy [6]. Features which may suggest bone marrow infiltration in sarcoidosis include extrapulmonary involvement and varying degree of cytopenia [7]. The characteristic granuloma in sarcoidosis is a noncaseating focal aggregation of macrophages or epithelioid cells, with or without multinucleated giant cells. Asteroid bodies are crisscrossing bundles of collagen fibers sometimes found within the giant cells. Its presence confirmed the diagnosis of a non-necrotizing granuloma, in particular sarcoidosis [8, 9].

Case Presentation

A 40-year-old Caucasian woman presented with a three-month history of polyuria, malaise, and weight loss. She had been receiving interferon (IFN) β -1 α for multiple sclerosis for the previous 12 years. Pertinent examination findings were conjunctival pallor and splenomegaly. Investigations revealed moderate normocytic anemia, hypercalcemia, hyperglobulinemia, and acute kidney injury (Table 1). B-cell monoclonality was not evident on myeloma screen. Her initial chest radiograph was normal, but

Table 1. Summary of laboratory investigation results.

| Tests [SI units] | Results | Reference interval |
|--------------------------------------|-------------|--------------------------------|
| Hemoglobin [g/L] | 86 | 115–155 |
| MCV [fL] | 83 | 80.0–98.0 |
| White cell count [$\times 10^9/L$] | 7.70 | 4.00–11.0 |
| Platelets [$\times 10^9/L$] | 384 | 150–450 |
| Creatinine [$\mu\text{mol/L}$] | 241 | 50–100 |
| eGFR [mL/min/1.37 m ²] | 21 | >60 mL/min/1.37 m ² |
| Calcium [mmol/L] | 3.60 | 2.10–2.55 |
| Ionized calcium [mmol/L] | 1.84 | 1.10–1.30 |
| Phosphate [mmol/L] | 1.41 | 0.65–1.45 |
| Total protein [g/L] | 88 | 65–85 |
| Albumin [g/L] | 35 | 34–48 |
| Globulin [g/L] | 42 | 21–41 |
| Paraprotein [g/L] | 0 | 0 |
| K/L ratio | 1.11 | 0.26–1.65 |
| PTH [pmol/L] | 1.1 | 0.8–5.5 |
| ACE [U/L] | 69 | 8–52 |
| 1,25-dihydroxyvitamin D [pmol/L] | 344 | 50–160 |
| 25-hydroxyvitamin D [nmol/L] | 61 | 60–160 |
| Urine calcium [mmol/24 h] | 9.0 | 2.5–7.5 |

eGFR, estimated glomerular filtration rate; PTH, parathyroid hormone; K/L, Kappa/Lambda light chain; ACE, angiotensin converting enzyme; SI, Système International. Bold = values not within normal range.

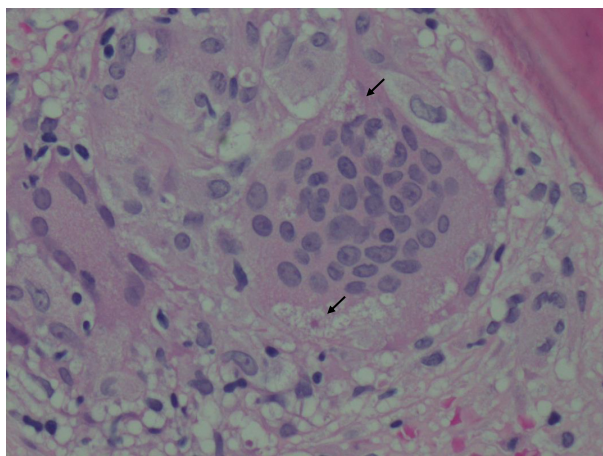


Figure 1. Histopathological section of a trephine bone marrow biopsy revealing a noncaseating granuloma composed of aggregation of multinucleated giant cells containing asteroid bodies (arrowed). Hematoxylin and eosin stain (x40).

further investigation with computed tomography showed diffuse lymphadenopathy in her chest and abdomen. There was also splenomegaly with hypodense lesions. Skeletal survey was normal. A bone marrow trephine biopsy demonstrated noncaseating granulomas (Figs 1 and 2) and asteroid bodies (black arrows in Fig. 1), confirming the diagnosis of sarcoidosis. Ziehl-Neelsen staining did not reveal acid fast bacilli. She received intravenous normal saline therapy for her hypercalcemia. Her IFN- β treatment

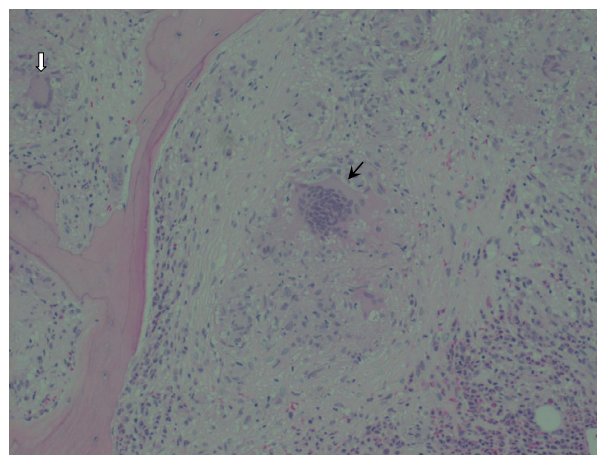


Figure 2. The noncaseating granuloma in the center (black arrow) is surrounded by pale pink amorphous material with scattered mononuclear cells interspersed throughout with some giant cells. There is also a surrounding cuff composed of reactive cells such as eosinophils and neutrophils. A second granuloma is visible in the periphery containing a Langhans giant cell (white arrow). Hematoxylin and eosin stain (x20).

was discontinued, and she was commenced on prednisolone (60 mg daily) with a slow tapering regimen over 6 months. Her renal function and hypercalcemia recovered promptly, and her hemoglobin normalized at 12th week. Her overall well-being improved.

Discussion

The exact etiology of sarcoidosis remains unknown. A cardinal feature of sarcoidosis is the presence of CD4⁺ T cells which display unregulated interaction with the antigen-presenting cells to initiate the formation and maintenance of noncaseating granulomas [10]. Oligoclonal $\alpha\beta$ T-cell repertoire observed in sarcoidosis suggests that the triggering antigens favor the progressive accumulation and activation of selective CD4 T-cell clones [11]. This in turn leads to the preferential differentiation of the Th1 helper cells which predominantly secretes interleukins (IL)-2 and IL-12 [12]. These ILs have been found in higher quantity in the bronchoalveolar lavage fluid of patients with sarcoidosis and subsequently stimulate increased production of IFN- γ and macrophage activation. IFN- γ belongs to type II IFN family. It has a different structure and binds to a different receptor than the type I IFN (α and β), and its gene is located on a different chromosome [12]. Although endogenous IFN- γ has been implicated in the pathogenesis of sarcoidosis, there is little evidence for other types of IFNs [11]. However, exogenously administered IFN- α and IFN- β activate macrophages in vitro [10].

The incidence of sarcoidosis is increasing with the use of type I IFN (IFN- α , IFN- β) for various conditions such

as hepatitis B, hepatitis C, lymphoproliferative malignancy, and multiple sclerosis [13–15]. To date, 60 cases of sarcoidosis have been reported in the English literature in association with the use of IFN- α , in comparison with only six cases which were associated with the use of IFN- β [13–20]. The characteristic of these six cases revealed a predilection for middle age women. The mean onset of development of sarcoidosis was 11.4 months after initiation of IFN therapy (ranged 1–60 months), which is much earlier than our patient [13]. The pattern of system involvement is similar to that of the idiopathic form of sarcoidosis. Only one case of the six is proven to have bone marrow involvement with a bone marrow biopsy [16]. IFN-induced sarcoidosis exhibits a relatively mild disease course that usually resolves with cessation of IFN treatment. A small proportion of patients required systemic corticosteroid [13–20].

Conclusion

Sarcoidosis is a disease with vast clinical heterogeneity. It is a diagnosis that should be considered in patients receiving IFN therapy of any type who present with anaemia and multiorgan dysfunction. The overall pattern of organs' involvement in sarcoidosis associated with IFN is similar to that of the idiopathic form. Bone marrow biopsy should be considered for cases predominant by extrapulmonary features.

Acknowledgment

We thank Dr J P Boey (Advanced Trainee, Haematology Department of Flinders Medical Centre) who provided the histology specimen for this publication.

Conflict of Interest

None declared.

References

- Gillman, A., and C. Steinfert. 2007. Sarcoidosis in Australia. *Intern. Med. J.* 37:356–359.
- Henke, C. E., G. Henke, L. R. Elveback, C. M. Beard, and D. Ballard. 1986. The epidemiology of sarcoidosis in Rochester Minnesota: a population-based study of incidence and survival. *Am. J. Epidemiol.* 123:840–845.
- Joint statement of the American Thoracic Society. 1999. European Respiratory Society and World Association of Sarcoidosis and other Granulomatous Disorders. Statement on sarcoidosis. *Am. J. Respir. Crit. Care Med.* 160:736–755.
- Iannuzzi, M., B. Rybicki, and A. Teirstein. 2007. Medical progress: sarcoidosis. *N. Engl. J. Med.* 357:2153–2165.
- Johns, C. J., and T. M. Michele. 1999. The clinical management of sarcoidosis. A 50-year experience at Johns Hopkins Hospital. *Medicine* 78:65–111.
- Eskenasy, A. 1987. Histodiagnosis of pulmonary sarcoidosis on different organ biopsies. *Morphol. Embryol.* 33:111–121.
- Yanardağ, H., G. E. Pamuk, and T. Karayel. 2002. Bone marrow involvement in sarcoidosis: an analysis of 50 bone marrow samples. *Haematologia* 32:419–425.
- Azar, H. A., and C. Lunardelli. 1969. Collagen nature of asteroid bodies of giant cells in sarcoidosis. *Am. J. Pathol.* 57:81.
- Gadde, P. S., and E. A. Moscovic. 1994. Asteroid bodies: products of unusual microtubule dynamics in monocyte-derived giant cells. An immunohistochemical study. *Histol. Histopathol.* 9:633–642.
- Agostini, C., L. Trentin, and A. Perin. 1999. Regulation of alveolar macrophage-T cell interactions during Th1-type sarcoid inflammatory process. *Am. J. Physiol.* 277:L240–L250.
- Silver, R., R. Crystal, and D. Moller. 1996. Limited heterogeneity of biased T-cell receptor V beta gene usage in lung but not blood T cells in active pulmonary sarcoidosis. *Immunology* 88:516–523.
- Shigehara, K., N. Shijubo, M. Ohmichi, and R. Takahashi. 2001. IL-12 and IL-18 are increased and stimulate IFN-gamma production in sarcoid lungs. *J. Immunol.* 166:642–649.
- Goldberg, H., D. Fiedler, and A. Webb. 2006. Sarcoidosis after treatment with interferon-alpha: a case series and review of the literature. *Respir. Med.* 100:2063–2068.
- Kikawada, W., Y. Ichinose, and A. Kunisawa. 1998. Sarcoidosis induced by interferon therapy for chronic myelogenous leukaemia. *Respiratory* 3:41–44.
- Chakravarty, S., A. Schreiner, and M. Crow. 2012. Sarcoidosis triggered by interferon-beta treatment of multiple sclerosis: a case report and focused literature review. *Semin. Arthritis Rheum.* 42:206–212.
- Bobbio-Pallavicini, E., C. Valsecchi, F. Tacconi, and M. Moroni. 1995. Sarcoidosis following beta-interferon therapy for multiple myeloma. *Sarcoidosis* 12:140–142.
- Mehta, C., R. Tyler, and D. Cripps. 1998. Granulomatous dermatitis with focal sarcoïdal features associated with recombinant interferon beta-1b injections. *J. Am. Acad. Dermatol.* 39:1024–1028.
- O'Reilly, S., A. White, and A. Florian. 2005. Mediastinal sarcoidosis in a patient receiving interferon-beta for multiple sclerosis. *Chest* 128:450S–a451S.
- Petousi, N., and E. Thomas. 2012. Interferon- β -induced pulmonary sarcoidosis in a 30-year-old woman treated for multiple sclerosis. *J. Med. Case Rep.* 6:344–347.
- Abdi, E., G. Nguyen, and R. Ludwig. 1987. Pulmonary sarcoidosis following interferon therapy for advanced renal cell carcinoma. *Cancer* 59:896–900.