

## CHOROIDEREMIA\*

BY

J. K. PAMEYER, P. J. WAARDENBURG, AND H. E. HENKES

*Deventer, Arnhem, and Rotterdam, The Netherlands*

CHOROIDEREMIA is a rare clinical entity. The name, which implies a congenital absence of the choroid, is not very well chosen, as the choroid is not absent at birth. The condition is progressive in males and leads to blindness. In the females of the family, who transmit the condition, fundus changes appear but do not lead to blindness or cause major functional disturbances.

It was first described by Mauthner (1871) and in the Netherlands by Goedbloed (1942), who identified it in a male patient aged 38 years whose mother and sister showed fundus alterations of the pepper-and-salt type. Goedbloed assumed an intermediate X-chromosomal transmission, and Waardenburg (1942), after an extensive study of the existing literature, came to the same conclusion.

Goedbloed observed that choroideremia was a separate clinical entity, and that there was no question of its being an extreme form of either atropia retinae pigmentosa or atrophica gyrata retinae et choroideae. Duke-Elder (1938) included choroideremia under the congenital developmental anomalies, assuming that it was not only congenital but also stationary, and advancing three possible explanations of the abnormality. Verhoeff (1947) maintained that the anomaly was due merely to the abnormal growth of a gliosis covering the choroid and pigment epithelium. Mann (1957) referred to it as a developmental disturbance and gave a somewhat mistaken description of the clinical picture. Mann suggested that the condition was due either to a failure of the ciliary arteries to bud out from the ophthalmic artery, or to a failure of the optic cup to produce pigment with a consequent absence of capillary outgrowth even if the arteries began to develop. Mann quoted the genealogy reported by McCulloch and McCulloch (1948), with the remark that the clinical picture was not yet clearly understood.

---

\* Received for publication September 11, 1959.

Present Investigations

In 1957, a 7-year-old boy was brought for examination to one of us (J.K.P.) because of deteriorating vision. At that time, the visual acuity was about 3/4 for both eyes, with correction -2 D cyl., axis 10° in the right eye, and -2 D cyl., axis 160° in the left eye. The anterior segment and the media were normal. The discs were somewhat pale and the retinal vessels normal. Around the optic discs some atrophy was present. The macular region seemed to be normal. At some distance from the central area another atrophic region was observed extending to the periphery; there was a pepper-and-salt appearance with all sorts of pigment shifts in the form of garlands and freakish shapes.

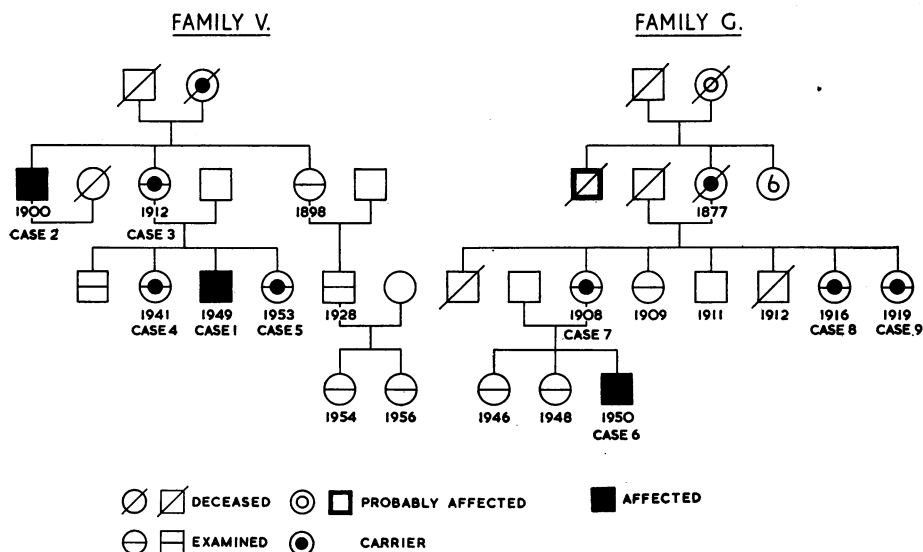
The mother said that the boy had not complained, but that she had noticed that he would take her arm when it began to grow dark. When he entered the dark room it was obvious that he had difficulty in finding his way.

A paediatrician reported that the boy was in good health, with no signs of congenital syphilis, and that blood tests were negative.

The diagnosis became obvious when the mother mentioned that her brother had poor sight. This patient (Case 2) proved to have been under observation for many years, and showed the typical picture of advanced choroideremia.

A detailed study of the two affected members of this family (Family V: see Pedigree Chart) as well as of three female carriers, was undertaken in 1958.

Another family (Family G: see Pedigree Chart) was brought to our notice in 1958 by Prof. J. ten Doesschate of Utrecht. A boy aged 6 was affected, and his mother and two aunts were found to be carriers.



## Case Reports

## FAMILY V

**Case 1, a boy born in 1949**, showed an early stage of choroideremia (Fig. 1, opposite).

*Visual Acuity*

Right Eye (with correction  $-1.75$  D sph.,  $-0.75$  D cyl., axis  $0^\circ$ ): 7/10.

Left Eye (with correction  $-0.75$  D sph.,  $-1$  D cyl., axis  $0^\circ$ ): 5/10.

*Examination.*—The anterior segment and media were normal, with no translucency of the iris. Discs pale but not wax-like, retinal vessels of very fair quality, zone of choroidal atrophy visible around the optic nerve. In the retina the macular region appeared to be more or less normal, though with very fine pigmentation; at the equator and already to some extent more centrally, there seemed to be large retinal "holes", where a pronounced atrophy of the choroid in the form of thinning and disappearance of the choroidal vessels was clearly visible. The meshes between the holes were brownish in colour and formed freakish shapes containing pigmentations. With the slit lamp and fundus contact glass, as well as with the binocular ophthalmoscope, it was seen that the pigmentations lay in the deepest layers of the retina and that no migration of pigment to the superficial layers had taken place. The retinal vessels crossed the meshes, climbing in and out of the "holes" of thinning chorio-retina, where the migration of the deeplying pigment epithelium was well under way but remained in the same layer. Here and there the choroidal vessels showed a narrowing of the blood column, with an apparent relative thickening of the vessel wall and farther on a partial or total dissolution of the vessel.

**Case 2, a man born in 1900**, the maternal uncle of Case 1, had suffered for years from advanced choroideremia.

*Visual Acuity*

Right Eye (with correction  $-6$  D sph.,  $-0.5$  D cyl., axis  $90^\circ$ ): 1/6.

Left Eye: Hand movements at 1 metre.

*Examination.*—Retinoscopy revealed a myopia of 3 D. The anterior segment was normal, and the iris not translucent. There was bilateral optic atrophy and a narrowing of the retinal vessels. Paracentrally in both eyes was a small area of a few degrees of normal retina, and corresponding to it a few choroidal vessels. Most of the choroidal vessels had disappeared, leaving the well-known appearance of the naked sclera.

**Case 3, a woman born in 1912**, mother of Case 1, had apparently normal vision, but there were certain fundus changes (Fig. 2, opposite).

*Visual Acuity*

Right Eye (with correction  $-0.5$  D cyl., axis  $120^\circ$ ): 10/10.

Left Eye: 10/10.

*Examination.*—The anterior segment was normal, with no translucency of the iris. The discs were somewhat pale, showing the same peripapillary atrophy of the choroid as Case 1. The retinal vessels were normal and the macular region more or less normal, but paracentrally and increasing towards the equator atypical garland-like pigmentations gave the fundus an extremely untidy aspect. Here and there the walls of the choroidal vessels seemed to be too clearly marked, and in some places a possible absence of the blood column and even occasionally a complete disappearance of the vessel was observed.



FIG. 1.—Early stage of choroideremia in a boy aged 8 (Case 1).

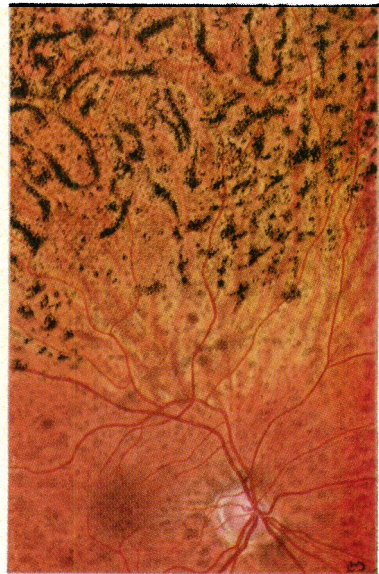


FIG. 2.—Female carrier of choroideremia (Case 3, mother of Case 1).

**Case 4, a young woman born in 1941**, the elder sister of Case 1, was also a carrier.

*Visual Acuity*

Right Eye (with correction — 1 D sph.): 11/10.

Left Eye (with correction —0·5 D sph., 0·5 D cyl., axis 15°): 11/10.

*Examination.*—The anterior segment was normal, with no translucency of the iris. There was some temporal atrophy of the optic discs, normal retinal vessels, and no alterations in the central area of the retina. More peripherally, especially at the equator, the same atypical pigmentations as those in Case 3 were visible. The Goldmann contact glass showed that these abnormal pigmentations occurred in the deepest layers of the retina and did not tend to come to the surface. The retina was of normal thickness. At the periphery of the fundus, the choroidal vessels again seemed to be pronounced, with a tendency to narrowing of the blood column.

**Case 5, a girl born in 1953**, the younger sister of Case 1, was already beginning to show signs of the carrier condition.

*Visual Acuity:* Both Eyes: 10/10.

*Examination.*—The anterior segment was normal. There were no abnormalities of the optic discs or retinal vessels. The macular area was normal, but towards the periphery the same granular, even garland-like, pigmentations were seen.

## FAMILY G

In this family, the diagnosis of choroideremia was more difficult because there were no older men showing the affection in a more advanced stage, but fundus changes were observed in the mother and two maternal aunts of the propositus.

**Case 6, a boy born in 1950**, was referred to one of us (H.E.H.) for diagnosis by electroretinography (atypical tapeto-retinal degeneration?) from the Utrecht University Eye Clinic. He had been complaining of night blindness and deteriorating vision for one year.

*Visual Acuity:* Both Eyes (with correction —2 D sph., —1·4 D cyl., axis 90°): 8/10.

*Examination.*—The anterior segment was normal. The fundus picture resembled that in Case 1, although the peripapillary atrophy was lacking. The macular region showed the same pigmentary mottling, and peripherally a “meshwork” consisting of areas of normal, though pigmented, retina with “holes” of atrophied choroid and retina between them was seen. Pigment migration was found only in the deepest layers of the retina. At the periphery the meshes were less marked and the picture became chaotic. The periphery was abnormal, in contrast to the gyrate atrophy of the chorio-retina.

**Case 7, a woman born in 1908**, mother of case 6.

*Visual Acuity:* Both Eyes (with correction —2 D sph.): 11/10.

*Examination.*—The anterior segment was normal. The same “meshwork” as that observed in Case 6 was seen in the periphery of the fundus with some pigment dispersion in the deepest layers of the retina, which showed no tendency to migrate into the superficial layers. In some places some of the choroidal vessels seemed to have disappeared.

### Visual Functions in Patients and Carriers

In the three affected males and four female carriers described above, the following data were recorded: visual fields (Goldmann perimeter), rate of dark adaptation (Goldmann-Weekers adaptometer), central colour vision (Ishihara, HRR-test, D-15 panel, and anomaloscope), and electroretinogram (single flash and flickering light stimuli). The technique of recording has been described in a previous publication (Henkes, 1958). The findings are summarized in the Table.

TABLE  
VISUAL FUNCTIONS IN PATIENTS AND CARRIERS

Sex	Case No.	Age (yrs) in 1958	Visual Acuity (with correction)		Visual Functions Investigated			
			Right	Left	Visual Fields	Dark Adaptation	Colour Vision	Electroretinogram
Male	2	58	1/6	1/300	Island of 5-10° located paracentrally	Not demonstrable	Impossible to determine	Right: Absent responses Left: Only rudimentary photopic responses
	1	8	7/10	5/10	Generally restricted Central sensitivity relatively intact Enlargement of blind spot	Considerable impairment, rods more than cones	Normal	Rod activity extinguished Cones practically intact left eye, but slightly affected right eye
	6	8	8/10	8/10	Generally restricted Central sensitivity relatively intact Some enlargement of blind spot of left eye	As Case 1	Protan-defect with D-15 panel Normal with anomaloscope	Rod activity extinguished Cone activity impaired
Female	3	46	10/10	10/10	Some enlargement of blind spot, otherwise normal	Rate of adaptation of cones and rods retarded?	Normal	Scotopic activity impaired Photopic activity practically normal
	4	17	11/10	11/10	Some enlargement of blind spot otherwise normal	Rate of adaptation of cones and rods slightly retarded?	Normal	Scotopic activity right eye probably diminished Photopic activity normal
	5	5	10/10	10/10	Normal	Normal? (not fully reliable)	Normal	Scotopic activity probably within normal limits Photopic activity normal
	7	50	11/10	11/10	Possible slight enlargement of blind spot left eye, otherwise normal	As Case 4	Normal	Scotopic activity left eye probably diminished Photopic activity normal

### Visual Fields

*Patients.*—A survey of visual field data in patients and carriers was published by François, Verriest, and De Rouck (1956). An annular scotoma, found in two patients showing an early stage of disease, is mentioned by Sorsby, Franceschetti, Joseph, and Davey (1952). In most of these cases the visual field was limited to a

central area of 5 to 10°. In our Case 2 this extreme limitation was found, but in Cases 1 and 6 the reduction in retinal sensitivity was not yet very marked, and an annular scotoma could not be demonstrated (Fig. 3, Cases 1, 2, 6).

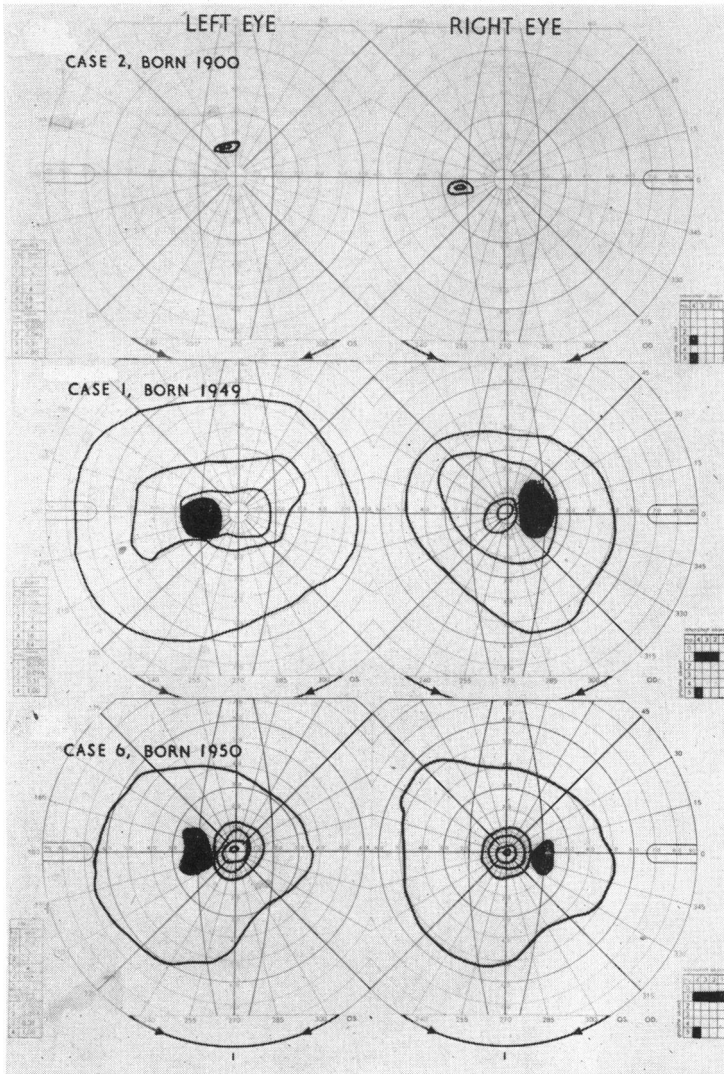


FIG. 3.—Visual fields of three male patients suffering from choroideremia. Advanced stage (Case 2). Early stage (Cases 1 and 6).

*Carriers.*—Alterations in the visual fields in carriers have not been described except by Schutzbach (1938). In our four carriers the isopters were normal, but we found in some cases an enlargement of the blind spot corresponding with alterations in the retina and choroid (Fig. 4, Cases 3, 4, 5, 7, overleaf).

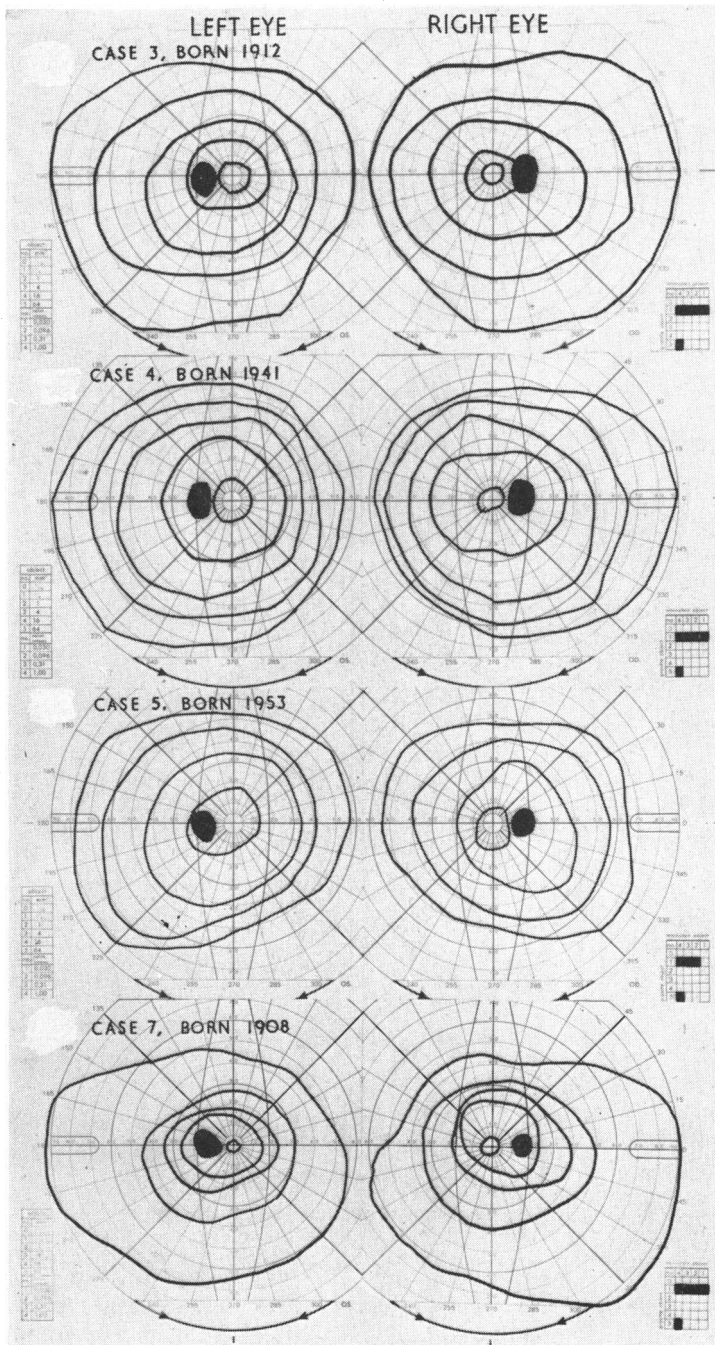


FIG. 4.—Visual fields of four female carriers of choroideremia (Cases 3, 4, 5, 7). Some show a slight enlargement of the blind spot.



### Dark Adaptation

*Patients.*—Night blindness has been noted in every recorded case as a prominent symptom, but dark-adaptation curves could not be plotted in most of the cases described owing to the advanced stage of the disease. This was so in our Case 2, but in Cases 1 and 6 the curves revealed a serious impairment of the photopic and scotopic adaptation (Fig. 5, Cases 1 and 6).

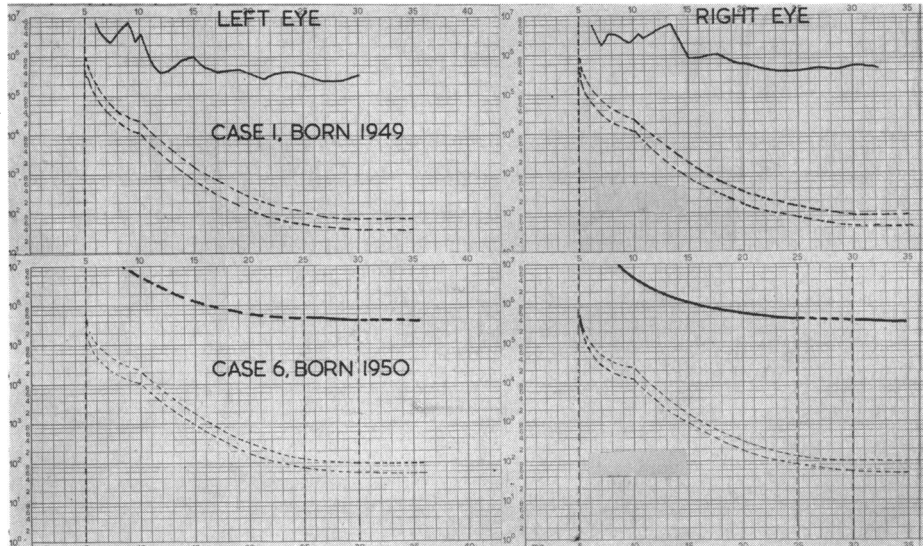


FIG. 5.—Dark-adaptation curves for left and right eyes of the two younger patients (Cases 1 and 6). The curves for Case 2 could not be plotted.

*Carriers.*—Abnormalities in the dark-adaptation curves in carriers have not been noted, except that Schutzbach (1938) and Sorsby and others (1952) described impaired scotopic adaptation. Sorsby and others mentioned that one of their carriers was pregnant and that in another the adaptation was measured with the Della Casa adaptometer, which is an unreliable instrument for scientific purposes. The examination of our four carriers indicates a slight decrease in the sensitivity of the scotopic retinal system (Fig. 6, Cases 3, 4, 5, 7, overleaf).

**Colour Vision.**—Tests with the pseudo-isochromatic plates (Ishihara, and AO.HRR test) and with the anomaloscope showed that colour vision in Case 1 and in the four carriers was intact. In Case 6 a protan defect could be detected by the Farnsworth dichotomous test (D-15 panel) but the anomaloscope gave a normal reading. In Case 2 we were unable to test colour vision.

### Electroretinography

*Patients.*—Bounds and Johnston (1955) and von Burstin (1958) were unable to record a response from the retinae of their patients, and François and others (1956) noted a negative response to the Xenon-light flash. In all these cases the disease was far advanced, leaving a central visual field of only a few degrees. Our

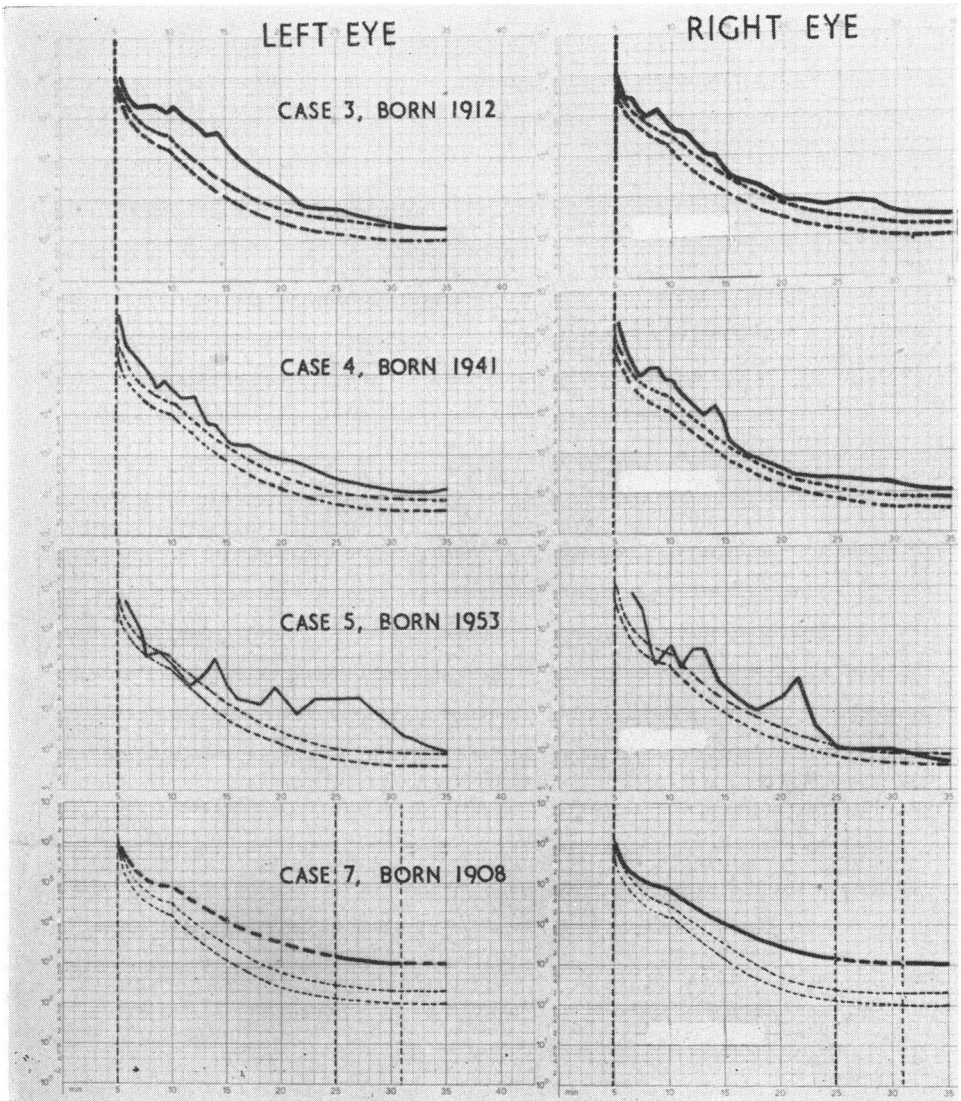


FIG. 6.—Dark-adaptation curves for left and right eyes of four carriers of choroideremia (Cases 3, 4, 5, 7). The rate of adaptation of the cone and rod systems is probably slightly retarded in some of the carriers. For Case 7 only the scotopic level after 25–30 min. is given for the left eye and 5–25 min. and 30–35 min. for the right eye.

findings in Case 2 were similar with the single flash electroretinogram, using the conventional amplification of 500 microvolts/cm. However, by selective amplification of the flicker electroretinogram a rudimentary photopic response could be demonstrated (Fig. 7B, C, D, opposite).

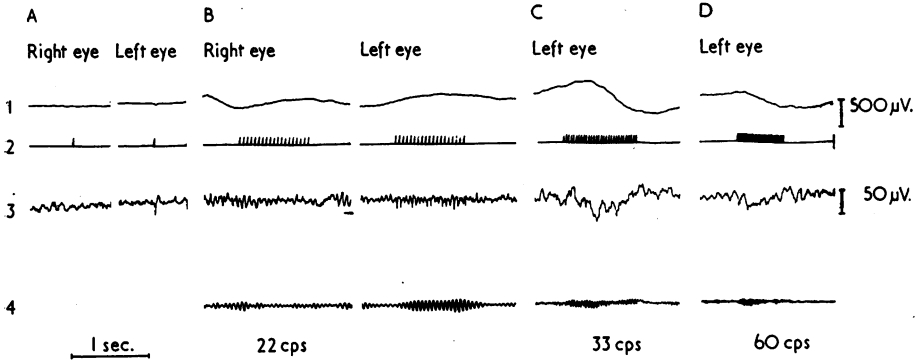


FIG. 7.—Electrorretinogram in an advanced case of choroideremia (Case 2) of Family V.  
 Channel 1: "Conventional" amplification (500 microvolts/cm.).  
 Channel 2: Stimulus recording. Relative intensity: 5,000.  
 Channel 3: Amplified electroretinogram (50 microvolts/cm.). Time constant: 30 m.sec.  
 Channel 4: Resonance pen of selective amplifier.

- (A) Single flash electroretinogram. Absent response in right eye. Electronegative response (so-called isolated negativity) in left eye.
- (B) Flicker electroretinogram of left eye at 22 flashes per sec. Using conventional technique (Channel 1), responses seem to be absent, but amplified flicker electroretinogram (Channel 3) shows clear responses. Resonance pen demonstrates response even more clearly (Channel 4).
- (C) Flicker electroretinogram of left eye at 33 flashes per sec. Photopic responses demonstrable only with selective amplifier (Channel 4).
- (D) Flicker electroretinogram of left eye at 60 flashes per sec. Fusion is almost reached, judged by decreased response of selective amplifier.

In Cases 1 and 6 the photopic response was relatively intact, both to the single flash (Fig. 8) and the flicker electroretinogram (Figs 9 and 10, overleaf). Scotopic activity was absent in the two young patients, although the disease was still in its early stages.

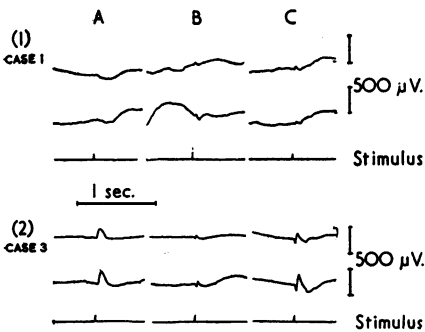


FIG. 8.—Comparison between single flash electroretinogram in Case 1 showing the disease in an early stage, and in a female carrier (Case 3), both of Family V.

- (A) Stimulus blue (Gevaert filter B 488). Dark adaptation.
  - (B) Stimulus red (Gevaert R 628). Continuous background illumination 20 lux.
  - (C) Stimulus white (Xenon). Relative intensity: 5,000. Dark adaptation.
- Scotopic Responses: Absent in choroideremic patient (1A); maximum *b*-potential 180 and 290 microvolts for right and left eye respectively in carrier (2A).
- Photopic Responses: Reduced in patient, after red light stimuli of 45 and 50 microvolts (1B); normal *a/x* potentials of 90 and 100 microvolts for right and left eye respectively in carrier (2B).

After white light stimuli only photopic activity can be demonstrated (*a/x* potentials 55 and 80 microvolts), in patient (1C), whereas carrier shows photo-scotopic responses of 180 and 290 microvolts in right and left eye respectively (2C).

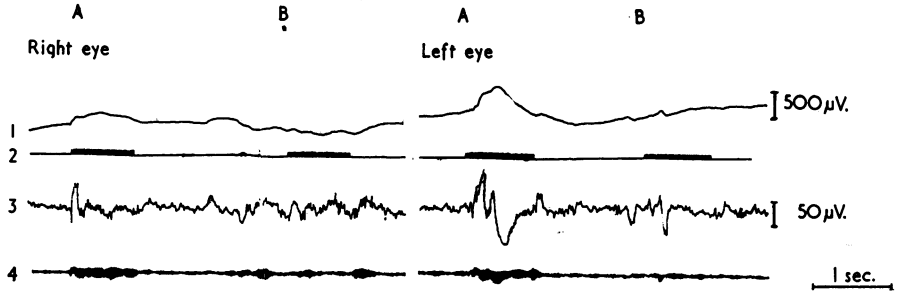


FIG. 9.—Flicker electroretinogram at 47 flashes per sec. in Case 1. Amplification and time constant as in Fig. 7. Relative intensities: 50 and 15 (Channel 2: A and B). Fusion reached for both eyes between 50 and 15, thus demonstrating a relatively intact photopic retinal system in both eyes, at least at the arbitrary frequency of 47 flashes per sec.

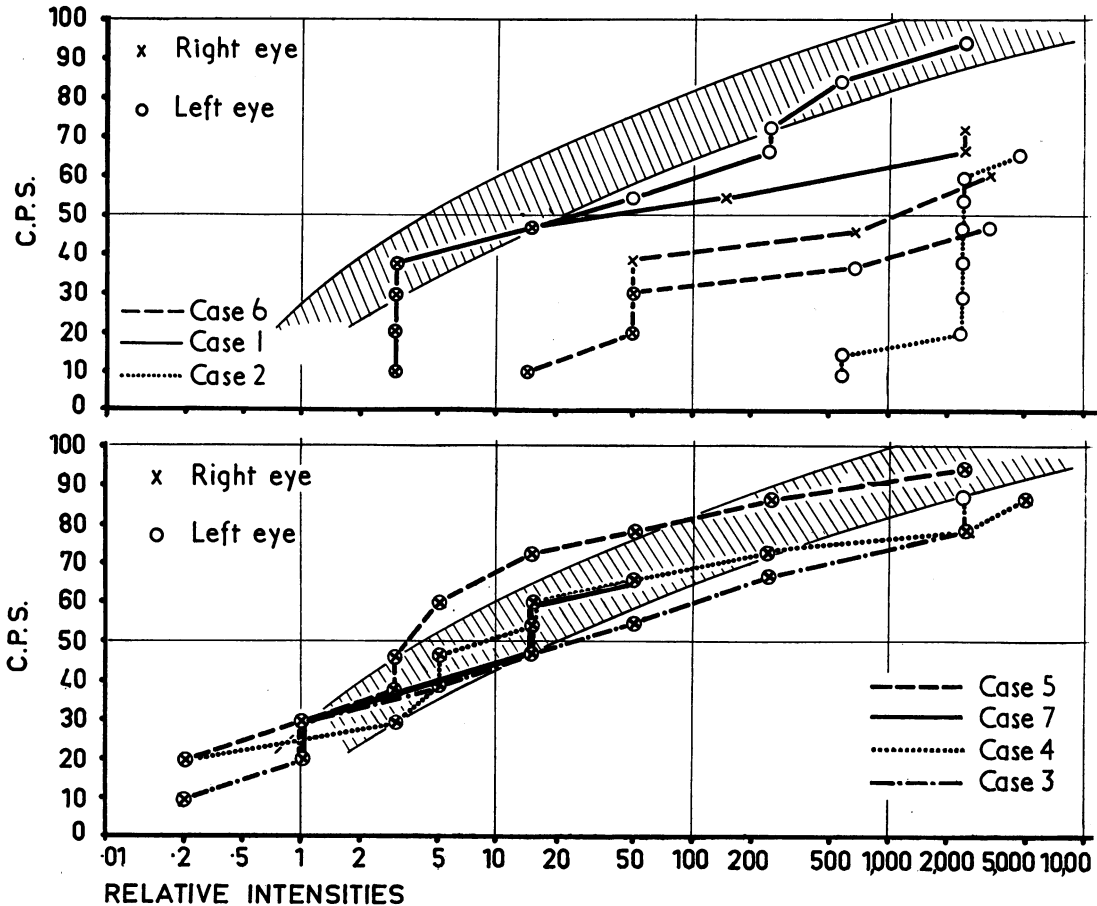


FIG. 10.—CFF-curves based upon flicker electroretinograms in three male choroideremic patients (Cases 1, 2, and 6) and four female carriers (Cases 3, 4, 5, 7).

Shaded band shows normal limits of CFF-curves. Only rudimentary photopic activity remains in left eye of Case 2, whereas in the youngest patient (Case 6) scotopic activity is absent and photopic activity markedly reduced in both eyes. In Case 1 scotopic activity is still fairly intact, showing only a reduced maximum CFF in the right eye with high intensity stimuli. In the carriers the photopic activity is normal.

*Carriers.*—No abnormality in the electrical response has been reported by previous authors, but our findings point to a possible slight dysfunction of the scotopic retinal system (Figs 8 and 10). Maximum *b*-potentials\* in the four carriers for the right and left eye respectively were:

180 and 225 microvolts, Case 3

180 and 290 microvolts, Case 5

210 and 145 microvolts, Case 7

The photopic responses were normal judged by the course of the CFF-curves (Fig. 10).

### Discussion

Our knowledge of choroideremia has been considerably advanced by the researches of McCulloch and McCulloch (1948), who investigated in 1948 a clan of 600 members, among whom they found 33 affected males and 53 female carriers. This investigation revealed the following facts:

- (1) The female carriers themselves show no symptoms, *i.e.* no visual field defects and no night blindness.
- (2) Among the men the affection is not stationary but progressive.
- (3) The onset probably occurs very early in life. Parents of affected children had noticed a defect in the vision of a baby which was probably due to the existing night blindness. The earliest case examined was that of a boy aged 22 months, who already showed definite fundus alterations (brilliant green areas associated with groups of pigment granules), but a detailed examination was impossible ("Only a fleeting glimpse was obtained of either fundus"). The youngest patient with symptoms was a boy aged 3, but the earliest cases which were fully examined were boys of about 6 years of age (McCulloch and McCulloch, 1948; Sorsby and others, 1952). The youngest carrier examined was a girl of 4½ months, in whom McCulloch found peripheral pigmentary alterations, associated, in his opinion, with the carrier state.
- (4) The mode of inheritance, as earlier deduced by Goedbloed (1942) and Waardenburg (1942), is intermediately X-chromosomal. This implies that only males will show the complete picture of choroideremia and that the sons of affected males will not show it at all, whereas all the daughters of affected males will be carriers and will show a modified form of the disease. Of the children of these carriers, 50 per cent. of the sons will be normal and 50 per cent. will show the disease, while 50 per cent. of the daughters will be normal and 50 per cent. will be carriers. A man who is not himself affected, or a girl who is not a carrier, cannot transmit the disease.

Since there are similarities in the fundi of patients in the early stages of the affection and those of carriers, and since the carriers differ from the patients

\* The normal values for females between the ages of 19 and 50 years vary, according to Karpe (Personal Communication) from 250 to 530 microvolts. Values lower than 210 microvolts are considered to be probably subnormal, and lower than 180 microvolts to be definitely subnormal.

in that besides the defective gene they have a normal gene, we thought it important to consider the following questions:

- (1) Where is the pigment defect of the carriers localized?
- (2) In what respects does the normal gene produce a different clinical picture in the carriers from that seen in the patients?
- (3) In what way does the clinical picture seen in patients and carriers differ from that seen in cases of the peripheral form of tapeto-retinal degeneration (dystrophia retinae pigmentosa)?

Fundoscopy, using Thorner's stereo-ophthalmoscope with red and red-free light, as well as the slit lamp with a contact glass, revealed the following condition in the two affected boys and in the carriers of the two families:

- (1) The irregular pigmentation spread over the area of the fovea centralis, though less intensely in the carriers than in the affected boys. In the periphery the alterations were coarser than at the posterior pole, where they showed a fine pigment mottling. In Case 3 (mother of Case 1) the macular yellow had decreased.
- (2) The pigment alterations were localized at the level of the tapetum.\* All the layers of the retina were free of pigment migration in both patients and carriers. In the latter the retina was of normal thickness. The ophthalmoscopic picture was entirely different from that of tapeto-retinal degeneration (dystrophia retinae pigmentosa). Large angular lumps of pigment were present, some of the cells appearing to have too much pigment and others too little; it is possible that the pigment epithelium consisted in some places of more than one layer of cells.
- (3) We were unable to identify a definite sclerosis of the choroidal vessels. In the affected boys the border zones between the fully-developed areas of atrophy in the choroid and those in which atrophy was incomplete showed vessels with a narrow blood column, while other vessels seemed to have disappeared completely. This does not agree with the histological findings of McCulloch and McCulloch in the four eyes of two older affected males. Their description harbours an inherent discrepancy when they write that the choroidal vessels were either sclerosed or absent. In our opinion it is inconceivable that true vessel sclerosis or hardening of the vessel wall should form a stage in the process of disappearance of the vessel. We prefer to assume that the muscle tissue of the vessel wall is temporarily replaced by connective tissue, which subsequently disappears. The degree to which the vessel walls are affected parallels the degree of change in the tapetum, and there appears to be a close connexion between the two.

In the carriers, the choroidal vessels may show only minor alterations. In some places, we saw a blood vessel that ended blindly and sharply. A few vessels may be absent, and in some we could see no blood column. Compared, however, to the distinct alterations in the tapetum, these slight irregularities in the choroid are insignificant.

---

\* By the word "tapetum" we mean "tapetum nigrum", a term used to connote the pigmented layer of the retina, first introduced by Leber (1916) in the term "tapeto-retinal degeneration" to embrace related progressive affections of the pigmented and other layers of the retina.

### Conclusions

From the fundus picture described above, the following conclusions regarding the aetiology of choroideremia may be drawn. The minor alterations in a few choroidal vessels in the carriers, compared with the striking disturbances in the pigment epithelium, prevent us from attributing a primary aetiological role to the choroid. The presence of the normal gene inhibits the progression of the pigmentary irregularities in the tapetum caused by the abnormal gene. These irregularities may, however, be responsible for the slight functional defects demonstrated in the carriers. It is not impossible that in some places rods or cones may disappear; in the circumpapillary area both the tapetum and the neuro-epithelium may possibly disappear in the end. From the available material (McCulloch and McCulloch, 1948; Sorsby and others, 1952), it appears that continuous progression in carriers is highly improbable: in the same family, fundus alterations were found in the young girls that appeared more serious than some of those found in the older women, and even when they were older these female carriers had no spontaneous complaints. There are undoubtedly differences among the carriers, partly attributable to their general constitution. However, we feel justified in assuming that, generally speaking, the normal gene checks the progression of the disease process. The comparatively intact condition of the tapetum explains the normal condition of the choroid in the carriers. An incidental slight progression can be detected only by re-examination at regular intervals.

Affected males, however, in whom the normal allele is missing, start with a fundus picture closely resembling that of the carriers, but this gradually changes, as the affection of the tapetum is always progressive and is associated with progressive dystrophy of the choroid, which will obviously contribute to a progressive dystrophy of the outer retinal layers.

We would not venture to claim that the progressive dystrophy of the choriocapillaris is the result of the abnormality of the tapetum, but we can exclude the possibility that it is the cause of this abnormality. At the most there may be a correlation, or even an interrelation, between the alterations in the tapetum and those in the choroid. Genetically speaking, there is a polyphaenic action of the gene on the two neighbouring tissues.

In any case the name "choroideremia", which is comparable to irideremia, and means absence of the choroid, is entirely incorrect. The preceding discussion has shown that the choroid is not absent at birth. The abiotrophic process begins shortly after birth and progresses gradually. To distinguish this condition from Leber's central and peripheral tapeto-retinal dystrophies, we should have to call choroideremia "tapeto-choroidal dystrophy", naturally based upon a primary dysplasia of the tapetum.

It is extraordinary that, while so much of the retina disintegrates secondarily, so little optic atrophy and narrowing of the retinal vessels is discern-

ible as the disease approaches its final stages. In this respect also the fundus picture differs significantly from that of dystrophia retinae pigmentosa and allied genetic diseases.

For this reason we reject the hypothesis of a primary total or partial aplasia of the chorio-capillary layers propounded by Mann (1957), as well as the two mechanical processes regarded by this author as responsible for the degeneration:

- (1) That not all or even most of the short posterior and anterior ciliary arteries have budded from the ophthalmic artery at the 16-mm. stage,
- (2) That the outer layer of the optic cup may fail to produce pigment (at the 10-mm. stage) and so the stimulus for the capillary growth may fail, even though the arteries do bud out."

### Summary

Three patients and six carriers in two families suffering from choroideremia are discussed. The youngest patients were 7 and 8 years old respectively when examined for the first time. The visual fields, rate of dark adaptation, colour vision, and electroretinogram were studied extensively. Marked alterations, more specifically in the scotopic functions, were found in the two boys, whereas only very slight alterations, or none, could be demonstrated in the carriers. Detailed studies of the fundi of the youngest patients and comparison with the fundi of the carriers led to the conclusion that the primary affection may be considered as an abiotrophic process of the "tapetum nigrum" with a secondary progressive dystrophy of the chorio-capillary layer and outer retinal layers.

These findings suggest that the hypothesis of a dysplasia of the choroid as a primary cause of the fundus alterations must be rejected.

### REFERENCES

- BOUNDS, G. W., and JOHNSTON, T. L. (1955). *Amer. J. Ophthal.*, **39**, 166.  
 BURSTIN, G. von (1958). *Klin. Mbl. Augenheilk.*, **132**, 869.  
 DUKE-ELDER, S. (1938). "Text-book of Ophthalmology", vol. 2, p. 1329. Kimpton, London.  
 FRANÇOIS, J., VERRIEST, G., and DE ROUCK, A. (1956). *Ophthalmologica (Basel)*, Suppl. **43**.  
 GOEDBLOED, J. (1942). *Ibid.*, **104**, 308.  
 HENKES, H. E. (1958). *Ibid.*, **135**, 138.  
 LEBER, T. (1916). "Graefe-Saemisch-Hess Handbuch der gesamten Augenheilkunde", bd 7, p. 1076-1225 (esp. p. 1079).  
 McCULLOCH, C., and McCULLOCH, R. J. P. (1948). *Trans. Amer. Acad. Ophthal. Otolaryng.*, **52**, 160.  
 MANN, I. (1957). "Developmental Abnormalities of the Eye", 2nd ed., p. 179. B.M.A., London.  
 MAUTHNER, L. (1871). *Ber. nat.-med. Ver. Innsbruck*, **2**, 191.  
 SCHUTZBACH, M. (1938). *von Graefes Arch. Ophthal.*, **138**, 315.  
 SORSBY, A., FRANCESCHETTI, A., JOSEPH, R., and DAVEY, J. (1952). *Brit. J. Ophthal.*, **36**, 547.  
 VERHOEFF, F. H. (1942). *Arch. Ophthal. (Chicago)*, **27**, 688.  
 ——— (1948). Discussion of McCulloch and McCulloch (1948), p. 188.  
 WAARDENBURG, P. J. (1942). *Acta ophthal. (Kbh.)*, **20**, 235.