

COMMUNICATIONS

PSEUDOTUMOUR OF THE ORBIT* **A CLINICAL AND PATHOLOGICAL STUDY OF 47 CASES**

BY

MARGARET E. COOP

Department of Pathology, Institute of Ophthalmology, University of London

ORBITAL pseudotumour is a term used to describe diverse clinical conditions which initially may simulate true orbital tumours but subsequently pursue a benign course. Although the first case was described over a century ago, a survey of the literature reveals little progress in the understanding of the processes involved in the production of pseudotumours. Many of the lesions are described as chronic orbital granulomata, but this non-committal term does little to elucidate their origin.

Birch-Hirschfeld (1930) was puzzled to find granulomata in sections from orbital material removed from patients free from tuberculosis, syphilis, fungus, or parasitic disease. More recently, Benedict (1949) reported two cases, confirmed histologically, of "solitary orbital sarcoid", but the patients gave no evidence of sarcoidosis or other pathology when traced for 22 years.

For these orbital lesions in cases in which granulomatous disease is absent elsewhere and does not manifest itself later, the name orbital lipogranuloma is here proposed; the present study suggests that these granulomata are due to fat necrosis and its sequelae: the reasons for this opinion are detailed later.

Although Reese (1951) noted the presence of fat necrosis in orbital pseudotumours, he regarded it as incidental to inflammation already present. The illustrations in his textbook, however, show features of late stages. Elsewhere in the literature no reference to the role of fat necrosis as an explanation for granulomatous orbital pseudotumours has been found.

The present study confirms that even to-day the aetiology remains clinically obscure in many cases, though pathological examinations reveal the cause in some, and clinical follow-up enables a few others to be diagnosed.

Confirmation of diagnosis is difficult as the clinical features can be mimicked by many conditions so that the differential diagnosis covers a wide field. This was well demonstrated by Cowan (1951); five clinical diagnoses were made before biopsy and exenteration finally revealed a chronic inflammatory retrobulbar mass. Treatment of the lesion can be rational

* Received for publication September 7, 1960.

only when the causation is understood. This explains the lack of standardized treatment as most writers are agreed that numerous factors may produce orbital pseudotumours.

This study involves the clinico-pathological investigation of 47 cases of orbital pseudotumour diagnosed histologically from 1924 onwards. 45 cases were provided by surgery (biopsy 29, enucleation 7, exenteration 9), and two by *post mortem* material.

39 of the patients, with an average follow-up just exceeding $4\frac{1}{2}$ years, have been traced post-operatively, and information has been obtained about progress, treatment, and present condition.

It is evident from this series that the visual prognosis for a patient developing an orbital pseudotumour is much improved in recent years, due to increased awareness of this benign condition, and the wise and accepted use of preliminary biopsy, together with the wider range of treatment available.

The prognosis for life was shown here to be unaffected by development of an orbital pseudotumour. Five patients in the series died and four of these were confirmed by *post mortem* examination to have died from other causes. One patient (Case 14), a woman aged 35 years, for many months was thought to have a pseudotumour but later died from lethal midline granuloma (Wegener's granulomatosis). Another patient died from perinephric abscess. Two male patients aged 81 and 61 years died from cerebral haemorrhage and arteriosclerosis. The remaining patient, who had been traced before death for over 9 years, was not known to have had an autopsy.

Analysis of 47 Cases

The length of follow-up is set out in Table I; the average for the 39 cases traced is $4\frac{1}{2}$ years.

TABLE I
LENGTH OF FOLLOW-UP

Follow-up (yrs)	No. of Cases
More than 10	2
5-10	11
3-5	12
1-3	10
$\frac{1}{2}$ -1	4
<i>Post mortem</i>	2
Not traced	6
Total	47

The age when the lesion was diagnosed histologically ranged from 14 to 83 years (average 48). There were 25 male and 22 female patients. The right orbit was affected in 24 cases and the left in eighteen, and in two it was not stated.

In three cases both orbits have subsequently become involved, but two of these have manifested as endocrine exophthalmos and the third may be accounted for by apparent exophthalmos. Two bilateral cases (Cases 4 and 8) are detailed later; the remainder of the traced cases were unilateral.

The patient's occupation was not noted as significant.

The site of the pseudotumour is set out in Table II:

TABLE II
SITE OF PSEUDOTUMOUR

Site	No. of Cases
Floor of orbit (one beneath periosteum)	12
Within muscle cone	8
Lacrimal gland region	8
Closely related to globe	5
Roof of orbit	3
Lateral wall extending to apex	2
Apex of orbit	1
Medial orbital wall	1
Diffusely in orbit	2
In a socket	1
Not stated	4
Total	47

In two cases associated with trauma the lesion involved the temporal side of the globe (Cases 11 and 15).

There were no known intracranial extensions from the orbit.

Clinical Features of Orbital Pseudotumour

Proptosis.—This was the commonest complaint, occurring in 37 cases. 23 patients presented with proptosis and fourteen developed it later. In the ten patients who did not develop proptosis, eight lesions involved the lacrimal gland region, one the orbital floor, and one the temporal side of the globe.

Pain.—Twelve patients presented with pain, five developed it later, and six had no pain. In nine other cases irritability of the eye was noted, but in the remainder no discomfort was mentioned.

Swelling of Lids or Chemosis.—Nine patients presented with lid swelling and five developed it later. In nine cases chemosis was noted.

Diplopia or Limitation of Movement.—Five patients presented with diplopia and seven developed it later: limitation of movement was present in sixteen and ptosis in four.

Orbital Swelling.—In sixteen patients a mass was palpable clinically. The only symptom of one patient was a swelling, which was palpable in the lacrimal gland region.

Pyrexia.—A mild transient pyrexia was noted in one case. In Case 5, in which death occurred from infection elsewhere, the temperature was high and swinging.

Disc Oedema.—This was present in eight cases. Visual acuity of 6/24 in one patient improved to 6/6 after surgical removal and radiotherapy when the disc oedema resolved.

Reduced visual acuity was mentioned in seven cases: in four it was due to disc oedema, in two to retinal detachment, in one the cause was not stated.

Visual Fields.—Defects due to disc oedema and retinal detachment were recorded, but there were no other visual field defects.

Retinal Detachment.—This was present in three cases.

Other Complications.—Uveitis, retinal haemorrhages, central retinal vein thrombosis, lagophthalmos, exposure keratitis, and panophthalmitis occurred in isolated cases.

Investigations of Orbital Pseudotumour

X-ray of Skull and Orbits.—This was helpful in excluding the presence of bone involvement, which is not a feature of orbital pseudotumour.

Several cases showed a soft tissue orbital shadow. One showed doubtful changes suggestive of sphenoidal ridge meningioma which was not confirmed *post mortem*.

X-ray of Sinuses.—In 23 cases these were normal. Treatable sinusitis was present in four cases where *x* rays showed antral opacity.

Carotid Arteriography.—This was performed in one case but no evidence of vascular abnormality was found.

Orbitography.—An inconclusive result was obtained in one case in which this was done.

Wassermann Reaction and Kahn Test.—In eighteen cases in which this was mentioned, all were negative.

Blood Examination.—Full blood counts were normal in 21 cases. In three patients (Cases 12, 13, and 14 which are detailed later) the erythrocyte sedimentation rate was raised. In two of these the condition was associated with trauma and in one with lethal midline granuloma. In each the symptoms and signs were progressive.

Basal Metabolic Rate.—This was insignificantly raised in two patients. In a third (Case 4) it was raised at one stage to +34 per cent., and the diagnosis later proved to be that of endocrine exophthalmos.

Lumbar Puncture.—This was performed in two cases and results were normal.

Aspiration Biopsy.—This was performed on two patients but was not of diagnostic value.

Surgical Biopsy.—This was performed on forty occasions. Biopsy was not always done on patients early in this series, but one or more biopsies were done on others later in the series.

Treatment

Surgery.—Of the first fourteen cases in this series, diagnosed between 1924 and 1953, twelve patients lost either an eye (by enucleation: 3, or by evisceration: 1) or the orbital contents (by exenteration: 8). One case was diagnosed after a *post mortem* examination and the one patient who eluded the surgeon's knife is well, although unilateral proptosis is still present after 6 years.

In the remaining 33 cases, diagnosed since 1953, three eyes were removed and one orbit was exenterated. This exenteration was done for a lesion that later proved to be a lethal midline granuloma (Case 14). Of the three eyes that were lost, two had pain together with retinal detachment in which malignancy was suspected and the third was blind and fixed.

In two cases a definite tumour was not demonstrated at operation, although biopsy showed dense chronic inflammatory tissue. These conformed with Birch-Hirschfeld's Type II (see below).

In three cases it was noted that one or more of the rectus muscles were greatly hypertrophied. One (Case 4) developed endocrine exophthalmos, and two other patients were not traced.

SURGICAL COMPLICATIONS

Orbital Haemorrhage.—This occurred after orbital exploration and exenteration was later necessary.

Perforation of the Globe.—The tumour was removed *via* a transfrontal approach and the cornea was already extensively damaged by hypopyon ulcer at the time of operation. Evisceration was necessary later.

Section of Optic Nerve.—An extensive pseudotumour was removed, and during the operation the optic nerve was cut. Exenteration was carried out later because of pain and immobility of this blind eye.

Weakness of all Ocular Movements.—This developed post-operatively in two cases.

Partial IIIrd Nerve Palsy.—This was seen in one case.

Ptosis and Displacement of the Globe.—This was seen in one case.

Anaesthesia over Distribution of Supra-orbital Nerve.—This was seen in one case.

Some of the above complications may be attributed to post-operative scar tissue.

Recurrence of Pseudotumour.—Case 18 shows that recurrence may occur and that this need not indicate malignancy.

Radiotherapy.—The best results were obtained in cases in which histological examination showed a cellular predominance rather than large amounts of fibrous tissue, and in which the symptoms were of recent onset.

Nine cases of orbital pseudotumour were given radiotherapy following biopsy. Three were markedly improved but six were unaffected. Two further cases received radiotherapy and Telecobalt therapy respectively immediately after surgical removal of the pseudotumour, with favourable results. As the relative value of radiotherapy and surgery could not be assessed, these two cases are not included.

Good Results with Radiotherapy.—Three patients, in whom symptoms had been present for from 2 to 6 months, improved markedly with treatment. In one of these the pseudotumour involved the lacrimal gland, which was infiltrated with lymphoid follicles containing germinal centres. The second case showed fat necrosis in orbital tissue with negligible fibrosis. The third case (Case 15) showed extremely cellular tissue and was given the alternative diagnosis of lymphoma or lymphosarcoma of the orbit. This lesion rapidly disappeared with radiotherapy.

No Response to Radiotherapy.—Six patients were unaffected by treatment. In four of them symptoms had been present for 18 months or more before treatment was given, and large amounts of fibrous connective tissue were present in the histological sections. In the fifth orbital swelling lessened but pain increased after radiotherapy and exenteration was done later. In the sixth, the patient, who complained of orbital pain before treatment was begun, still complains of pain preventing sleep. He was unaffected by radiotherapy.

Steroid Therapy.—Four patients received systemic steroid therapy. Two of these recovered dramatically and completely, a third gained temporary improvement, and the fourth was not affected. None of these patients belonged to the orbital myositis group.

Case Reports

Case 1.—8 weeks after the onset of redness and swelling of both lids, ptosis, proptosis, and diplopia, a male, aged 25 years, was given systemic cortisone and ACTH with improvement. On withdrawal of treatment, the symptoms increased, and biopsy showed fibro-vascular tissue with a minimal chronic inflammatory cell content. The histological picture would, no doubt, have been altered by the hormonal treatment. A further 2 months of the same therapy was given with marked improvement. 6 years later the patient was symptom-free. Mercury, iodides, and antibiotics had been ineffective in this case.

Case 2, a woman aged 70 years, had similar symptoms of swelling and redness of a lid, ptosis, proptosis, and diplopia for 8 weeks which were unaffected by penicillin. Potassium

iodide and prednisone were given for 2 months and the recovery was remarkable. The prednisone dosage was 5 mg. twice daily initially and later the dosage was halved. 2 years later the patient is well and symptom-free.

The biopsy specimen taken before treatment provided much controversy; three leading London pathologists made different diagnoses as follows: gliomatous infiltration of the orbital tissue, neurofibroma undergoing degenerative change, and orbital granuloma.

Case 3, a male aged 53 years, who complained of diplopia, ptosis, and proptosis of 8 weeks' duration, was not improved by antibiotics or potassium iodide and gained striking improvement lasting one week with prednisolone and a similar temporary effect with Diamox (acetazolamide). As the improvement was not maintained, the patient has been treated with radiotherapy, but this has had no appreciable effect. The fibro-fatty biopsy tissue showed early changes of fat necrosis.

Case 13, the fourth patient, who received systemic cortisone without effect, is detailed later. His symptoms had been present for over a year and histological section showed much dense acellular fibrous connective tissue.

Systemic Antibiotic Therapy.—Seven patients with orbital pseudotumour who received penicillin and/or other antibiotics were not improved.

Sulpha Drug Therapy.—This was ineffective in two cases.

Mercury or Iodide Therapy.—Three patients were not improved by mercury or iodide preparations by mouth. One of these later developed sensitivity to iodine dressings.

A fourth patient (Case 2) improved when a potassium iodide mixture was given during the course of systemic prednisone.

Illustrative Cases of Orbital Pseudotumour

Space does not permit a consideration of all 47 cases, but some are mentioned in detail to demonstrate salient features and diagnostic difficulties.

PSEUDOTUMOUR ASSOCIATED WITH ENDOCRINE EXOPHTHALMOS

Pathological changes due to endocrine exophthalmos and pseudotumour primarily involving extra-ocular muscles (chronic orbital myositis) are very difficult to distinguish with certainty. The pathologist confronted with a small biopsy specimen and, perhaps, scanty clinical details may be diffident about diagnosing endocrine exophthalmos.

The two relevant cases in this series confirmed the difficulties encountered in the clinical differentiation between orbital pseudotumour and endocrine exophthalmos in its early stages, especially when unilateral. However, if the second orbit becomes affected or further clinical features develop in the course of time, the diagnosis of endocrine exophthalmos may be established.

In support of this, Barkan (1938) quoted several cases of unilateral exophthalmos occurring in young girls which preceded the development of a thyrotoxic syndrome by about 18 months without change in the basal

metabolic rate. He considered these could account for cases of pseudo-tumour in which, at operation, no tumour is found.

Case 4.—This patient was presented by Meadows (1945). A man aged 56 years who developed right exophthalmos, chemosis, and limited ocular movements, later developed pain in the eye. There was no clinical evidence of endocrine exophthalmos, but the basal metabolic rate was +34 per cent. on one occasion. As the proptosis was irreducible and a palpable tumour was found in the orbit, a biopsy was done, which showed a "pseudotumour" of the orbit.

Because of pain, progressive exophthalmos, chemosis, lid oedema, lagophthalmos, and corneal ulceration, a neuro-surgical unit performed extensive orbital decompression. At operation a hard mass of tissue arising from the superior rectus muscle and extending to the back of the orbit was removed, together with the muscle. Histologically, this tissue, identical with that in the earlier biopsy, showed oedematous muscle with some degeneration of the muscle fibres and fibrous connective tissue. There were diffuse and focal collections of chronic inflammatory cells and some epithelioid cells.

Although the proptosis regressed a little post-operatively, hypopyon and corneal perforation necessitated evisceration 3 weeks later. 21 months after the onset of the right orbital symptoms the left orbit became similarly affected and the endocrine signs became obvious, and the diagnosis of endocrine exophthalmos was made. The exophthalmos fluctuated in severity, but the fate of the left eye was similar, with a perforated corneal ulcer, and finally leucoma adherens developed. The patient refused operation, and when last seen the vision in the left eye was reduced to perception of light with absent red reflex. The patient died 9 years after the onset of symptoms, at the age of 65 years, but the exact cause of death was not available.

Goldsmith (1945), in the discussion of this case, suggested that only one muscle may be enlarged in endocrine exophthalmos and this could lead to a mistaken diagnosis of pseudo-tumour. No further evidence along these lines was gained by this study. The fluctuation of exophthalmos and clinical signs was noted in only one other case not related to endocrine exophthalmos, so this was not a characteristic feature.

PSEUDOTUMOUR DUE TO CHRONIC ORBITAL MYOSITIS

Dunnington and Berke (1943) described this condition, in which the common symptoms are: painless lid oedema, exophthalmos, and diplopia.

Their four cases were all unilateral and the histology was characterized by lymphocytic infiltration, fibrosis, and degeneration of muscle fibres. Grossly the muscles were pale, enlarged, cartilaginous, and cut with a gritty feeling.

Four cases in the present series had symptoms and signs which, together with the typical histology described by Dunnington and Berke (1943), enabled them to be classified as "pseudotumours" caused by chronic orbital myositis (Table III, opposite). Three of these patients were male and one female. Only one orbit was affected and in each case the floor of the orbit was involved. Most have been traced for several years and none has manifested other clinical signs.

PSEUDOTUMOUR ASSOCIATED WITH FOCAL INFECTION

Case 5.—A man aged 60 years was admitted to a general hospital in 1936. He complained of proptosis and inflammation of the left eye for 3 weeks. The eye was immobile

TABLE III
PSEUDOTUMOUR ASSOCIATED WITH CHRONIC ORBITAL MYOSITIS

Sex	Age (yrs)	Duration of Symptoms (mths)	Site	Symptoms				Follow-up
				Diplopia	Proptosis	Lid Oedema	Limitation of Movement	
Male	32	18	Floor of Orbit	+		+	+	At operation the optic nerve was cut, so exenteration was done later. Well and symptom-free 11½ years later.
Male	57	18	Floor extending to Apex	+	+		+	Biopsy showed pseudotumour but globe later removed. Symptom-free 6 years later.
Male	64	12	Floor of Orbit	+	+		+	Inferior rectus muscle and mass removed at biopsy. Apart from limitation of movement, symptom-free 4 years later.
Female	54	6	Floor of Orbit	+	+	+		Satisfactory recovery after biopsy, symptom-free 6 months later.

and chemosis was present. His sinuses were explored and found normal. A retro-ocular tumour was suspected.

While under observation the patient died and *post mortem* examination revealed subphrenic and perinephric abscesses and apparently no sign of tumour growth or sepsis in the orbit. The patient had never complained of abdominal pain but his temperature had been markedly raised.

Histological changes were those of a fibrosing inflammatory orbital mass containing plasma cells, lymphocytes, a few polymorphonuclear leucocytes, and endothelioid cells. Large numbers of eosinophilic leucocytes were aggregated together surrounding fat cells in many areas, and occurred diffusely, in smaller numbers, throughout the remainder of the affected areas. The marked inflammatory changes surrounded a large occluded artery and numerous smaller occluded vessels lying in the affected orbital fat (Fig. 1). The globe, optic nerve, more distant orbital fat, and connective tissue trabeculae were unaffected. A rectus muscle showed increase in sarcolemmal nuclei and some perivascular lymphocytic cuffing.

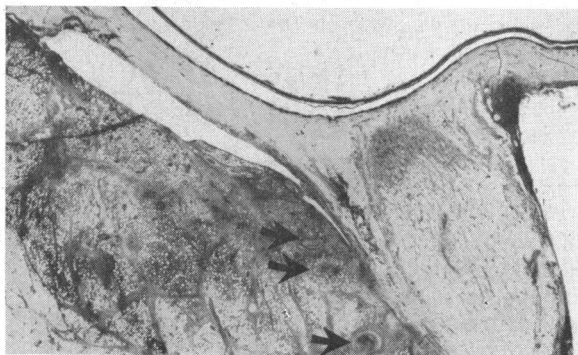


FIG. 1.—Case 5. Pseudotumour associated with focal infection. Occluded arteries lie close to the optic nerve (arrows) and extensive early changes of fat necrosis affect the orbital tissue.

It is of interest that this patient suffered from renal infection, for Boyd (1953) states that lymphatics from the kidney drain directly to the thoracic duct, often with no intervening lymph nodes, and infective material may, therefore, reach the blood stream in quantity.

The pseudotumour in this case resulted from changes in the orbital fat which were present as a consequence of arterial occlusion.

A further case of orbital pseudotumour associated with infection elsewhere in the body is presented in Case 6, in which the infective source was eliminated early and the orbital lesion was not extensive.

Cases 5 and 6 indicate that infection elsewhere in the body may be important in production of orbital pseudotumours. Such lesions were postulated by Duke-Elder (1952).

Case 6.—A man aged 59 years was admitted to a general hospital with a gangrenous appendix which was removed. At the time right chemosis was noted. 6 months later, he sought ophthalmological advice because of an indurated swelling below the right eye which was slightly proptosed. 2 years after biopsy the patient was symptom-free.

Histological sections of a very small biopsy showed a pseudotumour consisting of fibrovascular fatty tissue densely infiltrated with focal collections of small round cells, together with a few swollen endothelial cells and plasma cells.

PSEUDOTUMOURS ASSOCIATED WITH SINUSITIS

The close association between some orbital pseudotumours and paranasal sinusitis is demonstrated in the three following cases. Sinus infection may spread directly or act indirectly *via* the blood supply.

Case 7.—A woman aged 44 years complained of right retro-ocular pain, and thick creamy pus was obtained from a right antral washout. The pain persisted and 10 months later the vision became blurred in the right eye. A retinal detachment involving the right macular region was now present together with a secondary inferior detachment. As malignancy was suspected the eye was enucleated, after which the pain disappeared. One year later the patient was symptom-free and the orbit normal.

Fig. 2 shows a low-power section of the globe showing the thickening of the sclera extending from the equator to the disc. The sclera is thickened by fibrosis and chronic inflammatory-celled infiltration which is both diffuse and focal, forming in some areas well-marked lymphoid follicles with active germinal centres. The chronic inflammation extends into the choroid and the retina is detached by an exudate.

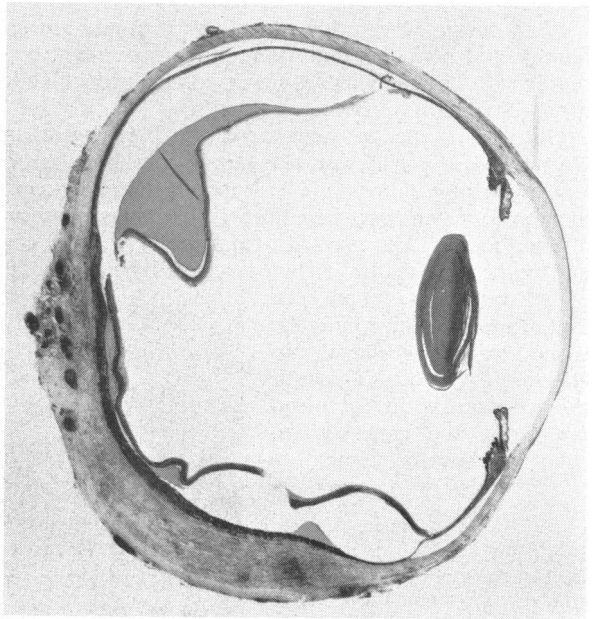


FIG. 2.—Case 7. Pseudotumour associated with sinusitis. There is gross scleral thickening and dense perivascular chronic inflammatory cell infiltration, together with retinal detachment with subretinal exudate.

The association between purulent sinusitis and the resultant ocular involvement seems unequivocal in this case. Unfortunately, the effects were well-established within the globe and treatment of the sinusitis did not relieve the ocular pain.

Case 8.—A boy aged 5 years living in South Africa had bilateral strabismus operations. When 13 years old he was treated by an ear, nose, and throat specialist, who noted conjunctival congestion together with enlarged turbinates and a deviated nasal septum. Nasal and sinus *x* rays showed opacity of both maxillary antra. The diagnosis made was that of allergy with secondary infection of the sinuses.

One year later, left exophthalmos developed and a large mass of tissue was removed from behind the globe (Fig. 3*a*). This tissue showed a typical pseudotumour of the orbit with dense fibrous connective tissue containing many follicles of chronic inflammatory cells, endothelial cells, and a few giant cells. The details are seen in Fig. 3*b*, which shows a high-power view of one of the follicles.

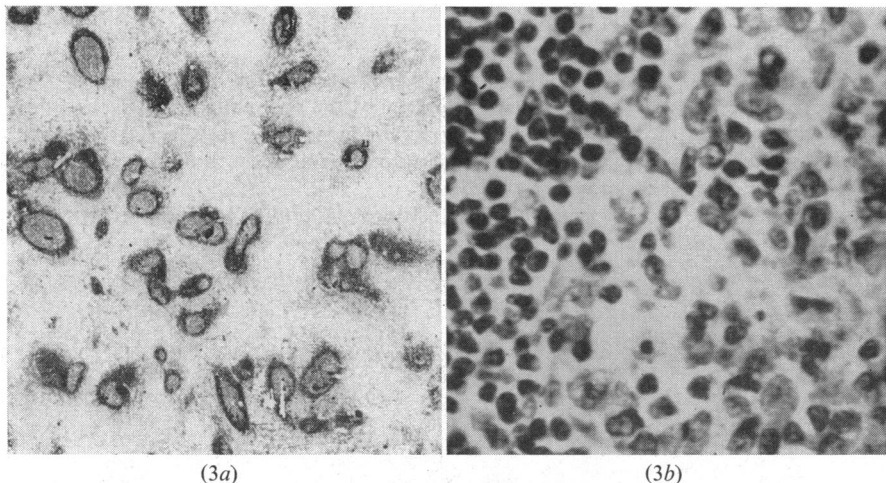


FIG. 3*a, b*.—*Case 8*. Pseudotumour associated with chronic sinusitis in a boy aged 14 years. (*a*) Aggregations of chronic inflammatory cells lie in dense fibrous connective tissue. $\times 9$. (*b*) High-power view of follicle seen in (*a*). To the left are peripheral lymphocytes and elsewhere endothelioid and plasma cells form the central area of the follicle. $\times 570$.

2 years later the left eye and orbit were stated to be normal but the right eye appeared to be slightly proptosed and the lids were swollen. This was associated with right chronic dacryocystitis which was relieved by systemic antibiotics, though regurgitation with pressure on the lacrimal sac persisted. The globe, lids, and vision were otherwise normal, but mild proptosis remained. The lid swelling of the right eye may be accounted for by the right chronic dacryocystitis. The slight right proptosis noted by the general practitioner who examined this boy for follow-up purposes may be apparent exophthalmos. This exophthalmos could be accounted for by a left enophthalmos which was in turn due to the removal of a *large* retrobulbar mass and also to post-operative scar tissue contraction. This case is therefore an example of an orbital pseudotumour occurring in a young person in association with chronic sinusitis.

Case 9.—A man aged 42 years sought advice because of onset of pain in the right eye. 20 years previously he had received facial injuries in a motor-cycle accident, and for many years he had noticed a right proptosis and restricted adduction of the eye. When he was examined, these signs, together with oedema of the right caruncle, were noted, but the eye was otherwise normal.

Because infection of the right maxillary antrum was present, two Caldwell-Luc operations were performed which cleared the sinus infection. A biopsy, taken from a lump

on the nasal side of the orbit, showed fibrous connective tissue undergoing hyaline change and infiltrated with chronic inflammatory cells and a few giant cells typical of a long-standing pseudotumour.

Post-operatively, although there was residual proptosis, full ocular movement was regained and the pain and oedema of the caruncle disappeared. 3 years later this patient is well and the proptosis has decreased by 3 mm.

Trauma and sinus infection were both associated in the production of the lesion in this case.

PSEUDOTUMOUR ASSOCIATED WITH A LEAKING DERMOID CYST

The following case occurring in a girl aged 18 years demonstrates some difficulties of pathological diagnosis.

Case 10.—A girl aged 18 was admitted to a general hospital for investigation of a mass near the right lacrimal gland. Biopsy was reported by the hospital pathologist as "similar to a mixed tumour of the parotid gland". Dacryoadenectomy was therefore performed.

2 months later, when pain, proptosis, and a palpable extension to the lower part of the orbit developed, a right exenteration was done.

Examination of the orbital contents at the Institute of Ophthalmology, London, showed an extensive organizing granuloma due to a leaking dermoid cyst (Fig. 4).

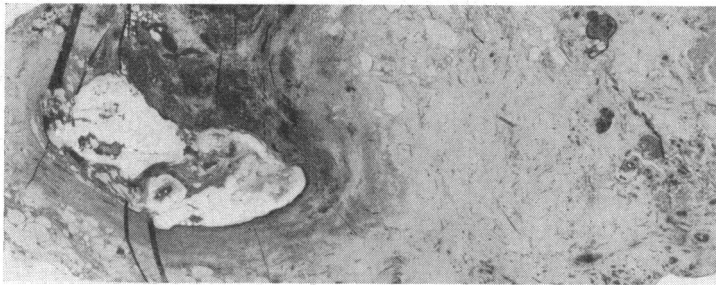


FIG. 4.—*Case 10.* Pseudotumour associated with the leaking dermoid cyst seen on the left. Extensive fibrosis present. $\times 5$.

6 years after the onset of symptoms, the patient is well and the socket has remained normal.

PSEUDOTUMOUR ASSOCIATED WITH A RETAINED AND UNSUSPECTED FOREIGN BODY

Case 11.—In 1931 a boy aged 14 years complained of pain in the head and in the left eye for 2 weeks. 4 days later vomiting occurred, proptosis developed, and the pain increased. When he was admitted to hospital the visual acuity of the left eye was 6/9 partly and chemosis was present. Vomiting persisted, all symptoms increased, and the left visual acuity was reduced to faint perception of light. A hypopyon ulcer developed together with secondary glaucoma. X rays did not show a foreign body and a left antral lavage was clear. 5 days after admission the left eye was enucleated.

The cause of the symptoms was not known before the histological examination of the specimen which showed a fine splinter of wood partly retained in the iris and partly lodged within the orbit (Fig. 5, opposite).

The foreign body within the globe was surrounded by subacute inflammatory cells, and hypopyon and fibrous exudate were present in the anterior chamber. Elsewhere the globe showed mild panophthalmitis.

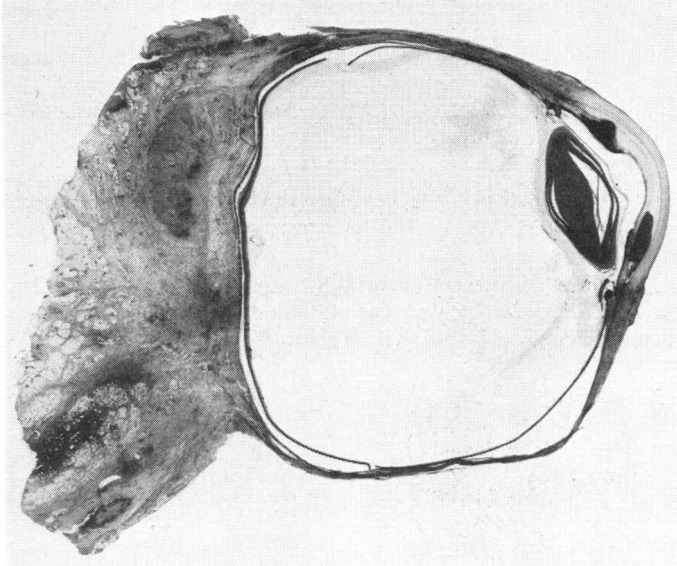


FIG. 5.—*Case 11.* Pseudotumour associated with a retained, unsuspected foreign body. Hypopyon is present in the lower part of the anterior chamber and dense cellular reaction surrounds the wood particle retained in the iris. Posteriorly and below a similar fragment is retained in the retro-orbital tissue. $\times 2.25$.

The orbital foreign body had produced an extensive reaction in the fibro-fatty orbital tissue, consisting of granulation tissue with enormous numbers of young fibroblasts and many eosinophils, together with endothelioid cells and small round cells.

The globe had been injured from the temporal aspect where it is least protected, although no history of injury could be obtained.

PSEUDOTUMOUR ASSOCIATED WITH INDIRECT TRAUMA

Case 12.—A man aged 74 was first seen with a head injury and laceration of the right supra-orbital region received when a box of papers felled him to the ground. *X* ray of the skull was normal.

2 years later, he complained of a prominent left eye and headaches. Clinically he had an irreducible left proptosis, chemosis localized to the upper temporal quadrant, and left lid swelling. The fundi were normal, but mild bilateral lens opacities reduced the visual acuity to 6/9 in each eye; otherwise the right eye was normal. During the following month the proptosis increased and there was limitation of movement of the left eye upwards and outwards.

The erythrocyte sedimentation rate was raised to 49 mm./hr; the cholesterol level, blood count, and ear, nose, and throat examinations were normal. The Wassermann reaction and Kahn test were negative.

X ray of the skull showed doubtful thickening of the left lesser wing of sphenoid, suggestive of a ridge meningioma.

A biopsy was taken from a mass above the left globe and a post-operative course of sulphatriad and penicillin was given. The specimen showed a mass of chronic inflammatory tissue divided into irregular lobules by dense fibrous trabeculae. Within the lobules, numerous small vessels showed a marked endovasculitis and perivasculitis, small

round cell infiltration, and fibrosis. The tissue was diffusely infiltrated with eosinophilic leucocytes.

The symptoms increased and papilloedema and ophthalmoplegia became evident so the left orbit was given a 14-day course of radiotherapy, without effect. 18 months later the patient returned for treatment of a right corneal ulcer. The corrected visual acuity was 6/18, but the left eye was now blind and grossly proptosed.

This patient was reviewed by the author 2 years later.

Right Eye.—The visual acuity was counting fingers at 2 metres because of corneal scarring and a central lens opacity; the movements were full with no proptosis. The orbit was normal.

Left Eye.—There was no perception of light, gross proptosis, chemosis, xerosis, and discharge (Fig. 6). The ocular tension was normal. The eye was fixed in a solid mass of tissue which filled the orbit. X rays showed a soft-tissue swelling in the left orbit but the bony walls were intact.

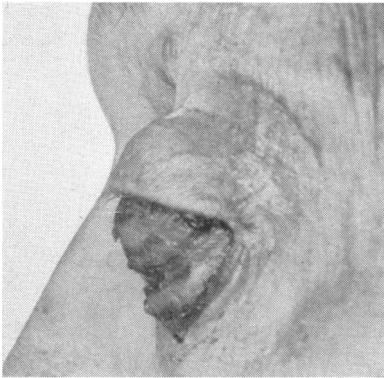


FIG. 6.—Case 12. Pseudotumour associated with indirect trauma. There is extensive left keratitis due to lagophthalmos and infected, chemotic conjunctiva. Lateral view showing proptosis.

Left evisceration was performed.

4 months later the patient, now aged 81, died at a general hospital and a *post mortem* examination was performed. This was 6½ years after the traumatic incident and 4½ years after onset of proptosis.

No tumour tissue was found elsewhere in the body. Death was caused by arteriosclerosis with cerebral haemorrhage into the basal nuclei of the brain. Apart from atrophic emphysema of the lungs and nephrosclerosis, the remaining organs were normal. The orbital tissues were not examined at autopsy.

PSEUDOTUMOUR ASSOCIATED WITH OLD PENETRATING INJURY

Case 13.—A man aged 67 years complained of pain in the left supra-orbital region and blurred vision in the left eye; 2 years previously the vision of the left eye had been reported as 6/6. Localized conjunctival congestion was seen on the temporal side of the globe which the patient had noticed unchanged for one year. The visual fields were full and sinus x rays were negative. The left fundus showed an ill-defined spot below the macula.

6 months later, the patient was investigated in a general hospital and, apart from quiescent pulmonary tuberculosis (13 years earlier), no cause was found for the eye lesion. A course of systemic cortisone for 3 weeks did not affect the symptoms.

The fundus next showed definite forward prominence in the lower, outer temporal area which transilluminated well. 6 months later a left uveitis developed together with an extensive temporal retinal detachment. The area of conjunctival congestion became a yellow, oedematous, infiltrative mass. The blood count, Wassermann reaction, and Kahn

test were negative. The erythrocyte sedimentation rate (Wintrobe) was 23 mm./hr; the left globe was then excised.

When reviewed by the author in connexion with this study 5½ years after the onset of the left conjunctival congestion, the patient was well and active and the socket was normal.

The right eye was normal with a visual acuity of 6/4. There was a pigmented and almost vertical linear scar an inch long near the left lateral orbital margin, and it was disclosed that, at the age of 4 years, the patient had received a penetrating injury in this region when he fell onto a sharply-pointed triangular piece of metal.

Fig. 7 shows a low-power view of the left globe of this patient, illustrating the solid mass of organizing granulation tissue which is indenting and invading the sclera and choroid on that side. The mass is fused with the lateral rectus which is involved in the same process. The retina is seen to be detached by a subretinal exudate.

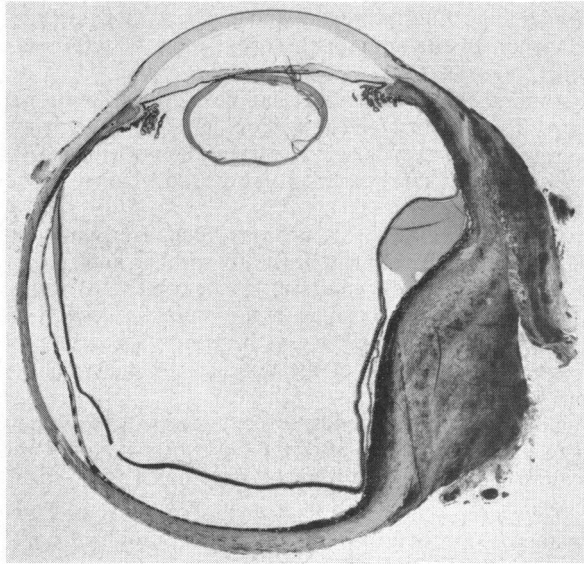


FIG. 7.—Case 13. Pseudotumour associated with old penetrating injury. There is scleral thickening indenting the globe and involving the lateral rectus muscle. Retinal detachment is present.

Histologically this granulating mass is characterized by sharply-demarcated lymphocytic foci, perivascular in distribution, lying in a dense fibrous stroma diffusely infiltrated with chronic inflammatory cells among which eosinophils and plasma cells are prominent. The remainder of the choroid shows a mild focal inflammatory reaction and moderate oedema.

Ramsey and colleagues (1948) described two cases of post-traumatic granuloma of the bony orbit and a third case occurring in a rib. In each of these three cases there had been authentic injury to the region over 20 years previously. Although the latent period in Case 13 was longer, the site of the old scar and the location of the ocular lesion occurring in the adjacent lower temporal quadrant seem undoubtedly related.

PSEUDOTUMOUR ASSOCIATED WITH LETHAL MIDLINE GRANULOMA (WEGENER'S GRANULOMATOSIS)

This rare tumour was twice diagnosed as an orbital pseudotumour from biopsies taken 11 months apart. It demonstrates the difficulties of

distinguishing lethal midline granuloma histologically from a benign orbital granuloma. The following case report was presented at the Ophthalmic Section of the Royal Society of Medicine in 1959 (Foulds and Wear, 1961).

Case 14.—A woman aged 35 years complained of pain in the left eye and constant diplopia for 3 months.

Examination.—The left eye was displaced upwards and laterally. A hard, painless swelling was palpable through the lower lid near the inner canthus. In both eyes the visual acuity was 6/6. The Wassermann reaction and Kahn test were negative. Chest and skull x rays were normal apart from some opacity of the left maxillary antrum. Sterile necrotic cells were obtained on left antral lavage.

Exploratory Operation.—A large mass was found which filled the lower orbit and infiltrated the inferior rectus and orbicularis palpebrarum muscles. Apart from a flat extension to the apex of the orbit, most of the mass was removed, with symptomatic relief.

4 months later the patient had developed a total ophthalmoplegia, marked exophthalmos, disc oedema, and a shallow left retinal detachment. The blood cholesterol was normal, but the erythrocyte sedimentation rate was raised to 54 mm./hr at this time. The orbit was decompressed from above and biopsy tissue again showed chronic granulomatous tissue.

One year later the left eye was blind from panophthalmitis and absolute glaucoma. The eye was enucleated, together with a large piece of hard, yellowish tissue which extended along the medial wall of the orbit to its apex.

The orbit filled again with firm tumour tissue producing considerable pain. Two courses of high voltage x ray therapy to the orbit were followed by relief of pain and regression in the size of the tumour. A course of erythromycin was given to control orbital infection.

Enlarged cervical glands, severe anaemia, and a lung abscess developed and the patient died just over 2 years after the onset of symptoms, the cause of death being toxæmia, extensive necrosis, and broncho-pneumonia with lung abscess.

Diagnosis.—The clinical diagnosis of lethal midline granuloma (Wegener's granulomatosis) was confirmed at *post mortem* examination. The left orbit was by now completely disorganized and replaced by a large putrefying abscess cavity.

Histology

FIRST BIOPSY SPECIMEN.—Biopsy showed a mass of fibrous tissue with numerous centres of inflammation in which there were lymphocytic, plasma cell, and polymorphonuclear infiltration, and some degree of necrosis. A few giant cells were present, but there was no typical tubercle formation to suggest sarcoidosis or tuberculosis.

SECOND BIOPSY SPECIMEN. This was taken 11 months later and was very similar to the first.

Section showed a nodule of fibrotic tissue that had undergone marked hyalinization. Scattered throughout were numerous aggregations of mature lymphocytes and plasma cells, many of which appeared to be encircling hyalinized and thickened vessels. There was also a diffuse infiltration of lymphocytes, plasma, giant cells, and fibroblasts.

POST MORTEM.—Granulomatous lesions of the same type were found in the cortex of the kidney and in the lung.

In retrospect there would appear to have been several ways in which this lesion differed from other orbital pseudotumours:

- (1) The presence of necrotic tissue foci which have not been noted in any of the other cases of orbital pseudotumour.

- (2) The presence of a raised erythrocyte sedimentation rate of 54 mm./hr.
- (3) A progressive and relentless course leading to early death.
- (4) Granulomatous lesions were found elsewhere in the body, which is not a feature of pseudotumour involving the orbit.

The clinical sign of a raised erythrocyte sedimentation rate and the pathological foci of necrosis may be of help in differential diagnosis in younger patients.

PSEUDOTUMOUR ASSOCIATED WITH LYMPHOMA OR LYMPHOSARCOMA

Case 15.—A woman aged 83 complained of prominence of the left eye for 6 months. Movements of this eye were limited and a mass was palpable through the left lower lid. Orbital *x* rays and a full blood count were normal. Biopsy was done and when radiotherapy was given the proptosis disappeared. 2 years after the onset of symptoms the patient was well and symptom-free. The histological picture of the small biopsy specimen with a heavy concentration of lymphocytes was considered to be characteristic of a pseudotumour although lymphoma or even lymphosarcoma were also possible diagnoses.

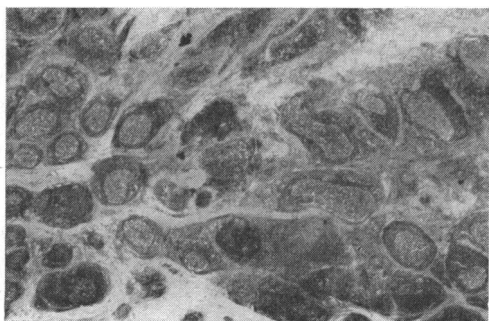
A case such as this, if bilateral, may account for some of the cases of bilateral pseudotumour which show a rapid response to radiotherapy.

PSEUDOTUMOUR INVOLVING THE LACRIMAL GLAND REGION

Case 16.—A man aged 71 years had a swelling in the region of the left lacrimal gland for several months. The Wassermann reaction was negative and *x* rays of the skull and chest were normal. There was no splenic enlargement or lymphadenopathy. The lacrimal gland was removed but no further treatment was given. Apart from occasional swelling of the eyelids, the patient was symptom-free 4 years later.

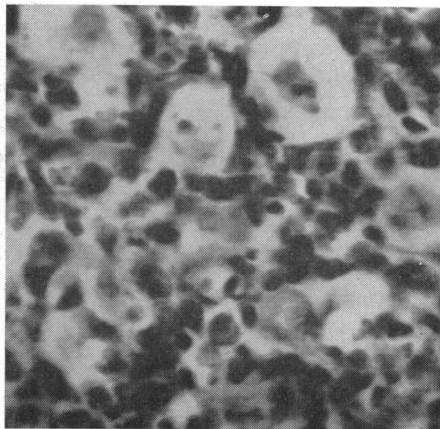
Histology.—Lying in a dense fibrous stroma there are numerous well-defined follicles of lymphoid tissue showing central mitotic and phagocytic activity of the reactionary type (Fig. 8*a, b*). The fibrous septa are diffusely infiltrated with chronic inflammatory cells in which lymphocytes predominate. There is no evidence of normal lacrimal tissue in the section. The lesion is that of a chronic inflammatory reaction of unknown cause and neoplasm can be excluded.

This is a non-specific pseudotumour of the lacrimal gland region.



(8*a*)

FIG. 8*a, b*.—*Case 16.* Pseudotumour from the lacrimal gland region. (*a*) Follicles lie in dense fibrous tissue stroma. No lacrimal gland tissue present. $\times 8$. (*b*) High-power view of centre of follicle seen in (*a*). $\times 570$.



(8*b*)

PSEUDOTUMOUR ASSOCIATED WITH CENTRAL RETINAL VEIN THROMBOSIS

Case 17.—A man aged 48 years complained of pain, diplopia, and swelling of left eye for 3 weeks.

Examination.—The left eye showed conjunctival injection, slight papilloedema, and 4-mm. proptosis, and there was diplopia on looking to the left. A solid mass was felt in the lower part of the orbit.

Ear, nose, and throat examination and skull x rays were negative. The blood count was normal, the erythrocyte sedimentation rate 2 mm./hr, and the Wassermann reaction negative.

4 months later sudden loss of vision developed because of thrombosis of the left central retinal vein, and at the same time proptosis was increased in amount. As a tumour was now also palpable in the upper quadrant of the orbit, exenteration of the left orbit was performed. 4 years after the onset of symptoms the patient's condition was satisfactory.

Histology.—The retro-ocular contents are completely encased in a dense mass of chronic inflammatory tissue which is not only closely adherent to the posterior sclera but extends forwards towards the upper and lower fornices (Fig. 9). Chronic inflammatory cells are diffusely scattered throughout the lesion, and there are also many follicle-like aggregations of lymphocytes embedded in the inflammatory mass and in the adjacent muscular tissue. An associated extensive thrombosis is present in the retro-ocular vessels and also in the vascular beds of both lids.

In the eye there is an extensive thrombosis of the whole uveal tract, and one large and several small cyst-like spaces between the ciliary and pigmented epithelium of the ciliary body. The retina shows some oedema, and an extensive venous thrombosis is present with diffusely scattered haemorrhages and larger haemorrhagic extravasations involving all the retinal layers. There is a localized exudative retinal detachment at the posterior pole and some exudate is present in the vitreous space.

Diagnosis.—Pseudotumour of the orbit with secondary thrombosis of central retinal, vortex, and ophthalmic veins.

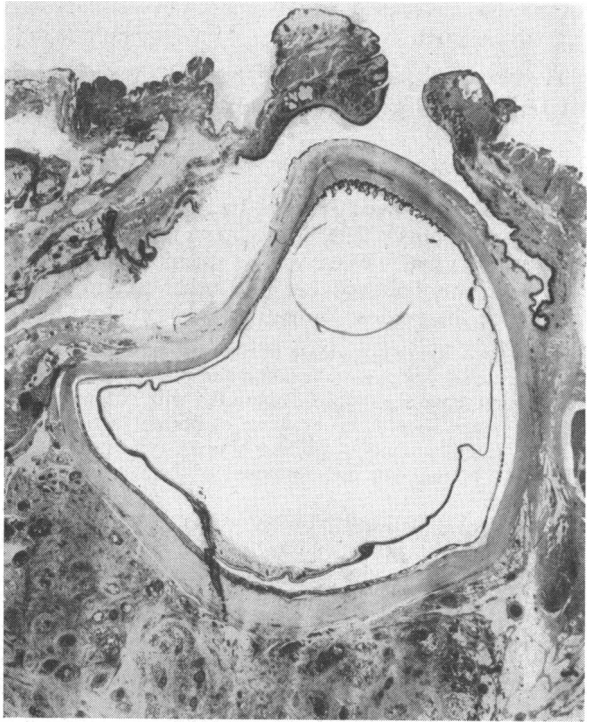

FIG. 9.—Case 17. Exenteration specimen, showing extensive lid, orbital, and central retinal vein thrombosis. Retinal oedema is present. $\times 3$.

PSEUDOTUMOUR RECURRING IN A SOCKET

Case 18.—A man aged 45 years had had high myopia (–23 D sph.) for 25 years, and for several months the eye had been blind and painful. When proptosis developed the eye was enucleated. This globe showed choroido-retinal degeneration in the posterior segment and an organized fibro-vascular plaque, probably due to organization of a haemorrhage, gave choroido-retinal fusion. Otherwise the eye was normal histologically.

6 months later, because of painful swelling in the socket, tissue was removed. This consisted of delicate fibro-vascular tissue only.

14 months later, recurrence of painful swelling necessitated further tissue removal from the socket. This second mass of tissue was similar to the previous biopsy.

10 weeks later the orbit had refilled with a mass of tissue, now cystic, and exenteration was therefore performed. The orbital tissues contained a large multilocular cyst with a thick fibrous wall containing delicate, oedematous fibroblastic and granulation tissue, cystic cavities, haemorrhages, and areas of intense small round-celled infiltration (Fig. 10). No bacterial, mycotic, or parasitic cause for the granuloma was demonstrable.

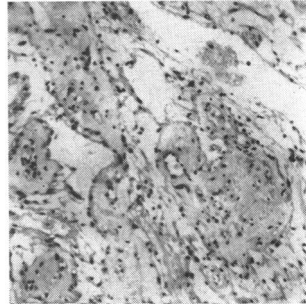


FIG. 10.—*Case 18.* Pseudotumour recurring in a socket. Delicate, oedematous fibrous tissue is lightly infiltrated with chronic inflammatory cells. $\times 80$.

After exenteration, a dermo-epidermic graft of the orbit from the thigh was successfully done. 5½ years after the enucleation, apart from a slight discharge, the orbit was normal and the patient well.

Orbital Lipogranuloma

Much of the remainder of this paper concerns the pathogenesis and aetiology of those orbital pseudotumours which are granulomatous in nature.

Pathogenesis

This is not known to have been described previously, therefore the name orbital lipogranuloma is suggested to distinguish this type from other orbital granulomata of known cause, *e.g.* tuberculosis, sarcoid, syphilis, etc. The pathological changes to be described are those of fat necrosis occurring in orbital tissue with resultant granulomatous infiltration, subsequent fibrous replacement, and eventual degenerative changes.

Fig. 11 shows the normal histological appearance of orbital adipose tissue which is divided into lobules by fibrous connective tissue trabeculae.

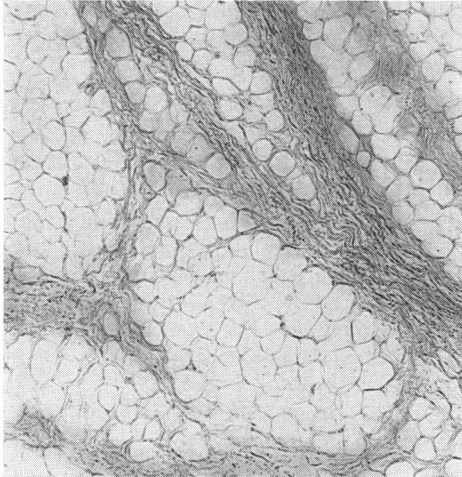


FIG. 11.—Normal adipose tissue of the orbit divided into irregular lobules by fibrous connective tissue trabeculae. $\times 43$.

Several cases in this series had very early exenteration, and Case 19 has been selected to show these typical early pathological changes, unmodified by treatment or surgery.

Case 19.—In 1932 a woman aged 75 years had noticed right proptosis for 1 month. Because of onset of pain in the right eye and forehead, together with diplopia, she was admitted to hospital.

Examination.—There was marked right proptosis, limitation of all ocular movements, marked chemosis, deep scleral injection, and raised ocular tension. The temperature was normal and the Wassermann reaction negative. X rays of her sinuses and antral lavage were normal and, as there was no improvement during observation, exenteration was done. A low-power view of the section is seen in Fig. 12.

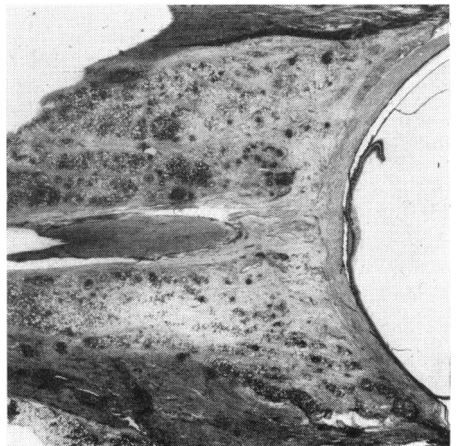


FIG. 12.—Case 19. Low-power view of early orbital lipogranuloma. Haemorrhage is present in the inferior rectus muscle.

HISTOLOGY.—The histology of orbital lipogranuloma, as seen in this and other cases, is now detailed.

Alterations in Orbital Fat.—Under low power (Fig. 13*a*), the orbital fat showed areas of intense necrosis involving almost every fat cell. Under higher power (Fig. 13*b*) destruction of fat cell walls and fusion to form globules was seen.

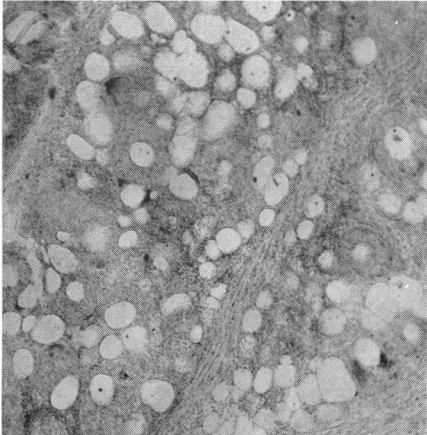


FIG. 13(*a*).—*Case 19*. Area of intense fat necrosis involving most fat cells. $\times 43$.

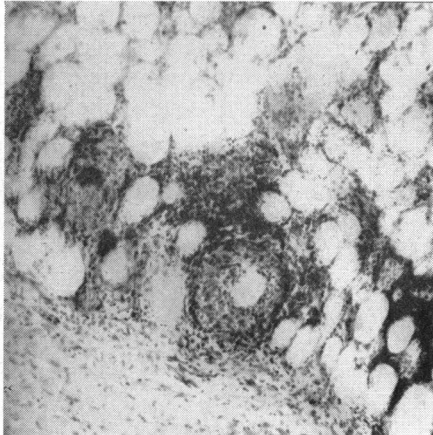


FIG. 13(*b*).—*Case 19*. Fusion of fat cells producing globules. Early nodule formation and some giant cells present. The trabeculae (as seen below) were little affected. $\times 80$.

Fig. 14(*a*) shows early cytological changes of dense infiltration of the fat cells and globules. These cells are neutrophils, eosinophils, numerous large pale epithelioid macrophages, and a few giant cells.

Fig. 14(*b*) shows detail of the area marked in Fig. 14(*a*); there is a central fat space lying within masses of pale macrophages and isolated giant cells. The darker peripheral zone consists of many lymphocytes and a few plasma cells. Figure 14(*a*)

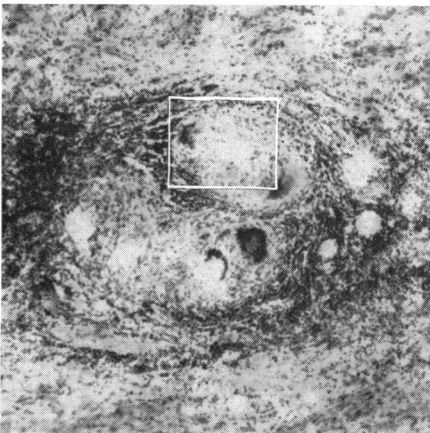


FIG. 14(*a*).—*Case 19*. Formation of nodule. $\times 80$.

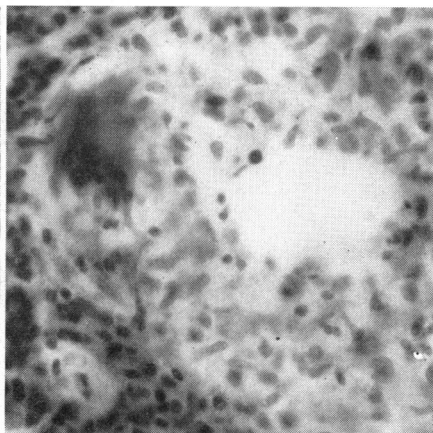


FIG. 14(*b*).—*Case 19*. Detail of same nodule. $\times 384$.

also shows the development of a larger nodule produced by the fusion of two smaller ones.

Elsewhere (Figs 13*a* and 15) foreign-body giant cells are seen which encircle fat cells or lie isolated on the circumference of the fat cell suggesting a local leakage of altered material which has attracted eosinophils and the foreign-body reaction.

Fig. 15 shows detail of the cellular invasion of a fat cell by neutrophils, eosinophils and epithelioid macrophages which lie within the fat space. Peripheral leakage is also occurring as foreign-body giant cells almost encircle the fat space. The giant cells are not only foreign body in type but also of the Langhans type. These latter were also seen in other cases of longer duration as in Fig. 16.

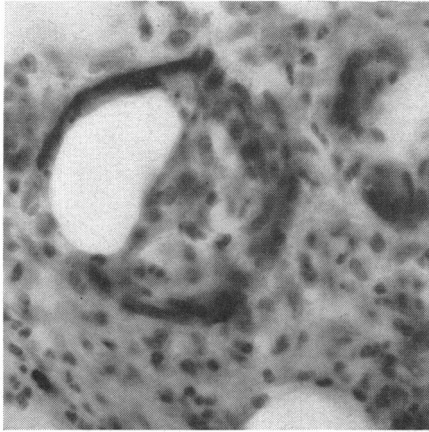


FIG. 15.—*Case 19*. Invasion of fat cell which is encircled by giant cells and invaded by epithelioid cells. Polymorphonuclear leucocytes, eosinophils, plasma cells, and small lymphocytes are also present. $\times 384$.

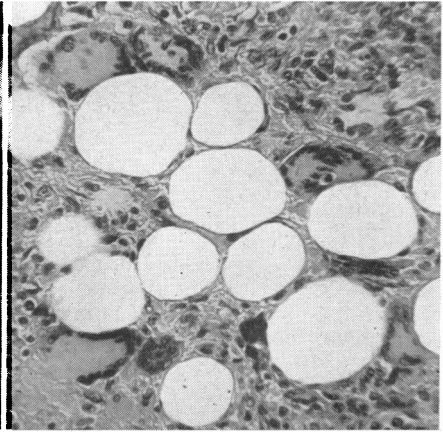


FIG. 16.—Giant cells of the Langhans type in another case of orbital pseudotumour.

Not every fat cell is involved in the earliest stages and, indeed, some may remain unaffected even in the final stages. Away from the above characteristic and prominent changes of fat necrosis, the cytological appearances were modified as cellular infiltration became patchy and fibrous proliferation marked.

As the integrity of the fat spaces was maintained, cellular fusion was not a feature here (Fig. 17).

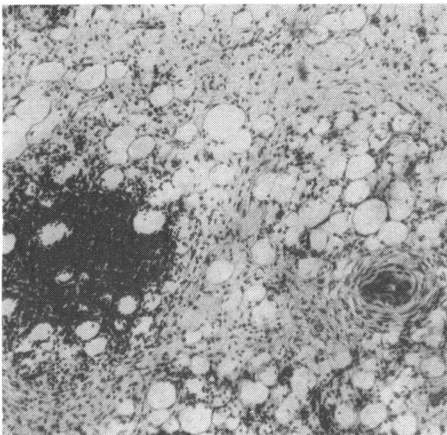


FIG. 17.—*Case 19*. Patchy areas of intense infiltration and moderate fibroblastic activity at periphery of orbital lipogranuloma. Note thick-walled blood vessel. $\times 65$.

In this region the inflammatory cells were predominantly lymphocytes, with some plasma cells and greatly reduced numbers of epithelioid macrophages, so that the localized lesions stained darkly with haematoxylin and eosin. Giant cells, polymorphonuclear leucocytes, and eosinophils were rare in these areas. Where mild fat necrosis was present, fibroblasts were seen in small numbers between individual fat cells.

This milder but chronic and comparatively patchy process was frequently seen in other cases without the intense and typical changes of fat necrosis first described.

Alterations in the Connective Tissue Trabeculae.—The cell content of the fibrous connective tissue trabeculae which divide the adipose tissue into lobules was moderately increased. This cellularity included a few eosinophils and sparse neutrophils, but the predominant content was due to greatly increased numbers of stellate fibroblasts.

Thick trabeculae related to areas of intense fat necrosis contained inflammatory cells which had spread into their outer portion, but their central areas were relatively unaffected by this "overflow" infiltration. However, thin trabeculae in areas of intense fat necrosis were usually heavily infiltrated with inflammatory cells throughout their width.

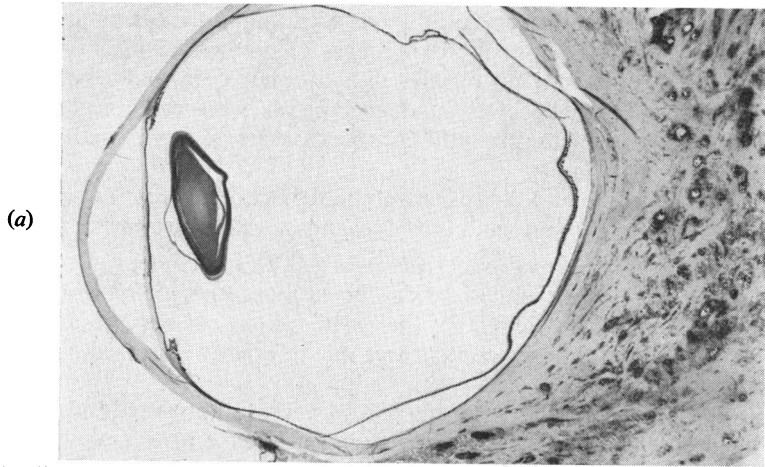Other Changes.—All the patent capillaries showed intense congestion and swelling of the lining endothelial cells, while many were already occluded. These vessel changes were also present in the rectus muscles and in the vessels of the sheaths of the optic nerve, together with small focal perivascular aggregations of lymphocytes and plasma cells. The lumina were crowded with polymorphonuclear leucocytes.

Apart from some increase in the glial content and vessel congestion, the optic nerve was unaffected, as were the smaller nerves. The rectus muscles retained their striations and showed no other signs of degeneration. Haemorrhage was present in one rectus muscle.

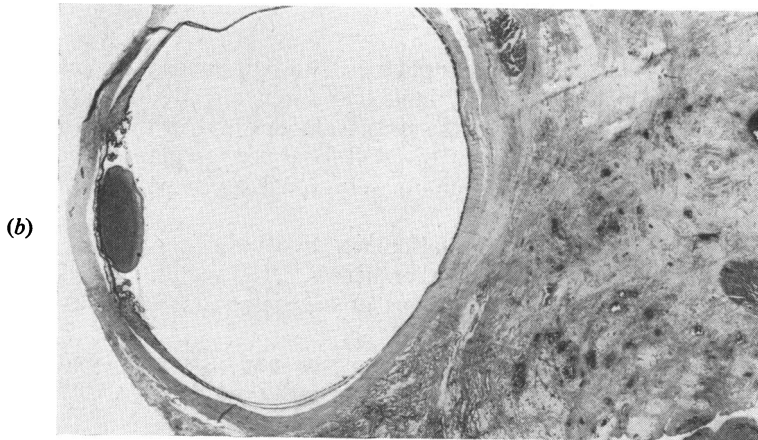
The globe was normal apart from disc oedema and peripheral cystic retinal degeneration. The lacrimal gland showed light diffuse infiltration with lymphocytes and plasma cells.

Late Changes as seen in Other Cases.—The changes of orbital fat necrosis of Case 19, just detailed, were those of a very early lesion. Later changes were seen in cases with longer histories (Fig. 18*a, b, c*, overleaf), indicating that fibroblasts arose, not only from thickened trabeculae and between the fat cells but also from the fibrous dural optic nerve sheath. This contribution from the dural sheath was recognized by Hine (1922), who called his case of orbital pseudotumour an "extra-dural tumour of the optic nerve"; Meadows (1945) used the term "fibromatosis of the optic nerve sheath".

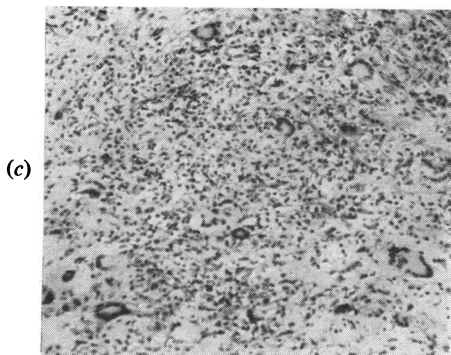
In the course of time the fat necrosis process subsides, the cellular content is reduced to a few lymphocytes, plasma cells, and residual giant cells which lie in a dense fibrous stroma, and fibrous replacement occurs as the cellularity decreases. In the later stages, eosinophils and neutrophils are seldom seen. Only isolated fat spaces in the stroma are left to remind one of the former nature of the tissue reaction. The ultimate changes are shown in Fig. 19 (overleaf), where the inflammation is reduced to sparse chronic inflammatory and giant cells lying in degenerate hyalinized connective tissue.



(a) Fibrous replacement of retro-orbital tissue with chronic inflammatory infiltration.



(b) Extensive fat replacement by dense fibrous tissue.



(c) Langhans' type of giant cells and other chronic inflammatory cells. $\times 80$.

FIG. 18*a, b, c*.—Later changes in lipogranulomatous orbital pseudotumour.

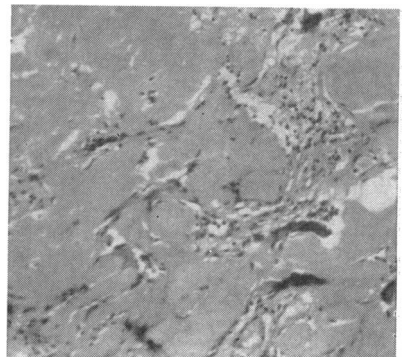


FIG. 19.—Ultimate changes of orbital lipogranuloma. Extensive areas of hyalinization with chronic inflammatory cells and scattered giant cells. $\times 100$.

Six cases in the present study showed this hyalinization of tissue. In two of these, where symptoms were present for only 1 and 2 months respectively before biopsy, the lesion must have lain quiescent until the late stages. But four other patients had symptoms for a minimum of 18 months.

Aetiology

Hirsch (1941) stated that all writers agreed that the lipids released through necrosis of fat tissue stimulated formation of granulation tissue. He described the initial stage as focal necrosis of the fat without haemorrhage or inflammation, and exudates of lymphocytes, leucocytes, and polyblasts appearing about the focus. The fat cell membranes disintegrated, droplets of fat were released into the tissues, and giant cells formed along the margins of the lipid substances.

Beerman (1953) confirmed that the released fat acted at first as a foreign body and added that necrosis of fat tissue was remarkable for its tendency to chronicity, extension, and the development of fibrosis. Regardless of the cause the pathogenesis was the same.

These writers were studying adipose tissue elsewhere in the body, but their observations and conclusions may be applied to the adipose tissue of the orbit.

The eyeball and other orbital structures are cushioned in fat which is thought to be semi-fluid during life (Whitnall, 1932). The orbital fat is closely related to the other orbital contents, to wide areas of periosteum, and to the paranasal sinuses, which have thin and frequently deficient walls, even in the healthy state. A large variety of lesions affecting many structures may thus involve the orbital fat.

In a study such as this, one can only postulate that toxic, anoxic, and other processes in some way alter the fat cells, perhaps by chemical means. The resultant effect is the death, destruction, and disappearance of the fat cells followed by their fibrous replacement.

Beerman (1953) described adipose tissue as extremely fragile. While more robust tissues (*e.g.* muscle, periosteum, etc.) subjected to noxious processes may be interfered with temporarily, their individual cells are not necessarily altered in structure. The process of fat necrosis thus depends on this greater fragility or vulnerability of the fat cells; these may be injured in many ways, but vascular changes and infection appear to be the most significant.

Vascular Changes.—In this series, endothelial proliferation, obliterative endarteritis, and occlusion of veins and arteries have been extremely common histological findings, as seen in Fig. 20*a, b, c* (overleaf). Numerous writers, including Hine (1922), Benedict and Knight (1923), Williamson-Noble (1926), Birch-Hirschfeld (1930), Lewis (1938), Offret, Hermann, and Hervouët (1947), Benedict (1949), Reese (1951), and Ingalls (1953), have described similar pathological vascular changes associated with orbital pseudotumours.

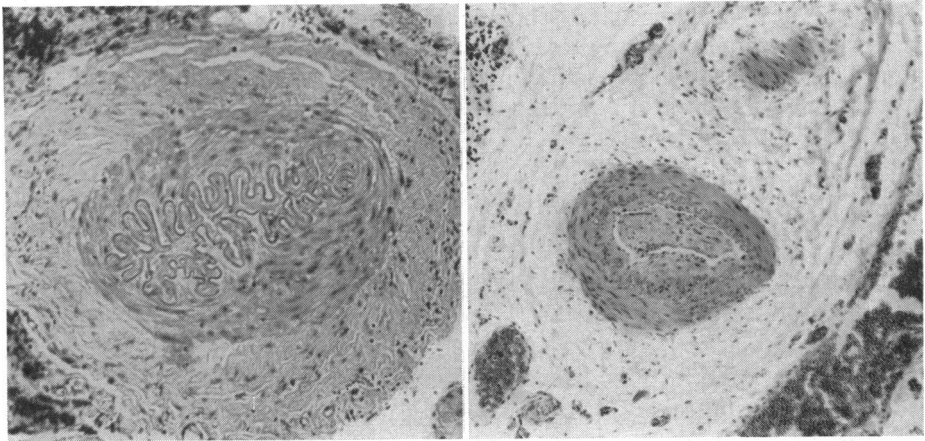
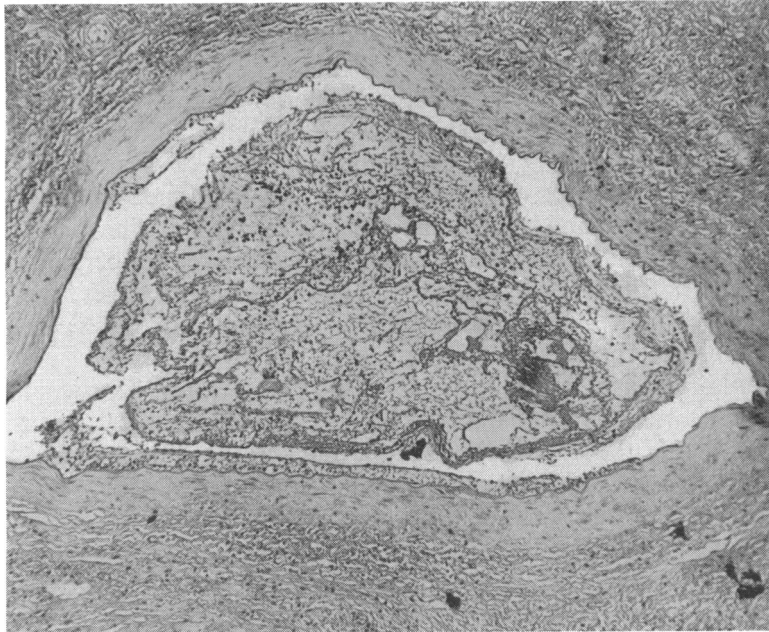
(a) Thickened walls. $\times 120$.(b) Occluded arteriole. $\times 60$.(c) Thrombosed vein. $\times 65$.

FIG. 20.—Vessel changes which occur commonly.

Infection.—The close association between paranasal sinus infection and orbital pseudotumour was illustrated by Cases 7, 8, and 9. This association was also noticed by Panas (1895), Batten (1906), Benedict and Knight (1923), Lewis (1938), Benford and Brunner (1947), and Ingalls (1953). Williamson-Noble (1954) attributed 70 per cent. of cases of orbital inflammation to paranasal sinusitis. The effect of sinusitis on the eye and orbit is acknowledged by our ear, nose, and throat specialists, and Lubart (1958) discussed

the difficulties of demonstrating deep-seated sinus infection, which is frequently asymptomatic, and not necessarily demonstrated by radiological examination.

Local Infective Orbital Lesions.—These may have a direct effect on orbital tissues or an indirect effect from the blood vessel changes which they produce.

Local Toxicity.—This factor was demonstrated by Case 10, in which an orbital pseudotumour resulted from a leaking dermoid cyst.

Focal Infection.—The production of pseudotumours where a verified source of gross infection elsewhere in the body coexisted with the early orbital symptoms was seen in Cases 5 and 6. Occlusion of medium-sized orbital vessels was a conspicuous feature of Case 5.

Retained Foreign Body in Orbit.—In Case 11 retained fragments of wood produced a widespread proliferative orbital lesion. Stallard (1940) and Paufique and Etienne (1952) described comparable pseudotumours produced by retention of a silver style and vegetable matter respectively.

This tendency for fibrous tissue proliferation in the orbit is seen in Case 18, in which there were several recurrences of pseudotumour.

Previous Literature on Orbital Pseudotumours

Many cases of orbital pseudotumour have been reported in the literature over the past century. In the vast majority the aetiology is unknown, and few of the reported cases have been followed over a period of time.

The first account of orbital pseudotumour was that given by Hartung (1845), in a case in which orbital malignancy was also suspected by Flarer and Jaeger. It seems, however, that the inflammatory crises described, which resulted in intermittent proptosis, were probably caused by recurrent attacks of ethmoiditis.

Birch-Hirschfeld (1930) reviewed thirty cases of orbital pseudotumour, including some of his own; he divided them into three groups:

- I. There is clinical evidence of a tumour which subsides spontaneously or following medical treatment with potassium iodide, mercury, arsenic, or quinine (10 cases).
- II. There is exophthalmos and the diagnosis of orbital tumour is made. At operation no tumour is found and microscopy shows only chronic inflammatory tissue (2 personal cases and 9 cases in the literature).
- III. There is exophthalmos and operation shows an abnormal orbital mass which histologically shows a chronic non-specific inflammatory mass containing diffuse follicular areas.

Dunnington and Berke (1943) preferred to subdivide the third group described by Birch-Hirschfeld into:

- (1) Cases in which the extra-ocular muscles were chiefly or primarily involved. They called this chronic orbital myositis.

(2) Cases in which the muscles were spared and the orbital fat affected primarily.*

Reese (1951), in his textbook, illustrated an histological classification consisting of five groups. These groups are chiefly from the late stages of the lesion.

Chinaglia and Santelli (1953) and Paufigue and Etienne (1953) have published papers on the subject in Italian and French with extensive bibliographies.

Orbital pseudotumours have been attributed to a wide range of causes, including endocrine exophthalmos (Hogan and Dickson, 1950), paranasal sinusitis (Williamson-Noble, 1954), orbital cellulitis (Trotter, 1923), syphilis (Hine, 1922), periarteritis nodosa (Hope-Robertson, 1956; Walton, 1959), solitary sarcoid (Benedict, 1949), chronic osteomyelitis (Benford and Brunner, 1947), post-traumatic granuloma of the bony orbit (Ramsey, Laws, Pritchard, and Elliott, 1948), irritation from cholesterol crystals (Williamson-Noble, 1922), "pimple" on the face (Smetana and Bernhard, 1950), dental infection (Benedict and Knight, 1923), and virus infection (Chinaglia and Santelli, 1953), to mention but a few.

Summary

A clinico-pathological survey of 47 cases of pseudotumour of the orbit is reported; many of the cases have been traced over a number of years after pathological diagnosis and some are reported in detail.

Orbital pseudotumour may present, over a variable period of weeks or months, in a subject of either sex from childhood onwards. The patient usually develops proptosis, unless the lacrimal gland region is involved, and may also develop pain, diplopia, irritability of the eye, chemosis, or lid swelling. Ptosis and intra-ocular lesions may occur. A swelling may be palpable in any part of the orbit and the lesion is usually unilateral.

In routine ophthalmological practice, diagnosis is commonly achieved by exclusion, after carrying out ophthalmological, general medical, and otorhinological examinations, urinalysis, blood counts, erythrocyte sedimentation rate, Wassermann reaction, Kahn test, gonococcal complement-fixation test, x ray of orbit and sinuses, basal metabolic rate, and tests for tuberculosis and sarcoidosis.

A positive diagnosis is made by the histological study of an adequate biopsy specimen.

Pseudotumours may resolve spontaneously, or may be treated by surgical removal, steroid therapy, radiotherapy, or a combination of treatments. In the present series sulpha drugs and antibiotics were not helpful.

The prognosis for vision and life are both good. The pseudotumours here reviewed were associated with orbital myositis, endocrine exophthalmos,

* These are the orbital granulomata which are described in the present paper.

sinusitis, foreign body granuloma without known injury, Wegener's granulomatosis (lethal midline tumour), lymphosarcoma with a normal blood picture, or leaking dermoid cyst, or they followed trauma or accompanied fatal subphrenic and perinephric abscesses.

Sixteen cases were of a chronic granulomatous nature. The pathogenesis in these cases is illustrated and discussed. It is shown that the granulomatous infiltration, replacement fibrosis, and ultimate hyaline degeneration are preceded by fat necrosis. This process has not previously been described in the orbit. The name "orbital lipogranuloma" is suggested to distinguish these benign lesions from other granulomata and to establish them as an entity.

This investigation was made in the Pathological Department, Institute of Ophthalmology, University of London, during the tenure of a Shepherd Scholarship.

I am grateful to the Director of Research, Sir Stewart Duke-Elder, for granting me facilities within the Institute.

My thanks are due in particular to Prof. Norman Ashton, Director of the Pathological Department, for his encouragement and discussions during the investigation, and to the large number of clinicians, too numerous to mention by name, for their ready help and co-operation in the follow-up of the patients included in this series.

I am also grateful to Mr. V. J. Elwood and the Medical Illustration Department at the Institute of Ophthalmology for the preparation of sections and photographs and to Miss E. FitzGerald for secretarial help.

REFERENCES

- BARKAN, H. (1938). *Amer. J. Ophthalm.*, **21**, 996.
 BATTEN, R. D. (1906). *Trans. ophthalm. Soc. U.K.*, **26**, 129.
 BEERMAN, H. (1953). *Amer. J. med. Sci.*, **225**, 446.
 BENEDICT, W. L. (1949). *Trans. Amer. Acad. Ophthalm. Otolaryng.*, **54**, 26.
 ——— and KNIGHT, M. S. (1923). *Arch. Ophthalm. (N.Y.)*, **52**, 582.
 BENFORD, M. C., and BRUNNER, H. (1947). *Amer. J. Ophthalm.*, **30**, 297.
 BIRCH-HIRSCHFELD, A. (1930). "Krankheiten der Orbita", in "Graefe-Saemisch Handbuch des gesamten Augenheilk." Band 9, Abt. 1, Teil 1, p. 497. Springer, Berlin.
 BOYD, W. (1953). "A Text-book of Pathology", 6th ed., p. 583. Kimpton, London.
 CHINAGLIA, V., and SANTELLI, F. (1953). *Ann. Ottal.*, **79**, 449.
 COWAN, T. W. (1951). *A.M.A. Arch. Ophthalm.*, **46**, 390.
 DUKE-ELDER, S. (1952). "Text-book of Ophthalmology", vol. 5, p. 5448. Kimpton, London.
 DUNNINGTON, J. H., and BERKE, R. N. (1943). *Arch. Ophthalm. (Chicago)*, **30**, 446.
 FOULDS and WEAR (1961). Personal communication.
 GOLDSMITH, A. J. B. (1945). *Proc. roy. Soc. Med.*, **38**, 599 (in Discussion).
 HARTUNG (1845). *Ann. Oculist. (Paris)*, **14**, 164.
 HINE, M. L. (1922). *Trans. ophthalm. Soc. U.K.*, **42**, 181.
 HIRSCH, E. F. (1941). *Arch. Path. (Chicago)*, **31**, 516.
 HOGAN, M. J., and DICKSON, O. C. (1950). *Trans. Amer. Acad. Ophthalm. Otolaryng.*, **54**, 573.
 HOPE-ROBERTSON, W. J. (1956). *Trans. ophthalm. Soc. N.Z. for 1955*, **8**, 56.
 INGALLS, R. G. (1953). "Tumors of the Orbit and Allied Pseudo-tumors". Thomas, Springfield, Ill.; Blackwell Scientific Publications, Oxford.
 LEWIS, P. M. (1938). *Amer. J. Ophthalm.*, **21**, 991.
 LUBART, J. (1958). *A.M.A. Arch. Otolaryng.*, **67**, 334.
 MEADOWS, S. P. (1945). *Proc. roy. Soc. Med.*, **38**, 597.
 OFFRET, G., HERMANN, P., and HERVOUËT, F. (1947). *Bull. Soc. ophtal. Paris*, p. 49.
 PANAS (1895). *Arch. Ophthalm.*, **15**, 529.
 PAUFIQUE, L., and ÉTIENNE, R. (1953). *Bull. Soc. Ophthalm. Fr.*, p. 398.
 ———, FIMBEL, and MOREAU, P. G. (1952). *Ibid.*, p. 107.
 RAMSEY, G. S., LAWS, H. W., PRITCHARD, J. E., and ELLIOTT, H. (1948). *Canad. med. Ass. J.*, **59**, 206.

- REESE, A. B. (1951). "Tumors of the Eye", p. 522. Hoeber, New York.
- SMETANA, H. F., and BERNHARD, W. (1950). *Arch. Path. (Chicago)*, **50**, 296.
- STALLARD, H. B. (1940). *Brit. J. Ophthal.*, **24**, 457.
- TROTTER, W. (1923). *Trans. ophthal. Soc. U.K.*, **43**, 169.
- WALTON, E. W. (1959). *J. clin. Path.*, **12**, 419.
- WHITNALL, S. E. (1932). "The Anatomy of the Human Orbit", 2nd ed. Oxford Medical Publications.
- WILLIAMSON-NOBLE, F. A. (1922). *Trans. ophthal. Soc. U.K.*, **42**, 189.
- (1926). *Brit. J. Ophthal.*, **10**, 65.
- (1954). *Ann. roy. Coll. Surg. Engl.*, **15**, 46.