

## WAARDENBURG'S SYNDROME\*

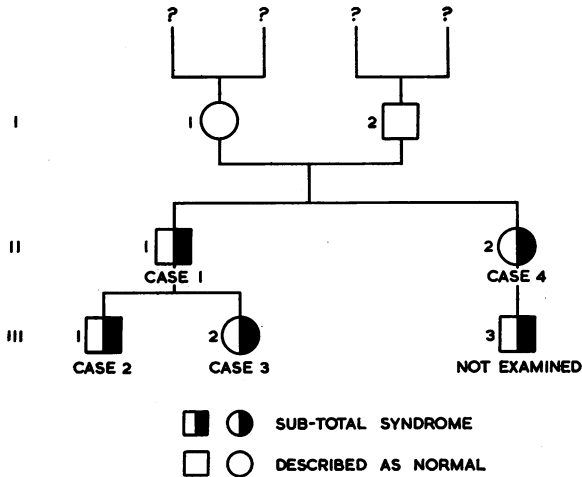
BY

D. K. RAY

*County Hospital, York*

Two children, a brother and sister, were brought to the County Hospital Eye Clinic in March, 1958, on account of diminished visual acuity and peculiar facial features. Their condition was diagnosed as hypertelorism.

On July 11, 1960, their father brought them back to the Clinic for a check-up; I observed a striking distribution of features of Waardenburg's syndrome in the father and children, and the father stated, on further questioning, that his sister and nephew also had the same features. The whole family was examined, with the exception of the baby nephew, and some interesting associated features were also noted.



### Case Reports

**Case 1 (II, 1), the father**, aged 29 years, was emmetropic; the visual acuity was 6/6 each eye unaided, and the fundi were normal. He showed the following physical features: hypertelorism, lateral displacement of medial canthus, broad root of the nose, displacement of puncta, blepharophimosis, hypertrichosis of medial portion of eyebrow, and a mild degree of cleft face showing minimally at the tip of the nose. He was deaf in the right ear.

\* Received for publication November 14, 1960.

**Case 2, a boy aged 5 years (III, 1),** had a small degree of hypermetropia. The visual acuity was 6/12 each eye unaided, and the fundi were normal. He showed the following physical features: hypertelorism, lateral displacement of the medial canthus, broad root of the nose, displacement of puncta, blepharophimosis, and hypertrichosis of medial portion of eyebrow. He was also partially deaf.

An associated feature was an intra-ventricular septal defect.

**Case 3, a girl aged 3 years (III, 2),** had a myopia of 5 D in each eye. The visual acuity of 6/24 each eye with glasses and the fundi were normal. She showed the following physical features: hypertelorism, lateral displacement of the medial canthus, broad root of the nose, displacement of puncta, blepharophimosis, hypertrichosis of medial portion of eyebrow, and heterochromia of the iris.

**Case 4, a woman aged 25 years (II, 2),** had visual acuity 6/6 both eyes, normal fundi, and the following physical features: mild hypertelorism, slight trichosis of the medial eyebrow, and a white forelock.

Her son (III, 3), a baby born in May, 1960, was not seen, but she described him as looking exactly like his cousin (III, 1).

### Summary

A family showing Waardenburg's syndrome is described. They all had normal fundi, and only one member had a visual defect caused by myopia. The syndrome is of embryonic fixation, with inheritance over two generations. There was no evidence of lack of intelligence. There was an intra-ventricular septal defect in one child only.

My thanks are due to Dr. B. Sheehan, Eye Department, County Hospital, York, for allowing me to publish these case reports, and to Prof. A. Sorsby for his suggestions.

### BIBLIOGRAPHY

- SORSBY, A. (1951). "Genetics in Ophthalmology". Butterworth, London.  
WAARDENBURG, P. J. (1951). *Amer. J. hum. Genet.*, 3, 195.