

PARTIAL CYCLECTOMY*

BY

H. B. STALLARD

London

SURGICAL exploration of part of the ciliary body is justifiable when gonioscopic examination shows an extension of a malignant melanoma of the iris posteriorly into the filtration angle and probably into the ciliary body, and also in the case of a malignant melanoma arising in the ciliary body either in an only eye, or when the other eye has grossly defective vision through disease or amblyopia. Indeed the procedure seems reasonable whenever the affected eye still has good vision.

Exposure of the ciliary body may be effected by reflecting either a three-sided scleral flap with a hinge posteriorly (Fig. 1) or two scleral flaps which open like panels (Fig. 2).

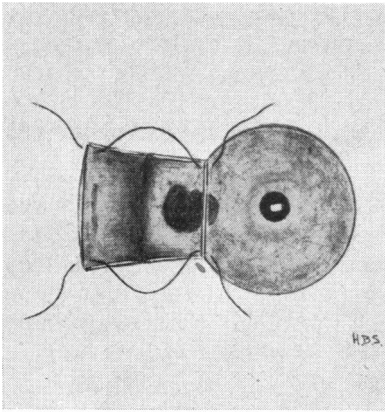


FIG. 1.—Exposure of ciliary body by a three-sided scleral flap.

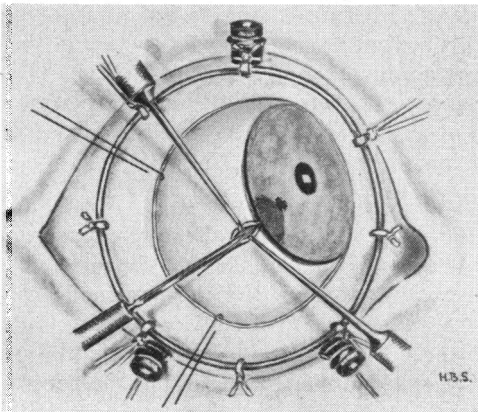


FIG. 2.—Exposure of ciliary body by two scleral flaps opening like panels.

The advantage of the former is its simplicity, but the latter affords slightly

better security through closure of one panel whilst excision of the neoplasm proceeds with the other panel reflected. The anterior incision of the scleral flap or flaps may conform with the limbus, or (as advised by Prof. H. C. Müller at the First North African Seminar, Tunis, 1959) it may pass as a straight line—a chord to a circle—vertically through the cornea about 1 to 2 mm. from the limbus (Fig. 3).

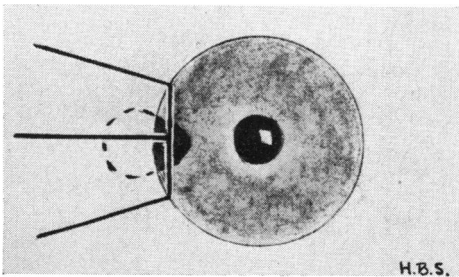


FIG. 3.—Anterior incision through cornea about 1 to 2 mm. from the limbus, with three radial cuts in sclera.

The advantage of the latter route is that it may avoid touching the growth in the filtration angle; its disadvantage is slightly delayed healing compared with that of the limbal incision (Fig. 2) and the risk of epithelial downgrowth into a vertical corneal incision. Müller advises three radial cuts in the sclera (Fig. 3), those on either side of the central incision diverging from the limbus. With this technique the two scleral panels may be reflected in turn posteriorly and closed in turn. Their purpose is to lessen the field of exposure during cyclectomy.

Premedication.—Before operation miosis is necessary.

Anaesthesia.—It is essential to reduce the intra-ocular pressure by Pentothal sodium, curare, and a retro-ocular injection of Xylocaine 2 per cent.

Preparation.—The lids are retracted by Castroviejo's lid screw-clamps. The conjunctiva is incised around the limbus for about half or more of its circumference, undermined as a hood flap, and retracted posteriorly by two traction sutures. Flieringa's ring, useful as a preventive measure against vitreous loss, is placed so that its centre is over the site of the neoplasm. It is sutured at eight sites to the conjunctiva and episcleral tissue. Four of the sutures holding the ring are cut short and four are left long for fixation to the head towel (Fig. 2). The eye, and if necessary the head as well, is turned so that the site of the limbal and scleral incisions lies uppermost.

Double Scleral Flap Incisions.—A radial scleral incision is made from the centre of the limbal incision in the antero-posterior axis of the neoplasm, the edges are retracted by scleral hooks and the incision deepened to the suprachoroidal lymph space. A limbal incision is then made *ab externo* with its centre over the neoplasm and extended for at least 6 mm. on each side of it. Sutures are inserted into the corners and sides of the scleral flaps (Fig. 4) with a stay-knot at one end for quick closure after excision of the neoplasm.

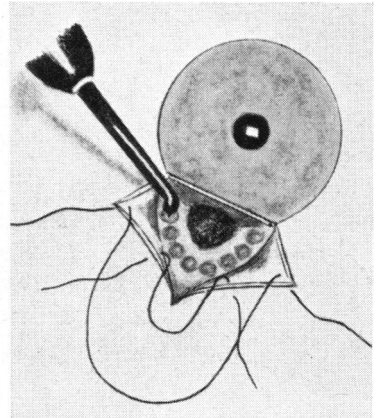


FIG. 4.—Insertion of sutures in scleral flaps, and circumvallation of neoplasm by diathermy.

Diathermy.—If, on reflexion of these scleral flaps or of a single flap, there are signs of pigment in the sclera in the region of the filtration angle this area is touched with a diathermy needle to produce electro-desiccation in any tumour cells.

If the extension into the ciliary body is only about 1 to 2 mm. and comprises a thin sheet of cells, it is, I think, justifiable to attempt the destruction of this small area by electro-desiccation with a fine diathermy needle and then to proceed to a wide iridectomy. If, however, the extension into the ciliary body is more than a thin sheet of cells, then the more formidable operation of partial cyclectomy is indicated. To reduce the risk of intra-ocular haemorrhage laevoglucosan drops are instilled on to the ciliary body and the growth is thoroughly circumvallated with penetrating diathermy (Fig. 4).

If at this stage there is some bulging of the ciliary body, portentous of vitreous prolapse, it is well to aspirate about 0.25 ml. vitreous through a diathermized site over the pars plana in the quadrant opposite to the neoplasm and to replace the aspirated vitreous at the end of the operation. A suture is passed through the edges of the scleral puncture; this is tied temporarily after the vitreous aspiration and is released to allow vitreous replacement at the end of the operation.

Iridectomy with Partial Cyclectomy.—The corneal side of the limbal incision is lifted by a scleral hook and two plane iris forceps are passed through the incision one on each side of the neoplasm (Fig. 5); the iris is then grasped and drawn through the incision where radial cuts are made with de Weckers's scissors from the pupil margin to the iris root on each side of the neoplasm (Fig. 6).

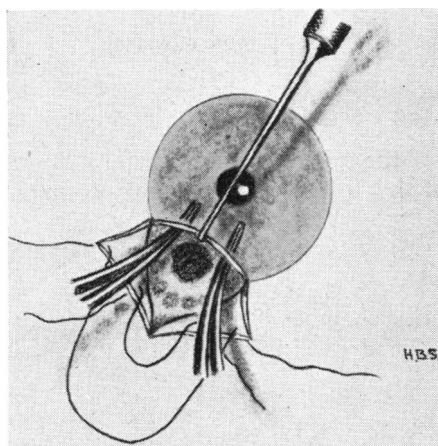


FIG. 5.—Insertion of iris forceps each side of neoplasm.

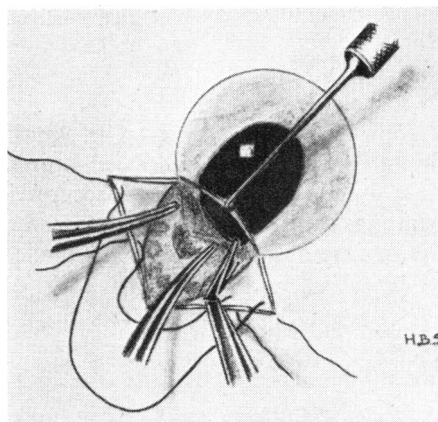


FIG. 6.—Radial cuts with de Weckers's scissors from pupil margin to iris root.

The cut portion of the iris, including the neoplasm, is now held in one pair of forceps whilst the blunt end of one blade of corneal scissors enters the circumlental space to cut the ciliary body through the diathermized zone (Fig. 7, overleaf). It is inevitable that some of the suspensory ligament at this site is severed. Care is taken not to touch the equator of the lens, and if possible to avoid damage to the hyaloid face by lifting the ciliary body from it as the scissors incision is being made. If any bleeding occurs in the line of resection the surgeon, to save delay in changing instruments, holds the tip of the scissors against the bleeding point whilst the

assistant touches the scissors with a coagulating diathermy terminal. It is generally desirable to achieve the partial cyclectomy as expeditiously as possible compatible with the utmost accuracy and care, and to close the scleral flap by pulling on the sutures with stay-knots immediately the neoplasm is withdrawn from the eye.

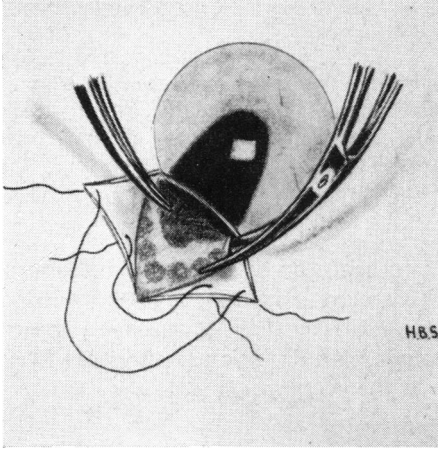


FIG. 7.—Insertion of blade of corneal scissors into circumferential space.

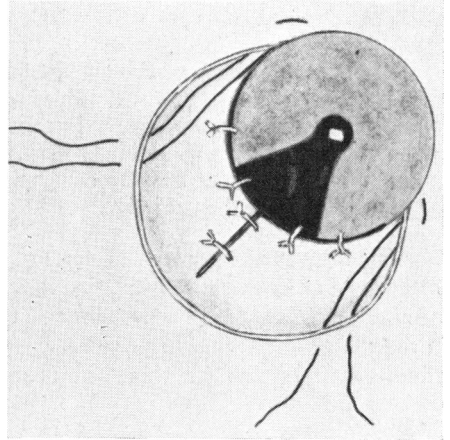


FIG. 8.—Closure of wound.

Closure of the Wound.—The stay-knots of the scleral sutures are now drawn forwards and cut off, and the sutures are tied. It is usually necessary to insert four or more corneo-scleral sutures in the limbal part of the incision (Fig. 8). Mattress sutures are now inserted on either side of the conjunctival hood flap and the first tie of a surgical knot is made in these.

An iris repositor is inserted into the anterior chamber if it is necessary to disentangle part of the iris from the incision. Usually the iris retracts into its proper anatomical place.

Sterile Air Injection.—To keep the vitreous face away from the posterior surface of the cornea, sterile air is injected into the anterior chamber. The fine cannula is passed into one end of the limbal incision until it rests on the anterior surface of the iris, and then the injection of air is made fairly rapidly. If the injection of air is made with the cannula in the iris coloboma and the rate of injection is slow, air may pass behind the iris and so defeat the object of reforming the anterior chamber.

Flieringa's ring is then removed by cutting the eight sutures with a Bard-Parker knife. The conjunctival hood flap is drawn over the scleral and limbal incisions and the mattress sutures in it are tied. Atropine and chloramphenicol ointment are instilled into the conjunctival sac and dressings are applied to both eyes for 48 hours, unless there is some contraindication to binocular occlusion.

Case Reports

The following notes concern four patients with malignant melanoma of the ciliary body spreading to the iris root, who were treated surgically.

Case 1, a woman aged 52, had a malignant melanoma of the choroid 14 mm. in diameter in the right eye (Fig. 9a); the visual acuity was counting fingers in the temporal field only.

There was a malignant melanoma of the ciliary body infiltrating the iris root in the left eye (Fig. 9b), the visual acuity was 6/9 with glasses.

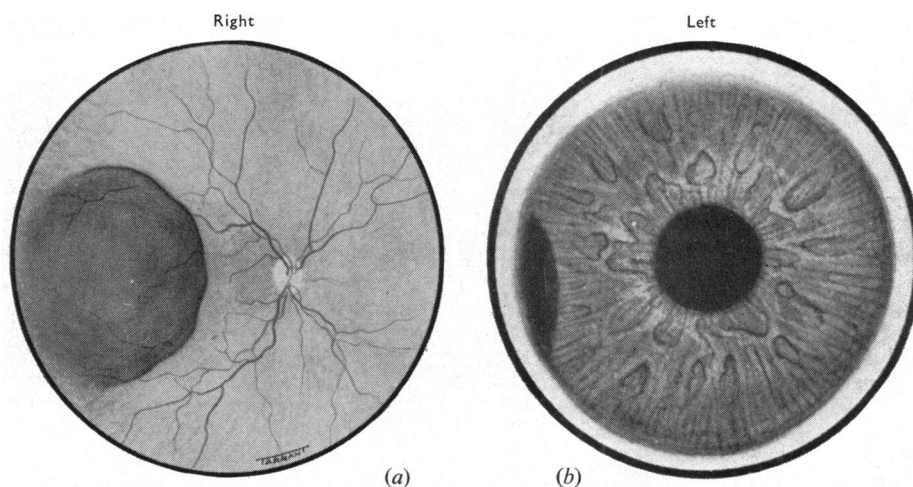


FIG. 9.—Case 1. Malignant melanoma of choroid in right eye (a), and of ciliary body with infiltration of the iris in left eye (b).

The patient was also suffering from disseminated sclerosis.

On August 11, 1959, the right malignant melanoma was treated by a 15-mm. active diameter 3·12 mC. ^{60}Co disk sutured to the sclera over base of neoplasm.

A partial cyclectomy was then performed in the left eye with a hinged scleral flap as in Fig. 1. A line of pigment in the filtration angle was treated with electro-desiccation. The malignant melanoma in the ciliary body was circumvallated with diathermy and after iridectomy the resection was made in the diathermized line.

In the closing stage of the operation there was an anaesthetic embarrassment, the venous pressure in the head and the intra-ocular pressure rose so that about 2 minims of vitreous seeped through the wound and some blood oozed into the vitreous. The vitreous haemorrhage subsequently absorbed.

Case 2, a woman aged 57, had a malignant melanoma of the ciliary body infiltrating the iris root in the upper nasal quadrant of the right eye.

On November 4, 1959, partial cyclectomy was performed. Müller's vertical incision was made as a chord across the upper nasal quadrant about 1 to 1·5 mm. anterior to the limbus. Two corneo-scleral flaps (as in Fig. 2) were reflected, and the neoplasm was circumvallated by diathermy and removed without intra-ocular haemorrhage or vitreous loss. On January 26, 1960, a cystoid cicatrix was evident at the junction of the two corneo-scleral flaps. The visual acuity in the operated eye was 6/9.

Case 3, a woman aged 42, had a leiomyoma of the iris pressing against the posterior corneal

surface in the lower temporal quadrant of the right eye (Fig. 10*a*), but there was no slit-lamp evidence of infiltration of the cornea. Extension into the ciliary body was suspected and was verified at operation.

On May 13, 1960, a limbal incision was made from 5 to 11 o'clock, and from the centre of this a radial scleral incision as in Fig. 2. Fig. 10*b*) shows the result after operation. The visual acuity in the right eye was 6/6 (pt) with -0.75 D sph., $+3$ D cyl., axis 135° .

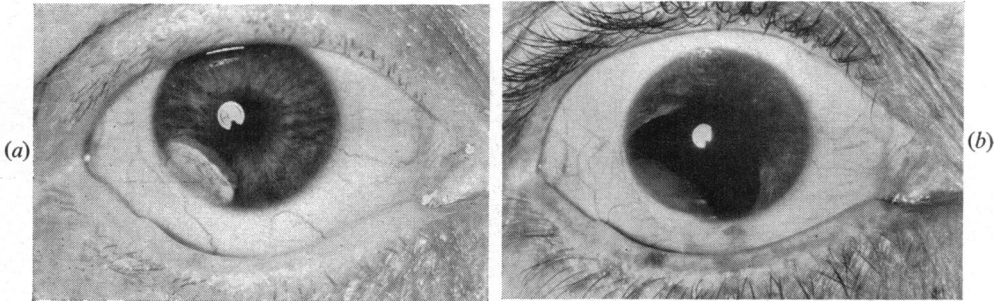


FIG. 10.—Case 3. Leiomyoma of iris and ciliary body (*a*). Post-operative appearance (*b*).

Case 4, a woman aged 25, had a malignant melanoma of the ciliary body and iris in the lower nasal quadrant of the left eye. The neoplasm was exposed by the technique shown in Fig. 2. After reflecting the scleral flaps, there was some portentous bulging of the ciliary body. 0.25 ml. vitreous was aspirated through a diathermized site over the pars plana of the ciliary body in the upper temporal quadrant. The scleral puncture was closed by a suture tied temporarily. After partial irido-cyclectomy and closure of the incisions, the scleral suture in the upper temporal quadrant was released to allow replacement of the aspirated vitreous and was tied again after the needle was withdrawn.

After operation the vitreous remained clear and the visual acuity with correction was 6/6 (partly). Fig. 11 shows the post-operative appearance.

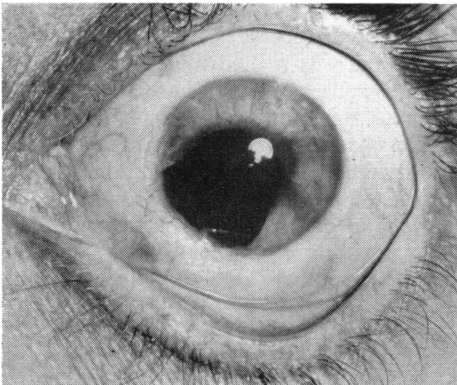


FIG. 11.—Case 4. Malignant melanoma of ciliary body and iris root in left eye. Post-operative appearance.

Summary

The indications for partial cyclectomy, and important technical points designed to prevent, in particular, vitreous loss and intra-ocular haemorrhage are discussed. The details of four patients, so treated, are given.

I thank Mr. S. J. H. Miller for referring Case 4 to me, and Dr. P. Hansell of the Medical Illustration Department of the Institute of Ophthalmology for the photographs.