

GONIOPLASTY IN GLAUCOMA*

A PRELIMINARY REPORT

BY

VITO LA ROCCA

New York, U.S.A.

“GONIOPLASTY” is the name given to a new surgical procedure which may be used in different forms of glaucoma: a plastic tube (made of polyvinyl) is inserted sub-sclerally to carry the aqueous from the anterior chamber to the sub-choroidal and sub-Tenon’s spaces.

The successful implantation of a similar tube in a case of buphthalmos in 1957 was announced in 1958 at the International Congress of Ophthalmology in Brussels (La Rocca, 1959). This patient had previously been treated unsuccessfully with goniotomies and diathermy (Case 1); in this and in five other cases, the tube was inserted subconjunctivally, but the technique has now been modified and has achieved such impressive results in adult cases of glaucoma that it promises to replace the old filtration operation. Goniotomy is not a Seton operation like those in which various materials were used to keep open a drainage channel surgically made (Qadeer, 1954); if such operations had been successful they would still be in use, but they now seem to be often regarded only as surgical curiosities.

In goniotomy, the drainage is accomplished through a U-shaped tube, which carries the aqueous from the anterior chamber into the sub-choroidal and sub-Tenon’s spaces like an aqueduct; there are no sutures to cause irritation or obstructive scar tissue, or to become the source of exogenous infection.

The operation is performed without iridectomy and without trauma to the lens, and this lessens the risk of traumatic cataract. The patency of the tube is guaranteed because the amount of connective tissue formation is negligible. As in the case of acrylic lenticular implants (Ridley, 1951, 1954; Strampelli, 1953; Bietti, 1955), the plastic material causes no electrolytic reaction when in contact with human serum. Bietti told me of the encouraging success obtained in 1953 by implanting a single tube of polyethylene into the opening of a regular cyclodialysis, the tube being fixed to the sclera with sutures. One of my early attempts (Case 1) failed because the suture cut through the conjunctiva so that the tube was displaced and later had to be removed. The principal advantage of the goniotomy and the U-shaped tube is that it can be fixed without sutures. All the cases reported below

* Received for publication August 27, 1961.

had had surgery, including goniotomy, goniotomy, goniotomy, iridencleisis, and diathermy.

Technique

First Method

This method, which has now been superseded, was used in several of my early cases. Except in the very first case of all, a pouch of folded conjunctiva was prepared at the upper part of the globe. The purpose of the pouch was to bring the epithelial layer in contact with the episclera and so to avoid any adherence of the conjunctiva to the globe. Next a puncture and a counterpuncture were made at the limbus at 1 o'clock and 11 o'clock respectively, and the U-shaped tube of polyvinyl was introduced into the anterior chamber, the external openings being lodged in the prepared conjunctival pouch, which was then sutured to the conjunctiva of the fornix.

Gonioplasty

Under general anaesthesia, the conjunctiva is sectioned 2 mm. from the limbus and parallel to it in the upper and temporal quadrant between the superior rectus and the lateral rectus. The conjunctiva is dissected towards the fornix, removing a piece of Tenon's capsule, exposing the sclera for a distance of about 8 mm. Two traction sutures are passed, one each side of the incision under the superior and lateral rectus, and these sutures are tied to the lids of the speculum to obtain a good fixation of the globe and a clear exposure of the sclera.

With a trephine 1 mm. wide, two discs of sclera 2 mm. apart from each other are removed at a distance of 6 to 7 mm. from the limbus (Fig. 1). In the enlarged eyes of congenital glaucoma, the site of application of the trephine is determined by the width of the abnormal limbus, as the trephining has to be done behind the ciliary body at the level of the pars plana; 8 mm. is usually a safe distance.

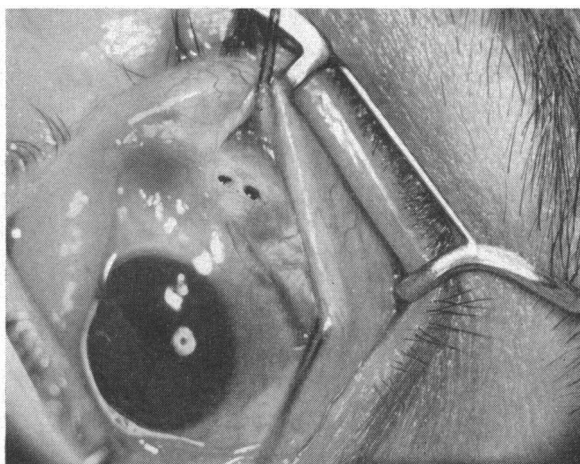


FIG. 1.—The superior and lateral recti are tied to the speculum. Two discs of sclera are removed with a trephine 1 mm. wide.

A small slanting incision is made with a cataract knife in the little bridge of sclera that remains between the two trephinings, but without penetrating the full thickness of the sclera. This groove prevents the tube from slipping backwards. A spatula 1 mm. wide is introduced by way of the trephine openings so as to reach

the anterior chamber, but no side turns are made as in cyclodialysis; this is in order to avoid a large detachment of the ciliary body, the possibility of haemorrhage, and trauma on an already weak zonule which could lead to subluxation of the lens. Usually little or no aqueous is lost through this manoeuvre and no haemorrhage occurs.

The polyvinyl tube is then removed from a solution of Zefiran in which it has been kept for 24 hours. The tube is held in the U-shaped position on the two prongs of a special holder (Fig. 2), and its length is compared with that of the sub-scleral tunnels (Fig. 3).




FIG. 2.—La Rocca's gonioplasty tube-holder (made by Storz & Co., Chicago, Ill.) and polyvinyl U-shaped tube. (a) Polyvinyl tube; two branches 6 mm. long joined by a bridge 2 mm. long. (b) Gonioplasty tube-holder.

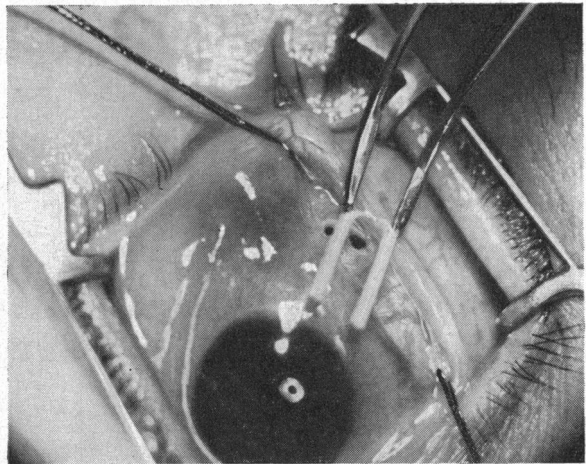


FIG. 3.—Tube is held by holder and its length compared with that of sub-scleral tunnel.

When the length has been measured satisfactorily, the tube is slipped through the two scleral openings and into the tunnels made by the spatula (Fig. 4, opposite), care being taken to follow the inner surface of the sclera. When the anterior chamber is reached, the holder is slowly withdrawn, thus allowing a slow escape of the aqueous and avoiding a sudden collapse of the eye. The bridge of the tube is settled into the groove between the two trephinations and air is injected through the tube into the collapsed anterior chamber with a No. 30 needle (Fig. 5, opposite). The wound is covered with conjunctiva, and is closed with three 6-0 silk sutures passed close to the limbus to avoid scarring at the drainage site.

Atropine 2 per cent. may then be safely instilled and a dressing with cortisone and antibiotics is applied.

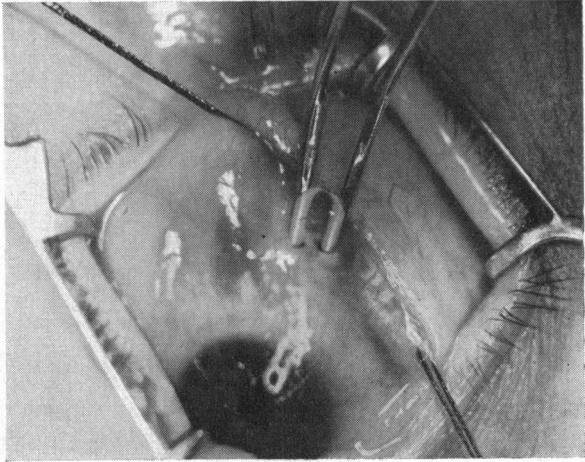


FIG. 4.—Tube is pushed into sub-scleral tunnel to reach anterior chamber without touching cornea.

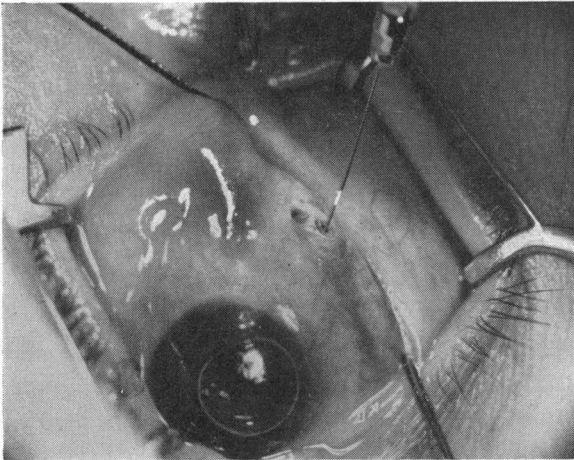


FIG. 5.—Bridge of tube half-buried in slot. Air is injected into the anterior chamber.

Instruments

One polyvinyl B.D.O. 039 442 T tube bent to a U-shape and cut to make two branches, each 6 mm. long, connected by a thin bridge about 2 mm. long (Fig. 2).* The tube is sterilized by keeping it in Zephiran solution for 24 hours before use. Two extra tubes should be kept sterilized in reserve.

La Rocca gonioplasty tube-holder
(Fig. 2).†

Eye speculum, preferably Arruga's.

Cataract knife.

Very sharp trephine 1 mm. wide.

Spatula 1 mm. wide.

Scissors, forceps, two traction sutures,
three 6-0 silk sutures.

Air-needle No. 30.

Hildreth cautery to mark spots on
sclera for trephining.

* Tubes ready for the implant can be obtained from: B. Gargano Plastics, 2 River Road, West 232nd Street Riverdale, New York.

† Made by Storz & Co., Chicago, Ill.

Case Reports

Case 1, a white boy of Italian extraction, was first seen in New York on January 4, 1957, at the age of 5 months.

Examination.—The left eye presented a striking example of advanced hydrophthalmos, a distended globe protruding from the orbit, with photophobia and pericorneal injection. The cornea was 16 mm. wide in the horizontal diameter with striae of ruptured Descemet's membrane, and it was so cloudy that a cataractous lens was not discovered until after the third operation. The ocular tension was very high and instillation of glycerine failed to clear the cornea.

The right eye was quiet, but showed a macrocornea 13 mm. wide in the horizontal diameter; the cornea was clear with a deep anterior chamber. The pupil was small, no fundus details were seen, and the tension was moderately raised.

A diagnosis was made of bilateral congenital glaucoma, far advanced in the left eye.

Treatment.—The patient was admitted to the New York Eye and Ear Infirmary on February 4, 1957. With the help of another surgeon more experienced in these cases, bilateral goniopunctures were performed, but the tension rose again on the following day.

The patient was re-admitted on May 19, 1957, and I performed a perforating cyclo-diathermy on the left eye with two rows of applications, one halfway around the ciliary body, but the tension still did not fall.

On October 5, 1957, he was again admitted and, with the consent of his mother, who had given up hope of cure by the accepted methods, the first implant of a U-shaped polyvinyl tube was made, but without a conjunctival pouch. The medial part of the tube was anchored to the episclera with a silk suture, which had to be removed a few days later because it had perforated the conjunctiva. However, the results seemed encouraging because the cornea became somewhat clearer, the eye was quiet all the time, and the tension was lower. A few days later, owing to the extreme difficulty in examining the patient, I had the impression that the tension was rising again and advised the mother to massage the eye through the upper lid. Because of these manipulations the tube became displaced; the boy was re-admitted on October 26, 1957, and the operation was then performed again, but with the conjunctival pouch, as described above under "First Method". The tube was introduced from the lower part of the limbus because the repeated operations and diathermy had made the conjunctiva in the upper part too friable for dissection.

Result.—The eye then showed great improvement, the tension fell to normal, and the patient was presented for the first time to a clinical conference of the hospital staff. He has been examined periodically, and on December 2, 1960, over 3 years later, the eye was quiet, the cornea clear, the tube still in place, and the tension normal. A gratifying surprise in this case is that, since the tension was made normal in October, 1957, there has been a remarkable reduction in the size of the globe and in the depth of the anterior chamber, showing that a certain degree of reversibility of the distension of the tissues is possible when a cure is effected in the early stages.

Case 2, a girl from Favignana, Italy, was first seen in New York on February 6, 1959, at the age of 9 months.

Examination.—The left eye had been operated upon 6 months previously, probably with trephining or iridectomy. It was greatly distended, with complete corneal opacity, peripheral injection, and photophobia. The ocular tension was extremely high to digital palpation. No details of the media or fundi were visible.

The right eye showed a macrocornea 13 mm. wide in the horizontal diameter, the anterior chamber was deep and the pupil small, and the fundus reflex present; no attempt was made to dilate the pupil for better examination of the fundus. The tension was slightly increased to digital palpation. A diagnosis was made of buphthalmos in the left eye and macrocornea in the right.

The patient was admitted on February 16, for examination under general anaesthesia. The ocular tension was found to be 35 mm. Hg (Schiötz) in the right eye and 90 mm. Hg in the left.

Treatment.—A cyclodialysis was performed in the right eye and the tension in this eye has since been normal.

On March 4, 1959, a polyvinyl tube was introduced into the lower part of the limbus in the left eye, using the "First Method". At the first dressing 24 hours later, the tube was well in place and the tension lower, and though the cornea was somewhat clearer a cyclitic membrane covered the entire pupillary area. The patient was put on penicillin and the conjunctival wound healed normally. On March 16, she was re-admitted for iridocapsulotomy which was performed on the upper part, but because the opening was found to be inadequate on March 23 the eye was re-opened as in a cataract extraction, and most of the membrane was dissected and removed.

Result.—When last seen in June, 1960, the eye was quiet, and the tension normal, but the cornea still showed a deep central opacity.

Case 3, a boy aged 8 years from New Jersey, was first seen in New York on February 20, 1959. The parents reported that the boy had been operated upon when 7 days old by goniotomy and goniopuncture in both eyes, and that this had been repeated several times until he was 4 years old.

Examination.—Diagnosis was made of bilateral congenital glaucoma. The corneae were very opaque and the ocular tension high.

Treatment

RIGHT EYE: A tube was introduced into the lower part of the limbus on February 27, 1959, using the "First Method". Healing was uneventful and the tension became normal. The cornea became slightly clearer and the vision improved from perception of light to counting fingers at 5 feet. When the patient was seen on June 11, 1960, the eye was quiet with the tube in place, and the tension normal. The cornea was still opaque and a corneal transplantation is to be considered in the future.

LEFT EYE: The patient was re-admitted to the New York Eye and Ear Infirmary on August 16, 1959, for an implant into the upper part of the limbus by the "First Method". The operation was uneventful and the ocular tension and vision improved, but on September 8 the tube was found to be displaced and was removed under local anaesthesia. The eye remained quiet, however, and a new implant using the sub-scleral gonioplasty technique is being considered.

Case 4, a boy aged 7 years from Corleone, Italy, was seen on May 1, 1959, in Italy.

Examination.—The right eye was normal and the left showed a buphthalmos with the cornea not too opaque, but with striae of ruptured Descemet's membrane.

Treatment.—The patient was admitted on May 26, 1959, to the Ospedale San Giovanni in Rome, where an implant into the left eye was performed following the "First Method". As soon as the cataract knife was withdrawn after the puncture and counterpuncture, the lens became subluxated into the anterior chamber, and fluid vitreous emerged from the corneal openings. The tube was introduced with difficulty and had to be removed 10 days later because it had become displaced. The patient was discharged with a quiet eye but with lens material still present in the anterior chamber.

Case 5, a boy aged 4 years from Brooklyn, was first seen in New York on April 12, 1959, with bilateral congenital glaucoma and intense photophobia.

Examination.—The ocular tension was very high in the right eye, with complete opacification of the cornea, and perception of light doubtful.

The left eye was blind, with a staphyloma and corneal vascularization.

Treatment.—The patient was given cortisone and Diamox for about 5 months, and on September 28, as both eyes were quieter, an implant was attempted into the right eye, but the tube was removed on October 25 because the irritation continued in spite of medical treatment.

Case 6, a boy aged 6 years from Italy, with bilateral congenital glaucoma, was first examined in New York on October 28, 1959.

Examination.—The left eye was soft, and the lens was displaced into the vitreous, with retinal detachment and vitreous in the anterior chamber.

In the right eye the ocular tension was high, but the cornea was not too cloudy, and perception of light was present.

Treatment.—The patient was admitted to the New York Eye and Ear Infirmary on November 15, 1959, and a sub-scleral gonioplasty of the right eye brought the tension down to normal.

Result.—The eye remained quiet and the patient recovered normally and was discharged after one week with visual acuity 10/200.

Case 7, a man aged 52 years from Port Jefferson, Long Island, was first seen in New York on December 19, 1959. The right eye was blind and the visual acuity in the left eye was 20/40 with correction. The patient had been a diabetic for the past 20 years, and had had bilateral iridectomies for acute glaucoma in December, 1957, and cataract extraction in the right eye in June, 1959. He was using di-isopropyl-fluorophosphate in the right eye and Daranide by mouth.

Examination.—The left eye showed iridectomy and lens changes, with normal tension; the right eye had absolute glaucoma, aphakia, anterior synechiae, bullous keratitis, and rubeosis iridea, with very high tension.

The patient had been advised by several consultants to have the right eye enucleated, but he was reluctant to take such a step. From December, 1959, to April 10, 1960, he was kept under observation, and was then admitted to the New York Eye and Ear Infirmary for right sub-scleral gonioplasty, on the understanding that if there was no improvement an enucleation had to be performed.

Treatment.—He was operated on under general anaesthesia and an implant was inserted into the upper temporal quadrant.

Result.—He was discharged in 5 days with a quiet, soft eye, much clearer cornea, and absence of ocular pain and headache. When last seen on March 11, 1961, the eye was quiet and the tension normal.

Case 8, a man aged 58 years from Brooklyn, had been treated with miotics and Diamox for chronic simple glaucoma in the right eye, which had been diagnosed in February, 1959.

Examination.—The ocular tension varied from 35 to 40 mm. Hg, while the visual fields and acuity steadily deteriorated.

Treatment.—On May 1, 1960, he was admitted to the New York Eye and Ear Infirmary for right sub-scleral gonioplasty.

Result.—The recovery was uneventful, and the tension at the last examination on June 11, 1960, was 18 mm. Hg (Schiötz). He had taken no drugs since the operation.

Case 9, a girl aged 4½ years from Vittoria, Sicily, had had bilateral congenital glaucoma diagnosed in Italy on May 13, 1957. She had had a goniopuncture and goniotomy in

the left eye and on May 31, 1957, in the right eye. Cyclodiathermy had been performed in the right eye on March 18, 1958, and in June, 1959, the eye was found to be atrophic. The tension in the left eye was 59 mm. Hg, and the cyclodiathermy was repeated.

Examination.—She was first seen by me in Italy in June, 1959, when the tension of the left eye was normal, though the eye had been very much irritated by the recent diathermy. I advised the parents that nothing could be done as long as the tension was normal and the eye was not quiet. On March 16, 1960, the child was brought to New York. The right eye was completely atrophic, while the left was quiet and the tension 45 mm. Hg (Schiötz), with total opacity of the cornea and the visual acuity reduced to hand movements at 12 in.

Treatment.—The patient was admitted to the New York Eye and Ear Infirmary on March 23, 1960, and a sub-scleral gonioplasty in the upper temporal quadrant of the left eye was performed under general anaesthesia. The corneal oedema having disappeared at the end of the operation, it was possible to see a pupillary membrane with some calcified lens matter covering the pupil.

Result.—The tension is now perfectly normal, with no sign of irritation, and the child sees and recognizes large objects. If no complications arise, an irido-capsulotomy is contemplated in a year or so, entering the anterior chamber from the lower part of the limbus. The patient is being kept on local cortisone therapy and 40 per cent. glucose ointment, in the hope of clearing the corneal opacities.

Case 10, a woman aged 56 years, was first seen on June 7, 1960, when she had been under the care of another ophthalmologist for the previous 8 months for chronic glaucoma of the right eye. She had used pilocarpine 2 per cent. and at other times prostigmine 5 per cent. four times a day.

Examination.—The visual acuity was 20/100 in the right eye and 20/50 in the left. The ocular tension was 34 mm. Hg in the right eye and 20 mm. Hg in the left. Fundus examination revealed a glaucomatous cupping in the right eye with contraction of the visual fields and an enlarged blind spot.

Treatment.—The patient was put on pilocarpine with eserine and Diamox and was seen regularly until October 22, 1960, when the tension in the right eye had risen to 45 mm. Hg, the visual fields were reduced, and the visual acuity 20/200. She was admitted to the New York Eye and Ear Infirmary on October 23 and gonioplasty was performed on the right eye under general anaesthesia.

Result.—She was discharged after 5 days with the tension below normal and 2 weeks after the operation the right eye was perfectly quiet (Fig. 6).

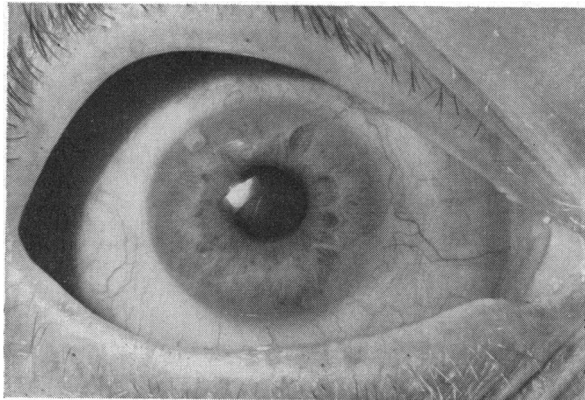


FIG. 6.—Case 10, chronic simple glaucoma in the right eye, 2 weeks after gonioplasty. The tension before operation was 45 mm. Hg (Schiötz) using miotics, and is at present below normal without medication. One of the branches of the U-shaped tube seen at 11 o'clock was pushed forward purposely to see if the contact with the iris would cause iritis—no aqueous flare was noticed at any time.

Case 11, a woman aged 53 years, was first seen in New York on December 17, 1960.

Examination.—The visual acuity was 20/25 in the right eye and 20/40 in the left, and the ocular tension was 20 mm. Hg in the right eye and 42 mm. Hg in the left. The ophthalmoscope showed a moderate glaucomatous cupping with displacement of the retinal vessels in the left eye. The contracted visual fields confirmed the diagnosis of chronic simple glaucoma.

Treatment.—With various miotics, the tension never fell below 30 mm. Hg, and the patient was therefore admitted to hospital on January 17, 1961, for sub-scleral goniotomy.

Result.—She was discharged after 5 days with a soft and quiet eye. Cortisone was used topically.

Case 12, a boy with cerebral palsy, aged 8 years, had been diagnosed as suffering from congenital glaucoma when 7 weeks old. Bilateral goniotomy and goniotomy had been performed at 3 months and left iridencleisis and right goniotomy at 11 months.

Examination.—On February 16, 1961, the ocular tension was normal in the left eye but raised in the right. The right cornea was hazy and measured 12 × 13 mm. No fundus details were seen because of bilateral lens opacities.

Treatment.—On March 6, 1961, a right goniotomy was performed by implanting a U-shaped tube 8 mm. long into the upper temporal quadrant.

Result.—Recovery was uneventful, and the patient was discharged after 5 days with a quiet and soft eye. Prednisolone is still used topically.

Case 13, a girl aged 9 years, had a normal left eye, but congenital glaucoma had been diagnosed in Italy in the right eye, and a goniotomy had been performed when she was 4 years old.

Examination.—The right cornea and ocular media were clear. The fundus showed advanced glaucomatous cupping and atrophy. The tension was very high and the corneal diameter 15 × 15 mm. The eye was quite blind.

Treatment.—On March 9, 1961, right goniotomy was performed successfully.

Result.—She was discharged after 6 days with a soft eye and moderate hyphaema. Prednisolone was used topically.

Case 14, a man aged 69 years, had an atrophic eye following several unsuccessful operations for chronic glaucoma. The left eye was also glaucomatous, and had been treated since 1954 with various miotics to which Diamox three times daily had recently been added.

Examination.—The visual acuity in the left eye was counting fingers at 5 ft, the ocular tension 40 mm. Hg, and the visual fields restricted. The pupil was miotic with sclerosis of the lens. No fundus details could be seen.

Treatment.—A sub-scleral left goniotomy was performed on June 27, 1961.

Results.—Recovery was uneventful. The ocular tension was 12 mm. Hg on December 12, 1961, and the visual acuity was 20/200. No medication was used.

Summary of Results in Fourteen Cases (see Table, opposite)

Congenital Glaucoma.—Five out of nine cases (ten out of six eyes) were operated on by the "first" method. In Case 3 (left eye) the tube became displaced and was removed, and Case 5 the tube had to be removed and the operation abandoned. In Case 4 the lens subluxated with vitreous loss

TABLE
RESULTS IN 14 CASES (15 EYES)

Case No.	Sex	Age	Eye	Diagnosis of Glaucoma	Gonioplasty Operation		Result
					Eye	Method	
1	M	5 mths	Both	Congenital; far advanced in left eye	Left	(1) "First" method. Implant of U-shaped tube without conjunctival pouch	Tube displaced
						(2) "First" method with conjunctival pouch. Tube inserted into lower part of limbus	After 3 years tube in place and tension normal
2	F	9 mths	Both	Congenital; worse in left eye	Left	(1) "First" method into lower part of limbus (2) Iridocapsulotomy (3) Cataract extraction	Tension normal but with corneal opacity 14 months later
3	M	8 yrs	Both	Congenital	Right	"First" method into lower part of limbus	Eye quiet and tension normal 16 months later
					Left	"First" method into upper part of limbus	Tube displaced and removed after 3 weeks, but eye quiet
4	M	7 yrs	Left	Congenital	Left	"First" method. Subluxation of lens and vitreous loss	Tube displaced and removed after 10 days, but eye quiet and tension lower after 18 months
5	M	4 yrs	Both	Congenital (left blind)	Right	Implant by "first" method	Tube removed after 4 weeks because of irritation
6	M	6 yrs	Both	Congenital (left blind)	Right	Gonioplasty	Tension normal, visual acuity 10/200
7	M	52 yrs	Right	Blind with diabetic keratitis and glaucoma	Right	Gonioplasty	Eye quiet with normal tension after 1 year
8	M	58 yrs	Right	Chronic simple	Right	Gonioplasty	Tension normal and eye quiet
9	F	4½ yrs	Both	Congenital	Left	Gonioplasty	Tension normal. Visual acuity improved
10	F	56 yrs	Right	Chronic simple	Right	Gonioplasty	Tension below normal and eye quiet
11	F	53 yrs	Left	Chronic simple	Left	Gonioplasty	Eye quiet and soft
12	M	8 yrs	Both	Congenital	Right	Gonioplasty	Eye quiet and soft

continued overleaf

TABLE—*continued*

Case No.	Sex	Age	Eye	Diagnosis of Glaucoma	Gonioplasty Operation		Result
					Eye	Method	
13	F	9 yrs	Right	Congenital	Right	Gonioplasty	Eye quiet and soft
14	M	69 yrs	Both	Chronic simple	Left	Gonioplasty	Tension normal. Visual acuity improved

and the tube became displaced and was removed. In Cases 1, 2, and 3 (right eye) the tube remained in place and the ocular tension became normal.

The other four cases (6, 9, 12, and 13) were operated on by sub-scleral gonioplasty and the tension was lowered with no complications.

All nine patients had previously undergone iridectomy, goniotomy, gonio-puncture, cyclodiathermy, or a combination of two or more procedures.

Absolute Glaucoma.—Case 7 had diabetes with aphakia, iridectomy, rubeosis iridis, anterior synechiae, and bullous keratitis. Gonioplasty brought the tension down to normal and the eye has remained quiet for more than a year.

Chronic Simple Glaucoma.—Cases 8, 10, 11, and 14 were treated successfully with sub-scleral gonioplasty.

Summary

In spite of efforts to save a higher percentage of glaucomatous eyes from blindness, our present medical and surgical procedures are inadequate, so that the majority of congenital cases and also those secondary to diabetic rubeosis end in blindness and enucleation.

In the last few years, I have observed many cases of glaucoma treated by diathermy, and it is my impression that this method either does not work or works too much, causing cataracts and atrophy of the globe.

The fistulizing operations still give the best results, but often need to be repeated and are often followed by the formation of cataracts.

The first implants of polyvinyl tubes into the anterior chamber and sub-conjunctival spaces were only partially successful, but they demonstrated the possibility of introducing into the eye a foreign body that caused no reactions. Two failures showed the importance of fixing the tubes without sutures, to safeguard the eye from exogenous infections.

Gonioplasty, the implant of a U-shaped polyvinyl tube into the sub-scleral space by the method described, is a safe and easy procedure carrying no risk of complications, the presence of the tube being well tolerated in every case.

Although this is a preliminary report, some of the patients were operated on over 4 years ago, and all have retained normal ocular tension, the poly-vinyl tube causing no irritation to the eye.

REFERENCES

- BIETTI, G. B. (1955). *Acta ophthal. (Kbh.)*, **33**, 337.
——— (1959). Personal communication.
LA ROCCA, V. (1959). "XVIII Concilium Ophthalmologicum, Belgica, 1958."
QADEER, S. A. (1954). *Brit. J. Ophthal.*, **38**, 353.
RIDLEY, H. (1951). *Trans. ophthal. Soc. U.K.*, **71**, 617.
——— (1954). *Brit. J. Ophthal.*, **38**, 156.
STRAMPELLI, B. (1953). *Atti Soc. oftal. Lombarda*, **8**, 292.