

NEMATODE ENDOPHTHALMITIS DUE TO *TOXOCARA**

BY

ANTOINE REY

Curepipe Road, Mauritius

CASES of endophthalmitis due to invasion of the eye by migrating larvae of *Toxocara canis*, the common round worm of the dog, have been reported by Irvine and Irvine (1959), Harris (1961), and Duguid (1961a, b), while five of the 46 cases reported by Wilder (1950) as nematode endophthalmitis were later identified by Nichols (1956) as being caused by *Toxocara*. Ashton (1960) described four cases of retinal granuloma due to *Toxocara canis*. A further example of this disease occurring in the remote island of Mauritius is here reported.

Case Report

A Chinese boy aged 8 years, from Reunion Island, complained of loss of vision of the right eye over a period of one year, and another oculist had already advised enucleation.

Examination.—In February, 1961, there was no perception of light in the right eye. The tension was digitally raised, but the eye itself was not tender on palpation. The conjunctiva appeared healthy whilst the cornea was bright. The pupil was inactive and the iris normal in appearance. After dilatation of the pupil with homatropine, a white mass with a pinkish area on its surface was seen in the vitreous through a clear lens. The coloration seemed to be due to new vessel formation. Transillumination was generally poor, but especially defective nasally.

The left eye with a visual acuity of 6/5 and Jaegar 1, appeared healthy in all respects.

Treatment.—Since retinoblastoma could not be excluded, the eye was enucleated and sent to the Department of Pathology, Institute of Ophthalmology, University of London.

Pathology (Copy of report by Prof. Norman Ashton)

Macroscopical Examination.—The eye was opened horizontally to show a funnel-shaped retinal detachment with an abundant subretinal albuminous exudate. No intra-ocular new growth was seen (Fig. 1, opposite).

Microscopical Examination.—The main pathological feature was a total retinal detachment with massive subretinal exudation; the folded, degenerate retina had come to lie behind the lens, to which it was adherent through a dense fibrous membrane infiltrated with chronic inflammatory cells in which numerous eosinophils were present. The uvea showed little abnormality, although there was one small inflammatory focus at the base of the iris on one side. A small quantity of exudate was present in the anterior chamber, but the filtration angles were patent and there were no peripheral synechiae. The lens was normal. In three of the 114 serial sections examined (Nos. 94, 95, 96), a well-defined inflammatory focus was found within the cyclitic membrane immediately behind the centre of the lens, which consisted centrally of necrotic fibrinoid material surrounded by a zone of epithelioid cells and a dense inflammatory reaction containing a very high

* Received for publication January 1, 1962.

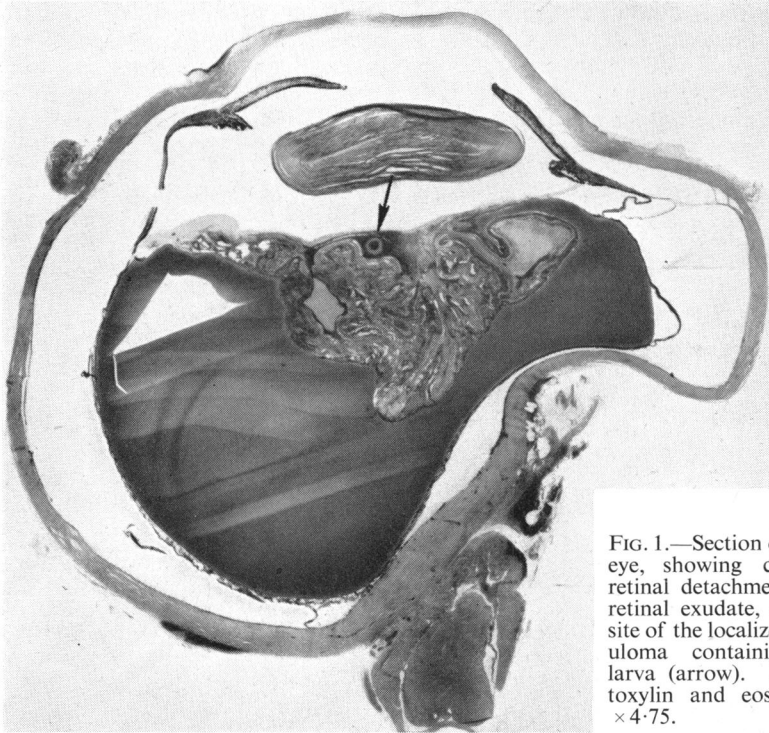


FIG. 1.—Section of whole eye, showing complete retinal detachment, sub-retinal exudate, and the site of the localized granuloma containing the larva (arrow). Haematoxylin and eosin. $\times 4.75$.

proportion of eosinophils. Within the inflammatory focus a cross-sectioned fragment and a small longitudinal fragment of a *Toxocara* larva were found (Figs 2 and 3).

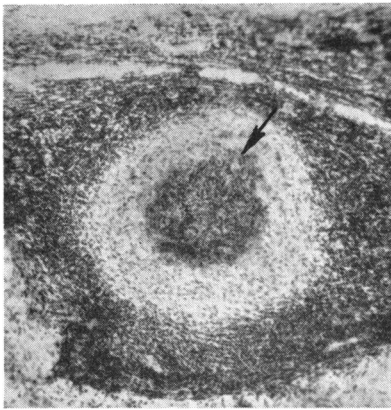


FIG. 2.—Larval fragment (arrow) lying in a well-defined inflammatory focus, consisting of a central area of fibrinoid necrosis, surrounded by a zone of epithelioid cells and lymphocytes. Haematoxylin and eosin. $\times 73.5$.

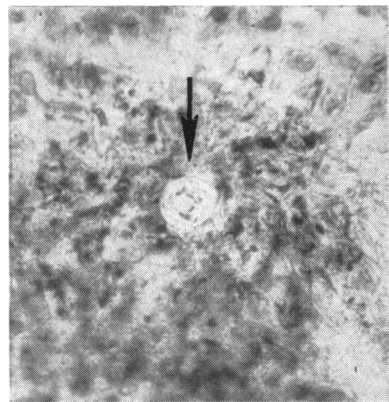


FIG. 3.—High-power view of cross-sectioned larval fragment (arrow) in central necrotic zone. Haematoxylin and eosin. $\times 440$.

Follow-up.—In view of these findings the patient was traced (with great difficulty as he had left Mauritius for Reunion Island), and again examined, 4 months after the enucleation. The differential blood count then showed an eosinophilia of 22 per cent. (white blood cells: 10,000 per cu.mm.), there was no history of fever, jaundice, pulmonary or neurological symptoms, nor of any previous illness; the patient had, however, been in contact with puppies, dogs, and cats.

My thanks are due to Professor Norman Ashton for the pathological report on this case.

REFERENCES

- ASHTON, N. (1960). *Brit. J. Ophthalm.*, **44**, 129.
DUGUID, I. M. (1961a). *Ibid.*, **45**, 705.
——— (1961b). *Ibid.*, **45**, 789.
HARRIS, WALDRON (1961). *Ibid.*, **45**, 144.
IRVINE, W. C., and IRVINE, A. R., (1959). *Amer. J. Ophthalm.*, **47**, No. 5, pt. 2, p. 185
NICHOLS, R. L. (1956). *J. Parasit.*, **42**, 349; 363.
WILDER, H. C. (1950). *Trans. Amer. Acad. Ophthalm. Otolaryng.*, **55**, 99.