

for his help and keen interest in this paper, and to Dr. B. Mitterstein, First Assistant of the Ophthalmological Department. We are furthermore indebted to Dr. Hilde Rosenburger for the drawings in Figures 2-5.

LITERATURE

1. ZONDEK, B. and BROMBERG, Y. M.—*Jl. of Allergy*, Vol. XVI, pp. 1-16, 1945.
2. ——— In press.
3. GALLOWAY and GOVADLY.—*Proc. Roy. Soc. Med.*, Vol. XX, p. 408; *cit. f. DUKE-ELDER*, Text-book of Ophthalmology, Vol. II, p. 1721.
4. RYLE and BARBER.—*Lancet*, Vol. XI, p. 1195, 1920; *cit. f. DUKE-ELDER*, Text-book of Ophthalmology, Vol. II, p. 1721.
5. HALLOPEAU, H.—*Handbuch der Haut- und Geschlechtskr.* Berlin, Julius Springer, 1932.
6. CONNERS, C. A., ECKHARDT, R. E. and JOHNSON, L. V.—*Arch. Ophthalm.*, Vol. XXIX, p. 958, 1943.
7. JOHNSON, L. V. and ECKHARDT, R. E.—*Arch. Ophthalm.*, Vol. XXIII, p. 899, 1940.
8. FISH, W. M.—*Amer. Jl. Ophthalm.*, Vol. XXVII, p. 354, 1944.
9. WISE, G.—*Amer. Jl. Ophthalm.*, Vol. XXVI, p. 291, 1943.
10. SULZBERGER, M. B. and COPE, E. P.—*Jl. Lab. Clin. Med.*, Vol. XXVI, p. 1403, 1941.
11. DUKE-ELDER.—Text-book of Ophthalmology, Vol. II, p. 1726, Ed. London, H. Kimpton. 1943.
12. THIEL, R.—*Klin. Monatsbl. f. Augenheilk.*, Vol. CVIII, p. 394, 1939.
13. LIEBENBERG, H. S.—*Amer. Jl. Ophthalm.*, Vol. XXVI, p. 307, 1943.
14. ELSCHNIG, A.—*Arch. f. Ophthalm.*, Vol. LXXVI, p. 509, 1919.
15. WOODS, A. L.—*Arch. of Ophthalm.*, Vol. XVII, p. 283, 1917.
16. VERHOEFF, F. H. and LEMOINE, A. N.—International Congress of Ophthalmology, Washington, 1922. William F. Pile Co., Philadelphia, 1922.
17. FRIEDENWALD, J. S.—*Amer. Jl. Ophthalm.*, Vol. XVII, p. 1008, 1934.
18. APPELBAUM, A.—*Arch. of Ophthalm.*, Vol. XXIV, p. 820, 1940.
19. GOODMAN, E. L.—*Arch. of Ophthalm.*, Vol. XIV, p. 90, 1935.

SOME OBSERVATIONS ON THE SYMPTOMATOLOGY AND DIAGNOSIS OF CASES OF PROPTOSIS *

BY

PROFESSOR HANDOUSA BEY

CAIRO

I HAVE had to examine and treat a large number of cases of proptosis, most of them referred to me by the various ophthalmic centres in Egypt. Study of the records of these cases reveals some valuable points worthy of publication.

The types of cases that I have come across, fall into the following categories:—

- 1.—Cases of Extra-Orbital Causation.
- 2.—Cases of Intra-Orbital Causation.
- 3.—Cases due to disease of the bony wall of the orbital cavity.

* Received for publication, October 18, 1946.

1.—Extra-orbital cases

These were mainly of nasal origin and inflammatory in nature. The frontal and ethmoid para-nasal sinuses were the main primary sites and usually the spread took place in an acute case or during an acute exacerbation on top of a chronic one.

Nasal trauma, mucocoeles, pyocoeles and neoplasms, were not uncommon causes.

Maxillary sinus infection in my cases has never been seen to give rise to proptosis unless the related anterior ethmoid is infected too, a point indicative that the infection has spread from the latter.

Nasal neoplasms causing proptosis were mainly malignant, affecting the ethmoid and maxillary regions. They were either carcinomata, sarcomata, or endotheliomata, with 4 cases of osteoclastomata and 3 cases of adamantinomata.

Nasal neoplasms of simple nature causing proptosis were mainly osteomata. I had only four cases of ethmoid fibromata and two ethmoid haemangiomata.

Nasopharyngeal tumours, whether simple or malignant have been commoner causes of proptosis than usually supposed, a point that stresses the importance of examining the nasopharynx in cases of proptosis of vague causation.

2.—The Intra-orbital category

I included under this heading all the cases in which the causative lesion has started inside the orbital cavity.

These were 31 in number, grouped as follows:—

1. *Inflammatory*—(a) One case of amyloid change in the orbital tissues round the globe, most probably secondary to chronic suppuration around the teeth and in the maxillary antra.

(b) One case of syphilitic change in the orbital contents on both sides, associated with enlargement of the parotid and submaxillary salivary glands simulating Mikulicz's disease.

2. *Cysts*—(a) Intra-orbital dermoids related to the upper eye-lid region.

(b) Retention cysts of the lacrimal gland.

(c) Haemorrhagic cyst of the lacrimal gland.

(d) Parasitic cysts—2 cases of hydatids. One lying inside the muscle cone and one lying outside it related to the orbital floor.

3. *New-growths*—These were the commonest in this category, (23 cases out of 31), 6 were simple, in the nature of fibromata, fibro-lipomata, rhabdo-myoma and lymph-angiomata: The malignant types were sarcomata, carcinomata, endotheliomata and one case of xanthoma. The carcinomata and endotheliomata were all arising from the lacrimal gland, the xanthoma was most probably arising from the tendon of the superior oblique muscle.

3.—Cases due to a disease of the bony wall of the orbital cavity

These were the least common among my group of cases and may be grouped as follows:—

1. *Traumatic*—One case of old fracture of the left maxilla that resulted in a large gap in the floor of the left orbit with the formation of an extensive arterio-venous varix, which pressed on the left globe and induced proptosis on stooping down.

2. *Inflammatory*—(a) Pyogenic, of the nature of osteomyelitis (acute and chronic) of the orbital wall.

(b) Tuberculous abscesses, and gummatous formations of the orbital wall.

3. *New Growths*—I have one case of capillary angioma of the frontal bone causing right proptosis, a very rare condition.

Study of the symptomatology of these cases shows that in spite of varying degrees of proptosis and eyeball deviations, diplopia is exceptionally complained of. I thought at first that this may be because the patients were more concerned with the bulge of the eye but I directed their attention while being under investigation in hospital to the possibility of seeing double; still this was not complained of except very rarely. Twenty successive patients were carefully tested, only in two diplopia was reported.

As regards diagnosis of the underlying cause of proptosis, I should like to stress that pitfalls with serious consequences are very likely unless careful history taking, systematic local and general examination is carried out in a routine manner, assisted by the various radiological and laboratory investigations. Many demonstrative examples can be given; I have among my cases, patients that were referred to me as having sarcomata of the orbit, with local clinical signs, suggestive of malignant disease, but simple careful history taking made me doubtful and with systematic investigation, these cases proved to be inflammatory. Inflammatory masses in the orbit may closely simulate malignant disease in many clinical aspects.

I have met with few but very valuable points in radiological study of my cases which are worth special consideration. These are:—

1. The pathological lesion in middle and posterior ethmoiditis may spread towards and into the orbital cavity giving rise to proptosis at the same time not presenting any clinical evidence intra-nasally. Even in some of these cases X-ray examination in the classical positions may prove to be negative. However, if this is repeated in various other positions, definite radiological signs may be found to indicate the site of the disease in the ethmoid. I have had two such cases which were considered clinically and radiologically negative for sinus disease and the cause of the proptosis was not then determined. Interest and patience in repeating the X-ray examination cleared up the diagnosis of ethmoiditis.

Fig. 1. is an X-ray which is very definite of left ethmoiditis with thickened bone was only arrived at after repeated negative trials in a case of proptosis.

2. Comparative X-ray study of both orbits has indicated or defined the site of the underlying cause of proptosis in many a case of obscure origin.

I shall stress here only two points—

(a) The presence of an X-ray shadow of the tumour mass.

(b) The presence of an X-ray shadow of the primary orbital dilation.

(a) With appropriate technique not only bony but also soft tissue masses can be demonstrated deep in the orbital cavity. I have cases in which the radiologist has succeeded even in demonstrating the shadows of both eye-balls in normal cases.

This fact was made use of in demonstrating tumours lying far back in the orbital cavity, not palpable or demonstrable otherwise, and is always worth a trial.

X-ray shadows of bony masses are well known; shadows given by soft tissue masses have been of two types: dense and light.

Dense shadows when present were always diagnostic of the underlying cause of proptosis. Fig. 2 is a demonstrative example of such a dense shadow. This patient is an old exophthalmic goitre case in which appropriate treatment resulted in great diminution of his exophthalmos with fall of his B.M.R. from (+45 to -7). It was noticed about one year later that his right eye-ball was again proptosing gradually. Investigations were negative as to the cause, but with careful radiological investigation and comparing both orbits a shadow could be seen in the right orbit (Fig. 2). This on exploration proved to be a rhabdomyoma, removal of which resulted in cure.

Light shadows show as veiling particularly over the orbital periphery. They were always found to correspond with the congested and oedematous orbital tissues and so they demonstrate secondary manifestations and not the primary cause of the proptosis. Fig. 3 is an example of such a shadow.

(b) Orbital dilatation has been seen to be produced by many extra- and intra-orbital lesions. For descriptive purpose may I term the former secondary and the latter primary dilatation. In my experience there has been no difficulty in differentiating one from the other.

As an example of secondary dilatation I refer to the X-ray (Fig. 4), in which the dilatation has been demonstrable in the film to be due to a communication between the orbital cavity and the dilated ethmoid. On the other hand X-ray (Fig. 3) shows simple orbital dilatation which is not due to any communication with neighbouring cavities, hence the term "primary dilatation."

Primary dilatation has been found consistent with the presence of an intra-orbital lesion and fully justifies exploration.

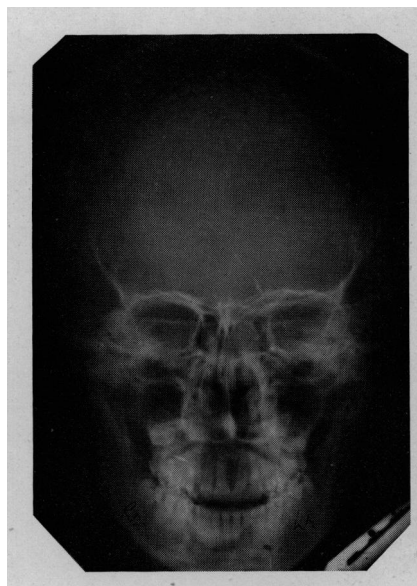


FIG. 1.

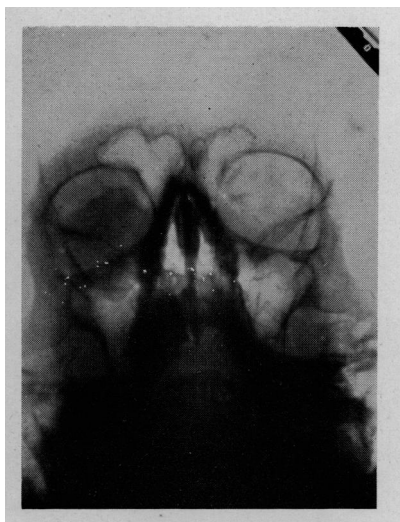

FIG. 2.

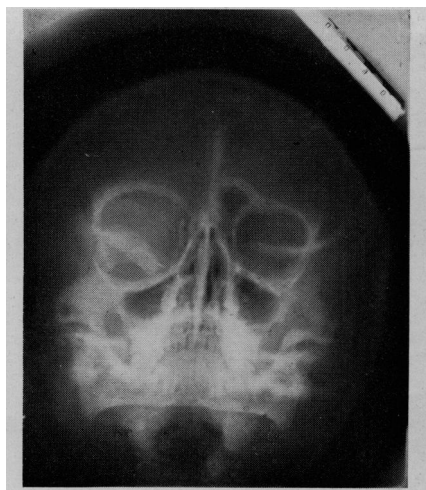


FIG. 3.

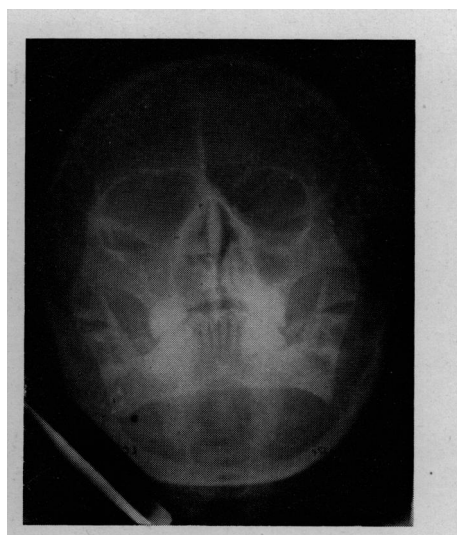

FIG. 4.

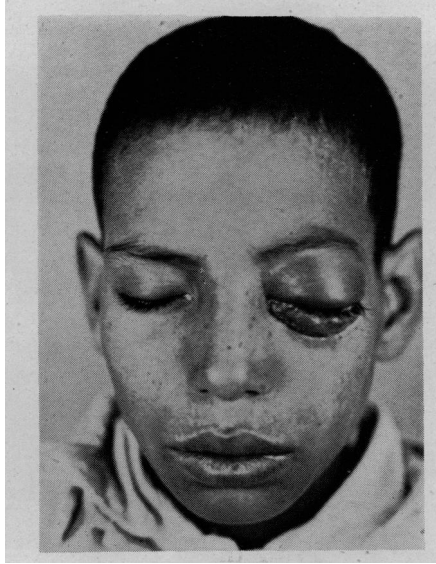


FIG. 5.

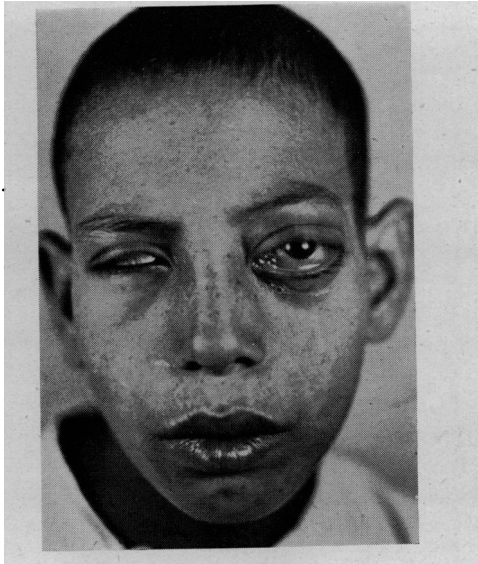

FIG. 6.

This sign was positive in 16 cases out of 21, and was the only evidence of intra-orbital tumour, a case in which a deep fibroma was found and removed on exploration.

It was negative in the following cases, all of which had other diagnostic signs:—

1. One case of osteoma of the ethmoid bone which was lying superficially and was palpable.

One case of myoma.

Both these gave definite X-ray shadows that were diagnostic.

2. One case of fibro-lipoma.

One case of ? Mikulicz's disease.

One case of endothelioma of the lacrimal gland.

In these three a mass could be palpated.

So these radiological findings may be of immense diagnostic value in obscure cases and justify exploration if need be.

Therapeutic tests: have been to me of great value in certain cases and so I feel they deserve trial if need be.

I had a case of a palpable mass in the left orbit firmly adherent to the bone and completely fixing the globe. The clinical signs were very suggestive of a new growth. This patient had an empyema of the left maxillary antrum with left ethmoiditis. On repeated punctures the eye condition improved considerably in 3 weeks. (Compare Fig. 5 and Fig. 6). With sinus treatment the patient was cured. This case demonstrates clearly the value of the therapeutic test (antral puncture).

There are other cases who had a positive Wassermann reaction—anti-syphilitic treatment resulted in resolution of the eye condition and saved major surgical intervention.

Exploration and biopsy has to be finally resorted to in obscure cases.

It has been my routine in any case where the lesion looked malignant on exploration to have a biopsy done before attempting to do radical operations. My case of amyloid disease demonstrates the wisdom of this conservatism. In this case all the appearances during exploration were suggestive of malignancy. If radical treatment was attempted straight out he would have lost the remaining bit of vision in that eye, a vision that is very much needed to him as he has a nebula on the opposite cornea.

Even if, on exploration, malignancy is certain, biopsy alone should be done as it determines the type of malignant disease present; a point which is of the utmost help in planning the line of treatment.

Cyst puncture: As a diagnostic aid has been advised and carried out by many. I am of opinion that it should not be freely done, as aspiration of the cyst contents not only makes the operation of complete cyst removal difficult, but also the procedure of puncture in itself may spread the disease in cases of hydatid cysts and breaking down malignant tumours.

I thank Prof. Sorour Bey and Dr. Hashem for their work on the pathology of my cases. I feel greatly indebted, too, to our expert radiologists, particularly Dr. Nissim Abou Saif and Dr. A. Marey for their valuable radiological study of these cases. I would like to express my deep gratitude to Dr. A. Barbary and Dr. Louis Labib who have assisted me in the operative work and have carried out a large part of the investigations, also to Dr. Ibrahim Mossalem, who has done the drawings, and to Sayed Ibrahim Eff, who has typed this paper.

THE INFLUENCE OF INTRA-OCULAR PRESSURE ON THE RATE OF DRAINAGE OF AQUEOUS HUMOUR, STABILIZATION OF INTRA-OCULAR PRESSURE OR OF AQUEOUS FLOW? * †

BY

ERNST H. BÁRÁNY

UPPSALA (SWEDEN)

I.—Introduction

THE problem of the stabilization of intra-ocular pressure has aroused much interest. There are theories postulating reflex regulation of some kind or other. These have been critically examined elsewhere (Bárány, 1946 *a*). On the other hand, there are two theories, namely those of Duke-Elder and of Friedenwald and Pierce, which put the burden of stabilization on the mechanism of aqueous outflow.

Based on his elegant determinations of intra-scleral venous pressure in the dog, Duke-Elder (1926) has proposed a "safety-valve action" theory of the aqueous drainage mechanism. According to this theory, the pressure relations between the anterior chamber and the drainage channels are such as to prevent any flow of aqueous at normal intra-ocular pressure. When the intra-ocular pressure is raised, however, the pressure relations are reversed and become favourable for drainage of the aqueous. It is obvious, that any drainage mechanism which permits an increase of aqueous outflow with increasing intra-ocular pressure will, in a certain sense, tend to stabilize the intra-ocular pressure. The efficiency of a mechanism in stabilizing intra-ocular pressure depends on the slope of the curve relating aqueous flow to pressure. If the mechanism is efficient, even a small change in pressure will cause a large change

* Received for publication, December 10, 1946.

†The radio-active sodium used in the experiments was kindly furnished by Prof. Manne Siegbahn, Research Institute for Physics, Stockholm.