

Quantitative computed tomography imaging in chronic obstructive pulmonary disease

Lalita Fernandes, Yasmin Fernandes¹, Anthony Menezes Mesquita

Departments of Pulmonary Medicine and ¹Radiology, Goa Medical College, Goa, India

ABSTRACT

Chronic obstructive pulmonary disease (COPD) is a heterogeneous disease having small airway inflammation, emphysema, and pulmonary hypertension. It is now clear that spirometry alone cannot differentiate each component. Quantitative computed tomography (QCT) is increasingly used to quantify the amount of emphysema and small airway involvement in COPD. Inspiratory CT guides in assessing emphysema while expiratory CT identifies areas of air trapping which is a surrogate of small airway inflammation. By constructing a three-dimensional model of airways, we can also measure the airway wall thickness of segmental and subsegmental airways. The aim of this review is to present the current knowledge and methodologies in QCT of the lung that aid in identifying discrete COPD phenotypes.

KEY WORDS: Airway wall thickening, chronic obstructive pulmonary disease, imaging, physiopathology, pulmonary emphysema, quantitative computed tomography

Address for correspondence: Dr. Lalita Fernandes, CA 3/8, Sapana Gardens, Porvorim, Bardez - 403 521, Goa, India. E-mail: drlalitafernandes@gmail.com

INTRODUCTION

The global initiative for chronic obstructive lung disease (GOLD) defines chronic obstructive pulmonary disease (COPD) as a common preventable and treatable disease characterized by persistent airflow limitation that is usually progressive and associated with enhanced chronic inflammatory response in the airways and lung to noxious particles or gases. Co-morbidities and exacerbations contribute to overall severity in individual patients.^[1] The diagnosis of COPD is based on GOLD guidelines where postbronchodilator forced expiratory volume in 1 s (FEV1)/forced vital capacity (FVC) is <0.70. However, COPD is a heterogeneous disease with varying amount of emphysema and small airway inflammation. Spirometry may not capture the

heterogeneity of the disease completely.^[2] Individuals with similar FEV1 may have substantial, little or no emphysema and Makita *et al.* showed that emphysema extent varies widely within the same disease stage.^[3]

COPD affects the small airways, lung parenchyma, and pulmonary vasculature leading to small airway inflammation, emphysema, and pulmonary hypertension. Pulmonary emphysema is defined as permanent enlargement of airspaces distal to terminal bronchiole with the destruction of alveolar walls and loss of alveolar attachments. Emphysema can be centrilobular, panlobular, and paraseptal. These pathological changes are visualized by conventional chest X-rays in severe COPD or when there are large emphysematous bullae. The early changes are neither sensitive nor specific to COPD on chest X-ray.^[4,5]

This is an open access article distributed under the terms of the Creative Commons Attribution-NonCommercial-ShareAlike 3.0 License, which allows others to remix, tweak, and build upon the work non-commercially, as long as the author is credited and the new creations are licensed under the identical terms.

For reprints contact: reprints@medknow.com

How to cite this article: Fernandes L, Fernandes Y, Mesquita AM. Quantitative computed tomography imaging in chronic obstructive pulmonary disease. Lung India 2016;33:646-52.

Access this article online	
Quick Response Code: 	Website: www.lungindia.com
	DOI: 10.4103/0970-2113.192880

Multidetector computed tomography (MDCT) scanners provide noninvasive methods to study the lung pathology in COPD. Quantitative methods based on CT are available to quantify emphysema and airway dimensions^[6] and a consistent body of literature suggests that CT represents an important tool in a clinical setting helping to accurately detect the location, quantify the extent, and severity of emphysema,^[7-9] as well as small airway disease (SAD). This body of evidence has promoted the use of thoracic CT and is now considered an indispensable technology for longitudinal analysis and intervention trial of $\alpha 1$ antitrypsin deficiency^[10] and severe emphysema.^[11]

METHODS

We searched MEDLINE via PubMed, PubMed Central, and Cochrane Library from 1960 to 2015 using search items related to COPD (COPD, chronic obstructive lung disease, pulmonary disease, and chronic obstructive) and radiology, imaging, CT, physiopathology, and pathology. We included review articles, original articles, editorials, and letters to the editor published in English language. We retrieved 2330 articles; of these 443 were free full-text articles and 1406 abstracts. We had access to 543 articles, and the review is based on these available literatures.

EMERGENCE OF COMPUTED TOMOGRAPHY IN ASSESSING EMPHYSEMA

In the 1980's Hayhurst *et al.* were first to quantify emphysema severity with CT and showed that Hounsfield units (HUs) frequency distribution curves of patients with histologically proven emphysema differed significantly from patients without emphysema.^[12] During this time, the images were 10 mm in thickness, and they appeared blurry because of averaging of structures within the slice.^[13] With MDCT scanners, thinner slice images of 0.5–1 mm of the entire lung are achievable within a single breath hold of 5–15 s which is referred to as volumetric CT or quantitative CT (QCT). On inspiratory CT, normal lung attenuation is about – 850 HU while air-containing spaces have an attenuation of – 1000 HU. Now with the development of computer-aided automated analytical software we can visualize the airways, vessels, and accurately measure lung density.^[14]

The extent of emphysema is estimated using the density mask. The density mask method was introduced in 1988 and is based on a predefined voxel as a threshold to differentiate between areas of normal attenuation values and areas of low attenuation (LAA).^[15] The two-dimensional (2D) picture element, called pixel, has the third dimension due to the thickness of the CT slice. This gives volume to a pixel and hence is called a voxel. The CT voxels are measured by their attenuation values in HUs. The mean lung density is the mean of the HU measured. The density mask technique is defined as the percentage of LAA of total lung volume that contains voxels of attenuation value <–950 HU on inspiratory

scans (proportion of lung parenchyma with attenuation values lower than a predetermined threshold). This type of densitometry analysis has been found to correlate with lung function.^[16] Gevenois *et al.* reported the strongest pathological correlation with emphysema at macroscopic^[17] and microscopic^[18] level, at –950 HU on 1 mm noncontrast enhanced high resolution filtered images. Although the highest correlation between QCT metrics and histology was found when CT threshold was set at –960 or –970 HU,^[6] a value of –950 HU is selected to balance sensitivity and specificity.^[19-21]

There is another method to quantify emphysema which is the 15th percentile cut off on the attenuation distribution curve called Perc15. This provides the HU under which 15% of voxels are distributed.^[22,23] There is evidence that the percentile approach is more robust for longitudinal studies and is less sensitive to changes in lung volume.^[24] It is observed that the first percentile has a better histological correlation, but many studies use the 15th percentile threshold due to artifacts from image noise and truncation artifacts at the first percentile.

Software available on most MDCT scanners makes evaluation faster and easier. We can now measure the total lung volume, right and left lung volume, mean lung density, the 15th percentile of lung density, the percentage of low attenuation regions, emphysema cluster analysis, core and peel involvement, regional distribution of emphysema, airway wall morphology, gas trapping, pulmonary vessel morphology, and coronary calcifications.

Densitometric analysis, however, cannot differentiate between centrilobular, panlobular, paraseptal, and bullous emphysema. This analysis is carried out by visual scoring (qualitative) but has inter- and intra-observer variability.^[25] Quantitative scores are preferred over visual scores as a quantitative assessment of emphysema gives a continuous score rather than categorical as in qualitative analysis.^[26] Quantitative scores help in disease follow-up, and emphysema quantification has been shown to be highly reproducible.^[27,28]

CT can detect emphysema even before the patient becomes symptomatic or is proven by spirometry. Remy-Jardin *et al.* showed that in smokers who had lobe resection done for lung nodule, there was a high incidence of emphysema seen in the pathological specimen even without any clinical symptoms or obstruction of airways.^[29] Early emphysema is usually asymptomatic for a long time, and >30% of total lung parenchyma has to be destroyed for the manifestation of clinical symptoms or changes in pulmonary function tests.^[30]

TECHNIQUE FOR QUANTITATIVE COMPUTED TOMOGRAPHY OF LUNG AND QUALITY CONTROL

Many large-scale clinical studies that investigate the effect of smoking on lung have incorporated QCT into

their trial protocol. These include genetic epidemiology of COPD (COPD Gene),^[20] Multi-Ethnic Study in Atherosclerosis,^[31] Subpopulations and intermediate outcome measures in COPD,^[32] Evaluation of COPD longitudinally to identify predictive surrogate endpoints,^[33] and Can COLD study.^[34] The severe asthma research program also uses QCT to study large and small airways in severe asthma.^[35]

To study emphysema and airway wall thickening on CT, the lung is scanned from apex to base in full inspiration (total lung capacity). Madani *et al.* showed that measures of emphysema changed when scans were performed at 100%, 90%, 80%, 70%, and 50% of vital capacity but there was minimal change between 90% and 100%.^[36] The largest variation in lung attenuation is driven by the ability of the patient to inspire or expire at the given lung volumes, maintain that volume for the duration of scan, 12 s or less and not move during the scan.^[37] For this the patient has to be coached by the CT technologist, ensuring that the patient has taken and maintains a deep inspiration. The scan time should be as short as possible, and this is achieved by minimizing the gantry rotation time, having maximum number of channels present and highest pitch which is a function of table speed and gantry rotation time. The pitch is set no >1 and rotation time no >0.5 s. The mAs delivered is adjusted based on the subject's body mass index. Patients must be centered within the CT scanner gantry. Optimal reconstruction kernel must be used. Visual assessment and quantification of emphysema is possible on the thin CT reconstruction of 1.25 mm or less thickness images.

Expiratory scans are obtained at functional residual capacity.^[20] Expiratory images are used to quantify air trapping due to SAD in COPD. There are some studies which perform an expiratory scan at residual volume^[33] but it is not clear which technique is better. Areas of air trapping on the expiratory scan are defined at HU < -856. This value is chosen as it is normal attenuation of the lung in inspiration and it is assumed that normal expiratory lung should have higher attenuation than -856 HU.^[38] The percentage low attenuation volume at -856 HU shows high correlation ($r = 0.85-0.90$) to FEV1/FVC, and FEV1 percent predicted.^[39,40] However, simple air trapping cannot differentiate between air trapping due to SAD or emphysema. Parametric response mapping (PRM) is a technique that differentiates emphysema and SAD from within regions of the lung identified by QCT as air trapping.

There is a concern for radiation dose in QCT. The Radiological Society of North America's Quantitative Imaging Biomarker Alliance aims to improve the value and practicality of quantitative imaging. To address this in longitudinal studies, iterative reconstruction methods are used. Hence, a lower dose can be used to generate images. Currently, the iterative reconstruction algorithms enable dose reduction

ranging from 20% to 80%.^[41] It is important to remember that reconstruction methods affect the quantitative measurement of emphysema and air trapping, hence, the same reconstruction algorithm and protocol must be followed throughout the course of study and in longitudinal studies requiring repeat scans.^[42]

QUANTITATIVE COMPUTED TOMOGRAPHY OF LUNG ANALYSIS BY PARAMETRIC RESPONSE MAPPING

PRM method is a unique quantitative assessment of CT images.^[43] It involves three fundamental steps. First is inspiratory and expiratory image acquisition, image processing which involves lung parenchymal segmentation and co-registration of inspiratory and expiratory scans digitally and finally classification of voxels on Hounsfield values where green represents normal lung parenchyma, yellow is functional SAD (fSAD), and red is emphysema. With this method, we can differentiate air trapping from emphysema and fSAD. The percentage of parenchyma < -950 HU on the inspiratory scan is quantified as percentage of emphysema. For the assessment of SAD, PRM technique generates a map based on the assumption that voxels of lung with inspiratory CT attenuation < -950 HU are emphysema while voxels > -950 HU on inspiration, but < -856 HU on expiration are areas of gas trapping due to fSAD [Figure 1].

The strength of PRM is to identify individuals with varying combination of emphysema and fSAD. Figure 2 shows how for the same severity of COPD the two individuals have varying amount of emphysema and SAD. PRM analysis could also help in individualized therapeutic interventions. Recently, it has been shown that PRM adds significantly to the diagnostic value of CT quantification methods in assessing the presence of COPD.^[44]

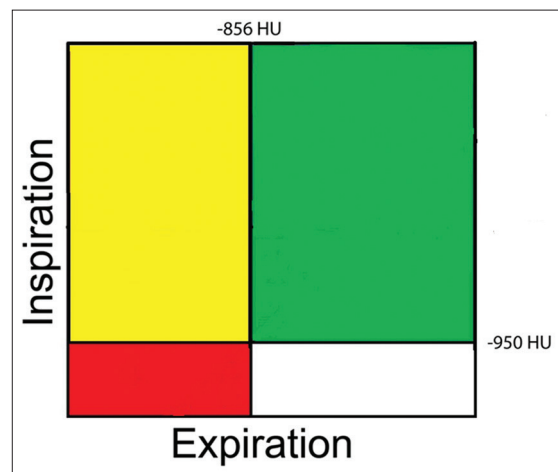


Figure 1: Classification of voxels by parametric response mapping. Green = Normal healthy and deforming voxels. Red = Emphysema voxels, yellow = Functional small airway disease voxels

QUANTITATIVE COMPUTED TOMOGRAPHY OF LUNG ANALYSIS BY PULMO THREE-DIMENSIONAL SOFTWARE

The quantitative assessment by Pulmo 3D Software, Siemens Healthcare, Germany can quantify emphysema and various subranges of HUs as seen in Figure 3. The software measures the percentage low attenuation volume (emphysema) in total lung as well as each lung and each third of lung. It further classifies the emphysema clusters in various classes as seen in Figure 4.

QUALITATIVE ASSESSMENT ON COMPUTED TOMOGRAPHY LUNG

The visual assessment of CT in COPD is done to assess the presence of emphysema, the type of emphysema, airway wall thickening, bronchiectasis, bronchiolitis, centrilobular nodules, fibrosis, and pulmonary artery size. The visual description of emphysema has inter-observer variability,^[25] and it is difficult to detect the earliest form of emphysema on CT scan when the size of the lesion is <5 mm on qualitative analysis.^[45] The observer agreement in the severity of emphysema on visual amount is also variable,^[26] and so also with visual amount of bronchial wall thickening.^[46] Figure 5 shows the presence of centrilobular and paraseptal emphysema.

ANALYSIS OF AIRWAY DISEASE

Animal studies have shown that airways are completely dilated at transpulmonary pressures of more than 10 cm of water, and hence, a reasonable inspiratory effort is adequate to compare airways.^[47,48] Airways can be assessed by measuring the airway wall and lumen dimensions. The parameters measured are lumen area (Ai), internal

lumen perimeter (Pi), and wall area percentage. The most widely used method for airway assessment is full-width-at-half-maximum principle; a computer-aided automated technique. It is based on the X-ray attenuation values measured along rays cast from the center of the lumen moving outward toward the airway wall in all directions. As the ray enters the wall, the attenuation increases and decreases as it passes into the lung parenchyma. The distance between the points at which the attenuation is half way to the maximum on the lumen side and halfway to the minimum on the parenchymal side is considered the wall thickness [Figure 6].^[6,49]

The commonly used summary measure of bronchial wall area is the square root of wall area of a hypothetical bronchus of internal perimeter of 10 mm called Pi10 which is derived from linear regression of all measured bronchi.^[50] Pi10 provides a method for standardizing airway measurements for comparisons between subjects.

Quantitative techniques to measure airways are still in development phase. Earlier studies have shown a correlation between airway dimensions and FEV1 using cross-sectional CT images.^[6,51] Nakano *et al.* showed that there was a correlation between wall area of small airways measured histologically and wall area of large airways measured using CT.^[50] Hasegawa *et al.* measured airway dimensions at 5th or 6th generation and showed that correlation to spirometry improved in more distal bronchial dimensions.^[51] Grydeland *et al.* showed that Pi10 was independently related to symptoms of a cough, wheeze, and dyspnea.^[52]

CONCLUSIONS

QCT of lung provides anatomical and physiological insights into the structure and function of lung in COPD. QCT is

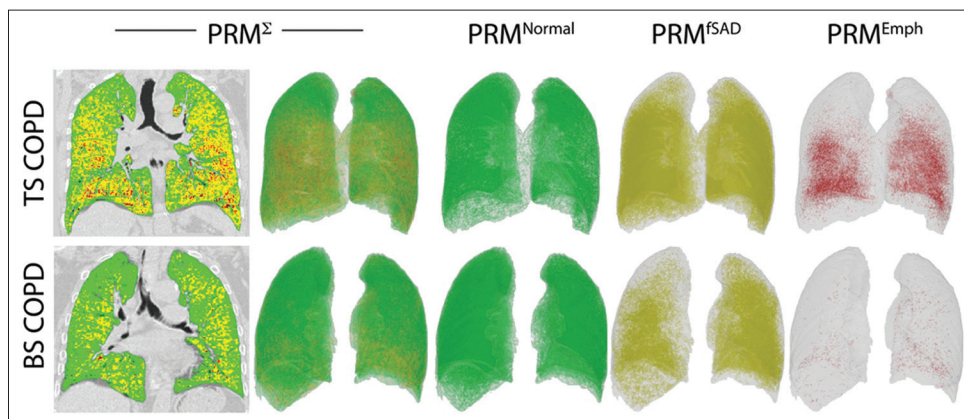


Figure 2: (Left to right) demonstrate the composite (PRM^2) voxel signature in global initiative for chronic obstructive lung disease stage two patient with tobacco smoke exposure chronic obstructive pulmonary disease (top panel) and biomass smoke exposure chronic obstructive pulmonary disease (bottom panel). The colours in the two-dimensional image (top and bottom left) and three-dimensional image reconstructions (left to right) represent (i) PRM^{Normal} : Normal healthy and deforming lung voxels (green), (ii) PRM^{SAD} : Functional small airways disease voxels (yellow) and (iii) PRM^{Emph} : Emphysema voxels (red). TS-COPD and BS-COPD having similar postbronchodilator forced expiratory volume in 1 s %, (67%). Tobacco smoke associated chronic obstructive pulmonary disease $PRM^{Emph} = 6.73\%$, $PRM^{SAD} = 40.36\%$ $PRM^{Normal} = 46.48\%$. Biomass smoke associated chronic obstructive pulmonary disease $PRM^{Emph} = 0.39\%$, $PRM^{SAD} = 69.61\%$ $PRM^{Normal} = 21.45\%$

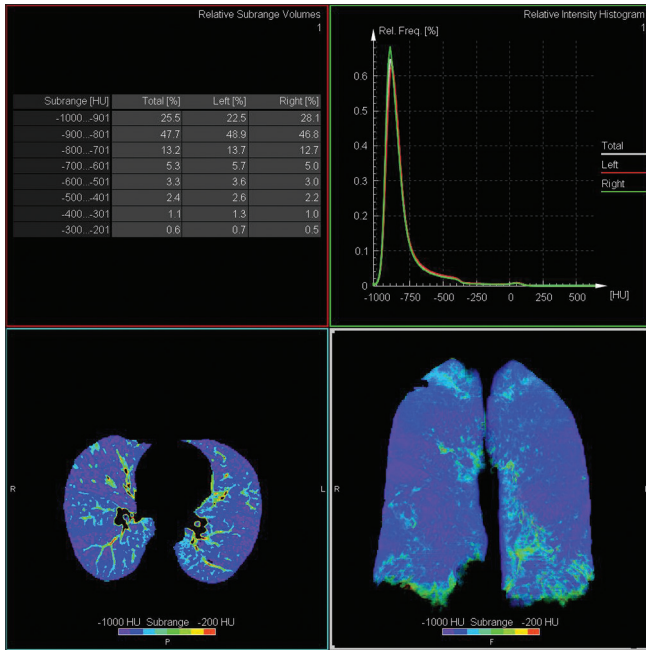


Figure 3: Axial and coronal density mask image giving overview of Hounsfield unit subrange distribution

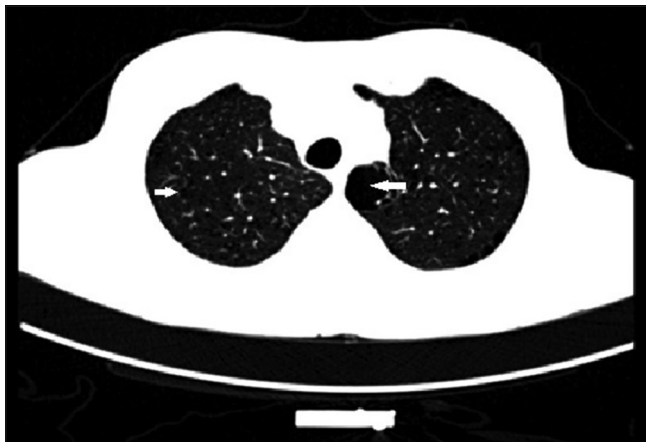

Figure 5: Axial computed tomography image demonstrating centrilobular (arrow) and paraseptal (thicker arrow) emphysema

now becoming an established tool to assess the pathological component in COPD in cross-sectional and longitudinal studies providing deeper knowledge in patient outcomes such as acute exacerbation of COPD, mortality, and quality of life. All along, the outcome of COPD treatment intervention was assessed by FEV1. Now QCT enables us to visualize and quantify the improvement in SAD and emphysema in response to bronchodilator therapy. Further, improved image reconstruction methods reduce radiation doses and hence can be used in longitudinal studies even in younger patients.

Acknowledgment

We thank Craig J Galban, Department of Radiology, Center for Molecular Imaging, University of Michigan, Michigan, USA for permitting use of PRM images generated in TS-COPD and BS- COPD patients.

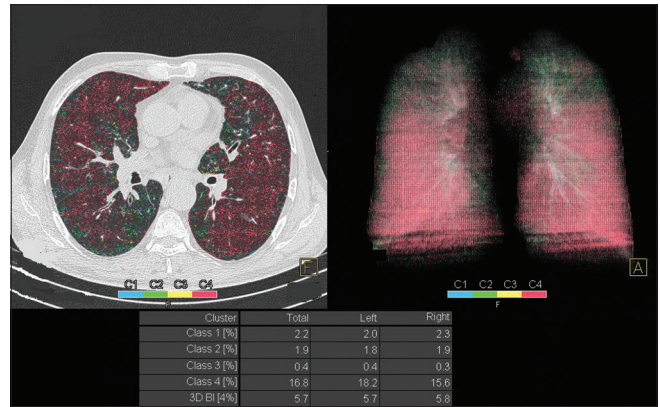


Figure 4: Image shows clusters of emphysema, mostly Class 4 (≥ 25 mm)

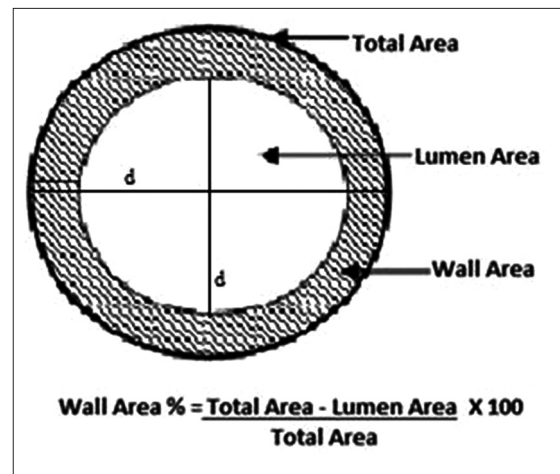


Figure 6: The average outer diameter for the segment is calculated and so also lumen diameter. Wall area is calculated by subtracting the lumen area from the total area. Wall area % is calculated by dividing the wall area by the total area

Financial support and sponsorship

Nil.

Conflicts of interest

There are no conflicts of interest.

REFERENCES

1. Vestbo J, Hurd SS, Agustí AG, Jones PW, Vogelmeier C, Anzueto A, et al. Global strategy for the diagnosis, management, and prevention of chronic obstructive pulmonary disease: GOLD executive summary. *Am J Respir Crit Care Med* 2013;187:347-65.
2. Agustí A, Vestbo J. Current controversies and future perspectives in chronic obstructive pulmonary disease. *Am J Respir Crit Care Med* 2011;184:507-13.
3. Makita H, Nasuhara Y, Nagai K, Ito Y, Hasegawa M, Betsuyaku T, et al. Characterisation of phenotypes based on severity of emphysema in chronic obstructive pulmonary disease. *Thorax* 2007;62:932-7.
4. Sutinen S, Christoforidis AJ, Klugh GA, Pratt PC. Roentgenologic criteria for the recognition of nonsymptomatic pulmonary emphysema. Correlation between roentgenologic findings and pulmonary pathology. *Am Rev Respir Dis* 1965;91:69-76.
5. Nicklaus TM, Stowell DW, Christiansen WR, Renzetti AD Jr. The accuracy of the roentgenologic diagnosis of chronic pulmonary

- emphysema. *Am Rev Respir Dis* 1966;93:889-99.
6. Nakano Y, Muro S, Sakai H, Hirai T, Chin K, Tsukino M, et al. Computed tomographic measurements of airway dimensions and emphysema in smokers. Correlation with lung function. *Am J Respir Crit Care Med* 2000;162 (3 Pt 1):1102-8.
 7. Coxson HO, Rogers RM. Quantitative computed tomography of chronic obstructive pulmonary disease. *Acad Radiol* 2005;12:1457-63.
 8. Madani A, Zanen J, de Maertelaer V, Gevenois PA. Pulmonary emphysema: Objective quantification at multi-detector row CT – Comparison with macroscopic and microscopic morphometry. *Radiology* 2006;238:1036-43.
 9. Matsuoka S, Kurihara Y, Yagihashi K, Nakajima Y. Quantitative thin-section CT analysis of the enlargement and coalescence of low-attenuation clusters in patients with emphysema. *Respiration* 2007;74:136-41.
 10. Stockley RA, Parr DG, Piitulainen E, Stolk J, Stoel BC, Dirksen A. Therapeutic efficacy of α -1 antitrypsin augmentation therapy on the loss of lung tissue: An integrated analysis of 2 randomised clinical trials using computed tomography densitometry. *Respir Res* 2010 5;11:136.
 11. Sciruba FC, Ernst A, Herth FJ, Strange C, Criner GJ, Marquette CH, et al. A randomized study of endobronchial valves for advanced emphysema. *N Engl J Med* 2010;363:1233-44.
 12. Hayhurst MD, MacNee W, Flenley DC, Wright D, McLean A, Lamb D, et al. Diagnosis of pulmonary emphysema by computerised tomography. *Lancet* 1984;2:320-2.
 13. Coxson HO. Lung parenchyma density and airway wall thickness in airway diseases. *Breathe* 2012;9:36-45.
 14. Stolk J, Versteegh MI, Monteni L, Bakker ME, Grebski E, Tutic M, et al. Densitometry for assessment of effect of lung volume reduction surgery for emphysema. *Eur Respir J* 2007;29:1138-43.
 15. Müller NL, Staples CA, Miller RR, Abboud RT. "Density mask". An objective method to quantitate emphysema using computed tomography. *Chest* 1988;94:782-7.
 16. Kinsella M, Müller NL, Abboud RT, Morrison NJ, DyBuncio A. Quantitation of emphysema by computed tomography using a "density mask" program and correlation with pulmonary function tests. *Chest* 1990;97:315-21.
 17. Gevenois PA, de Maertelaer V, De Vuyst P, Zanen J, Yernault JC. Comparison of computed density and macroscopic morphometry in pulmonary emphysema. *Am J Respir Crit Care Med* 1995;152:653-7.
 18. Gevenois PA, De Vuyst P, de Maertelaer V, Zanen J, Jacobovitz D, Cosio MG, et al. Comparison of computed density and microscopic morphometry in pulmonary emphysema. *Am J Respir Crit Care Med* 1996;154:187-92.
 19. Coxson HO, Dirksen A, Edwards LD, Yates JC, Agusti A, Bakke P, et al. The presence and progression of emphysema in COPD as determined by CT scanning and biomarker expression: A prospective analysis from the ECLIPSE study. *Lancet Respir Med* 2013;1:129-36.
 20. Regan EA, Hokanson JE, Murphy JR, Make B, Lynch DA, Beaty TH, et al. Genetic epidemiology of COPD (COPDGene) study design. *COPD* 2010;7:32-43.
 21. Heussel CP, Herth FJ, Kappes J, Hantusch R, Hartlieb S, Weinheimer O, et al. Fully automatic quantitative assessment of emphysema in computed tomography: Comparison with pulmonary function testing and normal values. *Eur Radiol* 2009;19:2391-402.
 22. Lynch DA, Newell JD. Quantitative imaging of COPD. *J Thorac Imaging* 2009;24:189-94.
 23. Matsuoka S, Yamashiro T, Washko GR, Kurihara Y, Nakajima Y, Hatabu H. Quantitative CT assessment of chronic obstructive pulmonary disease. *Radiographics* 2010;30:55-66.
 24. Dirksen A. Monitoring the progress of emphysema by repeat computed tomography scans with focus on noise reduction. *Proc Am Thorac Soc* 2008;5:925-8.
 25. Hersh CP, Washko GR, Jacobson FL, Gill R, Estepar RS, Reilly JJ, et al. Interobserver variability in the determination of upper lobe-predominant emphysema. *Chest* 2007;131:424-31.
 26. Cavigli E, Camiciottoli G, Diciotti S, Orlandi I, Spinelli C, Meoni E, et al. Whole-lung densitometry versus visual assessment of emphysema. *Eur Radiol* 2009;19:1686-92.
 27. Stolk J, Dirksen A, van der Lugt AA, Hutsebaut J, Mathieu J, de Ree J, et al. Repeatability of lung density measurements with low-dose computed tomography in subjects with alpha-1-antitrypsin deficiency-associated emphysema. *Invest Radiol* 2001;36:648-51.
 28. Bakker ME, Stolk J, Putter H, Shaker SB, Parr DG, Piitulainen E, et al. Variability in densitometric assessment of pulmonary emphysema with computed tomography. *Invest Radiol* 2005;40:777-83.
 29. Remy-Jardin M, Remy J, Gosselin B, Becette V, Edme JL. Lung parenchymal changes secondary to cigarette smoking: Pathologic-CT correlations. *Radiology* 1993;186:643-51.
 30. Gurney JW, Jones KK, Robbins RA, Gossman GL, Nelson KJ, Daughton D, et al. Regional distribution of emphysema: Correlation of high-resolution CT with pulmonary function tests in unselected smokers. *Radiology* 1992;183:457-63.
 31. Bild DE, Bluemke DA, Burke GL, Detrano R, Diez Roux AV, Folsom AR, et al. Multi-ethnic study of atherosclerosis: Objectives and design. *Am J Epidemiol* 2002;156:871-81.
 32. Couper D, LaVange LM, Han M, Barr RG, Bleecker E, Hoffman EA, et al. Design of the subpopulations and intermediate outcomes in COPD study (SPIROMICS). *Thorax* 2014;69:491-4.
 33. Vestbo J, Anderson W, Coxson HO, Crim C, Dawber F, Edwards L, et al. Evaluation of COPD longitudinally to identify predictive surrogate end-points (ECLIPSE). *Eur Respir J* 2008;31:869-73.
 34. Bourbeau J, Tan WC, Benedetti A, Aaron SD, Chapman KR, Coxson HO, et al. Canadian cohort obstructive lung disease (CanCOLD): Fulfilling the need for longitudinal observational studies in COPD. *COPD* 2014;11:125-32.
 35. Aysola RS, Hoffman EA, Gierada D, Wenzel S, Cook-Granroth J, Tarsi J, et al. Airway remodeling measured by multidetector CT is increased in severe asthma and correlates with pathology. *Chest* 2008;134:1183-91.
 36. Madani A, Van Muylem A, Gevenois PA. Pulmonary emphysema: Effect of lung volume on objective quantification at thin-section CT. *Radiology* 2010;257:260-8.
 37. Newell JD Jr., Sieren J, Hoffman EA. Development of quantitative computed tomography lung protocols. *J Thorac Imaging* 2013;28:266-71.
 38. Lynch D. Progress in imaging COPD, 2004-2014. *J COPD F* 2014;1:73-82.
 39. Schroeder JD, McKenzie AS, Zach JA, Wilson CG, Curran-Everett D, Stinson DS, et al. Relationships between airflow obstruction and quantitative CT measurements of emphysema, air trapping, and airways in subjects with and without chronic obstructive pulmonary disease. *AJR Am J Roentgenol* 2013;201:W460-70.
 40. Murphy K, Plum JP, van Rikxoort EM, de Jong PA, de Hoop B, Gietema HA, et al. Toward automatic regional analysis of pulmonary function using inspiration and expiration thoracic CT. *Med Phys* 2012;39:1650-62.
 41. Leipsic J, Nguyen G, Brown J, Sin D, Mayo JR. A prospective evaluation of dose reduction and image quality in chest CT using adaptive statistical iterative reconstruction. *AJR Am J Roentgenol* 2010;195:1095-9.
 42. Mets OM, de Jong PA, van Ginneken B, Gietema HA, Lammers JW. Quantitative computed tomography in COPD: Possibilities and limitations. *Lung* 2012;190:133-45.
 43. Galbán CJ, Han MK, Boes JL, Chughtai KA, Meyer CR, Johnson TD, et al. Computed tomography-based biomarker provides unique signature for diagnosis of COPD phenotypes and disease progression. *Nat Med* 2012;18:1711-5.
 44. Pompe E, van Rikxoort EM, Schmidt M, Rühaak J, Estrella LG, Vliegenthart R, et al. Parametric response mapping adds value to current computed tomography biomarkers in diagnosing chronic obstructive pulmonary disease. *Am J Respir Crit Care Med* 2015;191:1084-6.
 45. Miller RR, Müller NL, Vedral S, Morrison NJ, Staples CA. Limitations of computed tomography in the assessment of emphysema. *Am Rev Respir Dis* 1989;139:980-3.
 46. Bafadhel M, Umar I, Gupta S, Raj JV, Vara DD, Entwisle JJ, et al. The role of CT scanning in multidimensional phenotyping of COPD. *Chest* 2011;140:634-42.
 47. Brown RH, Mitzner W, Bulut Y, Wagner EM. Effect of lung inflation *in vivo* on airways with smooth muscle tone or edema. *J Appl Physiol* (1985) 1997;82:491-9.
 48. Brown RH, Mitzner W. Effect of lung inflation and airway muscle tone on airway diameter *in vivo*. *J Appl Physiol* (1985) 1996;80:1581-8.
 49. Nakano Y, Whittall KP, Kaloger SE, Coxson HO, Pare PD, English JC. Development and validation of human airway analysis algorithm using multidetector row CT. *Proc SPIE* 2002;4683:460-9.
 50. Nakano Y, Wong JC, de Jong PA, Buzatu L, Nagao T, Coxson HO, et al. The prediction of small airway dimensions using computed tomography.

- Am J Respir Crit Care Med 2005;171:142-6.
51. Hasegawa M, Nasuhara Y, Onodera Y, Makita H, Nagai K, Fuke S, *et al.* Airflow limitation and airway dimensions in chronic obstructive pulmonary disease. Am J Respir Crit Care Med 2006;173:1309-15.
52. Grydeland TB, Dirksen A, Coxson HO, Eagan TM, Thorsen E, Pillai SG, *et al.* Quantitative computed tomography measures of emphysema and airway wall thickness are related to respiratory symptoms. Am J Respir Crit Care Med 2010;181:353-9.

Indian Chest Society (ICS) grant for multi centric research project

ICS Invites applications on grant for multi-centric research project

Salient points to be included in the application are:

1. Title of the Research Project
2. Hypothesis and objectives
3. Proposed research project summary (not exceeding 150 words)
4. Detailed research plan. (Design, inclusion & exclusion criteria, sample size with appropriate calculations, detailed methodology and techniques to be employed for the project, including statistical methods any potential to obtain patents etc.)
5. Investigators and institutions of the proposed project
6. Duration of Research Project
 - i) Duration of the proposed project:
 - ii) Estimated time for data analysis:
7. Details of grant-in-aid asked for
8. Institution responsible for the research project
9. The Institution where the study is being done should ensure that there is no financial conflict of interest by the investigators.
10. Bio data of the investigators

Please note:

1. Ethics committee approval for the study will be obtained by investigators
2. Registration in Clinical trial registry will be done by investigators.
3. The biological samples will not be transported out of the country without proper permission. Interested applicants are requested to visit ICS website <http://www.indianchestociety.in> for more information.