



Editorial

Fetoscopic repair of spina bifida: safer and better?

D. A. L. PEDREIRA*†, E. A. REECE‡, R. H. CHMAIT§, E. V. KONTOPOULOS¶** and R. A. QUINTERO**

†Fetal Therapy Program, Albert Einstein Hospital, São Paulo, Brazil; ‡Office of the Dean and Department of Obstetrics, Gynecology and Reproductive Sciences, University of Maryland School of Medicine, Baltimore, MD, USA; §Department of Obstetrics and Gynecology, Keck School of Medicine, University of Southern California, Los Angeles, CA, USA; ¶Department of Obstetrics and Gynecology, University of Missouri, Kansas City, MO, USA; **Elizabeth J. Ferrell Fetal Health Center, Fetal Therapy, Children's Mercy Hospital, Kansas City, MO, USA
*Correspondence. (e-mail: denise.pedreira@gmail.com)

Introduction

Open spina bifida (OSB) is one of the most common birth defects, and often results in significant, lifelong motor and neurodevelopmental impairment. A recent randomized clinical trial, the Management of Myelomeningocele Study (MOMS), showed that prenatal compared with postnatal repair of OSB resulted in a reduced need for ventriculoperitoneal (VP) shunt placement and a decrease by one third in the rate of hindbrain herniation at 12 months of age, as well as doubling of the ability to ambulate without the assistance of orthotics and better level of motor function at 30 months¹. However, open *in-utero* repair was associated with higher rates of preterm birth, oligohydramnios, placental abruption, pulmonary edema and maternal transfusion at delivery, and a 35% risk of uterine thinning or dehiscence. Minimally invasive fetal surgery has essentially replaced open fetal surgery for most fetal conditions. Our group has worked on the development of fetoscopic correction of spina bifida in animal models, and we recently published the results of a phase-I clinical trial². In this Editorial, we discuss the science behind the current management of prenatally diagnosed OSB, the rationale for considering a minimally invasive approach as an alternative to open fetal surgery, the technical challenges inherent to this approach, and our preliminary clinical results using a fetoscopically applied skin-over-biocellulose technique.

Impact of open spina bifida

OSB affects 3.5:10 000 live births in the USA³ and 1.4:10 000 live births in Brazil⁴. It is characterized by non-closure of the elements that protect the medulla, leaving it exposed to amniotic fluid throughout pregnancy. The primary postnatal consequences of OSB are related

to lifelong impairment of the control of sphincters and motor function at or below the level of the lesion, sometimes including paralysis^{5,6}. The lesion is associated with Chiari-II malformation, characterized by herniation of the cerebellum through the foramen magnum into the spinal canal⁷.

Postnatal treatment of open spina bifida

The primary goal of postnatal treatment of OSB is to stop leakage of cerebrospinal fluid (CSF) from the lesion and to prevent infection of the exposed nervous tissue. To accomplish this, the neural placode is released and reshaped, the dura mater is closed in a watertight fashion, the paravertebral muscles are approximated, and the skin is closed. Approximately 52–91% of babies will require a VP shunt to treat ensuing hydrocephalus⁸.

Two types of complication can arise from postnatal surgical repair and VP shunting: problems with the VP shunt itself (e.g. obstruction or infection) and tethered cord syndrome. Both complications require subsequent neurosurgery, which can cause further loss of neurological function⁶.

Rationale for prenatal treatment

Extensive animal work and observation of human fetuses terminated at different gestational ages suggest that the exposed medulla undergoes progressive damage *in utero*^{9–11}. Prenatal repair could thus prevent or ameliorate damage to the medulla and improve neurological outcome^{12,13}. Early clinical reports also suggest that prenatal repair could result in reversal of the hindbrain herniation and improve Chiari-II malformation^{14,15}. These additional observations have generated great enthusiasm about the potential role of prenatal surgery in the treatment of OSB.

Management of Myelomeningocele Study (MOMS)

The results of a randomized clinical trial (the MOMS trial) comparing prenatal repair of OSB via open fetal surgery with postnatal repair showed that, except for the incidence of tethered cord syndrome, prenatal correction of OSB is associated with improved neurological outcome¹. The trial enrolled 183 patients, referred to one of three treatment centers in the USA, and reported the results of 158 patients. The primary composite outcome (fetal or neonatal death, or need for VP shunting before 1 year of age) occurred in 68% of the prenatal repair group *vs* 98% of the postnatal repair group ($P = 0.001$) and the rate of VP shunt placement was 40% *vs* 82% ($P = 0.001$). The number of infants in the prenatal repair group who could walk without orthotics or devices was twice as high

as that in the postnatal repair group (42% vs 21%). The composite score for mental development at 30 months was also better in the prenatal treatment group¹. By 1 year of age, 36% of infants in the prenatal repair group had no evidence of hindbrain herniation compared with only 4% of those in the postnatal repair group¹.

Maternal risks of open fetal surgery and uterine legacy

The MOMS trial was a very important step in demonstrating that prenatal correction is beneficial to the neurological outcome of affected individuals. However, the trial also showed that, compared with postnatal correction, prenatal correction via open fetal surgery was associated with statistically significantly higher maternal risks¹. These included an increased risk for preterm birth (79% delivering < 37 weeks in the prenatal repair group vs 15% in the postnatal repair group ($P < 0.001$) and 46% vs 5% delivering < 35 weeks ($P < 0.001$)), maternal pulmonary edema and placental abruption (6% vs 0%, $P < 0.01$), requirement for blood transfusion at delivery (9% vs 1%, $P < 0.05$) and uterine scar thinning or dehiscence in the index pregnancy (36% vs 0%, $P < 0.001$)¹. Furthermore, open fetal surgery, which requires maternal laparotomy and hysterotomy, can have detrimental consequences to subsequent pregnancies. Wilson *et al.*¹⁶ reported uterine dehiscence in 14% and rupture of the uterus in 14% of subsequent pregnancies in patients submitted to open fetal surgery in the index pregnancy. While fetal outcome may be maintained or improved by open fetal surgery, it is vital to preserve concomitantly maternal outcome and future reproductive health. Both goals are achievable using an endoscopic approach to prenatal fetal surgery.

Fetoscopic repair of open spina bifida

A fetoscopic approach for the *in-utero* correction of OSB was first reported in 1997 by Bruner *et al.*¹⁷, who used a complex technique involving endoscopic placement of a maternal split-thickness skin graft over the fetal neural placode to close the defect^{17,18}. This approach was abandoned after results that were less than satisfactory in four cases, with only half of these fetuses surviving and both survivors requiring a VP shunt.

Development of a fetoscopic technique in animal models

The main goal of our research effort was to develop a surgical technique to repair OSB *in utero* that could be performed endoscopically. From the outset, we understood that such a technique would need to differ substantially from the classic postnatal multilayer closure to be clinically applicable, reliable and reproducible. Thus, the characteristics of the new surgical technique would need to allow covering of the spinal defect without

requiring a multiple-layer closure. In addition to using a single-layer closure, fetoscopic repair of OSB should:

- (a) be watertight and result in reversal of hindbrain herniation; and
- (b) address risk factors associated with cord tethering to decrease the likelihood of such a complication.

Interestingly, while the intrauterine location of the fetus represents a technical challenge, it also represents a paradoxical benefit, because fetoscopic surgery is performed in an entirely different milieu, one which is aseptic and more conducive to healing^{19–21} than is the postnatal environment. We took these factors into account when developing our unique approach to repairing OSB, first in animal models and then in a phase-I clinical trial.

Bacterial cellulose (biocellulose) as a dura mater substitute

Our initial experiments^{22–25} focused on developing a practical way to protect the medulla. Through an extensive literature review (Table S1), we assessed several different materials that could be used as dural substitutes for the prenatal closure of meningocele-like defects²². Based on this review, we chose to use a sterile biosynthetic cellulose patch, produced by a bacterium (*Acetobacter xilinum*), which had been tested successfully as a dura mater substitute after craniotomy in an animal model²⁶. This craniotomy study showed that the biocellulose elicited a low fibrotic reaction, and that a thin internal and a thick external connective tissue layer, formed by fibroblasts, enveloped the biocellulose implant without adhering to the cerebral cortex²⁶. This material has also been used clinically as a dura mater substitute in patients who had undergone craniotomy for various indications (i.e. tumor, trauma and cerebral edema)²⁷.

To test the use of this biocellulose for correction of OSB, we used a fetal rabbit model, inducing and repairing a spinal defect at 23 days' gestation (term = 30 days)²⁵. We dissected the skin around the spinal lesion, placed the biocellulose underneath the skin edges, and approximated the edges using a single stitch. At 30 days' gestation, the skin had healed completely, the biocellulose remained in place and no foreign body reaction was observed^{24,25}.

The next step was to test the biocellulose in a larger animal model, with a more prolonged gestation, to check for any long-term effects of the biocellulose patch²³. A larger animal would also help us to work out technical issues that would be critical for clinical application of the surgical technique in humans²⁸. In an ovine model of OSB, the patch was in place for a median of 28 days. We closed the skin using a continuous running suture and observed that the fetal skin was healed at birth. Microscopically, the inner fibroblast layer surrounding the biocellulose was found in anatomical continuity with the original dura mater, which led to the formation of a neodura mater²⁹. This observation suggested that direct closure of the dura mater during surgery may not be necessary. Our

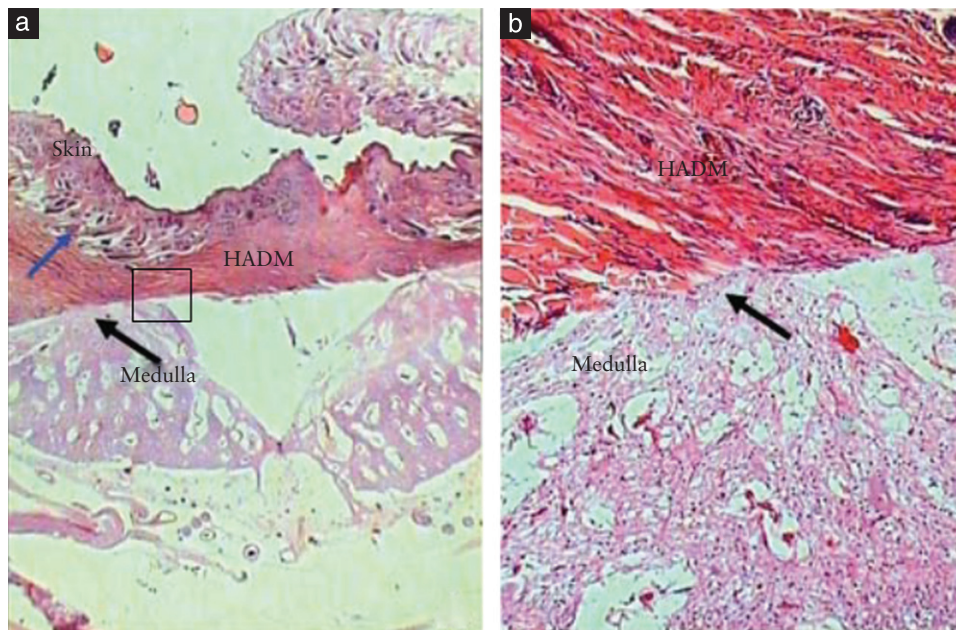


Figure 1 Surgical pathology analysis of lesion in a fetus which underwent prenatal correction of a meningocele-like defect using human acellular dermal matrix (HADM). (a) HADM adhered to skin (blue arrow) and to neural tissue (black arrow) (hematoxylin-eosin stain; original magnification, $\times 16$). (b) Magnification of the square section outlined in part (a), showing ingrowth of cells from the medulla (black arrow) into the HADM (hematoxylin-eosin stain; original magnification, $\times 100$). Reproduced with permission from Sanchez e Oliveira *et al.*²⁹.

finding represents a paradigm shift, because it indicates that a primary watertight closure of the dura mater was not essential for correction of OSB at the time of antenatal surgery, as it appeared that the fetus was able to repair the dura mater by itself subsequently.

We compared the biosynthetic cellulose with an acellular dermal matrix²⁹, a patch that has been used to correct OSB in humans³⁰. The biocellulose performed better, because it kept the medulla separate from the skin, thereby potentially avoiding spinal cord tethering, whereas the dermal matrix adhered extensively to the medulla (Figure 1)²⁹.

Fetoscopic closure of 'large defects'

In approximately 20–30% of fetuses undergoing prenatal correction of OSB using open fetal surgery, the skin defect is too large to allow primary skin closure³¹. To address this potential problem, we tested placement of a bilaminar skin substitute (silicone and acellular dermal matrix) over our biocellulose graft. We hypothesized that the artificial skin would keep the biocellulose in place when approximation of the skin edges was not possible. We conducted a study which showed that the artificial skin induces the formation of neoskin above the biocellulose such that the dermal matrix becomes a scaffold for neodermis formation, allowing a new epidermal layer to be formed above the repopulated dermal matrix³².

Definitive correction in a 'single step'

We hypothesized initially that fetoscopic correction of OSB would require two steps: a palliative *in-utero*

endoscopic step that would involve protection of the medulla, followed by definitive postnatal correction³³. However, after noting the development of a neodura mater and of a neoskin in our animal experiments, we surmised that we could achieve definitive OSB closure using prenatal endoscopic surgery alone (a one-step approach). This was subsequently shown to be the case in our preliminary clinical trial³⁴.

Comparison of repair techniques

Before conducting a clinical trial, we felt it was necessary to compare our innovative repair technique with the standard postnatal multilayer neurosurgical technique, which has been applied mostly as a translation from the postnatal treatment standard and has never been tested adequately in a fetal animal model. Therefore, using our ovine OSB model, we compared our skin-over-biocellulose repair to the standard multilayer closure technique that was used in the MOMS trial³⁵. Our data showed that the standard neurosurgical technique resulted in significant damage to the medulla, prevented the formation of a neodura mater and created a fibrous scar that caused adherence of the medulla to the skin. Conversely, our skin-over-biocellulose technique did not cause damage to the medulla, induced formation of a neodura mater (in anatomical continuity with the original dura mater) and created a natural separation between the medulla and the skin by the presence of the biocellulose (Figure 2). These findings suggest that the *in-utero* endoscopic approach is associated with better preservation of the posterior horns than is the

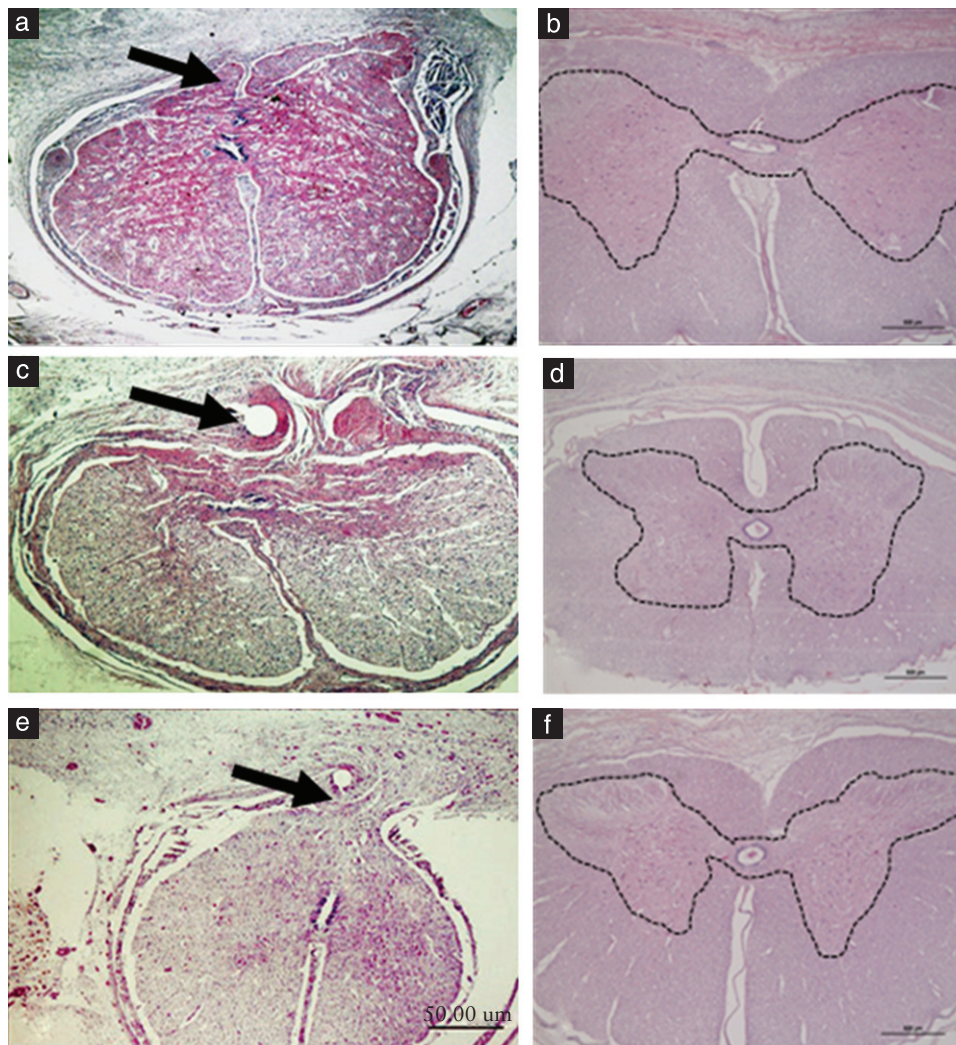


Figure 2 Surgical pathology specimens of fetal sheep medulla after repair of a spinal defect using two different techniques. (a,c,e) Standard neurosurgical multilayer repair: arrows show adherence of medullar tissue to the scar (meningoneural adhesion). (b,d,f) Skin-over-biocellulose technique using biosynthetic cellulose. Images show preservation of the medullar architecture; dashed lines outline the gray matter. Note absence of this line in the neurosurgical group, indicating disruption of the medullary tissue. Reproduced with permission from Herrera *et al.*³⁵.

standard technique, and that, potentially, it could be associated with a decreased likelihood of postoperative cord tethering²⁵.

Clinical experience with fetoscopic treatment: the German experience

In 2006, Kohl *et al.* reported the prenatal treatment of OSB in three patients between 23 and 26 weeks of gestation, using fetoscopy and partial carbon dioxide (CO₂) insufflation of the uterine cavity³⁶. Surgery consisted of simply covering the defect with a polytetrafluorethylene material, and all cases required postnatal neurosurgical repair³⁶. In 2009, the technique was further modified by the same group, providing definitive correction *in utero* and obviating the need for postnatal repair^{37–39}.

By 2012, the same group had operated on another 19 fetuses with OSB using an entirely percutaneous fetoscopic technique⁴⁰. Surgery consisted of circumcising the placode

and removing the junctional zone tissue close to the normal skin. The spinal cord was then covered with an insoluble patch that was sutured onto the paraspinal musculature with interrupted stitches, aiming to achieve a watertight closure of the dura mater. Among these 19 cases, there were three fetal and three neonatal deaths. The remaining 13 patients were compared in terms of segmental neurological function and leg muscle ultrasound density (MUD) with age-matched controls who had undergone postnatal repair. The prenatal repair group was born at a statistically significantly lower gestational age compared with the postnatal repair group (median, 32 *vs* 39 weeks) and experienced more complications (chorioamnionitis, premature rupture of the amniotic membranes, oligohydramnios and infant respiratory distress syndrome necessitating intermittent positive-pressure ventilation)⁴⁰. However, neurological function was better preserved in the prenatal compared with the postnatal repair group, with a median

motor and sensory gain of two segments and better knee-jerk ($P=0.006$) and anal ($P=0.032$) reflexes. The difference between the MUD caudal and cranial to the myelomeningocele was smaller in the prenatal than in the postnatal group, and this was associated with better preservation of segmental muscle function⁴⁰. None of the mothers experienced uterine dehiscence or rupture and none required postoperative blood transfusion.

The same group subsequently reported 51 cases undergoing a slightly different technique, in which a porcine small-bowel submucosa patch was used over an inert Teflon patch if needed. In this series, amniotic fluid leakage occurred in 43 patients, and the mean gestational age at delivery was 33 (range, 24.6–38.1) weeks. All abdominal and uterine trocar insertion sites were healed and the majority of women delivered beyond 32 weeks of gestation^{41,42}.

The first fetoscopic spina bifida repair performed in Brazil used the technique described by Thomas Kohl in direct collaboration with his group, while we awaited authorization from our National Ethics Committee to approve the use of our novel technique.

Fetoscopic repair in humans: the CECAM trial

After addressing in animal models several of the challenges mentioned above (i.e. the need to develop an endoscopically applicable watertight technique and the need to reduce the likelihood of cord tethering^{22–25,28,29,32,35}), our group conducted a phase-I trial of the fetoscopic repair of OSB, using our skin-over-biocellulose technique: the CECAM (Cirurgia Endoscópica para Correção Antenatal da Meningomielocele em humanos) trial. Patient inclusion and exclusion criteria were very similar to those of the MOMS trial. Surgery was performed under general anesthesia and with partial CO₂ exchange. Two 11-Fr trocars and one 14-Fr, or 5.0-mm, trocar were used. Once the fetus was positioned adequately, the skin around the placode was circumcised. A biocellulose patch was placed over the lesion and the skin was reapproximated using a continuous running suture over the patch, without dissecting or suturing the dura mater.

We reported the results of the first four human fetuses from the CECAM trial in 2014³⁴, and recently published the results of all 10 cases which underwent surgery in Brazil². Surgery was completed in eight of the 10 cases. There was one fetal and one neonatal demise, and one case of unsuccessful prenatal repair underwent postnatal repair. No tocolysis was needed during surgery, and atosiban was used prophylactically for 24 h postoperatively.

The mean gestational age at birth was 32.4 weeks and delivery occurred at a mean of 5.6 weeks after surgery. Among the seven infants available for postnatal analysis, no CSF leakage was present at birth and, in six, there was complete reversal of the hindbrain herniation, indicating that a watertight closure of the dura had been achieved successfully.

A comparison between the anatomical lesion level and the motor/neurological segmental level can better

express neurological improvement, since the motor level represents the lowest nerve roots that are preserved, i.e. the most distal active muscles present. The lower the motor level, the higher the chance the infant will be able to walk. Short-term observations showed that six of the seven (86%) infants had the same or better-than-expected (ranging from one to three levels better) motor *vs* anatomical level (assessed using neonatal magnetic resonance imaging), at a mean follow-up of 6.6 months. In the MOMS trial, 67% (43/64) of cases treated prenatally showed the same or better motor than anatomical level compared with only 46% (46/70) of cases in the postnatal surgery group. This suggests that the short-term motor outcomes with our technique are at least the same, if not better, than those reported in the MOMS trial.

In our series, there were neither maternal deaths nor significant maternal morbidity, except for preterm pre-labor rupture of membranes (PPROM), which occurred in all cases, but which did not affect our fetal outcomes significantly.

These results, although preliminary, indicate that our innovative technique is associated with less maternal morbidity than is open fetal surgery, and with as good or better neurological outcome of infants.

Tethered cord syndrome and postnatal neurosurgical intervention

One of the major postoperative complications of surgical repair of OSB is tethered cord syndrome. In the two available long-term follow-up case series published comparing prenatal with postnatal repair, there was a trend towards a higher incidence of tethered cord syndrome in the prenatal group^{1,40}. Verbeek and colleagues⁴⁰ reported tethered cord syndrome as a complication in 38% (5/13 cases) of infants operated on prenatally *vs* 15% (2/13 cases) of age-matched controls operated on postnatally ($P=0.37$). A similar trend for this complication was found in the MOMS trial⁴³, with 8% (6/77 cases) of babies needing surgery in the prenatal group, and 1% (1/80 cases) of babies in the postnatal group needing surgery ($P=0.06$).

All antenatal techniques used to repair OSB may result in the need for postnatal neurosurgical intervention. Kohl's group recently published the results of a 1-year follow-up of more than 70 cases treated fetoscopically⁴⁴. Maternal and fetal benefits were largely sustained, but 28% of the patients required early postnatal local neurosurgical intervention. In the MOMS trial, dehiscence of the repair site occurred in 13% of cases from the prenatal group *vs* 6% of cases from the postnatal group⁴⁴. We expect the need for postnatal neurosurgical intervention in our patients to be lower because our goal is primary skin closure². In our recent series of 10 cases, early postnatal intervention was required in only one of the eight cases treated successfully *in utero*.

Non-percutaneous fetoscopic closure

Another group in the USA recently reported the result in a case of fetoscopic closure of OSB⁴⁵. The procedure was not performed percutaneously, requiring a laparotomy and exteriorization of the uterus. The dura mater was included in the skin suture. At birth, the investigators observed CSF leakage and treated it successfully with steristrips. However, we believe that this may potentially lead to CSF leakage and may increase the risk of tethered cord syndrome.

We believe that any new closure technique should first be tested in an animal model, or be compared to the approaches currently in use in humans or, at least, to the classical neurosurgical technique. For instance, in our animal models, we showed that the suture itself may cause further damage to the nervous tissue (Figure 2)³⁵ and some patches (i.e. acellular dermal matrix) can cause meningoneural adhesions (Figure 1)²⁹. Such adhesions may result in tethered cord syndrome, which can compromise previously improved motor function, and which may be missed in early outcome evaluations, as this is usually a long-term complication.

Fetal acidosis and other central nervous system injuries

Another major concern is iatrogenic central nervous system (CNS) injury subsequent to the fetal surgical treatment itself. Bealer *et al.*⁴⁶ found that among human newborns who had undergone open fetal surgery, 21% had CNS injuries and, in almost 50% of these cases, this finding could not be attributed to prematurity or fetal distress. The authors postulated that these injuries could have been caused by sudden changes in fetal cerebral blood flow during the operative and postoperative course, attributable mainly to the aggressive tocolysis needed as a result of the hysterotomy. Although a direct cause could not be determined (e.g. maternal-fetal hypoxia, fetal bradycardia, use of tocolytic drugs), periventricular leukomalacia or periventricular hemorrhage leading to hydrocephalus were attributed to disturbances during the open fetal surgery approach itself.

An issue that has raised concern extensively is the possible occurrence of fetal acidosis during fetoscopic surgery using partial CO₂ insufflation of the amniotic cavity⁴⁷. Kohl and colleagues have addressed this issue in sheep and did not find evidence of histological damage in the fetal brain after CO₂ insufflation during fetoscopy³⁸. Furthermore, in neither Kohl's³⁷ nor in our clinical series⁴⁴ did imaging studies performed routinely after birth reveal evidence of adverse effects on the human fetal CNS from the use of partial CO₂ insufflation.

Future perspectives

The success of the MOMS trial underpins the rationale for treatment of OSB *in utero*. However, it also underscores the fact that fetal gains were obtained at the expense of the

mother. Thus, there is a need to improve fetal outcome while decreasing maternal morbidity in the context of fetal surgery. From the fetal point of view, a significant proportion of fetuses still require a postnatal VP shunt and many suffer from cord tethering after antenatal open fetal surgery⁴³. From the maternal point of view, PPRM is an important complication in almost 50% of cases of open fetal surgery, and the incidence of uterine thinning or dehiscence of nearly 36% is a major issue^{1,23}.

The fetoscopic approach is undoubtedly more challenging from a technical point of view, but has the potential to address all of the fetal and maternal shortcomings of the open fetal surgical approach. However, PPRM remains an important issue with which we still need to contend. Our skin-over-biocellulose closure technique overcomes the technical challenge associated with an entirely percutaneous approach while taking advantage of the unique healing properties of the fetus and of the intra-amniotic environment.

Concluding remarks

Prenatal compared with postnatal correction of OSB has proven to be of benefit to infants, but the open surgical approach is associated with significant maternal risks and long-term uterine injury. Our percutaneous fetoscopic repair technique is feasible and reliable, and is associated with infant outcomes as good as or better than those reported with open fetal surgery, without many of the associated maternal complications of the latter approach. Our technique is an improvement over previous OSB repair procedures and can be duplicated by others, thereby with the potential to become a new standard of care. Further research will be aimed at reducing the incidence of PPRM and reducing the operating time. Hopefully, such goals will not be unsurmountable and will allow the fetoscopic approach to become the surgical method of choice in the antenatal repair of OSB.

REFERENCES

- Adzick NS, Thom EA, Spong CY, Brock JW, 3rd, Burrows PK, Johnson MP, Howell LJ, Farrell JA, Dabrowiak ME, Sutton LN, Gupta N, Tulipan NB, D'Alton ME, Farmer DL; MOMS Investigators. A randomized trial of prenatal versus postnatal repair of myelomeningocele. *N Engl J Med* 2011; **364**: 993–1004.
- Pedreira DA, Zanon N, Nishikuni K, Moreira de Sá RA, Acacio GL, Chmait RH, Kontopoulos EV, Quintero RA. Endoscopic surgery for the antenatal treatment of myelomeningocele: the CECAM trial. *Am J Obstet Gynecol* 2016; **214**: 111.e1–11.
- Centers for Disease Control and Prevention (CDC). Notes from the field: investigation of a cluster of neural tube defects – central Washington, 2010–2013. *MMWR Morb Mortal Wkly Rep* 2013; **62**: 728.
- Orioli IM, Lima do Nascimento R, Lopez-Camelo JS, Castilla EE. Effects of folic acid fortification on spina bifida prevalence in Brazil. *Birth Defects Res A Clin Mol Teratol* 2011; **91**: 831–835.
- Oakeshott P, Hunt GM. Long-term outcome in open spina bifida. *Br J Gen Pract* 2003; **53**: 632–636.
- Oakeshott P, Hunt GM, Poulton A, Reid F. Open spina bifida: birth findings predict long-term outcome. *Arch Dis Child* 2012; **97**: 474–476.
- Stevenson KL. Chiari Type II malformation: past, present, and future. *Neurosurg Focus* 2004; **16**: E5.
- Chakraborty A, Crimmins D, Hayward R, Thompson D. Toward reducing shunt placement rates in patients with myelomeningocele. *J Neurosurg Pediatr* 2008; **1**: 361–365.
- Meuli M, Meuli-Simmen C, Hutchins GM, Seller MJ, Harrison MR, Adzick NS. The spinal cord lesion in human fetuses with myelomeningocele: implications for fetal surgery. *J Pediatr Surg* 1997; **32**: 448–452.

10. Meuli M, Meuli-Simmen C, Yingling CD, Hutchins GM, Hoffman KM, Harrison MR, Adzick NS. Creation of myelomeningocele in utero: a model of functional damage from spinal cord exposure in fetal sheep. *J Pediatr Surg* 1995; 30: 1028–1032; discussion, 1032–1033.
11. Biggio JR, Jr, Wenstrom KD, Owen J. Fetal open spina bifida: a natural history of disease progression in utero. *Prenat Diagn* 2004; 24: 287–289.
12. Meuli M, Meuli-Simmen C, Hutchins GM, Yingling CD, Hoffman KM, Harrison MR, Adzick NS. In utero surgery rescues neurological function at birth in sheep with spina bifida. *Nat Med* 1995; 1: 342–347.
13. Meuli M, Meuli-Simmen C, Yingling CD, Hutchins GM, Timmel GB, Harrison MR, Adzick NS. In utero repair of experimental myelomeningocele saves neurological function at birth. *J Pediatr Surg* 1996; 31: 397–402.
14. Tulipan N, Hernanz-Schulman M, Bruner JP. Reduced hindbrain herniation after intrauterine myelomeningocele repair: A report of four cases. *Pediatr Neurosurg* 1998; 29: 274–278.
15. Sutton LN, Adzick NS, Bilaniuk LT, Johnson MP, Crombleholme TM, Flake AW. Improvement in hindbrain herniation demonstrated by serial fetal magnetic resonance imaging following fetal surgery for myelomeningocele. *JAMA* 1999; 282: 1826–1831.
16. Wilson RD, Lemerand K, Johnson MP, Flake AW, Bebbington M, Hedrick HL, Adzick NS. Reproductive outcomes in subsequent pregnancies after a pregnancy complicated by open maternal-fetal surgery (1996–2007). *Am J Obstet Gynecol* 2010; 203: 209.e1–6.
17. Bruner JP, Tulipan NE, Richards WO. Endoscopic coverage of fetal open myelomeningocele in utero. *Am J Obstet Gynecol* 1997; 176: 256–257.
18. Bruner JP, Richards WO, Tulipan NB, Arney TL. Endoscopic coverage of fetal myelomeningocele in utero. *Am J Obstet Gynecol* 1999; 180: 153–158.
19. Dostal GH, Gamelli RL. Fetal wound healing. *Gynecol Obstet* 1993; 176: 299–306.
20. Krummel T, Longaker M. Fetal wound healing. In *The Unknown Patient*, Harrison MR, Golbus MS, Filly RA (eds). W.B. Saunders Company: Philadelphia, 1991; 526.
21. Lo DD, Zimmermann AS, Nauta A, Longaker MT, Lorenz HP. Scarless fetal skin wound healing update. *Birth Defects Res C Embryo Today* 2012; 96: 237–247.
22. Abou-Jamra RC, Valente PR, Araujo A, Sanchez e Oliveira Rde C, Saldiva PH, Pedreira DA. Simplified correction of a meningomyelocele-like defect in the ovine fetus. *Acta Cir Bras* 2009; 24: 239–244.
23. Pedreira DA, Sanchez e Oliveira Rde C, Valente PR, Abou-Jamra RC, Araujo A, Saldiva PH. Validation of the ovine fetus as an experimental model for the human myelomeningocele defect. *Acta Cir Bras* 2007; 22: 168–173.
24. Pedreira DA, Valente PR, Abou-Jamra RC, Pelarigo CL, Silva LM, Goldenberg S. A different technique to create a 'myelomeningocele-like' defect in the fetal rabbit. *Fetal Diagn Ther* 2002; 17: 372–376.
25. Pedreira DA, Valente PR, Abou-Jamra RC, Pelarigo CL, Silva LM, Goldenberg S. Successful fetal surgery for the repair of a 'myelomeningocele-like' defect created in the fetal rabbit. *Fetal Diagn Ther* 2003; 18: 201–206.
26. Mello LR, Feltrin LT, Fontes Neto PT, Ferraz FA. Duraplasty with biosynthetic cellulose: an experimental study. *J Neurosurg* 1997; 86: 143–150.
27. Mello L, Alcantara B, Bermardes C, Boer V. Late favorable results of duroplasty with biocellulose: clinical retrospective study of 20 cases. *Arq Bras Neurocir* 2012; 31: 128–134.
28. Pedreira DA, Oliveira RC, Valente PR, Abou-Jamra RC, Araujo A, Saldiva PH. Gasless fetoscopy: a new approach to endoscopic closure of a lumbar skin defect in fetal sheep. *Fetal Diagn Ther* 2008; 23: 293–298.
29. Sanchez e Oliveira Rde C, Valente PR, Abou-Jamra RC, Araujo A, Saldiva PH, Pedreira DA. Biosynthetic cellulose induces the formation of a neoduramater following pre-natal correction of meningomyelocele in fetal sheep. *Acta Cir Bras* 2007; 22: 174–181.
30. Danzer E, Adzick NS, Rintoul NE, Zarnow DM, Schwartz ES, Melchioni J, Ernst LM, Flake AW, Sutton LN, Johnson MP. Intradural inclusion cysts following in utero closure of myelomeningocele: clinical implications and follow-up findings. *J Neurosurg Pediatr* 2008; 2: 406–413.
31. Mangels KJ, Tulipan N, Bruner JP, Nickolaus D. Use of bipedicular advancement flaps for intrauterine closure of myeloschisis. *Pediatr Neurosurg* 2000; 32: 52–56.
32. Pedreira DA, Quintero RA, Acacio GL, Caldini ET, Saldiva PH. Neoskin development in the fetus with the use of a three-layer graft: an animal model for in utero closure of large skin defects. *J Matern Fetal Neonatal Med* 2011; 24: 1243–1248.
33. Pedreira DA. Keeping it simple: a "two-step" approach for the fetoscopic correction of spina bifida. *Surg Endosc* 2010; 24: 2640–2641; author reply, 2642–2643.
34. Pedreira DA, Zanon N, de Sá RA, Acacio GL, Ogeda E, Belem TM, Chmait RH, Kontopoulos E, Quintero RA. Fetoscopic single-layer repair of open spina bifida using a cellulose patch: preliminary clinical experience. *J Matern Fetal Neonatal Med* 2014; 27: 1613–1639.
35. Herrera SR, Leme RJ, Valente PR, Caldini EG, Saldiva PH, Pedreira DA. Comparison between two surgical techniques for prenatal correction of meningomyelocele in sheep. *Einstein* 2012; 10: 455–461.
36. Kohl T, Hering R, Heep A, Schaller C, Meyer B, Greive C, Bizjak G, Buller T, Van de Vondel P, Gogarten W, Bartmann P, Knopfle G, Gembruch U. Percutaneous fetoscopic patch coverage of spina bifida aperta in the human—early clinical experience and potential. *Fetal Diagn Ther* 2006; 21: 185–193.
37. Kohl T, Tchatcheva K, Weinbach J, Hering R, Kozlowski P, Stressig R, Gembruch U. Partial amniotic carbon dioxide insufflation (PACI) during minimally invasive fetoscopic surgery: early clinical experience in humans. *Surg Endosc* 2010; 24: 432–444.
38. Kohl T, Ziemann M, Weinbach J, Tchatcheva K, Gembruch U, Hasselblatt M. Partial amniotic carbon dioxide insufflation during minimally invasive fetoscopic interventions seems safe for the fetal brain in sheep. *J Laparoendosc Adv Surg Tech A* 2010; 20: 651–653.
39. Kohl T, Tchatcheva K, Merz W, Wartenberg HC, Heep A, Muller A, Franz A, Stressig R, Willinek W, Gembruch U. Percutaneous fetoscopic patch closure of human spina bifida aperta: advances in fetal surgical techniques may obviate the need for early postnatal neurosurgical intervention. *Surg Endosc* 2009; 23: 890–895.
40. Verbeek RJ, Heep A, Maurits NM, Cremer R, Hoving EW, Brouwer OF, van der Hoeven JH, Sival DA. Fetal endoscopic myelomeningocele closure preserves segmental neurological function. *Dev Med Child Neurol* 2012; 54: 15–22.
41. Kohl T. Percutaneous minimally invasive fetoscopic surgery for spina bifida aperta. Part I: surgical technique and perioperative outcome. *Ultrasound Obstet Gynecol* 2014; 44: 515–524.
42. Degenhardt J, Schürig R, Winarno A, Oehmke F, Khaleeva A, Kawecki A, Enzensberger C, Tinneberg HR, Faas D, Ehrhardt H, Axt-Flidner R, Kohl T. Percutaneous minimal-access fetoscopic surgery for spina bifida aperta. Part II: maternal management and outcome. *Ultrasound Obstet Gynecol* 2014; 44: 525–531.
43. Adzick NS. Fetal surgery for myelomeningocele: trials and tribulations. Isabella Forshall Lecture. *J Pediatr Surg* 2012; 47: 273–281.
44. Graf K, Kohl T, Neubauer BA, Dey F, Faas D, Wanis FA, Reinges MH, Uhl E, Kolodziej MA. Percutaneous minimally invasive fetoscopic surgery for spina bifida aperta. Part III: neurosurgical intervention in the first postnatal year. *Ultrasound Obstet Gynecol* 2016; 47: 158–161.
45. Belfort MA, Whitehead WE, Shamshirsaz AA, Ruano R, Cass DL, Olutoye OO. Fetoscopic repair of meningomyelocele. *Obstet Gynecol* 2015; 126: 881–884.
46. Bealer JF, Raisanen J, Skarsgard ED, Long SR, Wong K, Filly RA, Adzick NS, Harrison MR. The incidence and spectrum of neurological injury after open fetal surgery. *J Pediatr Surg* 1995; 30: 1150–1154.
47. Kohl T. Impact of partial amniotic carbon dioxide insufflation (PACI) on middle cerebral artery blood flow in mid-gestation human fetuses undergoing fetoscopic surgery for spina bifida aperta. *Ultrasound Obstet Gynecol* 2016; 47: 521–522.

SUPPORTING INFORMATION ON THE INTERNET

The following supporting information may be found in the online version of this article:



Table S1 Review of surgical techniques and patches, aiming to correct a meningomyelocele-like defect in fetal sheep, published between 1993 and 2009 (adapted from Abou-Jamra *et al.*²², with permission).