

SCOTOMATA IN MIGRAINOUS SUBJECTS

BY

T. HARRISON BUTLER

BIRMINGHAM

THE cause of migraine is, so far, wrapped in mystery and is likely to be elucidated only by a careful study of a large number of cases. For this reason I feel that the two following examples may be of some interest, in that they both had definite scotomata that could be accurately mapped out, and that in both there was a possibility of papilloedema. I say a *possibility* because there are many discs of the "embryonic" type, shewing sheaths on the vessels, and films over the disc that are difficult to distinguish from the appearance left by a past neuritis. In the first case this condition was found on one side only, and this was the side affected. The embryonic discs are generally bilateral. In the other case the appearances on one side seemed to be more marked on a second examination. Probably in both cases the discs were of the embryonic type, and the association with other symptoms was a coincidence.

The notes of the two cases are as follows:—

Mr. T. J. W., aged 47 years. *History*.—From the age of 15 to 35 years he was subject to violent headaches associated with spots before his eyes, scintillating scotomata, hemianopia, and numbness in the arms. For the past 12 years he has been completely free from headache and other symptoms of migraine.

A month ago he was making adjustments to his car with the engine running in a closed garage. He became giddy, and when he recovered from this vertigo he found that he was practically blind in the right eye. This blindness was almost complete, but he had some perception of light. He also had violent pain in the right frontal and parietal region, but he has had no recurrence of scintillating scotomata or numbness in the arm. The sight of the right eye gradually improved but is still very poor.

Condition when seen on July 13, 1931.

V. R. = 5/60. Not improved with glasses.

V. L. = 6/4.

No material error of refraction.

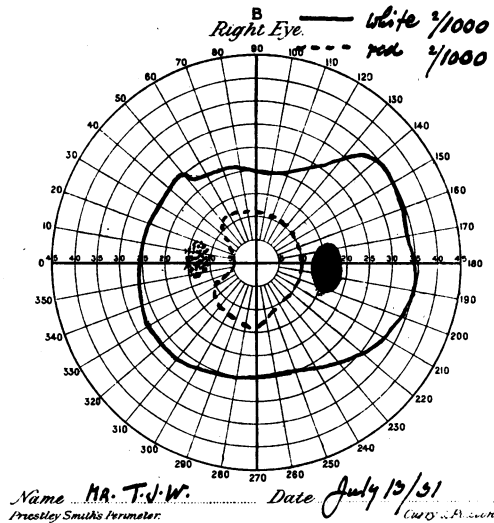
Fundi: the right disc shews an appearance which might be due to a past neuritis, but could also be caused by the persistence of embryonic structures. The nasal edge is blurred, there is a delicate filmy appearance on the surface of the disc, and there are sheaths on the arteries on the discs.

The left disc is normal.

Fields. The left field is normal.

The right field for white shews general contraction.

The field for red shews a reniform contraction on the nasal side. There is a relative scotoma on the nasal side. It is of the same size as the normal blind spot, and is in a position on the nasal



side of the field symmetrical with that of the actual blind spot. One may say that in this eye there are two blind spots, one on each side of the fixation point.

The patient still complains of pain in the right frontal and parietal areas.

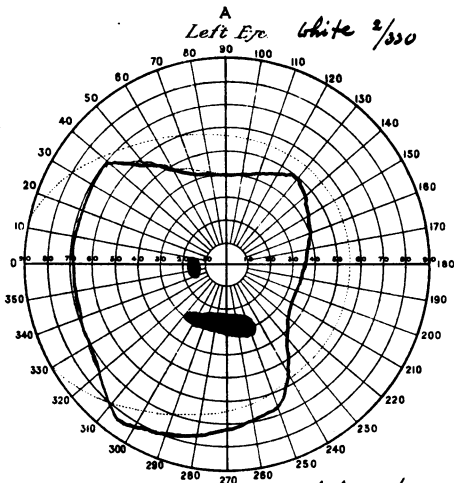
He was examined by a physician who found nothing wrong with his central nervous system. He was of the opinion that he was suffering from migraine and carbon-monoxide poisoning.

Unfortunately, being a private patient, I saw him once only, and was unable to get any X-ray pictures of his sellar region. My information from his doctor is that he has made a complete recovery and now has good acuity in the right eye.

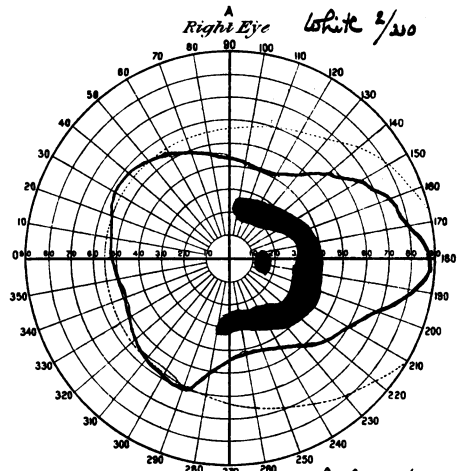
Mr. Hugh Cairns, whose advice I sought upon this case, writes as follows:—"I would not like to venture an opinion on the cause of the scotoma, and the alteration in the red field, though it seems to me that with a history of sudden blindness and the appearance of the disc that you describe, a destruction of a few fibres of the optic nerve might conceivably occur anywhere. Taking the rest of the case as a whole from the information that you give me, it

seems most likely that this man has an aneurysm. I have seen several cases of aneurysm that were preceded by a long history of migraine, and furthermore the sudden failure of vision limited to one eye, and followed by complete recovery is very suggestive. Under such circumstances I should expect that a good X-ray picture would shew erosion of the right anterior clinoid process."

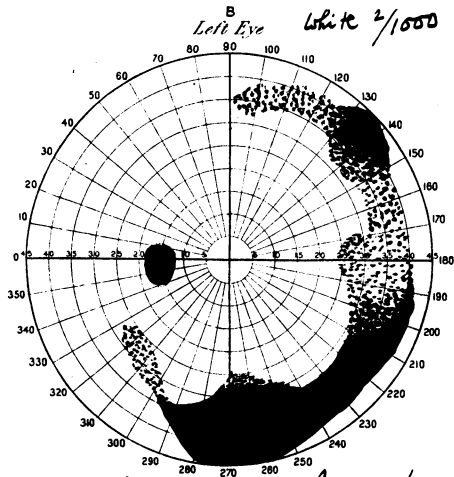
Mrs. L. B., aged 45 years. *History*.—For years has suffered from violent headaches especially at the menstrual periods,



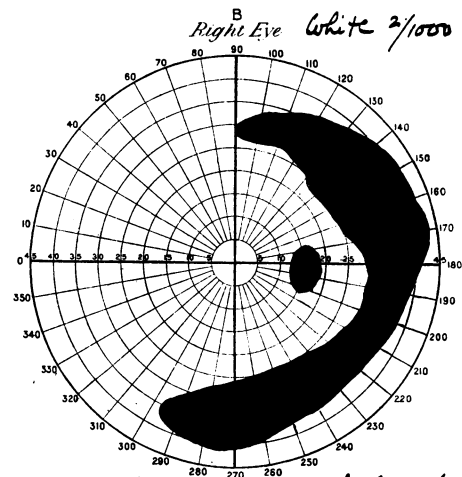
Name Mrs L. B. Date July 27/31
Prestley Smith's Perimeter. Carry & Paxton.



Name Mrs L. B. Date July 27/31
Prestley Smith's Perimeter. Carry & Paxton.



Name Mrs L. B. Date July 27/31
Prestley Smith's Perimeter. Carry & Paxton.



Name Mrs L. B. Date July 27/31
Prestley Smith's Perimeter. Carry & Paxton.

associated with scintillating scotomata. She vomits and suffers from frequent nausea. She is now getting symptoms of the menopause. During the past five years she has had attacks of vertigo. About eighteen months ago she had visual hallucinations of an organised type. She saw a man's form. Her husband states that his wife's temper has been getting very bad, and that she has become very difficult to live with.

Condition when first seen July 15, 1931. A highly neurotic woman. Below the left eye there is a haemangiomatic area.

V. R. c. +1.0 D. sph. = 6/7.5. V.L. c. +1.0 D. sph. = 6/7.5

8° of near and 12° of far esophoria.

Fundi: Both discs shew tenuous films over the disc, the nasal edges are blurred, and there are well-defined sheaths on the roots of the arteries. This appearance suggests either an embryonic "rest," or a past neuritis.

Fields. Both fields shew slight general contraction.

In each there is a hemianopic crescentic scotoma. This is absolute in the right eye; in the left it is partly absolute and partly relative. The blind spots are normal.

X-ray pictures of the skull. These were taken by Dr. Edmund Jones of Leamington. He reports that the skull is normal. The sella is large, but cannot be considered to be pathologically altered. A lateral view shews no signs of increased intra-cranial pressure. The sinuses are normal. The optic foramina are normal.

The patient was referred to Mr. Hugh Cairns who examined her on October 7, 1931.

He found no trace of the annular scotomata present on July 27. Examination of the C.N.S. revealed no abnormality. He was unable from one examination to make a definite diagnosis, but he suggested that the condition might be due to an aneurysm.

I examined this patient on November 30, 1931.

I could find no trace of the annular scotoma, the fields were normal in all respects. The acuity had increased to 6/6 partly right, and 6/5 partly left. She felt much better. Her headaches were less violent. She had occasional vomiting and slight vertigo. She still felt very depressed.

The appearance of papilloedema appears now to be more marked on the right side but less on the left.

It seemed to me that the second case might support the view held by Fisher and others that migraine is at any rate in some cases due to swelling of the pituitary gland. I therefore submitted the notes of both cases to Mr. Fisher and to Mr. Traquair for their opinions.

Mr. Traquair writes as follows.—“Mr. T. J. W. This case might well be due to vascular spasm. The history of migraine in his younger days is suggestive. It is evident that the interference must have been either in the right optic nerve or in the retina. It is impossible to exclude an aneurysm, but there is no evidence of this. Mrs. L. B. This case appears to me to be an ordinary migraine with temporary hemianopic scotomata. Here again the possibility of aneurysm cannot be absolutely excluded, though there is no positive evidence. The difficulty in this case is the increasing papilloedema. If this is actually the case some definite lesion must be present. It is true that recently in some cases with a history of “migraine” aneurysms have been discovered and from this a tendency has arisen to assume that any case of migraine may be due to an aneurysm of the Circle of Willis, but such are usually associated with more definite evidence of permanent change such as paresis of an ocular muscle or definite field changes of hemianopic type.”

Mr. J. H. Fisher writes:—“Mr. T. J. W. I am inclined to agree with Cairns, and do not think that he had carbon monoxide poisoning; if overcome by this he would probably have died if not succoured by someone else. A sudden haemorrhage would account for his symptoms, and if from an aneurysm, say on the anterior cerebral artery, it might well involve the intra-cranial portion of the right optic nerve. The sudden onset, the rapid blindness, and violent pain all seem to support this theory.

As regards Mrs. L. B.:—I still think that some forms of “migraine” are due to transitory tumefaction of the pituitary body. I think that Mrs. L. B. is one of this type. I do not think that the annular scotomata in this case can be explained by anything but an implication of the optic tract or its central communications. The organised type of hallucination, it is true, suggests a sub-cortical irritation in the left half-vision centre.”

I have seen Mrs. L. B. recently and she is very much improved. There has been no recurrence of the annular scotoma, and the headaches are better. I have lost sight of Mr. T. J. W.

I think that the former is a pure case of migraine, but the definite scotomata are most interesting. Mr. T. J. W. probably suffered from a vascular lesion, and the association with migraine is probably fortuitous.
