

THE BRITISH JOURNAL OF OPHTHALMOLOGY

MARCH, 1927

COMMUNICATIONS

COLOBOMA AT THE MACULA (BOTH EYES)

BY

ERNEST CLARKE, C.V.O.

LONDON

THE coloured Plate shows pictures of the fundi of a young man first seen by me thirty years ago. At that time I had a consultation with the late Mr. Henry Juler, who agreed that the case was one of a so-called coloboma at the macula in both eyes. We took a rather gloomy view of this child's prospects which fortunately has not been realized as he went normally through Harrow School, took his degree at Cambridge, and has always been fairly good at games, especially tennis.

Both pictures show a large defective area at the macula about three and a half discs in breadth and two in height. In the centre of this area there is a circular pearly-white region a little larger than the disc, ectatic and free from pigment, and on the left side a ciliary artery perforates this. The surrounding area in both cases is marked by patches of pigment, each having a pale centre. There has been no material change in the appearance of the fundi since he was first seen. There is no defect of colour vision. At five years of age the myopia was 5D. in the right eye, and is now 11D. with 0.5D. cyl. The left has a myopia of 5.5D. with 0.75D. cyl. As a baby he had horizontal nystagmus, but that has now disappeared. The patient never looks one straight in the face, but slightly obliquely. Now with correction his vision is 6/24 with both eyes. He has good near vision and can read J.2. At

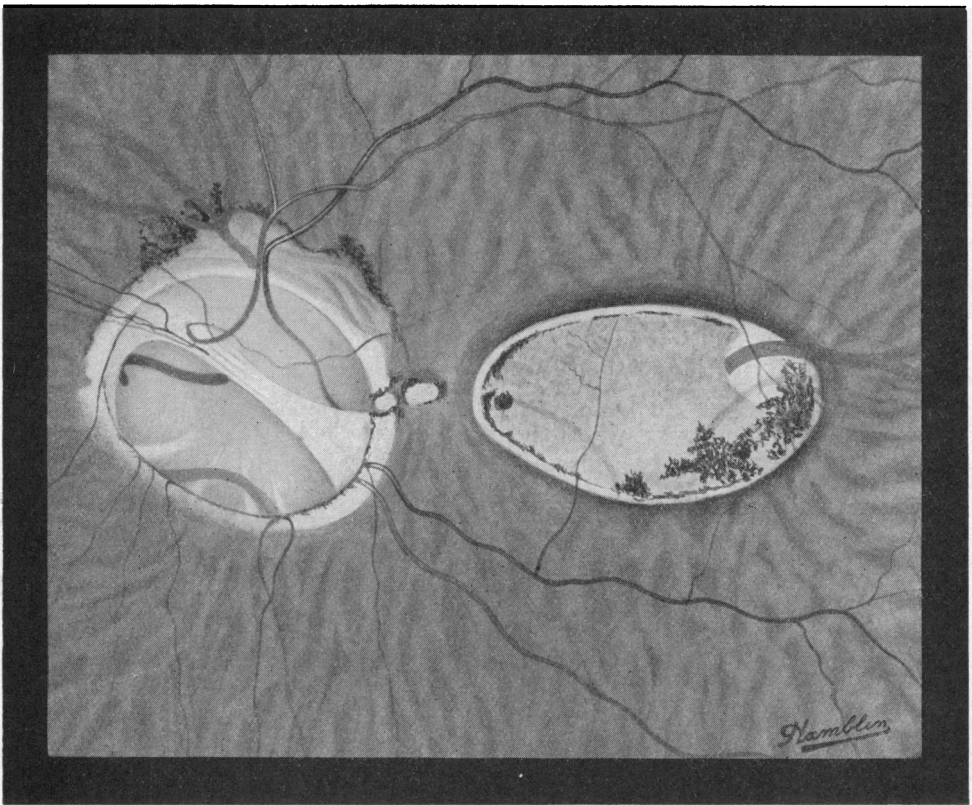
birth he had other congenital defects indicating arrest of development, such as undescended testes, and had development of most of the facial bones.

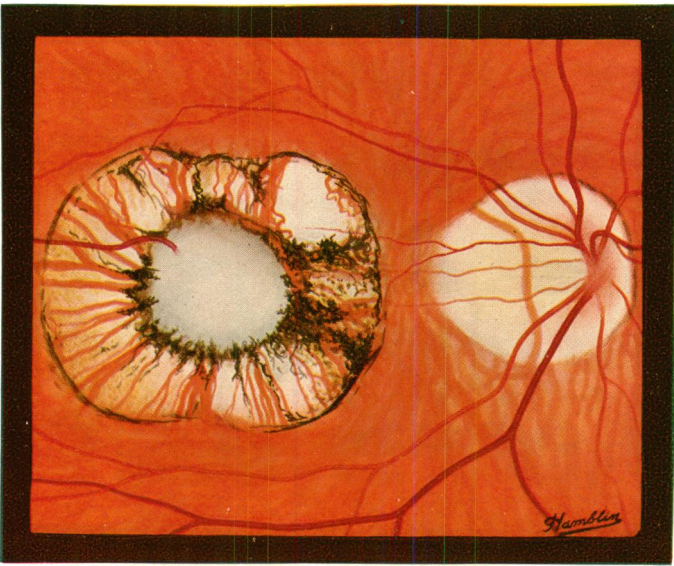
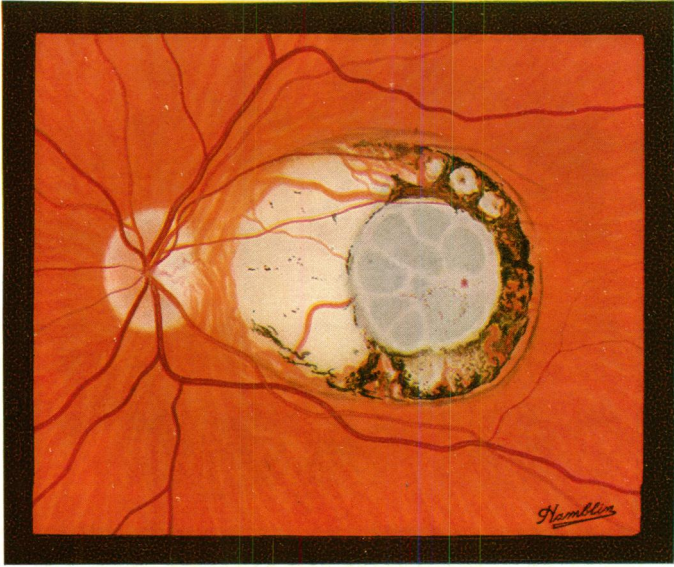
According to Miss Ida Mann this case comes into her second class and is the sequel of a destructive inflammatory process taking place about the fourth or fifth month of embryonic life and ought not to be called one of coloboma.

According to Mr. Treacher Collins, on the other hand, it is an atypical coloboma of the choroid caused by the arrest of development and consequent absence of the shorter ciliary arteries supplying the particular region affected. It is a very unique case, as is also Mr. Goulden's, and if atypical colobomata do exist, these cases surely come into that category. Mr. Goulden's case is as follows :

G.G., male, aged 40 years.

He knew that the left eye had been very defective as long as he could remember, and that it had always excited considerable interest in any oculist he had consulted. The right eye was healthy





in all respects and with a correction of +2.25D. sph. and +1.0D. cyl. ax. 80° read 6/5 and Jaeger 1.

The left eye showed a marked degree of microphthalmus, a shallow anterior chamber and well marked threads of persistent pupillary membrane. The vision with +9.0D. sph. was only hand reflex.

The accompanying sketch shows the condition of the fundus. The optic papilla was represented by a very deep and extensive cup, brilliantly white in colour. The lower part was deeper than the upper, and, dividing the two parts, was a transverse strand of what appeared to be fibrous tissue. The vessels were anomalous, in the lower part of the cup disappearing suddenly over its edge, but in the upper part passing gradually from the retinal level on to the cup. The cup was surrounded by a white ring of varying width edged in places by a finely-dotted pigment. In the upper part of the ring some ill-developed choroid was seen.

Between the disc and the macula there was a small area of bare sclera oval in outline. The macular area was occupied by a large oval area roughly white in colour but stippled over with fine brownish dots. The major axis of the oval was transverse, and the whole was slightly sunken. Two choroidal vessels were seen in the upper and outer part of this oval and another down and in. Down and out there was a large collection of fine pigment which extended around the periphery throughout.

ON CERTAIN ABNORMAL CONDITIONS OF THE MACULAR REGION USUALLY CLASSED AS COLOBOMATA*

BY

IDA C. MANN

LONDON

CERTAIN abnormalities of the macular region are usually classed as congenital colobomata. The main reasons for so regarding them appear to be, in the first place, that there is never any certain history of onset, though there may be a history of sudden discovery of the defect, and in the second place, that they are quite stationary throughout life. To this it may also be added that they have been found occasionally in very young children, and that a certain number of them occur in association with some other abnormality known to have been present at birth. On these grounds they are classified as congenital. The term "coloboma" appears to be

* Work done under a grant from the Medical Research Council.