

subconjunctival injections of penicillin should be combined from the start with local and general vitamin A therapy, atropine ointment to the eye, as well as with any appropriate general treatment.

Summary

A detailed description of a case of keratomalacia in an infant is given. Details of the treatment used and the progress made are mentioned.

A comment is made as to the proper treatment of keratomalacia with penicillin and vitamin A, with reference to the aetiological factors in this disease.

REFERENCES

- GRAVES, BASIL (1936).—*The Eye and its Diseases*. Edited by Berens, p. 521.
 PARSONS, J. H. (1934).—*Diseases of the Eye*. Seventh edition, p. 220.
 SORSBY, A. (1946).—*The Practitioner*, Vol. CLVII, p. 67.
 SORSBY, A. and UNGAR, J. (1947).—*Brit. Jl. Ophthalm.*, Vol. XXXI, p. 517.

ON GENESIS AND OPERATION OF THE CICATRICIAL (TRACHOMATOUS) ENTROPION OF THE UPPER LID

BY

Prof. A. KETTESY

DEBRECEN

MOST operations for trachomatous entropion assume that the cause is the progressively incurved tarsus. Accordingly the solution has been sought in the straightening out of the tarsus, hence the operations of Celsus, Hotz, Nicati, Streatfeild, Snellen, Blaskovics, and their many modifications, generally with unsatisfactory results. Kuhnt's tarsectomy is an exception.

Observing closely the slow changes of the trachomatous entropion, it is not difficult to state, the turning of the tarsus appears late in the trachomatous process, preceded by a long and often stationary period, during which the intermarginal surface gradually merges with the conjunctival surface of the tarsus.

The entropion begins with the cicatricial shrinking of the tarsal conjunctiva, contracting into the well-known linear scar of the sulcus subtarsalis. The shrinking displays a traction in one direction upon the fornix, drawing it downwards, in the other direction upon the inner edge of the intermarginal surface. Thus arises the first stage of the cicatricial entropion: the rounding off of the posterior edge of the intermarginal surface. The line of the openings of the Meibomian ducts is directed against the eye.

The contraction continues and the intermarginal surface of the tarsus is rounded off into the conjunctival tarsal surface. In this second stage we see a sharp edge instead of the intermarginal surface; skin and conjunctiva are meeting in a line running just on to the surface of the eyeball.

As the contraction still progresses this line is also drawn inside. Only in this third stage is the eye coming in contact with skin. In very severe cases it happens that we see a fourth and last stage, when the tarsus itself has become crooked and deformed.

The trichiasis is only secondary: the effect of the drawing power, running along the surface of the lid reaches the line of the lashes,

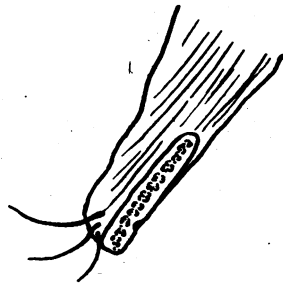


FIG. 1.

first the hindmost; in consequence of which the row of the cilia opens like a fan (Fig. 1).

We do not see always the above described regular progress, yet the same basic process and one of the stages may be always recognised.

From these changes the right solution can be deduced: the posterior half of the intermarginal surface has to be re-made, possibly of the same tissue and of course to last. There are proceedings that attain some more or less expressed posterior intermarginal surface as a by-result, while the aim has been to straighten out the tarsus or to raise the row of the eye-lashes.

Likewise, it is easy to understand, that all the operations called margino- or intermarginoplastics, cannot be of any use for trachomatous entropion. They all presume an intact tarsus and a normal posterior half of the intermarginal surface. Kuhnt's tarsectomy removes the support of the tarsal margin, therefore this is turning downwards, making a more or less expressed posterior intermarginal surface. Blaskovics' tarsoplasty (*inversio tarsi*) is the best example of the fact, that an operation devised on wrong conceptions may produce a good result.

Blaskovics intended to make an inverse curvature of the tarsus by turning it 180 degrees around its vertical axis. Of course this

could not lead to any result, but the execution of his idea made a tarsal incision necessary, bereaving the lower part of the tarsus of its support. As in Kuhnt's tarsectomy it produced a turning down of the marginal strip, uniting more or less rectangularly with the superior part of the tarsus.

We have had the opportunity of performing a long series of Blaskovics' tarsoplasty. From the comparison of the successful and unsatisfactory cases and from the interpretation of its manner

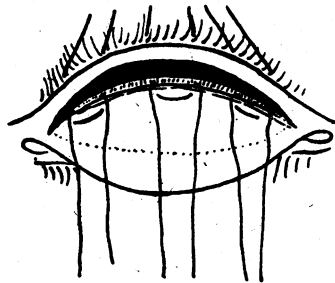


FIG. 2.

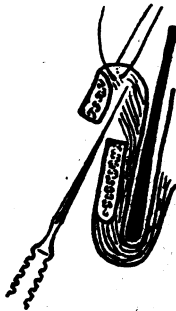

FIG. 3.

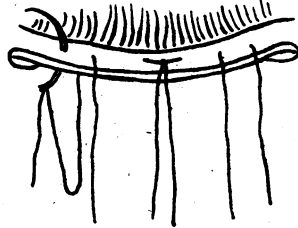


FIG. 4.

of acting, we have devised a new operation, the remodelling of the intermarginal surface out of the tarsus in a safe and simple way:

1. The upper lid is everted by Liebermann's sutures. Incision of the tarsus in the scar-line of the sulcus subtarsalis. The section has to penetrate through the tarsus perpendicularly and must divide it completely in its thickness and length.

2. Three mattress-sutures are inserted into the conjunctival margin of the section (Fig. 2). Every loop is about 4 mm. long. We take up also some tarsal tissue.

3. In order to facilitate the turning out of the marginal tarsal strip, we make an incision all along behind it, without buttonholing the skin (Fig. 3).

4. Lid-plate and Liebermann's sutures are removed, mattress sutures arranged, re-armed and brought through the marginal tarsal strip. The result depends chiefly on the correct position of these sutures. They have to go perpendicularly through the middle of the tarsal surface (Fig. 4).

5. After having them loosely knotted (in order to avoid cutting in during the next few days), the diverging ends are brought horizontally through the skin of the lid 10-12 mm. higher and knotted (Fig. 5). Thus we are preventing the tilting over of the new intermarginal surface and secure a thorough over-correction.

Vaseline dressing under slight pressure is made. Two days later the knots in the skin are removed. It would not be advisable to

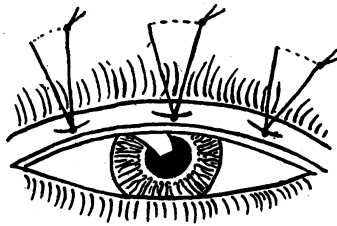


FIG. 5.

leave them any longer, they could cut into the lid-margin. The intermarginal sutures are removed on the sixth day.

Immediately after the operation we might consider that we had too much of an over-correction. We should never be afraid of it. The cicatricial contraction between the two tarsal pieces produces a rectangular position in any case; and 8-10 days later we see this result.

I have been performing this operation since 1930 for all stages and forms of trachomatous entropion with evenly satisfying result. It was published in *Ophthalmologica* in the year 1939, yet not exactly in the form now described, as the "turning out sutures," and some smaller modifications are newer additions. On the other hand the "folding sutures" proved to be superfluous. There I have presented photographs too; unfavourable changes in our life since that time have prevented further photographic recording.

In the above mentioned publication I have already pointed out that there are important differences between my proceeding and that of Panas, Sie-Boe-Lian, and Miric, who also make an incision in the sulcus subtarsalis and strive to attain rectangular apposition of the two tarsal pieces.

Lastly I would lay stress on the fact that I have had bad experience with all kinds of beads, rolls and any other pads laid below the knot in order to avoid cutting in of the sutures as it has

been so often recommended for the lid-margin. They all lead too easily to depressions or decubital ulcers, on the lid-margin which are particularly disfiguring. The exact but not tight simple knotting is the safest way, according to our experience.

**CONTRIBUTION TO DATA ON SIGHT DISTURBANCES
CAUSED BY PROLIFERATION OF
PIGMENT EPITHELIUM* †**

(An unusual complication after cataract extraction)

BY

MAGDA RADNÓT

BUDAPEST

SIGHT disturbance of patients suffering from iridocyclitis and glaucoma may be caused by pigment deposits on the capsule of the lens.

In the case of iridocyclitis, especially when enlargement of the pupil is not performed in time, granulated pigment is found sometimes on the place of the synechia posterior. This is a remainder of the pigment epithelium. Correspondingly a lack of pigment may arise in the iris. After a time the pigment on the capsule of lens may gradually disappear.

It is well known that in the case of glaucoma the pigment of the iris may be scattered as this fact is mentioned as one of the causes for glaucoma. In such cases lots of pigment may be observed partly on the posterior surface of the cornea partly on the capsule of lens. In eyes treated for a long time with pilocarpine, pigment cysts are developed, pictures of them can be seen in Vogt's atlas. Pupils constantly contracted with pilocarpine, if they are allowed to enlarge, or are enlarged if possible with tonogen (adrenaline) show a surprising amount of pigment deposited on the capsule of the lens.

A remarkable and generally known change is that of the pigment epithelium of the iris and ciliary body in case of diabetes. The pupillary pigment layer is swollen and grey instead of being black as may sometimes be observed with a slit-lamp. This depigmentation is easily to be distinguished from injury or inflammation-caused depigmentation. This latter is usually discontinuous compared with the homogeneous depigmentation known in cases of diabetes. The aqueous humour of the anterior chamber flowing away at cataract

* From the No. II Eye Clinic of the University of Budapest (Chief : Professor T. Nónay).

† Received for publication, February 9, 1948.