

In conclusion I wish to record my especial thanks to the Senior Specialist, Dr. W. A. Young, for the encouragement he has given me in this work, for much constructive criticism and in particular for his help in supplying the references quoted in the section dealing with syphilis.

I am indebted to the Director of Medical Services, Tanganyika Territory, for permission to submit this paper for publication.

REFERENCES

- DUKE-ELDER, SIR STEWART.—Text-book of Ophthalmology. Vol. III, 1945.
PARSONS, SIR JOHN H.—Diseases of the Eye. 1942.
ELLIOT, R. H.—Tropical Ophthalmology. 1920.
MANSON-BAHR, SIR PHILIP H.—Manson's Tropical Diseases. 1941.
MOORE, JOSEPH EARLE.—The Modern Treatment of Syphilis. 1944.
MOORE, J. E. and GIESKE, M.—Syphilitic Iritis. *Amer. J. Ophthal.*, Vol. XIV, p. 110, 1931.
ZIMMERMANN, E. L.—Syphilitic Iridocyclitis with a Consideration of Factors Influencing its Occurrence. *Arch. Ophthal.*, Vol. LIII, p. 549, 1924.
——— The Role of the Arsphenamines in the Production of Ocular Lesions. *Arch. Ophthal.*, Vol. LVII, p. 509, 1928.

AMNIOTIC MEMBRANE GRAFTS IN CAUSTIC BURNS OF THE EYE*

(Burns of the second degree)

BY

ARNOLD SORSBY

LONDON

and

H. M. SYMONS

TUNBRIDGE WELLS

THAT caustic burns of the eyes produce more ultimate damage than the immediate reaction would suggest and that recovery is always protracted is a common experience. To overcome corneal damage developing during the course of the affection, and to avoid conjunctival complications as exemplified by symblepharon, a variety of procedures have been suggested. Neutralization of the caustic appears to be of little use, whilst for severe burns immediate excision of the damaged conjunctiva, as advocated by Denig, seems to be valuable. The pathology of caustic burns, is, however, far from clear. How much of the damage is produced instantaneously and irreversibly is not known, nor is it known how

* Received for publication, April 4, 1946.

lesions in the cornea come to be developed as late manifestations. These might conceivably be delayed reactions to the instantaneously acting irritant, or the sequel to irritant products of the conjunctival lesion. Though there are many experimental studies on these points, no clear conclusions appear to be possible.

This lack of precision is reflected in the therapeutic measures. The Denig procedure is apparently based on the assumption that irritants liberated by the necrosed conjunctiva are the essential noxious agents. A. L. Brown (*Arch. Ophthalm.*, Vol. XXVI, p. 754, 1941) holds, on clinical and experimental evidence, that the apposition of inflamed surfaces tends to maintain the inflammatory reaction and advocates separating the opposing surfaces by a graft of fat-free peritoneum from the rabbit. Both Bulson and Masters in discussing Brown's paper from personal experience supported his procedure but stressed that rabbit's peritoneum tended to act as an irritant.

Clinical findings in 30 cases of caustic burn treated by grafting with amniotic membrane

Brown's suggestion that inflamed surfaces should be kept apart seems clinically sound. It was felt that amniotic membrane of human origin might be more suitable than rabbit's peritoneum. An opportunity to test this presented itself in a patient who responded but poorly to the classical methods of conservative treatment.

Case report. T.D., aged 50 years, ten days ago sustained a moderately severe lime burn which had involved the upper and lower fornices and the lower third of the cornea. He had been receiving the usual in-patient treatment including atropine, irrigations, and the daily passage of a glass rod round the fornices to prevent symblepharon formation. On the tenth day the lower third of the cornea still stained with fluorescein and the bulbar and palpebral conjunctiva of the lower fornix showed the ulcerated and marbled appearance typical of this type of burn. An amniotic membrane graft was applied so as to separate the affected conjunctival surfaces. The eyes were bandaged for two days and at the end of that time it was found that the whole appearance of the burn had altered considerably. The conjunctiva had become more normal in colour, had a smooth surface and no longer stained with fluorescein. The corneal abrasion had also healed. Observation was continued for a few days; vision was now 6/6 and as the eye was white no further treatment was found to be necessary.

This encouraging result led to a more extensive trial of the method. To date thirty burns have been treated. The details are shown in Table I and the following summary gives the essential features in this series:—

TABLE I

Clinical details on caustic burns healed by amniotic graft

Successive No. in series.	Age	Extent of cornea involved	Conjunctival fornices involved	No. of days when grafted after burn	Days in hospital	Final vision (with correction)	Nature of caustic	Remarks
1	50	Lower 1/3	Upper and lower	10	17	6/6	Lime	—
2	20	Lower 1/4	Upper and lower	4	9	6/5	Lime	—
3	40	Complete	Upper and lower	6	21	6/9	Lime	Lime 4 days in fornices
4	64	Lower 1/3	Lower	2	10	6/9	Lime	—
5	52	Lower 1/3	Lower	2	8	6/9	Lime	—
6	30	None	Lower	2	5	6/6	Hydrochloric acid	—
7	16	Lower 1/3	Lower	1	5	6/5	Lime	—
8	17	Lower 1/3	Lower	2	7	Not recorded	Lime	—
9	25	Lower 1/4	Upper and lower	2	12	6/5	Lime	—
10	56	Lower 1/4	Upper and lower	3	17	Not recorded	Lime	—
11	43	Lower 1/4	Upper and lower	5	18	6/9	Lime	—
12	64	Complete	Upper and lower	5	64	P.L.	Ammonia	—
13		Complete	Lower	6	64	6/6	Ammonia	—
14	16	Lower 1/4	Upper and lower	3	10	6/6	Sodium hydroxide	—
15	39	None	Lower	2	5	6/6	Hydrochloric acid	—
16	15	Lower 1/4	Lower	3	15	6/9	Lime	One strand of symblepharon
17	50	Lower 1/4	Lower	2	10	6/6	Lime	—
18	50	Lower 1/4	Lower	2	6	6/6	Lime	—
19	37	Lower 1/4	Lower	3	11	6/6	Lime	—
20	17	Lower 1/4	Lower	5	7	6/6	Sodium hydroxide	—
21	48	Complete	Upper and lower	3	27	6/6	Lime	Two grafts (on 3rd & 35th day)
22	24	Lower 1/4	Upper and lower	2	2	6/6	Lime	—
23	36	Lower 1/4	Lower	0	—	6/6	Lime	Grafted in out-patient dept.
24	32	Lower 1/4	Lower	0	5	6/6	Lime	ditto
25	47	Lower 1/4	Lower	0	7	6/12	Lead	ditto
26	14	1/4	Lower	0	2	6/6	Lime	—
27	39	Lower 1/4	Upper and lower	0	4	6/6	Lime	—
28	38	Lower 1/4	Lower	3	9	6/6	Sulphur dioxide liquid	—
29	16	Lower 1/4	Lower	2	5	6/6	Lime	—
30	38	Lower 1/3	Lower	0	—	6/6	Lime	Graft done in out-patient dept.

1. Nature of caustic:—Hydrochloric acid and sodium hydroxide were each responsible for 2 cases; liquid sulphur dioxide, and lead for one each, whilst ammonia caused burns in the two eyes of the same patient. In the remaining twenty-two cases lime was the responsible agent.

2. Severity. In all cases except two—the exceptions being the two burns caused by hydrochloric acid—the cornea was involved when the patient was first seen. Mild cases without corneal involvement were not subjected to grafting. Corneal involvement at its mildest was loss of epithelium as shown by staining with fluorescein; severe involvement, as shown by diffuse or localised opacification of the cornea, was less common. Localised reddening of the conjunctiva at the site of the burn was a constant feature, and fluorescein staining revealed the extent of the epithelial damage. The severity of the burns in this series can be judged by the following data:—

Conjunctiva:

Both upper and lower fornices burnt	...	11 cases
Lower fornix only	19 cases

Cornea:

Clear	2 cases
The whole of the cornea involved	4 cases
Three-quarters of the cornea involved	3 cases
Half of the cornea involved	11 cases
Lesser areas	10 cases

3. Time of grafting. In the earlier cases a graft was generally not applied until after some days. More lately grafting has been carried out immediately.

4. Duration of treatment and end-result. At first the patients were admitted to hospital. More lately immediate grafting has been carried out in the out-patient department with or without admission for 2 to 3 days as in-patients. To present averages in this experimental series would be fallacious, but it may be stressed that immediately treated eyes and those treated early, tend to be very nearly white in 3 to 5 days; by the end of a week the eye is generally normal. In no case, except the three specially noted below, were there any corneal or conjunctival sequelae. In twenty-eight eyes in which vision is known, twenty-six showed vision of 6/9 - 6/5.

5. Complications and sequelae. In three cases in this series of thirty permanent complications were noted.

(1) One thin strand of symblepharon developed in case 16. It does not appear to give any difficulties or discomfort.

(2) Irregular cloudiness of the cornea has persisted in case

3 (in which the lime had stayed in the fornices for four days before treatment was sought).

(3) Cases 12 and 13. A man, aged 64 years, sustained a severe ammonia burn in both eyes, distinctly more marked in the right eye than the left. He did fairly well after two evacuations of the anterior chamber of the right eye, but on the tenth day developed hypopyon which did not respond to treatment. An amniotic graft had been inserted on the fifth day. The eye must be regarded as lost from inflammatory reaction. This patient, incidentally, illustrates the value of amniotic grafting in cutting short complications that had already set in. Whilst the right eye caused anxiety from the beginning, the left appeared at first to show an uncomplicated recovery. By the sixth day, however, fairly tense strands of symblepharon had formed, which reformed after breaking down with a glass rod, and it was then that an amniotic graft was applied. On removing the bandage forty-eight hours later it was gratifying to find a practically normal conjunctiva without any trace of symblepharon formation. This eye is now—six months later—completely normal. (In another patient treated since this series was closed, an amniotic graft applied on the fifth day in a cement injury, which had not been grafted initially, also controlled a tendency towards symblepharon formation.)

6. Delayed recovery. In one patient (No. 21) recovery was distinctly slow. The whole of the cornea was diffusely opacified and a graft was not applied until after he had been treated for three days by another surgeon. Both fornices were involved, and twenty-seven days of in-patient treatment was needed. Even then the eye was irritable. A second graft applied in the out-patient department on the thirty-fifth day gave a remarkable improvement within two days. The eye is now quiet and vision is full 6/6.

Technique of grafting

The human amniotic membrane ("amnioplastin") is that prepared by the London Hospital. It is dry and free from fat and resembles tissue paper. It is sent out in pieces of about four square inches folded twice and kept sterile in a cellophane envelope inside the usual paper covering. The folded piece is roughly 1" by 1" and this is about the right size when both fornices are involved; if only one fornix is to be grafted the membrane may be folded again. Several layers are an advantage as the tissue is friable and the needle tends to cut out if too few layers are used. It was found that the material is more easily handled dry as it tends to crumple and become unmanageable when it becomes wet. For this reason the tissue is folded to the correct size and then placed on a sterile dry towel and a No. 6 ophthalmic needle threaded with

No. 0 black silk is passed through each corner. The towel with graft and threaded needles is then brought up to the eye which is already cocainised and kept open by a self retaining speculum. The needles are then in turn passed through the bulbar conjunctiva and the graft sutured into place. When the fornix alone is involved it is sufficient to place two sutures in the depths of the fornix and the other two near the limbus so that all the affected bulbar conjunctiva is covered as well as the lower section of the cornea.

It is not advisable to cover too much of the corneal surface as the presence of the graft appears to affect the cornea adversely and

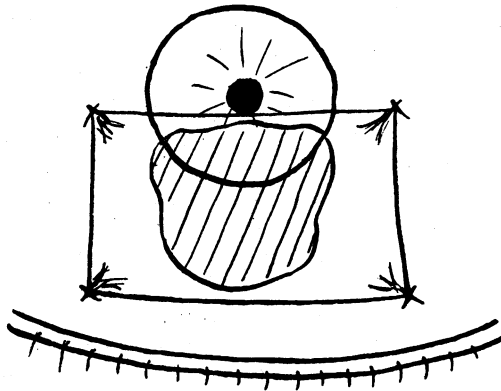


FIG. 1.

Schematic representation of graft held in position by four sutures (two in the lower fornix and two on the bulbar conjunctiva) and covering a burn involving the lower third of the cornea and a larger area of conjunctiva. (Area of burn shown by shaded lines.)

there is a temporary increase in the haziness of the cornea covered. This was noted in early cases when the whole cornea was covered and did not appear later when this point was appreciated. When it is necessary to put in a graft from the depths of the upper fornix to the depths of the lower fornix which necessarily passes right over the cornea, it is advisable to cut a small circular opening in the graft to correspond to the central area of the cornea.

It was at first thought that the optimum time for insertion of the graft was on about the second or third day after the burn, but it appears that immediate grafting is best. When the bandages are removed after 48 hours it is found that the graft is no longer visible. It has become transparent and forms a layer over the conjunctival surface. If there are any tags which have not been well in contact with the conjunctiva these may be seen as semi-transparent pieces of membrane in the conjunctival sac. The previously ulcerated conjunctiva is invariably found to have a smooth surface

and does not stain with fluorescein and though there may be some localised temporary corneal haze there is most often no staining of the corneal surface. The sutures are removed on the third or fourth day and at this stage the eye can be left open and protected with parolein drops and dark glasses, or if there is still some irritation a light pad can be used for a few days. The patients were not discharged until the eyes were quiet and there was no staining of cornea or conjunctiva.

To get the best results it is probably necessary to bandage both eyes for 48 hours as this ensures close apposition of the graft to the conjunctiva. In moderately severe cases a unioocular bandage has been found adequate.

Prior to inserting the graft the eye should be subjected to intensive local penicillin therapy. Penicillin drops in a concentration of 2,500 units per c.c. should be used. Where the graft is done immediately and in the out-patient department it is best to instil one drop every minute for ten minutes. For delayed grafting in the in-patient department more leisurely disinfection of the conjunctiva can be carried out.

Experimental study

Whilst these clinical investigations were in progress an attempt was made to study the effect of amniotic grafting under experimental conditions in the rabbit. These studies were largely unsuccessful owing to a combination of two circumstances. In the first place it was difficult to obtain a standard control lesion by the use of lime, of which several varieties, such as slaked lime and chalk lime, were tried. Small quantities applied to the conjunctiva tended to produce lesions that healed spontaneously, whilst massive applications destroyed the eye. No adequate dosage for a controlled lesion giving scarring of the cornea could be established. Something approaching a controlled standard lesion was obtained when the upper fornix and the upper bulbar and tarsal conjunctiva were painted with 20 per cent. silver nitrate, care being taken to wash away any excess before the lids came in contact with the cornea. Even so, a contact burn tended to form on the cornea, but in addition there appeared to be a corneal lesion secondary to the conjunctival damage. An even more serious difficulty emerged when amniotic grafting was attempted on to these relatively satisfactory lesions. It was found that the membrane behaved as an irritating foreign body. Instead of becoming readily absorbed, as it does in man, it tended to swell and assume a hard parchment-like aspect. The longer it was left in the eye the more irritation it caused, and if removed early it did not seem to have much effect one way or the other. It is possible that amniotic membrane of rabbit origin would behave differently, but this point was not pursued.

Discussion

In the absence of control clinical or experimental evidence, the results recorded here must be taken as an expression of clinical opinion rather than proof. The protracted course of caustic burns and the tendency towards conjunctival and corneal complications are, however, well known and the rapid recovery after grafting, both in fresh cases and in cases that have shown poor response to the standard treatment, is impressive. Simple as grafting with amniotic membrane is, and satisfactory as the results are, it is not suggested that all caustic burns are best treated by grafting with amniotic membrane. Patients whose cornea shows minimal or no fluorescein staining some hours after experiencing a caustic burn—burns that might be designated as those of the first degree—are quite safely treated by the classical methods, and they respond quickly. Patients with severe lesions with necrosis and blackening of the conjunctiva (burns of the third degree) appear to be best treated on the lines laid down by Denig, but of this type of burn and the appropriate therapeutic procedure we have no experience. Most caustic burns are intermediate between these two types in severity, and may be designated as burns of the second degree. These show a localised and relatively superficial conjunctival lesion and a variable superficial corneal lesion. In these cases, which are both common and productive of much disability, grafting with amniotic membrane appears to offer a simple means of considerably reducing the normally protracted course of recovery and preventing both corneal and conjunctival complications.

No opinion is offered on the mode of action of amniotic membrane grafts. It is possible that the graft acts in the manner suggested by Brown for the use of grafts of rabbit peritoneum, *i.e.*, mechanical separation of burnt surfaces; but it is difficult to believe that any substantial mechanical effect can be achieved by amniotic membrane which is rapidly absorbed. That amniotic membrane grafts act biologically rather than mechanically is suggested by the rapid effect and still more by the fact that it behaves in an apparently species-specific manner, if one is to judge by the different behaviour of the graft in man and in the rabbit. In one patient the graft became loose and was found 24 hours later under the bandage on the skin of the lid. On the conjunctiva it would have become largely absorbed by that time; on the skin it was similar to the appearance an amniotic graft assumes in the rabbit's conjunctival sac. This, too, rather suggests a specific biological interaction between the graft and the damaged conjunctiva.

Summary

1. An account is given of thirty cases of caustic burn of the eye treated by grafting with human amniotic membrane. Recovery was rapid and there were but few complications and sequelae.

2. The technique of amniotic membrane grafting is described.
3. Grafting with amniotic membrane—immediately or after 1 to 2 days—is advocated for second degree burns of the eye.
4. The difficulties of assessing experimentally the value of amniotic grafting are indicated and the possible mode of action is discussed.

QUININE AMBLYOPIA*

BY

J. D. J. FREEMAN

GLOUCESTER

THE following case history demonstrated several interesting points and for that reason is worth recording. The patient, Mrs. L., was a leading Wren aged 27 years, and was stationed at a Royal Naval Establishment on the east coast of Ceylon. She was married in June, 1944, and went up country for her honeymoon. Towards the end of this period, July 2, she developed general symptoms of malaise, frontal headache, pain behind the eyes and on moving the eyes, shivering at times and teeth chattering. On her return to Trincomalee on July 4 she was admitted to the sick quarters where her temperature was found to be 104° F. As well as general malaise she was complaining of headache, backache and nausea. She had left England in November, 1943, and had had no previous tropical diseases. I did not see her until July 24, 1944, when she was admitted to R.N. Auxiliary Hospital, Colombo, and came under my care. The following physical signs up to that date are taken from the notes made by Surg.-Commander H. L. Hoffman, R.N.V.R., Medical Officer in charge at Trincomalee.

General examination revealed no abdominal tenderness or enlargement of liver or spleen. On July 5 her urine contained bile pigments, but no albumen. On July 8 a blood film showed the presence of B.T. malaria parasites. The same day she started quinine and was given grs. x t.d.s. by mouth. On July 11 her spleen was palpable and she was also tender in the gall bladder area. Two days later on July 13 she complained of deafness and of seeing black spots in front of her eyes, which became bigger and paler turning greenish in colour. Her quinine therapy was stopped at once. She had had 120 grs. in all. She was put on tabebrin until July 18th being given 1.2 grammes in all. On July 19 she was complaining of blurred vision, especially in the left eye and that her eyes were sore and hurt on movement. The next day her pupils were dilated and reacted sluggishly to light. On

* Received for publication, March 8, 1946.