

CLASSIFICATION OF AMBLYOPIA*

BY

CARLO MAGGI

Rome

ALTHOUGH amblyopia was recognized in ancient times, it began to be treated only during the 18th century by Buffon (1746), whose pioneer work was not followed up because of the prevailing idea that squint was secondary to amblyopia, which was consequently thought to be essential and congenital.

At the beginning of the 20th century the treatment of amblyopia by occlusion of the fixing eye was again attempted, but the numerous failures of occlusion treatment provoked the scepticism of most authors, until Chavasse produced a classification of amblyopia and its pathogenesis which is to a large extent still held to be valid (Lyle, 1950).

Chavasse divided amblyopia into two main groups: amblyopia of arrest and amblyopia of extinction.

Amblyopia of arrest was said to occur when a deviation occurred during the "plastic period of macular development", from birth to 6 years, so that macular development in the deviating eye was arrested. The visual acuity was thought to be lost because it was believed that further development after the formative period, *i.e.* after the age of 6 years, was impossible, and that sight could therefore be recovered only to the point reached at the time when the deviation occurred.

Amblyopia of extinction was said to occur when the visual acuity already developed was lost through inhibition and disuse, sight being a conditioned reflex depending on use to remain normal. Thus that part of the visual function which had not yet become an unconditioned reflex was irreparably lost and could not be recovered. As these theories became more widely recognized, greater importance was attached to the type of fixation present in the amblyopic eye, to which Worth had also previously drawn attention (Lyle, 1950). It was found that although occlusion was valuable in patients with central fixation, it was actually harmful to patients with eccentric fixation, and the treatment of amblyopia came once more to a standstill.

More recently new techniques have been developed by Comberg (1936), Bangerter (1953), and Cüppers (1956), and the better results obtained have led to modern authors (Cüppers and Sévrin, 1956) to doubt Chavasse's opinion on the amount of visual acuity recoverable.

* Received for publication July 29, 1958.

The idea that the arrest of macular function is the basis of the amblyopic syndrome is still accepted, though the importance of a changed spatial direction is now recognized as well as the macular inhibition.

This new spatial value may be the result of newly-formed inter-neuronic synapses (on the physiological basis formulated by Lorente del No, 1938), causing a new association between the macula and the cortex (Cüppers and Sévrin, 1956).

TABLE
IMPROVEMENT IN VISUAL

Types of Amblyopia				Case No.	Age at Onset (yrs)	Age (yrs)
Group No.	Squint	Retinal Correspondence				
I	Present	Normal		None	—	—
II	Present	Abnormal	High Grade Amblyopia	1	2	3
				2	1	10
				3	Birth	6
				4	Birth	5
				5	Birth	10
				6	Birth	14
				7	3	6
				8	2	10
				9	Birth	8
				10	4	9
				11	Birth	17
				12	Birth	10
III	Present	Abnormal	Low Grade Amblyopia	13	3	7
				14	2	9
				15	3	6
IV	Present	Mixed	Convergent Squint	16	4	10
				17	3	11
				18	3	18
			Divergent Squint	19	4	12
				20	4	8
				21	10	21
V	Absent	Normal	Myopic Anisometropia	22	2	19
				23	3	9
			Hypermetropic Anisometropia	24	5	18
				25	14	15
				26	9	10
VI	Absent	Abnormal	Manifest Deviation Reduced Spontaneously	27	2	21
				28	2	5
VII	Bilateral (operated cases of congenital cataract)			29	Birth	12
				30	Birth	10

Method of Classification

We have classified them according to the type of retinal correspondence observed, exact information on this point being no less important than the type of fixation present. The retinal correspondence seems to be the only indication of the spatial value of the macula (*i.e.* the unocular projection), the study of the fixation by means of the special ophthalmoscopes designed by Cüppers and Bangerter being often inadequate.

We have observed that the fixation is always central if the retinal correspondence is normal—*provided that the fixation target subtends a visual angle greater than the visual acuity of the observed eye* (as in Groups I and V). This allows for differentiation between a true eccentric fixation and a condition which is merely due to central suppression. These two types nearly always give an identical response on testing with the Visuscope, but in the case of central suppression the spatial value of the macula remains unchanged, and the patient, although he can see the fixation star only paramacularly, is aware that the position of the star is eccentric to his visual axis.

It would appear that the after-image transfer test of Brock and Givner (1952)—which we use to test the intensity of central suppression in amblyopia—has the same significance, and in such cases (as in the above-mentioned examples in Groups I and V) there must exist a normal retinal correspondence, the presence of which has already been determined by other means.

Our method of performing the transfer test is to provoke a vertical after-image in the fixing eye and, using, for example, the amblyoscope, to ask the patient to fix a small point with the amblyopic eye. If there is intense central suppression, the patient will see the after-image (transferred from the now occluded normally-fixing eye) passing from side to side of the fixation point and superimposition will not be possible. This response indicates an inability to fix centrally, and the patient interprets the small lateral movements of attempted fixation as movements of the after-image itself. If, however, the small fixation point is exchanged for a circle of paramacular size, the patient now sees the after-image centrally superimposed, halving the circle vertically and remaining quite still. This indicates that the inability to fix centrally is due to central suppression and not to eccentric fixation.

In cases of high-grade myopic anisometropia, or whenever the tests described are not conclusive, we resort to examination of the retinal correspondence with the objective after-image. The routine procedure described by Cüppers (1956) is carried out with young children, whose answers are unreliable, by means of the objective provocation of an after-image in the amblyopic eye with the Euthyscope, and of a linear after-image in the unaffected eye. If with this technique it can be demonstrated that the retinal correspondence is normal, even if it has been demonstrated as abnormal with other tests (“mixed correspondence”), it is certain that the unocular

macular projection is correct and that the prognosis for the treatment of the amblyopia is good.

The presence of normal retinal correspondence, even with obligatory central suppression, is proof of normal sensory conditions of spatial projection, both unocularly and binocularly. Successful treatment is guaranteed by these conditions, whatever may be the state of fixation in the amblyopic eye as observed with the special ophthalmoscopes.

The contrary, however, does not always apply when the retinal correspondence is abnormal. Included under this heading is the classical type of high-grade amblyopia (Group II) in which the eccentricity or lack of fixation is the expression of changed spatial values.

Cases may also occur (Group III) in which, notwithstanding abnormal retinal correspondence and central suppression (which may show the characteristics of eccentric fixation on examination with the Visuscope), the spatial projection of the macula is normal. If an after-image is produced with the Euthyscope in the amblyopic eye, it is projected correctly on the fixation point (for example, a letter "E" which may or may not be distinguished according to the visual angle represented). On the other hand, if a macular after-image is provoked in the fixing eye also, and if both eyes are then closed, the two resultant positive after-images will be seen at a distance from one another, denoting abnormal retinal correspondence. These responses indicate that the macular projection in the amblyopic eye is abnormal in binocular vision but normal in unocular vision, in spite of the central suppression.

Our series of cases may therefore be grouped as follows (Table):

- I. Amblyopia with strabismus and normal retinal correspondence.
- *II. High-grade amblyopia with strabismus and abnormal retinal correspondence.
- *III. Moderate amblyopia with strabismus and abnormal retinal correspondence.
- *IV. Amblyopia with strabismus and mixed retinal correspondence.
- V. Amblyopia without strabismus, due to anisometropia, with normal retinal correspondence.
- VI. Amblyopia without demonstrable strabismus, due to spontaneous reduction of a manifest deviation.
- VII. Bilateral amblyopia.

I. Amblyopia with Strabismus and Normal Retinal Correspondence.—No cases of this type are reported here, as they usually turn out to be due to neglected

* Clinically all three of these groups may be diagnosed as "lack of normal correspondence" on the synoptophore.

accommodative strabismus, or to strabismus of late onset in which, owing to the normal retinal correspondence, facultative macular inhibition is present when the macula of the other (fixing) eye is in use.

Occlusion of the fixing eye is usually sufficient to restore normal visual acuity at any age.

II. High-grade Amblyopia with Strabismus and Abnormal Retinal Correspondence. (Cases 1–12).—These are usually squints of early onset (in the first 3 or 4 years of life), in which the system of spatial projection of the amblyopic eye has suffered profound changes in order to adapt itself to the abnormal conditions of the deviation.

These changes, according to the description given by most modern authors, may be listed as follows:

- (a) Eccentric fixation with alteration of the spatial sense of the macula;
- (b) Disturbances in sensory co-ordination, *i.e.* a deficiency in retinal separation and discrimination, and difficulty in orientation and form-sense, held to be of cortical origin, and known as “visual agnosia”;
- (c) Arrest of macular development, with consequent modification of possible re-education, depending on the age at onset of the abnormal condition.

The treatment of these cases which do not improve with occlusion of the fixing eye has been much advanced by the work of Cüppers. In such cases the retinal correspondence is always abnormal, a fact which we consider to be of primary importance and which we will discuss later.

III. Moderate Amblyopia with Abnormal Retinal Correspondence (Cases 13–15).—In these cases the visual acuity of one eye is usually 6/36 or even more. In two of our cases eccentric fixation was diagnosed with the Visuscope, but in all of them the macular projection was normal unocularly when the stimulus was objectively applied.

We treated these cases with the Euthyscope in conjunction with binocular after-image treatment in an attempt to restore normal retinal correspondence, a sensory guarantee that surgical treatment of the small angle of strabismus would be successful.

In all these cases the amblyopia soon disappeared (which indicated that it was due to suppression), but the abnormal retinal correspondence persisted unchanged and the strabismus thus became alternating.

IV. Amblyopia with Strabismus and Mixed Retinal Correspondence (Cases 16–21).—“Mixed retinal correspondence” means a functional association in which the correspondence is not firmly stabilized, so that it appears to vary with the method or time of testing.

This is typical of *divergent strabismus*, whatever its aetiology, as in the three following cases in which the amblyopia rapidly disappeared and normal binocular vision was obtained after operation:

- (i) Anisometropia in which the refraction of one eye differed from the other by an astigmatism of 9 D cyl.
- (ii) Slight myopia and moderate anisometropia.
- (iii) Corneal opacity caused by a burn at age 11.

The cases of *convergent strabismus* in this class had a very small angle of deviation (5–10° degrees of convergence), and in all of them a marked motor deviation had occurred at about 3 years of age, and had then spontaneously decreased.

To the relatively late onset and the variability in the angle of squint may be attributed the failure to establish an anomalous sensory adaptation with the fixity which the small angle of squint would normally permit.

In these cases, therefore, the only advisable treatment is that designed to restore the visual acuity of the amblyopic eye. The success of the treatment appears to be unioocular; if treatment is neglected at this stage it will later become more difficult, and perhaps even impossible, through the presence of abnormal retinal correspondence.

V. Amblyopia without Heterotropia (Cases 22–26).—This is found in association with anisometropia, when the defective visual acuity is due merely to inhibition of the central retina caused by a stimulus originating in the contralateral macula to remove the troublesome image which prevents clear binocular fusion.

If the anisometropia is hypermetropic, or only moderately myopic, there is not only normal retinal correspondence but also good fusion which may be demonstrated on the synoptophore.

An indication of the presence of central suppression (of value in forming a prognosis and in deciding the type of treatment necessary) may be obtained by using the Visuscope, or, better, by the after-image transfer phenomenon as described by Brock and Givner (1952).

As retinal spatial localization is normal, treatment offers no difficulties; in many cases occlusion of the better eye is sufficient. Nevertheless, treatment with the Euthyscope is necessary for older patients and in such cases may need to be prolonged for 2 months or more before full success can be achieved.

Myopic anisometropia of high degree, on the other hand, shows certain unusual characteristics. Since fusion is impossible and fixation very poor, it is often necessary to examine the retinal correspondence in order to detect the presence of heterotropia, the deviation being often undetectable by other means.

In our two cases the correspondence was normal, but contrary to what might have been expected, we were unable to obtain any worthwhile improvement. Corneal contact lenses, and even the introduction of a Strampelli lens into the anterior chamber, had little effect on the amblyopia, and the prognosis in these cases appears to be poor.

VI. Amblyopia without Demonstrable Strabismus (Cases 27–28).—If high-grade amblyopia is the expression of an altered spatial projection it must necessarily be

associated with a manifest squint. In some cases of squint the presence of dense amblyopia makes it difficult to determine the presence of a motor deviation on cover test, and the fixation (as determined by the Visuscope) may be so close to the fovea that the diagnosis remains uncertain, especially if some degree of anisometropia is present.

In such cases no angle of anomaly is demonstrable by any method whatsoever, and even the state of retinal correspondence as tested with the after-image (produced with the Euthyscope) remains doubtful.

The presence of abnormal retinal correspondence indicates a sensory disturbance which is always secondary to a motor deviation.

Contrary to what might be expected, the anatomical correspondence of the two retinæ brought about by the re-establishment of parallel visual axes does not lead to any improvement in the visual acuity of the amblyopic eye.

These cases are strongly resistant to pleoptic treatment (possibly because they are usually first examined too late in life).

VII. Bilateral Amblyopia (Cases 29–30).—This is generally caused by congenital cataract, and is held to be the classical type of amblyopia ex anopsia (of disuse).

Recently, early operation has been advocated in the belief that the elimination of the optical impediment renders visual function possible and thus allows an improvement in visual acuity.

However, the lack of improvement in most cases has led to the opinion that, even in this form of so-called "pure amblyopia", macular inhibition exists.

It is difficult to explain this in cases of bilateral cataract, and to discover the origin of the stimulus to inhibition, given that, in cases of unilateral amblyopia associated with squint, the contralateral macula is considered to be the source of the inhibition.

In cases of unioocular cataract in which operation has already been performed and a clear pupil obtained although the amblyopic eye deviates, the stimulus for macular inhibition is, at least theoretically, possible, having its origin in the fixing eye. However, the visual acuity in the non-fixing eye is so poor that macular or retinal rivalry, which is held to provoke the inhibition, is absent.

Furthermore, if the retinal correspondence in unilateral aphakia can be demonstrated with the Visuscope, it is found to be very uncertain and approximate. There is thus a definite parallel between the actual visual acuity of the amblyopic eye and the capacity for retinal correspondence; the higher the visual acuity the more definite the retinal correspondence (whether normal or abnormal).

If it be admitted that retinoception is the basis of the visual process, the latter would be a conditioned reflex, the development of which is more or less advanced according to the density and type of obstacle caused by the cataract.

Thus, in cases in which sight is reduced to perception of light, the retinoception develops in a rudimentary and approximate form. The position of the eyes depends more on the postural reflex (which is non-retinal) than on the fixation reflex, so that the clinical picture is that of the most severe type of bilateral amblyopia, which does not respond to treatment.

In less severe cases, the development of retinoception (the sensitivity of which increases progressively with the retinal value from the periphery towards the

macula) has to a certain extent taken place and is sufficient to allow the development of the fixation reflex, even if approximately and imprecisely.

The greater the development of retinoception the better the capacity for fixation, and therefore also the better the macular or discriminative vision.

It is in these cases that treatment with the Euthyscope is indicated so that the localization of the after-image along the spatial axis can allow the patient a degree of fixational control, apart from the fixation reflex.

Thus, with the improvement in fixation, an improvement in visual acuity can be expected.

Our experience, limited to two cases (both of which showed only slight improvement), is not sufficient to confirm factually this hypotheses on the pathogenesis of these forms.

Physiological Bases of High-Grade Amblyopia

From the observation of the cases concerned one factor of great importance becomes evident, *i.e.* the age of the patient at the onset of the deviation.

In fact, of the seven cases with onset at birth or during the first few months of life, all experienced only a limited degree of improvement and none achieved a visual acuity superior to 6/36. Those cases which were of later onset all showed noticeable improvement, with the re-establishment of complete normality in a few instances.

Of much less importance appear to be the angle of the deviation, the age of the patient when treatment is begun, and the length of duration of the deviation.

Where the sensory association of the two retinae is concerned, it is found that the state of retinal projection varies according to whether observation is made during uniocular or binocular fixation.

During uniocular fixation by the amblyopic eye, there is no suppression, but while binocular fixation is maintained there is macular suppression in the amblyopic eye.

This may be verified by observing the absence of suppression of the Visuscope star in the amblyopic eye while the normally fixing eye is occluded, and by comparing this with the result of the bi-macular fixation test described below.

Bi-Macular Fixation Test.—In this test the Visuscope star is projected on to the retina of the amblyopic eye while the dominant eye fixes the reflection of a point of light seen in a mirror held by the patient against his nose.

The retinal point in the amblyopic eye at which the star is seen by the patient as superimposed on the fixation light observed in the mirror will have the same directional value as the fixing macula. If the central star disappears (the patient seeing only the illuminated background of the Visuscope), suppression must be present.

As Fig. 1 shows, the area of suppression in the amblyopic eye during binocular fixation does not correspond with the macula, but with that part of the retina which has the same spatial value as the macula of the fixing eye.

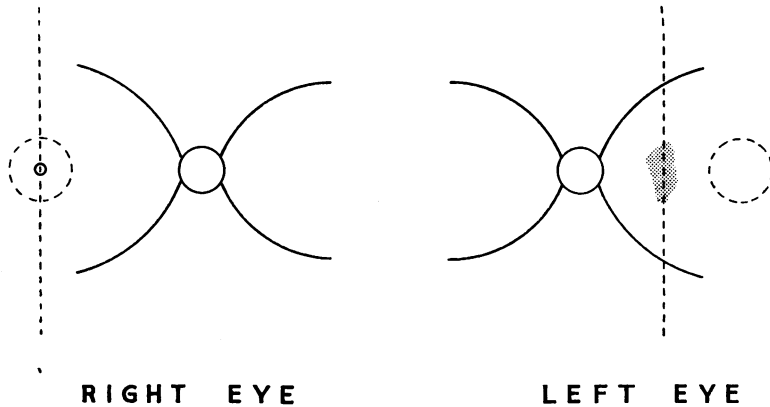


FIG. 1.—Diagram to show the binocular projection in a case of convergent squint with amblyopia of the left eye, as determined by observation with mirror and Visuscope.

In the right eye the (fixing) macula is coincident with the normal spatial axis, and is the dividing point of the right and left projection areas of the retina.

In the left eye the line dividing the two areas of projection is displaced nasally. The shaded area in the centre represents the zone of origin of the new spatial axis which is approximately parallel with the other. Given the relatively high sensorial value of the retina there is suppression here, and the Visuscope star disappears.

The macula (inside the circle) is only inhibited, not suppressed, and the Visuscope star remains visible.

Development of Abnormal Binocular Correspondence

On studying the theory of the binocular sensory association of the two retinæ in convergent squint, it is found that the non-fixing eye adapts its spatial projection in order to correspond with the correct localization of the fixing eye.

The point which divides the new functional areas of nasal and temporal projection of the retina of the squinting eye, and which has the same spatial value as the macula of the fixing eye, becomes the spatial axis of the amblyopic eye in binocular fixation. The position of all points in space is judged in relation to the spatial axis (which in the normally fixing eye originates at the macula), which in the deviating eye is parallel with and secondary to the spatial axis of the fixing eye.

In other words it is as though images received by the non-fixing eye were projected in relation to the spatial axis of the fixing eye.

Owing to the variability of the angle of squint, and to the notably inferior sensory value of the peripheral retina, the point of origin of this spatial axis is represented in the squinting eye by an area which becomes larger and less well-defined in proportion to the size of the deviation as the corresponding

retinal area concerned becomes more peripheral. This fact is recognized in orthoptic terminology as "crossing".

Because of retinal rivalry, the visual acuity of the macula of the deviating eye is reduced by active inhibition whilst fixation is maintained by the other eye.

When an oculomotor deviation exists without amblyopia, two types of uniocular retinoception exist; a normal retinoception, which is present only during fixation with the same eye, and an abnormal retinoception, which is present only in conjunction with the normal retinoception of the contralateral fixing eye. If the deviating eye is amblyopic, the normal retinoception is deeply suppressed and the amblyopic eye is no longer capable of assuming a dominant role.

Thus, of the two types of retinoception originally present in an oculomotor deviation, in the amblyopic eye only the abnormal retinoception remains (and is always secondary to and dependent on the correct retinoception of the fixing eye).

The Amblyopic Eye in Eccentric Fixation

When the fixing eye is occluded, compelling the amblyopic eye to fix for the first time, fixation is initially maintained by means of the anomalous retinoception. Thus the uniocular fixation point of the amblyopic eye coincides originally with its spatial axis, which is eccentric to the macula and represents that retinal area which would correspond in binocular fixation with the macula of the fixing eye.

However, owing to the occlusion of the fixing eye, the amblyopic eye is now compelled by necessity to seek to improve its visual acuity.

Since the spatial axis is not as well defined as in the normal eye—in many instances it is at the optic disc—and the inhibition of the central retina has diminished on covering the normally-fixing eye, the fixation tends to become displaced in order to gain a retinal zone of higher sensory value (Fig. 2, overleaf).

In brief, there is created alongside the principal directional axis a visual axis in strict antithesis to the former; *thus the patient sees the image at a different point from that at which he localizes it*. This circumstance is physiologically unacceptable and provokes an inhibition of the area of the retina extending from the anomalous principal projection axis which has a greater sensory value, *i.e.* towards the macula.

As the macula in a range of 2 to 3° has an extremely high visual power, it is here that the inhibition reaches the value of absolute suppression (as may be determined by means of examination with the Visuscope).

This macular suppression is the result of conflict between the anomalous retinoception (giving rise to central suppression originating in a stimulus from the fixing eye to prevent the confusion of images) and the new individual function of the amblyopic eye in the para-central retina (eccentric fixation).

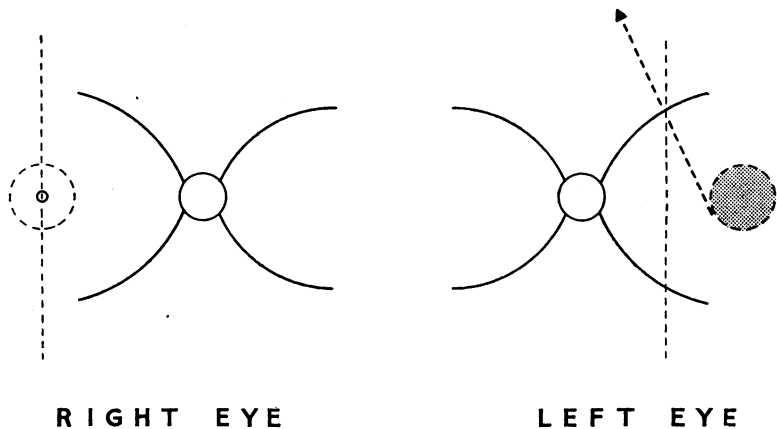


FIG. 2.—Diagram to show displacement of the visual axis in the amblyopic eye towards the macular area in an attempt to improve its visual acuity in unocular fixation.

The right eye is occluded.

The left eye is fixing unocularly.

The *spatial axis* is parallel with that of the fixing eye (abnormal retinal correspondence) and becomes the principal axis of the unocular abnormal retinoception on occlusion of the fixing eye.

The *visual axis* represents the direction assumed by the amblyopic eye in an attempt to improve its visual acuity, and fixation is maintained by the point of highest sensorial value outside the macular area, which is profoundly inhibited. The Visuscope star disappears inside the shaded area, which represents the area suppressed in unocular fixation.

It appears that this antagonism between the peripheral and the central retina, already noted by Burian (1947) in cases of squint, and by Swan and Laughlin (1944) and de Jaeger and Bernolet (1956) in amblyopia, is the conditioning factor of macular suppression.

It is interesting to note, however, that occlusion or even enucleation of the normal eye merely stimulates the macular suppression and aggravates the anomalous condition of eccentric fixation.

With the dissociation of the two components of vision—perception and discrimination, as described by Roelofs (1935)—the group of disturbances known as “motor incoordination” can be easily explained: the patient is merely seeing the image at a different point from that at which it is localized.

Similarly, the difficulties of retinal separation can be explained: if it is difficult to localize one isolated point, how much more difficult must it be to localize and interpret one point selected from many others!

It must be emphasized that, as sight is a reflex, the patient is obliged to rely upon his own sensations (among which the imperfect localization is predominant). And this incoordination cannot be corrected by means of the higher cortical faculties as the incorrect localization by now amounts to a conditioned reflex.

During pleoptic treatment, in fact, the patient must learn to neglect and suppress the localization impulse from the peripheral retina in favour of the central visual impulse, aided by the macular impulse which is given to him objectively.

Practical Use of the Macular After-image in the Re-education of the Visual Reflexes.—The Euthyscope dazzles the extramacular retina and stimulates the macular area.

Thus the inhibitory mechanism is actively reversed in favour of the macula, which has previously been inhibited, and the co-existence is provoked of the two basic functions of unocular vision (perception and discrimination) now made independent and of necessity antithetic.

Although the patient sees better within the area covered by the central after-image he is incapable of controlling it; each time he attempts to change the position of the after-image, that is to control his fixation, he re-adopts the anomalous projection, and will see the after-image move away, always to the same side (in a convergent squint in a nasal direction), or else disappear altogether as it is overcome by suppression.

The after-image represents not only discriminative or clear visual function, but also the spatial axis of correct localization. This correct localization exists only during the presence of the after-image and disappears together with it, because of suppression, being replaced by the renewed false localization which again becomes dominant.

The removal of macular inhibition during treatment is thus only one stage (6/6 angular visual acuity with the E-test) toward the reversal of the spatial inhibition, and if treatment is now terminated the visual acuity will return to the original level, with the prevalence of false localization and the associated duration of the inhibition.

The characteristic type of fixation—nystagmus between the macula and the eccentric point of fixation—which is often observed in cases previously treated by occlusion of the fixing eye is also encountered in those patients who discontinue treatment at this stage. It seems to be the sign of continuous attempts to gain macular fixation, frustrated by the dominant inhibition.

After a long period of treatment, and almost always suddenly, there is a new improvement. The patient sees as much as 6/9 or 6/12 (cortical vision with Snellen's chart); and on the synoptophore, where treatment is being carried out simultaneously with the constant presence of an objective macular after-image, a double spatial projection may be noted, manifested by unocular diplopia in the amblyopic eye.

During successive treatments the normal macular projection gradually predominates until the abnormal projection has completely disappeared.

At this stage the visual axis and principal projection axis of the amblyopic eye once more coincide, and the inhibition maintained by the false localization is eventually overcome.

Thus normal correspondence becomes dominant and the abnormal correspondence is now suppressed. The restored equilibrium is confirmed by the fact that the patient no longer requires the after-image in order to see correctly, and the disturbances of coordination have practically disappeared.

The treatment of amblyopia, therefore, does not depend on the re-education of the altered retino-motor associations but merely on the reversal of the inhibition of normal retinoception.

This reversal also means a re-establishment of normal retinal correspondence (as long as both eyes are used together only during exercises at the objective angle of squint, and the non-corresponding points remain unstimulated).

The amblyopic eye must remain constantly occluded.

Visual Development with Regard to Prognosis.—If visual development in the normal child is studied, it is found that, although spatial projection develops during the first 3 months, the macula is not fully developed anatomically until 5 months, and only at one year does the visual acuity reach a grade attributable to the beginnings of macular function.

A motor anomaly occurring at 3 months (during the “plastic period” or period of formation of the retinoception reflex) would provoke a functional adaptation so well-established that the anomalous retinoception becomes fixed as normal function does in other cases. The inhibition in such a case is so profound that no after-image can be appreciated and the prognosis is consequently poor.

However, among our successfully treated patients, is one with a constant squint and eccentric fixation which was reliably diagnosed by the age of one year. In this case, although the onset was very early, the abnormal condition was not deep-seated enough to prevent its reversal by pleoptic treatment.

The attainment of normal visual acuity seems to depend on the completion of normal retinoception in the first months of life, although of course macular function is not yet active. In this case the fact that macular vision had not been used for 9 years did not prevent the assumption of full macular function after a few months of treatment, once normal retinoception had been established. The normal retinoception, therefore, was of such maturity by the time the patient was one year old that the suppression caused by the abnormal sensory adaptation to the deviation proved amenable to treatment.

On the other hand, it is well known that the nature of the “fixity” of the striate area (which represents the cortical projection of the spatial value of the single retinal elements) is due to the precocity of the plastic formative period, both phylogenetically and ontogenetically. Moreover, the complex changes in the electro-encephalogram found by Dyer and Bierman (1952) in amblyopia, explained as signs of an alteration in the inter-neuronic association in a large portion of the cortex, also support this opinion clinically.

The inhibition and the new association of the neurones (Lorente del No, 1938) invest the whole striate area and are the basis of the amblyopic syndrome.

Thus the lack of macular function is only one consequence (and not the most important one) of amblyopia.

If, therefore, the cure of amblyopia can be identified with the re-establishment of normal retinal correspondence (*i.e.* correct binocular retinoception), only the surgical correction of the deviation, by restoring parallelism of the visual axes, will allow a normalization of the binocular function.

The spontaneous and continuous use of binocular vision is the best guarantee of the maintenance of the recovered visual acuity in the amblyopic eye.

What is obtained immediately after operation is fusion of the so-called "peripheral" type, as described by Lyle and Foley (1955). Since this type of fusion appears to embrace small angles of deviation, we cannot tell how these patients behave with regard to binocular vision in every-day life; the cover test is difficult to interpret as there is a certain sluggishness of the fixation reflex in the amblyopic eye. Examination on the synoptophore (with the help of objectively applied after-images) shows perfect superimposition of the two images but little fusional amplitude. Obviously, given the early onset of the deviation in most of these cases, the reflex of fusional amplitude (being conditioned later by more complex visual needs in the normal child) cannot have existed in the altered binocular association of the squinting amblyope.

However, in our patients who recovered binocular function post-operatively, the fusional amplitude improved continually. When tested with the Polarized Television Trainer (Anderson, 1956), a binocular response was given, which supports our belief that true binocular function had been attained.

We trained binocular vision after operation by various means: total occlusion of the amblyopic eye was discontinued while treatment on the synoptophore was carried out, and during homework exercises only.

As binocular function became more stable, partial occlusion was applied to the lens in front of the non-amblyopic eye while these exercises were carried out. This partial occlusion was also discarded during treatment as soon as the patient could maintain simultaneous foveal perception.

Among the cases of high-grade amblyopia, we had only two of this type (Cases 2 and 8 in the Table) where in spite of the early onset of tonic squint the recovered visual acuity has remained normal, or almost normal, after 4 and 10 months respectively after the conclusion of treatment, and the fusional amplitude has continued to improve spontaneously.

In the other three cases (Cases 1, 7 and 10) where operation was refused or was not performed because of a satisfactory cosmetic appearance, a condition of relative alternation has developed. In these cases, of course, the "good" eye remains dominant, as the amblyopic eye maintains a tendency to suppress, and the visual acuity is inclined to deteriorate. Short periods of treatment by occlusion of the fixing eye have been necessary to maintain the standard of vision previously attained.

Conclusion

In assessing the advisability of treatment in cases of amblyopia, an examination of the retinal correspondence is of primary importance, and should be tested, to ensure accuracy, with an objectively applied after-image.

The altered retinoception is the most important cause of defective vision in the amblyopic eye, and may be held responsible for inhibition of macular function, deficient form-sense, dissociation of the discriminative and localizing functions of the retina (leading to spatial incoordination), and the lack of establishment of such important reflexes as uniocular fixation, convergence, and fusion.

Treatment should aim at liberating from inhibition a sufficiently developed normal retinoception.

The first and most evident sign of success is the recovery of a normal visual acuity. This leads to the re-establishment of correct retinoception and normal retinal correspondence (or normal binocular retinoception) if parallelism of the visual axes is restored by surgery.

It is only in conditions of simple sensory binocularity (as described by Winkelman, 1953) that one can hope to regain eventually all those motor and sensory fusion reflexes which together form the complex of normal binocular function.

I should like to thank Professor Benedetto Strampelli for the facilities he has given me in carrying out this research, and for his permission to use his patients; also Dr. George Sévrin of Brussels for allowing me to follow his method of treatment; and Mr. T. Keith Lyle for his helpful criticism and suggestions.

REFERENCES

- ANDERSON, E. C. (1956). *Brit. orthopt. J.*, **13**, 82.
 BANGERTER, A. (1953). "Amblyopiebehandlung," *Bibl. Ophthalm.*, Fasc. 37. Karger, Basel.
 BROCK, F. W., and GIVNER, I. (1952). *A.M.A. Arch. Ophthalm.*, **47**, 775.
 BUFFON, L. G. DE (1746). *Hist. et Mém. Acad. Sci. (Paris)*, Année 1743, Mém., p. 231.
 BURIAN, H. M. (1947). *Amer. J. Ophthalm.*, **30**, 1005.
 CHAVASSE, F. B. (1939). "Worth's Squint," 7th ed. Baillière, Tindall and Cox, London.
 COMBERG, W. (1936). *Zbl. ges. Ophthalm.*, **36**, 369.
 CÜPPERS, C. (1956). *Klin. Mbl. Augenheilk.*, **128**, 353, 345, 741.
 ——— and SÉVRIN, G. (1956). *Bull. Soc. franç. Ophtal.*, **69**, 359.
 DE JAEGER, A., and BERNOLET, J. (1956). *Bull. Soc. franç. Ophtal.*, **69**, 385.
 DUKE-ELDER, S. (1949). "Text-book of Ophthalmology," vol. 4, p. 3841. Kimpton, London.
 DYER, D., and BIERMAN, E. O. (1952). *Amer. J. Ophthalm.*, **35**, 66.
 LORENTE DEL NO (1938). *Quoted by Sévrin, 1956.*
 LYLE, T. KEITH (1950). "Worth's and Chavasse's Squint," 8th ed. Baillière, Tindall, and Cox, London.
 ——— and FOLEY, J. (1955). *Brit. J. Ophthalm.*, **39**, 474.
 ROELOFS, C. O. (1935). *Arch. Augenheilk.*, **109**, 395.
 SÉVRIN, G. (1955). *Bull. Soc. belg. Ophtal.*, No. 109, pt. 2, p. 80.
 ——— (1956). *Bull. Soc. Ophtal. Fr.*, p. 21.
 SWAN, K. C., and LAUGHLIN, E. (1944). *Arch. Ophthalm. (Chicago)*, **32**, 302.
 VERHOEFF, F. H. (1938). *Ibid.*, **19**, 663.
 WINKELMAN, J. F. (1953). *A.M.A. Arch. Ophthalm.*, **50**, 179.