

CASE REPORT

Integral multidisciplinary approach in a patient with chronic complete spinal cord injury and hip disarticulation

J Quinzaños-Fresnedo¹, G Rodríguez-Reyes², C Mendoza-Cosío¹, R Pérez-Zavala¹, EA Márquez-Guitérrez³ and S Hernández-Sandoval⁴

STUDY DESIGN: Case report.

OBJECTIVES: To highlight the importance of the integral multidisciplinary management of a patient with complete chronic spinal cord injury and hip disarticulation secondary to pressure ulcers (PU).

SETTING: Mexico City.

METHODS: The case of a 40-year-old male violinist with a spinal cord injury, American Spinal Injury Association Impairment Scale A and neurological level T4, is reported. The patient initiated with bilateral ischiatic, left trochanteric and sacral PU. The ulcers were complicated with infection with sluggish evolution. Thus, it was decided a multidisciplinary management by means of left hip disarticulation and elaboration of a cosmetic prosthesis and the manufacture of a viscous elastic foam cushion for the prevention of new PU. The patient was quickly included in his professional and social activities.

CONCLUSION: This study proves that multidisciplinary management of patients with spinal cord injury with complications such as the presence of PU that are resistant to noninvasive treatment can be the solution for the patient's reintegration into their normal life with adequate quality of life.

Spinal Cord Series and Cases (2015) 1, 15016; doi:10.1038/scsandc.2015.16; published online 8 October 2015

INTRODUCTION

The presence of chronic pressure ulcers (PU) can generate, in the patient with spinal cord injury (SCI), a significant impact on health, functionality and quality of life (QOL).¹ The annual incidence of PU in patients with SCI is 23–33% and it is estimated that between 85 and 95% of patients with SCI will present at least one PU in their lifetime, and that 70% will present multiple PU.^{2,3} According to the World Health Organization, in countries with low and medium incomes, PU continue to be one of the main causes of death, because of their association with fatal infections. Their management is principally conservative but, depending on their evolution, management can be surgical, with the capacity of leading to extensive amputations in the case of presenting osteomyelitis resistant to conservative treatment.³ Among the disadvantages that can present with amputation, we can find the following: postural instability; poor weight distribution with secondary dorsalgia; body image alterations; and new formation of PU in up to 13–91%.^{4,5} To date, there is no successful program of prosthetization in these patients. Adverse conditions associated with the amputation could improve with multidisciplinary management, with a team of physicians, psychologists, nurses, biomedical engineers and social worker, and long-term follow-ups.⁵

The purpose of this report is to highlight the importance of the integral multidisciplinary management of a patient with complete chronic SCI and the presence of chronic, infected PU and extensive amputation of lower limb.

PRESENTATION OF THE CASE

Our patient is a 40-year-old male, with a diagnosis of chronic SCI, American Spinal Injury Association Impairment Scale A and

neurological level at T4, associated with a shotgun wound in the year 2001. He is a professional violinist with a degree in music, single and he lives alone. He is a social smoker (one cigarette a month) and has no other addictions. In 2009, he presented a grade II trochanteric PU that remitted with conservative management, and he has no history of other PU. He has been diagnosed with heterotopic ossification in 2009, and in 2011 a right Girdlestone resection arthroplasty was performed because of severe alteration of hip movement. He has mild spasticity (1+/1 in right/left hip and 1/0 in right/left knee according to modified Ashworth scale) and he does not use antispastic drugs. In April 2013, the patient initiated with bilateral ischiatic, left trochanteric and sacral PU associated with a change in his wheelchair seat. He did not seek for medical care and cured the wounds with sterile water by himself. Two months later, the patient presented infection at these sites, so he went to a private hospital where he received medical care. On not improving and on presenting persistent fever, chronic anemia, severe malnutrition and right hip fistula, the patient came 3 months later to the National Rehabilitation Institute (INR), in Mexico City, for his multidisciplinary management with the objective of PU management.

A first session was held in conjunction with the Institute's SCI Rehabilitation, Plastic Surgery, Infectology and Orthopedics Services, deciding on initial improvement of the patient's general and nutritional status before performing any surgical procedure. The patient was discharged from the hospital in order to continue ambulatory management through nutritional support, conservative management of PU with weekly institutional reviews, and assessment of the patient by the Infectology Service.

On presenting torpid evolution of PU (Figure 1) with osteomyelitis, sepsis and severe malnutrition, it was decided on

¹División de Rehabilitación Neurológica, Instituto Nacional de Rehabilitación, Mexico DF, Mexico; ²Laboratorio de órtesis y prótesis, Instituto Nacional de Rehabilitación, Mexico DF, Mexico; ³Servicio de Cirugía Plástica, Centro Nacional de Investigación y Atención de Quemados, Instituto Nacional de Rehabilitación, Mexico DF, Mexico and ⁴Servicio de Psicología, Instituto Nacional de Rehabilitación, Mexico DF, Mexico.

Correspondence: Dr J Quinzaños-Fresnedo (jimenaqf@hotmail.com)

Received 7 July 2015; accepted 7 July 2015

the patient's hospital readmission 1 month later. A second session was held, this time with the Institute's SCI Rehabilitation, Plastic Surgery, Infectology, Orthopedics and Psychology Services, deciding on immediate management with left hip disarticulation and the advance of flaps for defect coverage. During the patient's hospital stay, a more extensive assessment was requested by the Psychology Service, and a diagnosis of Narcissistic personality disorder (NPD) determined. Major depression and ectodermic syndrome were discarded.

Due to the patient's high esthetic and functional demand in his work activity, once he was stable, a third joint session was held with personnel from the Institute's SCI Rehabilitation, Plastic Surgery, Amputee Rehabilitation and Engineering Services, and it was decided to undertake the elaboration of a cosmetic prosthesis and the manufacture of a viscous elastic foam cushion to prevent the formation of new PU.

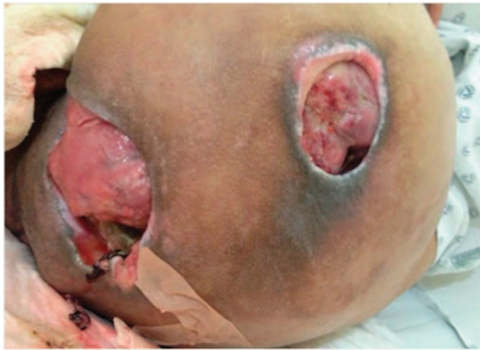

Figure 1. Ischiatic and trochanteric pressure ulcers.

The remainder of the normally described prosthetic components was discarded, due to their weight as well as to the important limitation that they offer in terms of range of motion.

The proposed design took into consideration the use of the framework of a cosmetic modular unit for shoulder disarticulation. Instead of the terminal element, adequate adaptations were made for the pyramid adapter, to which the prosthetic foot is fixed, to be set in place. Elbow and shoulder joint prostheses served as knee and hip joint prostheses, respectively. The prosthetic hip (shoulder) joint was fixed to a 10×15-cm polypropylene plate that was anatomically molded to the left anterior wall of the patient's pelvis. As subsection/restraint, a sports pants-type mesh garment fashioned of synthetic elastic fibers was designed for the patient to wear underneath his everyday clothing. To this garment, we sewed a pocket in the anterior portion at the level of the patient's left pelvic wall where the previously described polypropylene plate was inserted, and this was secured with a self-adhesive material (Velcro, Naucalpan, Mexico), achieving adequate restraint of the patient's prosthesis (Figure 2).

The previously described design resulted in a prosthesis that does not interfere with the cushion or with the positioning of the patient in his wheelchair. The prosthesis allows the patient to engage in transfers with ease because an additional weight is no longer involved. Finally, given the range of motion of all of the joints involved, the patient can accommodate this cushion and fix it easily while sitting in the wheelchair or outside of it, which confers a natural and symmetrical appearance.

In order to fulfill the requirement of adequate positioning of the patient in the wheelchair to avoid the recurrence of PU, the commercial air/foam cushion system that the patient used was discarded as a subsection restraint system. A customized cushion with




Figure 2. Adaptation of cosmetic modular unit for shoulder disarticulation.

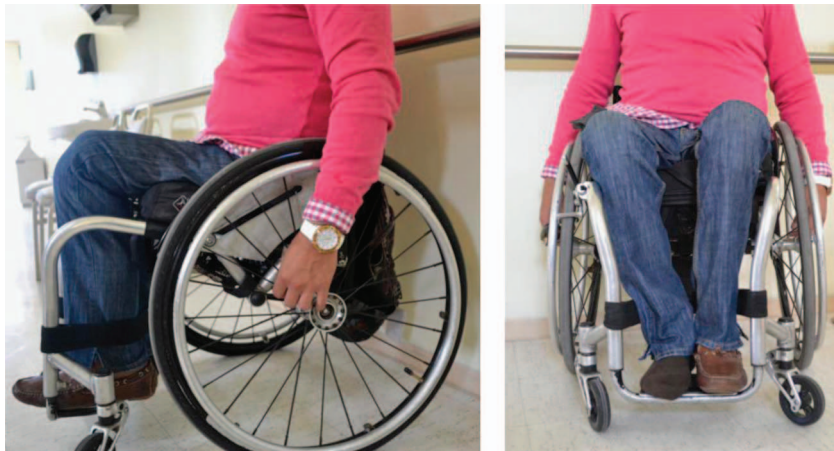

Figure 3. Lateral and front views of the patient with the prosthesis.

viscoelastic foam was then elaborated and pressure maps showed minimal pressure zones.

Three months after the disarticulation, the patient was found to be integrated into his normal life and working as a violinist. The SCI reintegration to normal living index was carried out, obtaining a score of 75, as well as a life satisfaction questionnaire with a score of 47. At 1 year of follow-up, he uses the cosmetic prosthesis 12 h per day in all his activities. The subject is independent on the use of his prosthesis, with good posture, without the presence of PU and with good emotional equilibrium (Figure 3).

DISCUSSION

This case report presents a patient who was quickly included in his professional and social activities after a serious complication of a SCI.

Yusmido *et al.*,² reported a similar case and mention that PU resistant to conservative management should be undertaken by means of amputation, with the aim of improving the patient's QOL, the level of functional independence and shortening of the hospital stay.

Different from that reported by Ohry *et al.*,⁴ in which the authors cite the total failure of prosthetization in SCI patients with amputation, in our case, good results were obtained in the prosthetization and integration of the patient into his work, familial and social life. This failure in the rehabilitation of the patient with amputation and SCI could be due to the complications mentioned by Ohry *et al.*⁴ and Meiners *et al.*,⁵ among which are found postural instability, poor body weight distribution with secondary dorsalgia, body image alterations and the formation of new PU, as well as phantom limb pain. In the present case, we prevented these complications with the management of an individually customized cushion, a light-weight and functional prosthesis and close psychological management.

Something noteworthy in this case and that Correa *et al.*¹ share is that patients with some personality disorders are at a greater risk of presenting PU, and even more so when the patient has NPD, which is considered as an obstacle for the recovery from and management of PU, but with positive results after amputation. In fact, we presume this personality disorder is the main cause of the

development of deep PU. The patient did not seek for help when the PU appeared and took too much time to do so because, according to the NPD, he thought he 'couldn't be wrong with the decisions token' (Sic. the patient).

In contrast with the studies reviewed, in our case, the patient's management was integral and multidisciplinary. Thus, we consider, in the result of our patient, the integral work of these previously mentioned services, to be of utmost importance.

As a recommendation for subsequent studies and as has been previously demonstrated in the study of Meiners *et al.*,⁵ at present there are, to our knowledge, no details with regard to indications to follow regarding the use of prostheses in this type of patient. Therefore, it is important to continue to conduct investigations on this theme.

CONCLUSION

This case illustrates the importance of working with a multidisciplinary team to approach complex cases, with multiple problems and special needs, with the aim of creating solutions for the reintegration of patients into their normal lives and with adequate patient QOL. This also opens the way to investigation on the prosthetization of patients with SCI.

COMPETING INTERESTS

The authors declare no conflict of interest.

REFERENCES

- 1 Correa GI, Calderón WO, Roa RG, Guzmán LM, Burnier LA, Danilla SA. Proximal amputation of inferior extremity secondary to recurrent pressure ulcers in patients with spinal cord injuries. *Spinal Cord* 2008; **46**: 135–139.
- 2 Yusmido YA, Hisamud-Din N, Mazlan M. Elective proximal lower limb amputation in spinal cord injury patients with chronic pressure ulcers. *Eur J Phys Rehabil Med* 2014; **50**: 557–560.
- 3 Chan J, Virgo K, Johnson F. Hemipelvectomy for severe decubitus ulcers in patients with previous spinal cord injury. *Am J Surg* 2003; **185**: 69–73.
- 4 Ohry A, Heim M, Steinbach T, Rozin R. The needs and unique problems facing spinal cord injured persons after limb amputation. *Paraplegia* 1983; **21**: 260–263.
- 5 Meiners T, Böhm V, Abel R, Gerner H. Amputation der unteren extremitäten bei querschnittgelähmten. *Orthopäde* 2001; **30**: 150–154.