

THE BRITISH JOURNAL

OF

OPHTHALMOLOGY,

JUNE, 1926

COMMUNICATIONS

THE TRIGEMINAL AND ITS OCULAR LESIONS

BY

LESLIE PATON

LONDON

THE following paper deals mainly with three types of ocular lesion, herpes simplex corneae, herpes zoster ophthalmicus and neuropathic keratitis. In all three types the trigeminal nerve is seriously involved and I have deemed it desirable to enter into some detail on the anatomy of this nerve. The peripheral distribution of the nerve is to be found in detail in all the anatomy textbooks. The primary nuclei and the secondary paths in the central nervous system are the subject of much controversy and many statements on these must be regarded as purely hypothetical. I have based my description mainly on Winkler and Cajal, but I would not have it thought that I wish to shelter myself behind the great authority of these names for any errors I may have committed. What I have tried to do was to work out some scheme that could be used for teaching purposes in my lectures at the National Hospital. It is this scheme that I have embodied in the two diagrams reproduced in the first part of my paper.

In the clinical part of the paper I have tried to summarize as shortly as possible some of the vast body of work that has been done in the last ten years on the subject of herpes, zoster, and varicella. The third part of the paper dealing with neuropathic keratitis is the most unsatisfactory. The more I read about this

condition and the more I see of it, the less satisfied do I become with all the hypotheses that have been advanced to explain it, and I fear my state of agnosticism finds its reflexion in the confused condition in which I have left this part of the paper.

I.—Anatomical

The trigeminal nerve may be regarded as a compressed group of afferent posterior roots and the Gasserian ganglion as a fusion of posterior root ganglia. The sensory afferent nerves from the whole face area and from a portion of the scalp are gathered together into the three main branches of this nerve and pass into the Gasserian ganglion and thence into the pons to be distributed up and down over a very extensive area of the brain stem from the mid-brain on a level with the anterior corpora quadrigemina to the upper part of the cervical region of the cord. It is a summation of posterior sensory roots corresponding to all the motor nerves originating from the brain stem. Of these motor nerves, one emerges from the brain as part of the fifth nerve (the motor root) to supply the muscles of mastication. The afferent fibres coming from the Gasserian ganglion enter the pons and have in part an ascending course, the mesencephalic root, and in part a descending course, the bulbo-spinal root. The mesencephalic, or ascending root, lies close to the grey matter surrounding the aqueduct and its fibres probably end in cells of the locus coeruleus and of the tectum. The bulk of the fibres pass down as the descending or bulbo-spinal root, close to the substantia gelatinosa Rolandi, forming a kind of cap over it, and end in relationship with cells of this area. It is traceable in gradually diminishing size as far as the second cervical level. This extensive distribution of the fifth nerve from the mid-brain down to the second cervical level and the numerous inter-relationships which it forms with the nuclei of origin of all the other cranial nerves form one of the reasons why headache so frequently results from many different causes and is so vague in its distribution. .

The Gasserian ganglion from which the fibres of the sensory portion of the fifth nerve arise lies in a small depression near the tip of the petrous bone on its antero-superior surface. It is semi-lunar in shape and the dura mater splits to form a sheath for it. The motor root passes behind it to join the third division of the nerve. The ganglion lies somewhat obliquely in the middle fossa of the skull and from its upper mesial portion arises the first or ophthalmic division with which we are mainly concerned. This trunk passes almost at once into the cavernous sinus and runs in its lateral wall. In this position it is joined by sympathetic

branches originating in the superior cervical ganglion and coming immediately from the carotid plexus round the ascending portion of the internal carotid in the cavernous sinus. Here also it probably forms anastomoses with the third, fourth, and sixth nerves and also gives off the recurrent nerve of Arnold which passes backwards into the tentorium cerebelli, possibly reaching the posterior pole of the brain and supplying the dura mater. Before leaving the sinus, the nerve splits into three main branches, the lacrymal, the frontal, and the naso-ciliary. All three enter the orbit through the superior orbital foramen, but only the naso-ciliary passes inside the annulus of Zinn.

The lacrymal is usually the first to branch off and passes outwards along the outer wall of the orbit where it divides into two branches, the lower of which anastomoses with the zygomatic (temporo-malar) branch of the second division of the fifth. By means of this anastomosis fibres from the facial nerve (*pars intermedia* of Wrisberg) may reach the lacrymal nerve. These fibres originate from the geniculate ganglion of the facial and, as the great superficial petrosal nerve, run to join the great deep petrosal from the cervical sympathetic and form the Vidian nerve. This enters the spheno-palatine ganglion which receives its main sensory supply from the superior maxillary branch of the fifth by the two main spheno-palatine nerves. The facial fibres must pass up these to reach the main trunk of the superior maxillary branch from which the temporo-malar arises. Evidence has been adduced to show that these fibres are the main secretory fibres of the lacrymal gland and that the fifth nerve does not itself contain secretory fibres (Goldzieher and Parsons). On the other hand, Wilbrand and Saenger suggest the possibility of a double secretory path: (a) for reflex secretion of tears by the fifth nerve; and (b) for emotional or psychic weeping by the seventh nerve. Hartmann thinks that reflex tear secretion may be innervated by the seventh. In this connection it is of interest to note the occasional cases in which yawning is accompanied by an increased tear flow, and even a suppressed yawn may lead to an increase in the tear secretion. Similarly excessive laughter is frequently accompanied by increased tear flow—"I laughed till I cried." The bulk of the lacrymal nerve fibres pass through the gland to supply the skin of the upper lid and conjunctiva in the neighbourhood of the outer canthus.

A case has been recorded in which the lacrymal nerve entirely replaced the zygomatic, supplying the skin area in the temporo-malar region usually supplied by the latter.

The frontal nerve runs along immediately under the roof of the orbit and gives off the supra-trochlear nerve which runs inwards and over the trochlea to reach the skin surface. The main stem is continued forwards as the supra-orbital. The supra-trochlear

nerve anastomoses with the infra-trochlear branch of the nasociliary and is distributed to the skin of the forehead above the eyebrows from the middle line outwards to the region of supra-orbital distribution and in connection with the infra-trochlear supplies the skin of the upper lid and the conjunctiva in the neighbourhood of the inner canthus.

The supra-orbital passes through the supra-orbital notch where it gives a twig to the frontal sinus and reaching the forehead, divides into a smaller median and a larger lateral branch. Its distribution passes back in the scalp as far as the coronal suture. Before passing through the notch, it gives twigs to the upper lid, and, in the notch, twigs to the diploe of the frontal bone and to the frontal sinus.

The naso-ciliary nerve is the most important branch from the ophthalmic surgeon's point of view, since from it is derived the main sensory nerve supply of the eyeball. It passes through the annulus of Zinn between the upper and lower divisions of the third, and passes obliquely beneath the superior rectus in company with the ophthalmic artery. Before crossing the optic nerve, it gives off the long or sensory root to the ciliary ganglion and also the long ciliary nerves, two or three in number. After crossing the nerve, it runs forward in the inner wall of the orbit, gives off the infra-trochlear nerve and then leaves the orbit by the anterior ethmoidal foramen. It then enters the cranial cavity and lies on the forepart of the cribriform plate of the ethmoidal bone. It gives off twigs to the dura in this neighbourhood and again leaves the cranial cavity by a slit at the side of the crista galli. Its three terminal branches are distributed respectively to the anterior part of the mucous membrane of the septum, to the anterior third of the mucous membrane on the lateral aspect of the nose and to the skin on the tip of the nose in the area below the nasal bones. The peripheral distribution of the second and third divisions of the trigeminal does not directly concern the ophthalmic surgeon.

The Primary Nuclei of the Fifth

The fifth nerve, then, is a very complex nerve: mainly composed of afferent fibres, there is a definite admixture of efferent fibres (the motor root of the fifth) for the supply of the muscles of mastication, and also of autonomic fibres, both centrifugal and centripetal. Only very brief notice need be taken here of the motor fibres and autonomic fibres. The motor nucleus of the fifth is a large nucleus which lies in the pons obliquely down and out from the corner of the fourth ventricle. The motor root passes out through the transverse fibres of the pons ventrally to the sensory root and passing under the Gasserian ganglion, joins up with the third division of the fifth.

The nature of the mesencephalic root of the fifth is a much discussed question. A balance of evidence seems to point to its being autonomic in function and the cells in the neighbourhood of the locus coeruleus where it is relayed are similar in character to the cells of the intermedio-lateral tract of the cord. The mesencephalic nucleus of the fifth lies in the border of the grey matter forming the angle between the floor and the side of the iter. It is subdivided into a dorsal and a ventral portion and lying between the two is a group of cells which do not seem to form a connection with the fifth nerve (the nucleus intertrigeminalis of Kohnstam) (Horsley and May). There may be a small bundle of fibres crossing the mid-line to the mesencephalic nucleus of the opposite side. The bulk of the fibres originating from cells of the mesencephalic nucleus or ending in it join up with the motor root of the fifth and go to supply corresponding areas.

The main nucleus of the fifth is the long bulbo-spinal nucleus in which the large, sensory descending root of the fifth is relayed. It is the primary central nucleus of the fifth and it stretches from a point in the pons anterior to the entry of the nerve to the level of the second cervical root. It can be subdivided into three parts which differ from one another in function and the secondary paths arising from these three parts have different destinations. The most anterior part (the nucleus sensibilis *a* of Winkler) is concerned in the reception of proprioceptive impulses. This portion probably does not pass back further than the medulla. The cells forming it correspond to the cells of the nuclei of Goll and Burdach, and some of the most posterior fibres of the fifth probably pass into the nucleus of Burdach directly. The second portion does not come forward quite so far as the first but passes further back (the nucleus sensibilis *b* of Winkler). It is concerned in the reception of interoceptive impulses and possibly also pain and temperature, and, as will be seen later, its secondary tract crosses to the opposite side to join the spino-thalamic tract. The cells forming this portion of the nucleus correspond to cells of the posterior horn and stratum spongiosum Rolandi. The third portion of the nucleus (the nucleus gelatinosus of Winkler) can be traced right down into the level of the second cervical where it is continuous with the substantia gelatinosa Rolandi. Proximally this portion of the nucleus stops much before either of the other two. The descending fibres of the spinal tract of the fifth pass down external to this and occupy the position of Lissauer's tract. Internal to it are commissural fibres of short range, *fibrae concomitantes*.

The fibres of the descending spinal tract of the fifth which reach the most distal portion of the nucleus are those which come from the ophthalmic division. Next come those from the second

division, and the third division are the most proximal. In other words, the earlier metameric division is to a limited extent maintained in so far that the sensory nerves from the buccal aperture go to the most anterior portions of the nucleus, those from the nasal apertures and the corresponding skin areas go to the middle portions and those from the eye and its surrounding area go to the lowest portions of the nucleus. It is sufficient to look at any reptile's head to see why this is so (Fig. 1). Clinically this fact may come into evidence in cases of syringomyelia high up, or syringobulbia when there may be loss of sensation affecting the forehead and the eye region with normal sensation over the buccal area. This low distribution of the ophthalmic division of the fifth

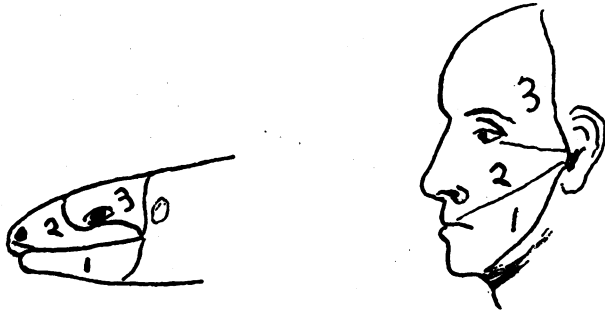


FIG. 1.

helps to explain the frequency of suboccipital headache in eye disease, as the great occipital nerve reaches the same level as the first division of the fifth, and it is not fanciful to regard them as dorsal and ventral branches of the same spinal root; further, it explains why there may be loss of corneal sensation in lesions not reaching the level of the bulb, and even, though rarely, neuropathic keratitis. The diagram (Fig. 2) has been constructed to show the primary central distribution of the fifth nerve.

The Secondary Paths of the Fifth

(a) *Short Paths concerned in Reflexes.* Stimulation of the peripheral endings of the fifth nerve results in a number of different reflexes. The probable paths of some of these are indicated in the diagram. Obviously, in some cases, the efferent fibres concerned must come from both sides, but, to avoid confusion, I have only drawn the collateral and omitted any contra-lateral connections in Fig. 2. The linking up with the mesencephalic root of the fifth, if the assumption of its autonomic function is justified, will give rise to the vascular and secretory reflexes. The motor fifth takes part in the various reflexes concerned in mastication and

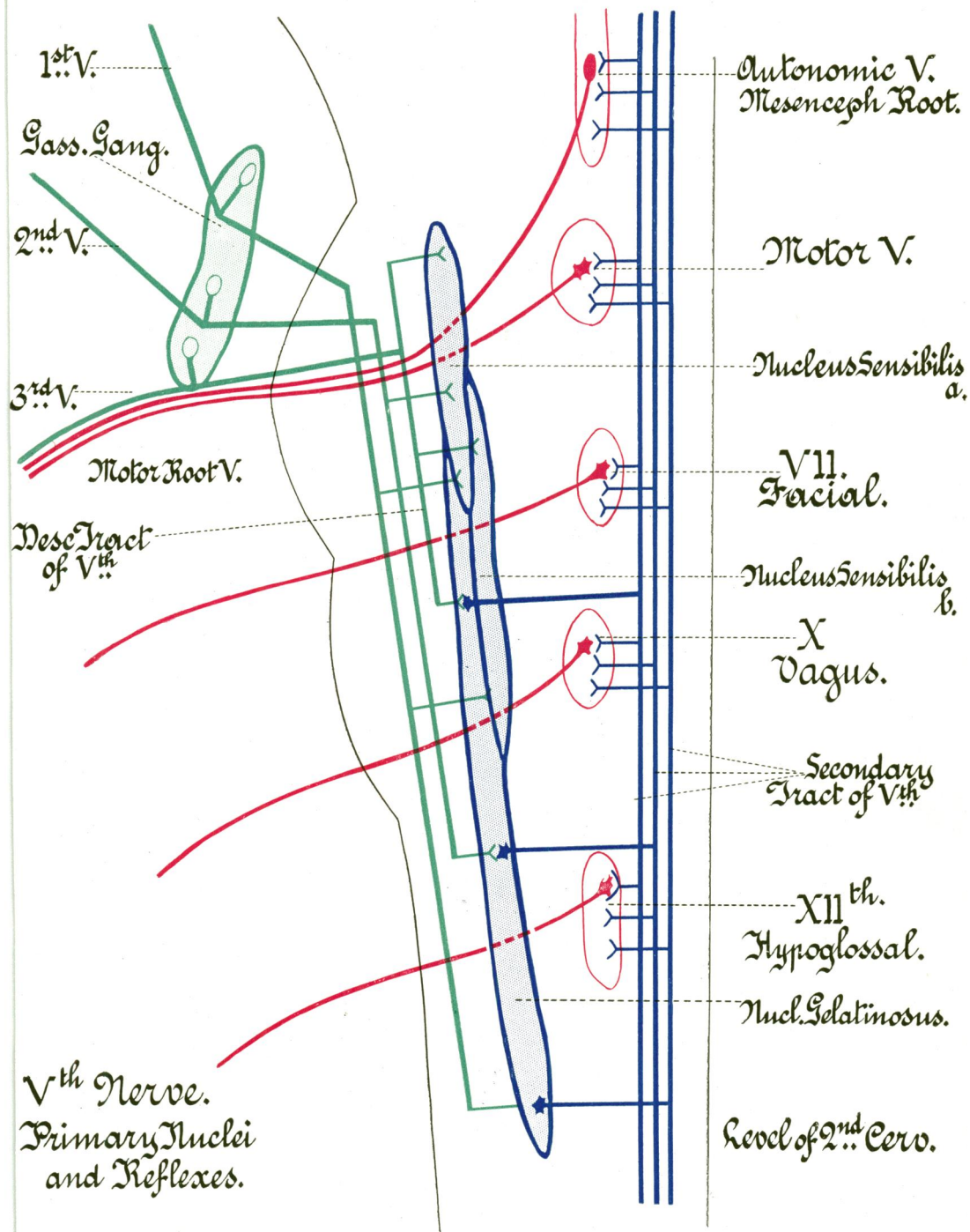


FIG. 2. Trigeminal Nerve. Primary Nuclei and Reflex Arcs.

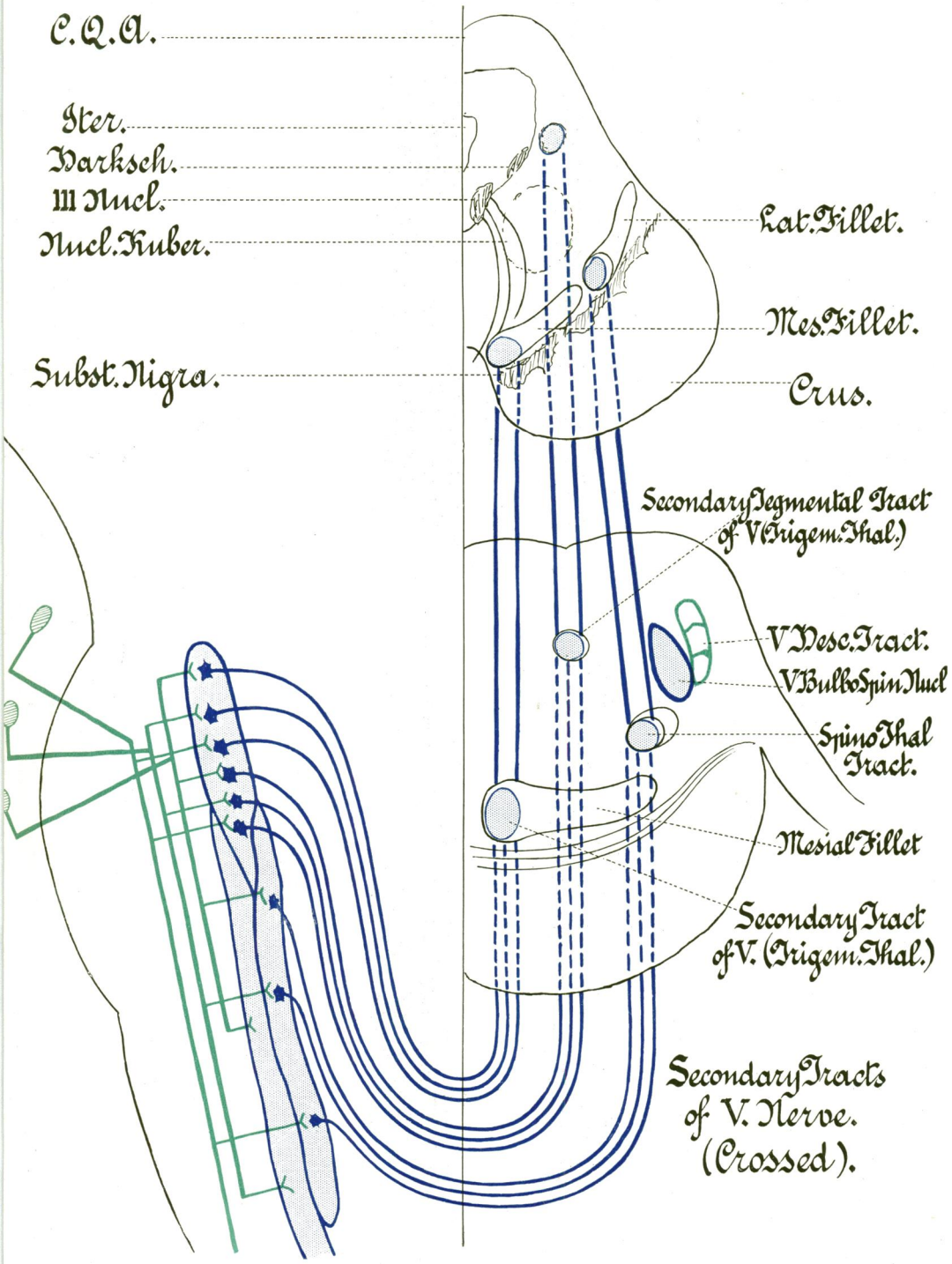


FIG. 3. Trigeminal Nerve. Secondary Tracts. (Crossed).

the motor fifth and the seventh and the hypoglossal are concerned in the sucking reflex. The seventh is the efferent nucleus mainly concerned in the protective blinking reflex and is possibly also concerned in the reflex secretion of tears by the intermediary of the nerve of Wrisberg and the great superficial petrosal. In the sneezing reflexes, the vagus mainly is concerned, and again in the oculo-cardiac reflex. This linking up with the vagus also accounts for the marked vascular and gastro-intestinal disturbance and vomiting that may occur in acute glaucoma. In addition, these short fibres may be the secondary path for some form of common sensation.

(b) *The Ascending Secondary Paths of the Fifth.* The main secondary paths which have been traced from the other portions of the fifth nucleus cross the mid-line at once and join ascending contra-lateral tracts (Fig. 3). Those from nucleus sensibilis *a* of Winkler (proprioceptive fibres) have two separate paths to reach the thalamus. The first and most important pass across ventrally by the arcuate fibres and form the trigemino-thalamic tract at the inner end of the mesial fillet, and so reach the ventro-lateral surface of the ventral nucleus of the thalamus. The dorsal path crosses the raphé to reach the formatio reticularis tegmenti and in all its course remains dorsal and lies laterally to the grey matter of the iter. It reaches the dorso-medial surface of the ventral nucleus of the thalamus. In addition to carrying the proprioceptive impulses, these two secondary paths probably also carry some tactile sensation from areas corresponding to their distribution.

The secondary path from the nucleus sensibilis *b* crosses the raphé ventrally and joins the spino-thalamic tract which, as it runs forwards, lies ventrally and a little mesially to the lateral fillet when this is formed in the pons. In this position it runs up to reach the lateral part of the thalamus but its exact termination has not, so far, been very definitely ascertained. Like the spino-thalamic tract, it conveys sensations of heat and cold and pain, mainly interoceptive, *i.e.*, from the mucous membranes of the areas concerned.

Physiological Constitution of the Fifth

The physiological constitution of the ophthalmic division of the fifth is almost as complicated as its anatomical distribution. In the main sense, it is a sensory nerve, it certainly has linked up with it fibres from the cervical sympathetic which carry not only vaso-constrictor impulses but also the motor fibres of supply to the unstriated fibres of the levator palpebrae superioris, to Müller's muscle and to the dilatator pupillae fibres which leave the naso-ciliary nerve by the long ciliary nerves. There is also a possibility that it

conveys secretory fibres to the lacrymal gland by the lacrymal nerve, though, as I have already stated, secretory fibres to the lacrymal gland may arise from the facial and reach their destination by joining up with the zygomatic branch of the second division.

The possibility of vaso-dilator action in a sensory nerve must also be considered specially in connection with the trigeminal, and whether it is produced by anti-dromic impulses in normal afferent fibres or implies the existence of special efferent fibres.

Lastly, there is the very important question of the existence or non-existence of special trophic fibres in the nerve.

II.—Pathological

In dealing with the ocular lesions in which the fifth nerve may be concerned, we must fix somewhat arbitrary limits. In one sense it may be stated that the fifth nerve is involved in all ocular lesions. The reflex distribution of pain in ocular lesions is along the distribution of the fifth. In milder cases, only the ophthalmic division may be affected, but in more severe cases, the pain may spread to the other divisions, as in acute glaucoma. Not only so, but the headache resulting from eye strain may affect not only the areas supplied by the various branches of the fifth, but probably owing to the central connections of the first division passing down so far into the cervical region, we may find headache referred to the distribution of the great occipital and other of the upper cervical nerve roots. It is well known that suboccipital and occipital headaches frequently result from disturbed eye conditions, and the pain occasionally passes down the back of the neck. The linking up of the fifth nerve with the vagus accounts for the gastrointestinal disturbance and vomiting that occur in acute glaucoma and explains also the oculo-cardiac reflex. It may also help to explain why relief of eye-strain may in some cases be of value in the treatment of nervous indigestion. Reflex sneezing, reflex yawning and reflex weeping are all matters whose explanation requires a consideration of the connections of the trigeminal nerve. Further, vascular changes must be considered, and the occasional phenomena resulting from abnormal associations of the fifth, *e.g.*, the jaw winking which results from some linking up of the motor fibres of the fifth with the third nucleus on the one hand and possibly the facial on the other hand.

Some of these possibilities have been alluded to in dealing with the central connections of the fifth nerve, but it is in a much more limited sense that I wish to discuss ocular lesions of the fifth nerve, where a lesion, traumatic or toxic, whatever the source of the toxin, affecting the nerve in any part of its course, either centrally or in its ganglion or in its peripheral distribution, forms an essential, primary or secondary, element in the ocular lesion.

We have to deal with a ~~series of cases somewhat ill-defined~~, and, consequently, difficult to classify, and where the nomenclature in use only adds to the confusion. Also, the cases with which we have to deal have revealed during the last decade connections of the most unsuspected and wide-spread nature, and almost every week, fresh researches appear, so that the statements written to-day may be completely out of date before they are printed.

Provisionally, we may subdivide the ocular conditions into three classes :

1. Where only the peripheral nerve terminals are affected by the lesion.
2. Where the peripheral nerve terminals and the nerve in general are affected :
 - (a) From the periphery up, or
 - (b) Simultaneously.
3. Where the primary lesion is central or in the ganglion and the peripheral distribution is only affected secondarily.

But it is only necessary to write down the classification to see how unsatisfactory it is, *e.g.*, recurrent erosion of the cornea would certainly be included in the first class, but dendritic ulcer of the cornea may be in Class 1 or Class 3. It may be a local herpes corneae simplex or it may be a secondary herpes corneae, following on pneumonia or influenza or meningitis, or it may be a herpes corneae febrilis and so come into Class 2 (b). Again, neuropathic keratitis resulting from excision of the Gasserian ganglion would go in Class 3, but herpes zoster ophthalmicus may belong to Class 3 or Class 2 (b) when it occurs in epidemic form. The symptomatic form of herpes zoster would undoubtedly go into Class 3 and is closely related to neuropathic keratitis. The toxic form of herpes simplex, *e.g.*, resulting from arsenic or carbon monoxide poisoning, may be a peripheral phenomenon, but the relationship of herpes febrilis to a form of encephalitis and possibly to vaccinia shows that, sometimes, at any rate, the local peripheral manifestation is purely a secondary phenomenon.

From a clinical standpoint, it is desirable to make a very clear distinction between herpes simplex corneae, and herpes zoster ophthalmicus. Whatever the ultimate verdict may be on the work of Grüter in Germany, of Lipschütz in Vienna, and of Goodpasture and Teague in America, the two conditions in their typical manifestations are easily differentiated from one another. Further, it is desirable to differentiate clearly between what I have called epidemic herpes zoster and symptomatic herpes zoster. In the following pages, as far as possible, I shall use the term "herpes" meaning herpes simplex or herpes febrilis and "zoster," meaning herpes zoster.

Peripheral Lesions involving the Terminal Distribution of the Fifth Nerve

(1) Recurrent erosion of the cornea (recurrent bullous or vesicular keratitis). The pathology of this condition is obscure, but as the result of an abrasion of the cornea there is injury to the superficial plexus of nerve fibrils. It may be that, instead of regenerating properly and making their way in amongst the new epithelial cells, the nerve fibrils form terminal neuromata as in a painful stump, and so an area of regenerated epithelium is formed without its normal nerve plexus. In favour of this hypothesis is the fact that scraping the edge of the exfoliated erosion usually results in preventing further recurrences. An exactly similar condition may occur without any history of antecedent injury.

(2) Superficial punctate keratitis also may have a distinct nerve element in it. The punctate distribution of the condition probably corresponds with the points where the nerve fibres pass through Bowman's membrane from the deeper to the superficial corneal plexus and its occasional association with attacks of supra-orbital neuralgia points to a nervous element in it. I have seen it after alcohol injection of the Gasserian ganglion (*v. infra*).

(3) Marginal dystrophy of the cornea (marginal keratectasia). There is some evidence for ascribing this rare condition to a neuropathic basis, but the anaesthesia in this condition and in Mooren's ulcer may be secondary.

Herpes corneae (not zoster)

(4) Dendritic ulcer of the cornea is the commonest form in which herpes corneae manifests itself. This may occur (1) as a local corneal reaction to the herpes virus without any coincident systemic affection; or (2) as a reaction of the corneal tissues to the herpes virus when the tissue resistance has been lowered by some other disease, such as influenza, pneumonia, etc.; or (3) there may be a coincident systemic invasion by herpes virus (herpes febrilis corneae); (4) it is possible that a similar condition may be produced in the absence of the herpes virus by the action of other toxins, either of microbic origin, Pfeiffer's bacillus, pneumococcus, b. coli, typhosus, etc., or mineral poisons, such as arsenic and carbon monoxide, though these latter are more likely to cause outbreaks of herpes of the skin or mucous membranes rather than of the cornea.

To Grüter is due the main credit of the discovery of the transmissibility of herpes febrilis and of the relationship of the various forms of simple herpes to one another. The commonest manifestations are herpes labialis, herpes facialis, herpes genitalis and herpes corneae.

The virus belongs to the ultra-microscopic filter-passing group. Lipschütz claims that it belongs to the class of chlamydozoa and that it forms inclusion bodies (acidophil) in the nuclei of the affected epithelial cells. The formation of these intranuclear inclusions has been confirmed by Goodpasture and Teague, and Luger, but the nature of their relationship to the herpes virus is very doubtful and it has yet to be proved that they are specific manifestations of herpes febrilis. Similar inclusion bodies are found in the nuclei of the cells of the central nervous system in cases of encephalitis herpetica in rabbits. They have also been said to be present in chicken-pox. The absence of the inclusion bodies in cells in encephalitis lethargica has been used by Goodpasture as an argument against the hypothesis of Levaditi and his school on the identity of encephalitis lethargica and encephalitis herpetica. But as it has been found that these inclusion bodies are only to be found in the earlier stages of the infections, too great stress must not be laid on negative results. Though the analogous inclusion bodies (intracellular) discovered by Prowazek and Halberstaedter were at first regarded as the causal agents of trachoma, the relationship still remains unproven and in both cases, the changes may simply be due to the action of the toxins on the cellular or nuclear tissues.

Whatever its nature, the virus from a vesicle in any case of true febrile herpes can be transferred by suitable means to the cornea of rabbits and there sets up a very clearly defined type of reaction in which the cells of the infected tissues show these intranuclear changes.

The work of Grüter has put on a definite basis the original theory of Horner (1871) as to the relationship of herpes corneae to herpes febrilis but its greatest importance lies in the wide new field of research which it has opened up, leading in quite unexpected directions. The discovery that infection of the rabbit's cornea with the virus from herpetic vesicles may lead to an infection of the central nervous system and the production of a form of encephalitis similar in its nature to encephalitis lethargica is due to the work of Doerr and Vochting, Loewenstein, Harvier and Levaditi and the pupils of Levaditi and many others. It yet remains in doubt whether the encephalitis is a special form, encephalitis herpetica, or, as Levaditi and his school teach, the same disease as encephalitis lethargica. The histological changes produced in the grey matter of the central nervous system in the two diseases are very similar, but the identity of the virus is not as yet proven. The doctrine of the Levaditi school is that the herpes virus is capable of assuming in different strains and under varying conditions either a dermatropic tendency or a neurotropic tendency. Under normal conditions of toxicity it is dermatropic and produces only the skin reactions of herpes simplex but its

toxicity may be increased (by passage through a series of rabbits), and it then acquires a neurotropic tendency. In the hands of Levaditi, this doctrine has been extended to a much wider field and applied to other viruses which he claims can show a similar variability, *e.g.*, the allied virus of vaccinia. The most interesting development of the doctrine is its application to syphilis and the suggestion that the *spirochaeta pallida* may exist in two differing strains, one with a mainly dermatropic tendency and the other mainly neurotropic.

It must not be forgotten, however, that the variations in the tissue reactions to herpes virus may be due to variations in the tissue resistances (different states of allergie) rather than to any great variations in the toxicity of the virus. The liability of herpes corneae to develop in asthenic conditions is one of the commonplaces of ophthalmic experience, and it is equally true of all the other forms of herpes simplex. We find the condition manifesting itself in association with a number of diseases which reduce general tissue resistance. We may not be prepared to go as far as Grüter who regards contagious impetigo as primarily herpetic with a secondary staphylococcal infection, but there are considerable grounds for the belief that there exists a definite percentage of the population normally carriers of the herpes virus and that, on the least lowering of tissue resistance, local or general, this class develops herpetic manifestations. And it is interesting to speculate on what part the war may have played by its lowering of general nutrition and its strain on the nervous system in determining the attack of a virus of this nature on the central nervous system, and the consequent appearance in Austria of encephalitis lethargica in the year 1917.

The work of Marinesco and Draganesco and of Goodpasture has shown that the virus passes from the periphery to the central nervous system by the nerves and that any nerves, motor, sensory or sympathetic, can transmit it. When, as is usual, the cornea is selected for primary infection, the path centrally is by the first division of the fifth, and the primary focus of infection in the central nervous system is the bulbo-spinal root. Marinesco and Draganesco suggest the perineural lymph spaces as the path of transmission, but Goodpasture argues for direct transmission along axis cylinders inside the myelin sheath. The former hypothesis is much more in conformity with previous work on the paths of infection of the central nervous system (*e.g.*, Orr and Rows' work).

There seems to be little doubt that the slowness of healing and the tendency to constant recurrences which make dendritic ulcers so troublesome to deal with depend on the extent of the neural involvement. The greater the diminution of corneal sensibility the greater is the tendency to recur and the slower the healing.

LESIONS INVOLVING THE WHOLE NERVE AS WELL AS
NERVE TERMINALS

I.—Herpes Zoster Ophthalmicus

Jonathan Hutchinson gave the first good clinical account of ophthalmic zoster in the year 1866. It still remains as one of the best descriptions of the disease. I think, however, it is necessary to recognize that cases of herpes zoster must be separated into two distinct categories, the one I shall call "epidemic zoster," and the other "symptomatic zoster." Epidemic zoster occurs as the result of a definite infection which produces constitutional disturbance and fever and runs a more or less similar course in all cases from the time of onset to subsidence. It mostly attacks adults and is more frequent in the later decades of life but Roll reports a case in a child aged 3 years, Verhoeff a case in a child, and Fisher a case, a child of 9 months. Its epidemics seem to bear some definite relationship to epidemics of chicken-pox. There is indeed a very definite body of evidence in favour of the infective agent being the same in the two diseases. Epidemic zoster seems to be a disease closely allied to the exanthemata on the one hand, and to anterior poliomyelitis and encephalitis lethargica on the other. It is said to be more frequent in males than in females, but, personally, I have seen more cases in women than in men. The epidemics, in my experience, are most frequent in the early spring months, but occasional sporadic cases may be met with in the autumn.

In symptomatic herpes zoster, we find quite a different history. The outbreak of the herpetic eruption is here due to the secondary involvement of the sensory nerve or posterior root ganglion in the course of some other lesion, *e.g.*, in the course of a syphilitic or tuberculous meningitis, a basal or a spinal cord fracture, a pontine tumour, in tabes, and in various other ways by which the Gasserian ganglion or the spinal root ganglia may be secondarily affected.

Epidemic herpes zoster, like others of the exanthemata, seems to convey an immunity, comparative if not absolute, against recurrence. Head and Campbell state that its recurrence is less common than the recurrence of measles. They found only four cases of recurrence in a series of 400 cases. The occurrence of chicken-pox in childhood does not safeguard the adult against herpes zoster (but *v. infra*, Kundratitz's work). In symptomatic herpes zoster the evidence of nerve involvement, *e.g.*, the neuralgic pains, may precede any herpetic eruption by long periods. In epidemic zoster, the neuralgic pain and the constitutional disturbance only precede the eruption of vesicles by one to four days, and sometimes they are simultaneous in their development. It is of considerable importance in the interpretation of cases to remember the possibility that zoster may be secondary and

symptomatic and that, in consequence, many of the lesions developing in the course of such a case may be the results of the primary lesion, *e.g.*, a cerebral tumour, and not of the secondary involvement of the nerve ganglion or nerve.

The history of an ordinary case of ophthalmic herpes zoster will show a sudden onset of very severe neuralgic pain over the distribution of some or all of the branches of the nerve, accompanied by more or less marked constitutional disturbance, and some degree of fever. This is rapidly followed by flushing of the affected skin area and an outbreak of vesicles and severe oedema over the distribution of the affected nerves. The vesicles are at first filled with clear fluid, perfectly sterile in all ordinary culture media. The fluid rapidly becomes turbid and yellow, and the vesicles may coalesce until hardly any area of normal skin remains. In course of time, the vesicles break, discharge, and then dry up to form scabs which leave deep permanent scars, showing that the true skin has been affected by the necrotic process. In this respect true epidemic zoster differs from the herpetiform eruptions which occur in herpes febrilis, *e.g.*, herpes labialis. The neuralgic pains subside, as a rule, with the subsidence of the eruption, but may persist for even some months, and may leave a permanent hyperalgesia. As a rule, the whole process lasts about three to six weeks.

Distribution of Eruption :—The two branches which are almost invariably affected are the supra-orbital and supra-trochlear; the lacrymal and naso-ciliary frequently escape, but all the branches of the first division may be invaded. It is very rare to find the second or infra-orbital division of the fifth involved, but, during a recent epidemic, I saw a case in which both first and second divisions were completely invaded.

Douglas described a case of herpetiform eruptions on both sides of the face and neck, and Myers describes and figures two cases of symmetrical herpes. Passera, in 1913, described a case in which the first and second divisions on both sides were affected, and several others have been described, but from the descriptions I have read, I incline to the belief that some of them at least belong to the category of symptomatic herpes. The other branches of the fifth may be affected independently of the first, but the ophthalmic division is by far the most frequently affected.

Even before the vesicles develop, there is usually definite photophobia and lacrymation, and the surface temperature is raised on the affected side. According to Horner, there may be a difference of as much as 2° between the two sides. In one of my cases at St. Mary's Hospital, which came under observation two days after onset of the vesicles, the surface temperature on the healthy side was 98° , on the affected side 99.8° , the records being

taken simultaneously and confirmed by changing the thermometers. As the condition subsides this difference in surface temperature disappears.

In most cases it is possible to demonstrate a marked diminution of sensibility over the affected area, which may persist for some considerable time after the subsidence of the other symptoms. As Head has shown, this is quite consistent with the hyperalgesia to which I have already referred. This anaesthesia may be associated with the persistence of severe neuralgic pain, often much exaggerated on exposure to cold, the very distressing condition of anaesthesia dolorosa. As a rule, however, after subsidence of the main symptoms, the patient complains mostly of a feeling of tightness or numbness over the affected area.

I think it is safe to say that ptosis is invariably present, but it must be remembered that it is partly due to the oedema of the upper lid, and partly a reflex blepharospasm. It is consequently difficult to say in what proportion of cases there is a paralytic element in the causation of the ptosis and still more difficult to say whether the paresis affects only the sympathetic fibres going to the levator palpebrae superioris, or also the oculo-motor fibres.

The conjunctival and episcleral tissues are invariably in a condition of hyperaemia.

The globe itself is affected in just over 50 per cent. of cases, and in the majority of these it is the cornea that suffers (35 per cent. of all cases). Jonathan Hutchinson laid great stress on the fact that the globe is never affected except in cases where the naso-ciliary nerve is affected. In the *Ophthalm. Hosp. Reps.*, Vol. VI, p. 48, the law is stated: "All the cases I have yet seen support the opinion I have expressed that it is only when the side of the nose is affected that any serious inflammation of the eye ensues and that in the worst cases the vesicles will be found on the very tip of the nose, the part supplied by the oculo-nasal nerve." Personally, I have found this dictum of great service in prognosis though quite a number of exceptions to it have been recorded. I have records of two recent cases, in one of which, despite the absence of any obvious sign of naso-ciliary involvement in the skin, the globe was affected. In the other, despite the very severe involvement of both first and second divisions of the fifth, I thought at first that the globe had entirely escaped and it was only some time after the subsidence of all the symptoms that I was able to find three very faint nebulae in the cornea.

In my own experience, the most frequent primary corneal lesion takes the form of small round infiltrations in the more superficial layers of the substantia propria of the cornea (Figs. 4 and 5). It is tempting to think that these infiltrations take place round the points where the nerve fibrils pass from the deeper corneal plexus to the

more superficial. In the earlier stages, definite lines of infiltration may sometimes be seen as well as the round spots. These infiltrations may give rise to vesicles, but in many cases they do not do so. Secondary infection may take place and result in superficial ulcers or in keratitis profunda. Or the condition may subside without suppuration. The most serious corneal complication I have met with was one case in which a neuroparalytic keratitis developed with a marked hypotony and subsequent phthisis bulbi. The shrunken globe remained acutely painful and had finally to be removed eighteen months after the occurrence of the zoster.

My own observations are in agreement with those of Sulzer and many others, and with what, on *a priori* grounds, the general pathology of zoster would lead us to expect, that the primary corneal changes should occur in subepithelial regions, and that vesicle and ulcer formation should be secondary to deeper infiltrations. As may be evident, I am not altogether in agreement with Cohn on the nature of the corneal complications met with in zoster. He divided them into the following classes :

1. Herpetic vesicles.
2. Ulcers. (a) Superficial.
(b) Deep.
(c) Ulcus serpens.
3. Non-suppurative keratitis.
(a) Superficial.
(b) Deep.
4. Neuroparalytic keratitis.

And there may be various combinations of these. Cohn is very sceptical about the occurrence of deep keratitis without a pre-existing superficial lesion. Personally, I think the primary corneal lesion is the subepithelial infiltration represented in Figs. 4 and 5. This may result in vesicle formation and subsequent secondary infection and ulceration, or it may lead to keratitis profunda, but in many cases, it remains the sole manifestation in the cornea.

When corneal ulcers do develop in herpes, I have found them very slow to heal and very troublesome to treat. I think the only thing to do in very severe cases is to treat them like cases of neuroparalytic keratitis and sew the lids together.

The pupil in the majority of cases is small. This is mostly a reflex miosis. In a small number of cases, however, a paralytic mydriasis occurs, sometimes associated with paralysis of accommodation and ptosis. I shall refer to that again in connection with ocular palsies. Iritis or cyclitis have been, in my experience, mostly late manifestations, *i.e.*, towards the end of the first week, but iritis has been seen occasionally preceding the skin eruption. Gould gives an account of one case where the iritis preceded the

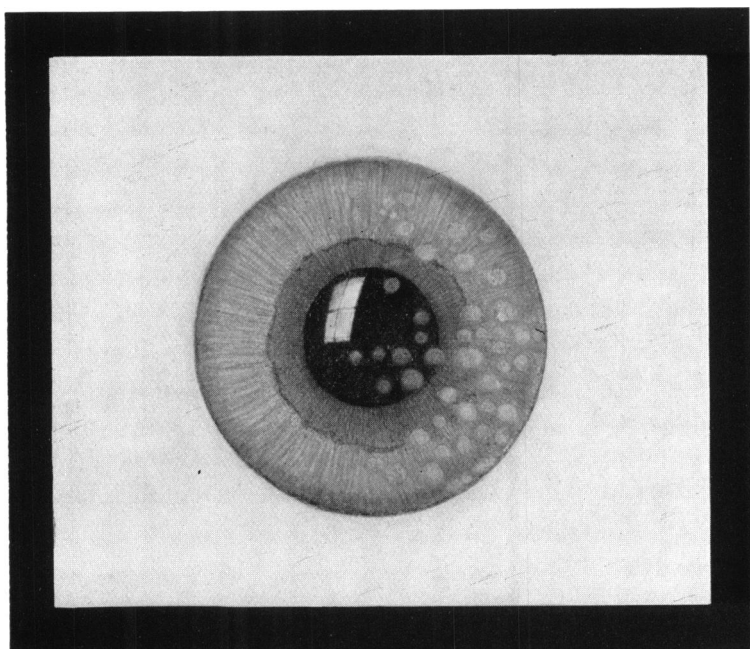


FIG. 4.

The common type of corneal involvement in zoster ophthalmicus.
(From a pencil drawing by the author.)




FIG. 5.

A similar spot in another case as seen by the slit-lamp.

skin eruption by some weeks. The case was complicated in other ways and does not seem to belong to the ordinary type of epidemic herpes zoster. In one of my cases the skin eruption had all subsided and the scabs had dried before any sign of cyclitis showed itself. Then definite cyclitis developed with keratic precipitates but no iris adhesions. The iritis occasionally shows a definitely herpetiform character. Rollet subdivides the cases of iritis into two classes, a primary iritis zostérienne and a secondary infected iritis. The development of irido-cyclitis probably explains the cases of raised tension sometimes recorded after herpes.

As a rule the intraocular tension is low in herpes, and the condition of hypotony may persist for a considerable time. In the early stages the severe inflammation makes it impossible to measure the intraocular tension accurately, but finger testing will often show a very definite lowering. Even in this stage, however, the occurrence of quite definite foldings in Descemet's membrane may be seen on slit-lamp examination. These folds when they occur are probably due to the hypotony. Later on when the tonometer can be used I have found a difference of 5 mm. Hg. pressure between the two eyes though by this time the foldings in Descemet's membrane could no longer be seen. The tension in the normal eye in one case was 19 mm. and in the affected eye 12 mm. Hg. On the other hand quite a number of cases have now been recorded with raised tension. At a meeting of the Netherlands Ophthalmological Society in December, 1918, G. ten Doesschate recorded a case of right herpes ophthalmicus in a man, aged 52 years, where the intraocular tension in the right eye rose to 60-70 mm. Hg. with marked exophthalmos. In the following year, 1919, at a meeting of the American Ophthalmological Society, Veasey reported a case of right herpes with plus tension following two weeks after. In the discussion on Veasey's case several speakers, including Knapp and de Schweinitz referred to similar cases, and the general opinion was that the rise of tension was due to irido-cyclitis and that mydriatics could be used with benefit.

Optic Neuritis in Herpes :—The occurrence of true optic neuritis as a complication of ophthalmic herpes is comparatively rare. Personally, I had never seen a case with this complication until 1922, when, through the courtesy of Mr. Adams of Oxford, I saw a private case of his, a lady, aged 35 years. She had had shingles on the right side, commencing on May 15. The whole first division of the fifth was affected. When the eye was opened again after the attack of herpes had subsided, it was found that she had become completely blind in that eye. The pupil was semi-dilated and did not re-act to light at all. When I saw her she was still slightly under the influence of atropin, so I was not able to confirm the question of pupil re-action. Her tension was quite normal.

There was no perception of light. Ophthalmoscopic examination showed an absolutely atrophic disc. I have seen her since and there has been no recovery of vision.

The second case, Mrs. W., aged 67 years, was sent to me at St. Mary's by Dr. Vincent of Strood, Kent, in the beginning of December, 1922. The history was that at Easter, 1922, she had had a bad attack of ophthalmic herpes affecting all the branches of the first division of the fifth on the left side. There were faint nebulæ in the cornea, lying under the surface. On recovery from the herpes she found that the vision of her left eye was lost.

When first seen—

$$\begin{array}{l} \text{R.V. } + 3\text{D. Sph.} \\ \quad + 1.5\text{D. Cyl. ax. } 100^\circ \end{array} = 6/6.$$

L.V. Hand movements.

Field evidently very limited. Left pupil did not re-act to direct stimulus, but re-acted well on consensual stimulus; re-acted slightly to concentrated light. The ophthalmoscope showed an opaque, white disc, with fairly clean-cut edges. Lamina cribrosa not seen. No obvious disturbance of retinal pigment round edges of disc. Vessels reduced in calibre.

Quite a number of such cases have already been recorded. Jonathan Hutchinson, in his classical account of the condition, when he first clearly differentiated it, showed its nature and described its clinical history, gives (*Ophthal. Hosp. Reps.*, Vol. V, p. 191) one case of blindness resulting from an attack of ophthalmic herpes.

Some time in the year 1867, Bowman reported another case of left herpes with optic atrophy, and in the same volume Hulke records a case in which optic neuritis preceded by a few days the development of herpes, but in these cases, the herpes was probably secondary in character and not a primary acute infective herpes.

The next case that I can find is a case of Daguinet, recorded in 1877: "Zona ophtalmique avec nevríte optique du côté correspondent." In this case, during the acute stages, vision was reduced to bare perception of light, but four days later the vision was recorded as being one-sixth. Gould in 1888, recorded a case in an American publication, *The Polyclinic*, but I have not been able to see a copy of it. I cannot find any further record until a case recorded by Wangler in an inaugural dissertation at Zürich in 1889. In 1893, Haltenhoff, in the *Ann. d'Ocul.*, Vol. CIX, p. 201, recorded a case in which there was haemorrhagic retinitis, associated with herpes. From the description of the case, it seems almost certain to my mind that there had been a thrombosis of the central vein of the retina, because the haemorrhages were most profuse, involving the whole retina,

except the macula. The veins were very dilated and tortuous, and obscured in numerous places by haemorrhages, and the arteries were reduced in calibre. There was, however, very little evidence of any swelling of the disc. Sulzer, in 1898 recorded a case of double optic neuritis, more severe in the right eye than in the left eye, with right herpes. The fact that there were three recurrences points rather to the conclusion that this was not an ordinary case of primary herpes zoster, but rather a symptomatic herpes associated with some intracranial condition. As Jonathan Hutchinson points out, in true herpes zoster there is no liability to a recurrence of the disease. In cases where recurrences are frequent it is more likely that these are either herpes simplex or what I have termed symptomatic or secondary herpes.

Antonelli, in 1902, recorded another case, and at a meeting of the American Ophthalmological Society in June, 1919, Dr. Clarence Veasey recorded a case in which on the seventh day of an attack of right ophthalmic herpes, vision was lost in the right eye except for a small portion in the upper field, the loss beginning as a central scotoma and gradually spreading without evidence of ophthalmic changes or of corneal involvement. A month later some vision was restored in the peripheral field and the patient could count fingers at two feet. The optic disc was quite pale and atrophic and subsequently all vision was lost. In this case then the neuritis was evidently retrobulbar. Mr. McMullen has since told me privately of a further case under his observation.

Oculo-motor Paralysis:—Any of the oculo-motor nerves may be affected and suffer temporary paralysis. The occurrence of an oculo-motor palsy seems to bear no relation to the intensity of the pain or the severity of the disease. According to the records the third seems to be more frequently affected than the fourth or sixth. I have already spoken of the frequency of ptosis and the possibility that in many cases it is mainly mechanical from oedema or partly due to oedema and partly sympathetic, but there are cases in which it is accompanied by mydriasis and paralysis of accommodation, and sometimes also by paralysis of the internal rectus, so that some of the cases where these complications are absent may be due to partial third nerve palsy. On the other hand, Wyss, in his pathological examination of a case of herpes, published in 1871, found numerous haemorrhages in the muscle substance of the ocular muscles, and ascribed the muscular paralysis to a thrombo-phlebitis and not to nervous causes.

I have seen in the last two years one case of sixth nerve palsy and three of third nerve palsy, and Vogel, in an inaugural thesis, described two cases of fourth nerve paralysis occurring in herpes zoster.

The facial nerve is occasionally affected, but is more likely to

suffer when the second and third divisions are attacked. In one of my cases where the first and second divisions were both invaded, there was no evidence of facial weakness.

Pathology

The majority of pathological examinations in cases of herpes zoster indicates that the primary lesion is in the posterior root ganglion or the Gasserian ganglion. This original discovery of von Bärensprung in 1861 has been confirmed in many subsequent papers and more especially in the admirable work of Head and Campbell, with its large series of fully investigated cases, published in 1900. Briefly stated, their standpoint is that herpes zoster is an acute toxic infection of the posterior root ganglion exactly allied to anterior poliomyelitis occurring often in epidemics which seem to have some dependence on seasonal changes. "The acute changes found in the ganglion . . . consist of (1) an extremely acute inflammation with the exudation of small, round, deeply staining cells; (2) an extravasation of blood; (3) destruction of ganglion cells and fibres; (4) inflammation of the sheath of the ganglion. If severe, such a condition ultimately leaves a scar in that part of the ganglion affected and leads to thickening of the sheath above the affected area. On the other hand, if the eruption has not been severe, all traces of the inflammation present in the acute stage may pass away leaving the ganglion apparently normal."

Sunde (*Deutsch. med. Wochenschr.*, No. 18) in 1913 examined a recent case of herpes zoster and found the Gasserian ganglion swollen, numerous haemorrhages, especially in the neighbourhood of the origin of the first division, round-celled infiltration, fibrino-purulent exudation and numerous gram-positive diplococci, some of them arranged in chains.

Some observers have reported cases which would seem to indicate the possibility that a peripheral neuritis or perineuritis may also cause herpes zoster. Pitres and Vaillard in 1883, and again Curschmann and Eisenlohr in 1884, found in their cases peripheral nerve changes. Dubler also in 1884, as the results of an examination of two cases, concluded that the condition was primarily a perineuritis and that the changes in the ganglion were secondary.

Relationship of Herpes Zoster to Herpes Febrilis

We are now justified in defining herpes zoster as an acute infection, epidemic in its incidence and due to an as yet unknown specific virus, probably of the filterable type. The foci of its action are the posterior root ganglia, the nerve fibres originating from these ganglia, and the skin and mucous membrane

and other structures supplied by these nerve fibres. In the present state of our knowledge no dogmatic statement can be made as to which of these is first attacked. From the way in which the skin disturbance seems to be limited to the area of distribution of the affected nerve, it would seem probable that the primary lesion is in the nerve ganglion and that the implication of the skin is secondary to this. On the other hand, it remains to be shown from consideration of allied conditions, especially chicken-pox, that the virus may be purely dermatotropic in its incidence under certain conditions. In the central nervous system the nearest analogy is to be found in acute anterior poliomyelitis where there is an acute epidemic infection of the anterior horn cells by a virus of a filterable nature.

On the clinical side, we can lay down certain points which differentiate herpes zoster from herpes simplex or febrilis.

HERPES ZOSTER EPIDEMICA

HERPES SIMPLEX OR FEBRILIS

1. Follows distribution of nerve or nerves affected.

May do so, but not necessarily so. May affect both sides and may be quite irregular in distribution.

2. Always a preceding neuralgia. Arises independently of any preceding disease.

No preceding neuralgia. Follows on many infections of different kinds which produce a lowering of general tissue resistance. Also may result from certain mineral poisons, *e.g.*, arsenic and carbon monoxide.

3. Attacks true skin and leaves permanent scarring.

Only superficial dermis or mucous membrane affected. Vesicles heal up without leaving permanent scars.

4. One attack seems to confer nearly permanent immunity.

Tendency to frequent recurrences.

5. Duration: three to four weeks with frequently long continued diminution of sensibility of affected area.

Duration very variable, often very short (two to three days). No impairment of sensibility left.

In addition to these tabulated forms of differentiation it has been found that the sera or antigens from zoster patients do not give positive complement fixation tests against the antigens or sera from cases of herpes febrilis. Nor has it proved possible in the great majority of cases to produce any infection of the rabbit's cornea with material from zoster vesicles. The few cases in which

I have had the experiment made were completely negative. Lipschütz claims to have obtained positive results in infecting a rabbit's cornea with zoster virus, and Grüter in three cases produced a superficial punctate keratitis by inoculation from zoster vesicles. We must regard the question of the possibility of the infection of rabbits with pure zoster virus as, for the moment, unproven. The clinical symptoms and histological changes produced in the rabbit's corneae differ from those caused by infection with herpes virus, and the changes may only be the result of contamination. The common lesion of the cornea produced by herpes virus is a dendritic ulcer, that produced by a zoster virus is a rounded subepithelial grey infiltrate (*v.* Figs. 4 and 5). No immunity was conferred against subsequent infection with herpes virus (herpes virus confers a local immunity), whereas it is well known that zoster confers a very full degree of immunity against a subsequent attack of zoster.

The serum of zoster convalescents gives a positive complement fixation test with the antigen from fresh zoster vesicles, but the serum from herpes convalescents gives a negative test with the same antigen. Kundratitz found that experimental inoculations of children with herpes virus only produced a local reaction, but zoster virus produced a general exanthema. Herpes inoculations conferred no subsequent immunity to herpes nor to zoster. He found that he could get a herpes reaction after varicella in children, but not a zoster reaction.

On the other side of the question the opinion of Grüter and of Goodpasture must be quoted. Grüter considers that the virus is the same in the two conditions, and that the difference in the reactions is due to variations in the toxicity of the virus and in the resistance of the different tissues.

Teague and Goodpasture have produced in guinea-pigs and rabbits a condition much resembling zoster by using a very virulent strain of herpes febrilis virus with a strongly neurotropic tendency. With virus obtained from the posterior root ganglion thus affected, they have then produced a herpes corneae similar in nature to that produced by the original herpes virus. Goodpasture holds that there is no qualitative difference between the virus of herpes febrilis and herpes zoster, but only a quantitative difference in virulence.

Relationship of Zoster to Varicella

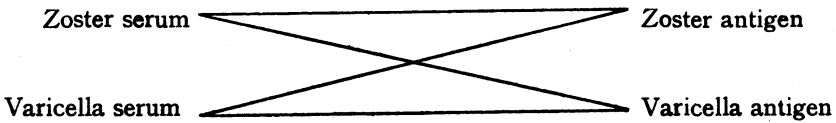
Bókay in 1892 was the first to call attention to the relationship existing between epidemics of chicken-pox and of herpes zoster, and subsequent clinical experience has confirmed the probability of a close connection between the two infections, if it has not established the identity of the virus. I may cite one or two striking examples that have come under my own notice. In one case a

grandmother was attacked by ordinary intercostal herpes zoster. Within three weeks, her son-in-law, living in the same house, got a sharp attack of ophthalmic zoster, and later, her grandson, a child of six years, got chicken-pox. In a second instance, a mother got an attack of ophthalmic herpes zoster, and on the same day her infant got chicken-pox. In the 1923 epidemic, one of the cases I admitted to St. Mary's Hospital with zoster ophthalmicus came out of a house where four children had chicken-pox. Similar experiences could be multiplied but while they point towards a relationship they do not amount to proof of identity of virus.

Serum tests with zoster and varicella have, on the whole, given positive results. Lange and Bókay, with a chicken-pox antigen and a zoster serum, got positive results. Netter and Urbain, on a much wider basis, also got positive results.

Their conclusions are :

1. In the serum of zoster and chicken-pox patients specific anti-bodies exist which can fix the homologous antigens.
2. The anti-bodies of zoster serum are identical with those of the chicken-pox serum, so that positive results are obtained with either kind of serum and either kind of antigen.



All these interchanges give positive results.

Kundratitz in his experiments with children found that when he had produced a zoster reaction in a young child that child was completely immune to chicken-pox, and could be kept in the same bed with a chicken-pox patient without becoming infected. Also he never succeeded in producing a zoster infection in children who had had chicken-pox. Using the zoster virus he produced either a slight local reaction or a generalized exanthem exactly like chicken-pox. This work of Kundratitz goes far to confirm the theory suggested by Cranston Low in the *Brit. Med. Jl.*, 1919. He considers that zoster and chicken-pox are identical viruses and only differ in their mode of attack. In chicken-pox they gain access to the system by the blood-stream and produce a generalized exanthem, while in zoster they gain access by lymphatics and produce a localized attack. The assumption that the nasopharyngeal mucous membrane afforded the most easy mode of entry for the virus would explain the frequency with which the Gasserian ganglion and the fifth nerve formed the focus of attack.

Cipolla suggests the possibility of two forms of epidemic zoster, one allied to chicken-pox, zoster *varicellosus*, and one allied to herpes, zoster *herpeticus*.

Further research is obviously necessary to elucidate these relationships and the relationship, on the one hand, to allied exanthemata, such as variola and the varioloid infections and vaccinia, and, on the other hand, to the simpler conditions such as molluscum contagiosum, contagious impetigo and phlyctenular conjunctivitis.

Summarizing these conditions, we find a chain of related lesions, commencing with conditions like recurrent corneal erosions, superficial punctate keratitis and herpes corneae with allied forms of herpes febrilis, linking up on the one hand with encephalitis herpetica and so with encephalitis lethargica and on the other hand with herpes zoster. Herpes zoster in its turn may be symptomatic when the Gasserian ganglion or posterior root ganglion becomes involved in some other lesion, inflammatory, traumatic or neoplastic, or it may be epidemic. The epidemic zoster is only very doubtfully related to simple herpes, but much more definitely linked up with varicella. It may, in its turn, also produce an encephalitis (zosterica) and varicella also may produce central nervous system disturbances. Varicella, in its turn, forms a connecting link with other analogous exanthemata, variola and varioloid diseases and vaccinia, and the latter also may produce a form of encephalitis allied to encephalitis lethargica.

II.—Neuropathic Keratitis

The condition known as neuropathic keratitis is one in which we find marked degenerative conditions developing in the cornea as the result of lesions affecting the fifth nerve, seemingly in any part of its course.

My experience of this condition is partly derived from cases of cerebral tumour involving the origin and roots of the fifth nerve and the gasserian ganglion, but principally from having seen a large number of cases of trigeminal neuralgia which have been treated either by extirpation of the ganglion, or by alcohol injections into it. But I would also note the great interest from a pathogenetic standpoint of the case shown by Lawford in 1907, where neuroparalytic keratitis occurred in a child with probably bilateral congenital paralysis of the ophthalmic division of the trigeminal.

The treatment of trigeminal neuralgia by alcohol injections into the Gasserian ganglion affords an opportunity of watching the development of the condition in the human subject.

One of the immediate results of an alcohol injection into the Gasserian ganglion is a marked flushing of the conjunctival vessels. This hyperaemic condition persists sometimes as long as eight or ten days, gradually diminishing in intensity. If during that period the eye is kept covered with a moist pad, carefully adjusted

over the closed lids, no further damage may follow. But despite this precaution, in a very definite proportion of cases, corneal changes set in within the first few days, often within twenty-four hours of the injection. The whole corneal surface becomes faintly stippled and hazy and the dessicated cornea begins to lose its surface epithelium, first in the centre of the cornea, but gradually spreading outwards until nearly the whole of the corneal epithelium becomes exfoliated, leaving only a small peripheral ring. The denuded surface is slightly opaque, and, if neglected, this opacity increases in density. Secondary infections may follow, resulting in corneal ulceration and sometimes in *ulcus serpens*, but apart from those the cornea may in course of time become quite opaque and look dried up on the surface. One of the most striking features about neuroparalytic keratitis is the rapidity with which the cornea clears up and resumes its transparency if the edges of the lids are rawed and the lids sewn together. Almost invariably within three days of sewing the lids together, the corneal epithelium has regenerated and the corneal transparency is restored. Only in cases where the condition has been allowed to pass on to ulceration and the deeper corneal tissues have been involved is there any permanent opacity left. As a general rule, if you can steer the patient through the first ten days following the injection, and the conjunctival flush has subsided, there is little risk of corneal trouble following. But this is not always the case. I have seen cases in which keratitis did not develop until a few months had elapsed. One case was an old gentleman from Brighton, who some two months after injection developed first iritis and then keratitis. Another case I can quote is Miss F., where the injections were done in May, 1920. It was followed by double vision due to sixth nerve paresis which soon cleared up. In August, 1920, she developed neuroparalytic keratitis, and Mr. Levy saw her for me and sewed the lids together. In that case there was an interval of fourteen weeks. Not only may a considerable interval elapse before the development of corneal trouble, but in a case where it has once occurred and the lids have been sewn together, it may recur immediately on breaking down the adhesions. In one of the earliest cases in which I had to sew the lids together, I tried to open up the eye again no fewer than four times and invariably within twenty-four hours the whole corneal surface had become opaque and the central epithelium had begun to exfoliate. In another early case, I broke down all the adhesions after an interval of six months. The old lady, unfortunately, got an attack of bronchitis the next day and was unable to turn up at the hospital again for some time. When I saw her again, the cornea was completely opaque and the surface quite dry. There had been no ulceration nor were there signs of any active

inflammation but the sight was lost beyond recovery. It is astonishing how small a band may prevent this. A band of adhesion under two millimetres in breadth, crossing the outer margin of the cornea seems to be all that one need leave. Mr. M., a patient of Dr. Buzzard's, had keratitis following alcohol injection and had his lids sewn together. Three months later, I cut through the adhesions from within outwards leaving a band at the outer margin of the cornea. The eye remained perfectly healthy and in another three months, at the urgent request of the patient, I cut through the final small band. Next day I had a wire from Mr. Adams at Oxford to tell me that Mr. M.'s cornea had become opaque and his eye was very flushed. I had to wire back and request Mr. Adams to sew the lids together again at once. I have seen this happen so frequently that I am now very chary of breaking down the last adhesion. It can at times be done with complete impunity as witness a case of a patient from Wolverhampton whose lids I sewed together at St. Mary's for neuro-paralytic keratitis. I sent her with a note to Mr. Cridland. I had evidently not been sufficiently explicit in my note as to leaving the small band of adhesion, and a month later he opened the eye completely and the last report of the case stated that no ill effects had resulted.

Before leaving this question of corneal complications I must note a much milder form sometimes seen in which the lesion more resembles superficial punctate keratitis or recurrent neuralgic keratitis with tiny pin-point stippling on the corneal surface.

I have seldom seen *ulcus serpens* developing after removal of the Gasserian ganglion or after its destruction by alcohol. I think this is mainly due to the promptness with which the cases have been dealt with and the lids sewn together. I have seen, however, several cases of its development where the ganglion or its origins or trunks have become involved in a basal growth and here again I have been struck with the rapidity with which even deep sloughy ulcers heal up as soon as the lids are sewn up. It demands a certain amount of courage to close up the lids over a deep sloughy-looking suppuration of the cornea which looks as if it were on the verge of passing into a panophthalmitis, but I think the results almost invariably justify the action, and after all, the only other resource is excision of the eye.

The cornea is the portion of the globe most predominantly affected in paralysis of the trigeminal, but it is not the only portion affected. From time to time, we may see cases of iritis, not only secondary to affections of the cornea, but preceding the corneal affection or at least arising independently of it. I have already referred to one such case in which the iritis preceded the keratitis and I have notes of two others in which iritis occurred.

Another feature I have noted in some cases is that the tension is definitely reduced and may remain so over long periods.

Lesions in any part of the course of the trigeminal can set up these changes. Many of the hypotheses that have been advanced to explain the condition start on the assumption that the main lesion must be in the Gasserian ganglion or infra-ganglionic. Though in all probability, the keratitis develops more rapidly in ganglionic and infra-ganglionic lesions, it undoubtedly occurs in supra-ganglionic lesions, and in lesions affecting the bulbo-spinal roots and their related nuclei. Some years ago I reported a case of Foville's syndrome, due to a deep-seated tuberculoma in the anterior part of the medulla. In this case, subsequently, a very severe neuropathic keratitis developed, and I had to sew the lids together to save the eye. Wilbrand and Saenger, in their analysis of 170 cases of trigeminal lesions, give 49 cases in which the root and nuclear region of the fifth were affected, and in 16 of these (approximately 33 per cent.) neuropathic keratitis developed. Out of the total of 170 cases, 64 developed keratitis (approximately 38 per cent.).

Pathogenesis of Neuropathic Keratitis

There are few subjects in the domain of ophthalmic neurology which present greater difficulties in providing even a moderately satisfactory explanation as to causation than neuropathic keratitis. Against every hypothesis advanced up to the present time, numerous objections can be raised. It may serve a useful purpose to try to state briefly various possibilities and then to review the arguments for and against them.

I shall put them in a series of questions :

(1) Are the changes in the eye mainly due to central causes, or mainly to peripheral causes or to a combination of the two?

(2) Does the ophthalmic division of the fifth, an afferent nerve, contain efferent trophic fibres, or is there such a thing as anti-dromic trophic impulses in an afferent nerve? If either of those possibilities exist, are the changes the result of irritation resulting in the development of abnormal trophic impulses, or are they due to withdrawal of the normal trophic impulses?

(3) Are the changes the result of interference with the normal vaso-motor impulses? If so, are they the result of the blocking of the passage of vaso-constrictor impulses from the sympathetic, or of irritation of vaso-dilator impulses, passing down as anti-dromic impulses in the sensory fibres?

(4) Are the changes due simply to the sensory loss depriving the eye of its normal protective impulses, and so rendering it more subject to the influence of minor traumatism?

(5) Is there a diminution in the normal ocular secretions, especially in the secretion of tears and a resulting abnormal desiccation of the eye surface, leading to desquamation of the corneal epithelium? Is there an alteration in the physiological properties of the ocular secretions, a diminution in the bacteriolytic property of the tears?

(6) Are the changes the result of the activity of a specific bacterium?

(7) Are the changes due to degenerative changes passing down the nerve and affecting the whole course of the nerve to its ultimate arborizations among the cells of the stratified corneal epithelium?

It is essential in the discussion of these problems to consider not only the phenomena of neuropathic keratitis, but also the conditions allied to it and especially herpes zoster ophthalmicus. I must take the risk of uttering a platitude and make the statement that neuropathic keratitis results from injury to or destruction of the ophthalmic division of the fifth in some part of its course, so there must be a central element in its causation, and secondly, that protecting the eye by sewing the lids together invariably results in preventing the development of the condition, or in the rapid cure of the condition if it has developed, which would seem to indicate almost equally definitely that there must be a peripheral element in its causation.

A third point is also worth remembering, and that is that iritis may develop in association with neuropathic keratitis or independently of it after lesion of the fifth, *e.g.*, from alcohol injections. It is unlikely that the iritis is the result of surface injuries, especially when it precedes the keratitis.

In herpes zoster the lesions are found in the whole distribution of the ophthalmic nerve. In neuropathic keratitis I do not remember ever to have seen any trophic skin lesion, even when the anaesthesia and analgesia were absolute. The destructive process has always been restricted to the eye itself, and nearly always mainly to the cornea. In herpes zoster I am becoming more and more convinced that superficial corneal lesions are relatively rare, and that the commoner corneal lesions consist of deeper corneal infiltrations. From careful watching of recent cases I feel sure that many of the earlier descriptions where corneal opacities left after an attack of herpes zoster have been ascribed to corneal vesicles during the attack are wrong. I have seen now a number of cases showing these small, faint corneal opacities in which there has not been, at any time, a trace of a corneal vesicle. In one case of herpes in St. Mary's Hospital we were able to watch the development of keratitis profunda with the typical deep striae, and simultaneously these faint nebulae appeared in more

superficial layers of the substantia propria, but at no time were there any superficial vesicles.

In herpes there is an acute inflammation of the ganglion, with obvious irritative effects exemplified in the central portion by the acute pain and in the peripheral portion by the hyperaemia, oedema, vesicle formation, and the other changes described. There is lowering and there may be temporary blocking of conduction in the nerve. In this respect it resembles the "glossy skin" described by Paget in 1864, and more fully in the same year by Weir Mitchell. In this condition the marked trophic changes are accompanied by an equally marked hyperalgesia. Weir Mitchell remarks: "It was somewhat rare to see any case of glossy skin, especially with causalgia, unattended with vesicles." Head and Sherren give an illustrative case where the condition resulted from a gunshot wound, injuring the ulnar nerve. I mention it specially because of the light it throws on such cases. "On January 30, 1902, the ulnar nerve was dissected at the site of the injury, the two ends freshened and united by a graft. On February 4, the glossy appearance of the skin and all hyperalgesia had disappeared, the sensory state of the hand being that which follows complete division of the ulnar nerve."

During the course of the prolonged and classical experiment which Head made on himself, and which resulted in such a change in all our knowledge of sensation, a small trophic ulcer developed in the skin on the back of the metacarpus of the thumb. This remained in a more or less sluggish condition from July to September, 1903, and only began to heal as the protopathic sensibility became restored, but healed rapidly as soon as the skin in its neighbourhood became sensitive to pin pricks.

In herpes zoster there is an acute irritative lesion in the course of a sensory nerve producing changes of this type in all the area of its distribution.

In neuropathic keratitis primarily, at least, it is the superficial epithelium only that desquamates, and if no secondary infection occurs it may regenerate without leaving the faintest trace of opacity. If it passes to a stage in which vascularization takes place on healing the vessels are all of the superficial arborescent pannus type. In neuropathic keratitis the rest of the distribution of the nerve shows no sign of disturbance resembling the skin lesion of herpes zoster. Not only is this so but I have frequently noticed the rapidity with which the raw edges of the lids form a firm union when I have had to sew the lids together in such cases.

The hypotheses of the pathogenesis of neuropathic keratitis can be divided into two main groups: (1) Those laying the main stress on the central (nervous) factors in the causation; and

(2) those which regard the peripheral (surface) factors as of greater importance. In the consideration of the first group of hypotheses we find that some authorities base their theories on the existence of trophic fibres, while others regard the vaso-motor changes as of fundamental importance.

The Trophic Hypothesis

Magendie, in 1824, was the first to call attention to the changes in the cornea resulting from cutting the trigeminal nerve. He concluded that the trigeminal nerve had a direct influence on the nutrition of the cornea. On the original experiments of Magendie on the corneal changes after section of the fifth nerve, most of the elaborate superstructure of the existence of trophic nerve fibres generally has been based. Magendie and Longet concluded that the trophic fibres must enter the Gasserian ganglion from the sympathetic, since cutting the main root of the nerve above the ganglion did not cause neuropathic keratitis, but Claude Bernard showed that this was not correct, but that the results of section were only much slower in showing themselves when the section was supra-ganglionic. Gaule, in 1891, suggested that the corneal changes resulting from supra-ganglionic and infra-ganglionic section might be due to different causes. The trophic influences lie in the cells of the ganglion. These are affected in infra-ganglionic section and rapid corneal changes result from such a lesion. In supra-ganglionic section he considered that the corneal changes, much later in their development, result only from inflammations caused by the loss of the normal protective impulses. The very rapid early changes which Gaule described in the cornea can, however, be simulated by simple drying of the cornea (Hanau, Ollendorf).

According to Charcot the trophic disturbances following on nerve lesions were not the result of loss of normal trophic impulses but of inflammatory irritation. The removal or absence of any activity in the nervous system has no direct immediate influence on the nutrition of the tissues, but disordered activity, irritation of nerve fibres or nerve centres, may produce the most varied trophic disturbances.

Samuel, in the article on trophoneurosis, published in Eulenberg's Encyclopaedia in 1860, stated his view that there existed both centrifugal and centripetal fibres concerned in the regulation of the nutrition of tissue cells, and that interference with these might result in either atrophy, hypertrophy or dystrophy of the tissue concerned. The eye lesions result from a diminished resistance on the part of the tissues to small injuries which would not affect the normal eye. This hypothesis of Samuel's introduces

the peripheral factor of superficial traumatism as well as the central element of nerve injury. In 1862, Büttner showed that very slight protection of the eye greatly diminished the chances of inflammations developing in it. In his opinion the loss of sensory impulses was of no importance, and the disturbance of vaso-motor influences could also be excluded as a cause. Büttner tried to prove by partial section that the neurotrophic fibres and the sensory fibres ran separate courses in the nerve stem, and Merkel further suggested that the mesencephalic root was concerned in the reception of the trophic fibres. Meissner also found that in partial section of the nerve, neuropathic keratitis might occur with undiminished sensibility.

Of course, the difficulty at once arises in the interpretation of these cases of partial section of the nerve, that, though nerve conduction may remain, and there may be some retained sensibility we cannot exclude the probability of nerve irritation. The work of Head and Sherren, which I have already referred to, shows the importance of this point in regard to trophic ulcers. Further, in the time of Büttner and Meissner, the investigation of peripheral sensibility was only in a crude state and the more refined methods of the present day would probably have shown that certain forms of sensibility had been lost. Head's classical experiment showed the tendency of a trophic ulcer to heal rapidly as soon as protopathic sensibility was restored in the surrounding skin.

Clinically, there are good arguments in favour of this combined theory of a combination of trophic and traumatic factors. There is a much greater likelihood of neuropathic keratitis developing in a case where the facial nerve is also involved, with resulting lagophthalmus. On the other hand, when ptosis develops with a trigeminal lesion, the tendency to keratitis is greatly diminished, though even with complete ptosis, keratitis has occasionally developed.

An argument against the theory of nerve irritation is the long interval that may elapse before signs of keratitis develop. I have mentioned two cases, one with an interval of two months, and the other with an interval of four months. The first of these cases also affords an argument against the hypothesis of surface injury, since the first sign of ocular disturbance was iritis, and the keratitis developed subsequently. Also in the second case, after the keratitis cleared up, there was a much later attack of iritis without recurrence of the keratitis. In yet a third case there was neuropathic keratitis following within three days of an alcohol injection. This cleared up at once on sewing the lids together, but some weeks later a mild iritis developed which resulted in a fairly broad posterior synechia.

Krause, in his earlier work, seems to have been particularly fortunate in avoiding neuropathic keratitis after extirpation of the Gasserian ganglion. His early conclusion was that complete removal of all trigeminal influence led to no disturbance and even where the anaesthesia was complete no special protection was required to guard against keratitis.

The Vaso-motor theories

Schiff, in 1867, first suggested that the changes might be due to vaso-motor changes. His first idea was that paralysis of the vaso-motor nerves led to vaso-dilation, congestion, and subsequent inflammation. He later on modified his hypothesis to the extent of allowing that the congestive condition rendered the eye more susceptible to surface irritation.

Claude Bernard's opinion was the exact opposite of Schiff's. He thought that paralysis of the vaso-dilators led to an unbalanced activity of vaso-constrictors, and consequently an anaemia.

Spalitta's experiments, published in 1894, had for their object the elucidation of this problem. He found that extirpation of the Gasserian ganglion in dogs produced exophthalmos, a preliminary rise followed by a marked lowering of intraocular tension, corneal disturbance going on to destruction, and secondary conjunctivitis. If, however, the superior cervical ganglion was removed before extirpation of the Gasserian ganglion, there was retraction of the globe, the tension remained normal, or was slightly raised, and if corneal symptoms followed, they were only slight and evanescent. His conclusion from these experiments bore out Claude Bernard's hypothesis that destruction of the Gasserian ganglion gave rise to strong vaso-constriction, especially in the peri-corneal region leading to corneal necrosis. He further was of opinion that section of the Gasserian ganglion had in addition an irritative effect.

Ollendorf, in the course of an article on the part played by micro-organisms in the causation of neuropathic keratitis, refers to evidence of vascular disturbance produced by section of the fifth; the increased proteid content in the aqueous; the congestion of the vessels of the iris and conjunctiva which follows rapidly on the section; and the subsequent diminution of the intraocular pressure.

Krause, on the other hand, was never able to ascertain any definite change in the pupil or in the vessels of the eye after extirpation of the Gasserian ganglion in men.

Schiff, in his first paper, advanced a theory of neuropathic keratitis based on pure vaso-motor disturbance, but later (in 1876) modified it by the suggestion that the hyperaemia resulting from

loss of vaso-constrictor impulses made the eye more susceptible to the influence of slight external injuries which converted the simple congestive hyperaemia into an inflammatory hyperaemia. The hyperaemic condition he considered lasted from ten to twelve days. Personally, I have put it at from eight to ten days, and I think a patient is moderately safe at the end of ten days.

Seydel has gone much further than Schiff and taken up what I think is quite an indefensible position in stating that neuropathic keratitis can only occur when the sympathetic is also affected. Against this are the numerous cases arising when the lesion is supra-ganglionic and even intra-cerebral.

The second big group of theories regard the condition as due, in the main, to surface causes either (1) traumatisms; (2) drying; or (3) microbic infections.

The Traumatic Hypothesis

Snellen, in 1857, from the fact that sewing the lids together was so effective in preventing the development of neuropathic keratitis, inferred that simple surface traumatism was the important factor. Senftleben thought that a small traumatism caused a small area of necrosis, which, in its turn, acted as an irritant and set up an advancing inflammatory reaction from the corneal margin to the primary necrotic area.

von Gudden, in 1884, dealing with the general question of trophic ulcers, was opposed to the idea of trophic nerve influence in neuropathic keratitis and regarded the condition as of superficial and more especially traumatic origin. All his experience tended to show that so long as the eye was protected, whatever the method of protection adopted might be, the cornea remained clear.

There are many difficulties in accepting this theory of traumatism acting on an insensitive eye. For myself, I find it difficult to understand why a small band of lid adhesion not broader than 2 mm. and situated to the outer margin of the cornea should suffice to prevent the development or recurrence of corneal trouble, and yet when one slits through this final small band, the cornea often breaks down within twenty-four hours. The insensitiveness is just the same at both times, and the area of exposed cornea is very little greater.

The Evaporation Hypothesis

The first suggestion that the corneal condition arose from drying of the cornea was made by Feuer, in 1877. His hypothesis is that owing to a diminished sensibility of the cornea there is a diminution

in the number of blinking movements on the affected side, and a consequent greater time for evaporation from the surface resulting in drying and consequent necrosis of the exposed cornea. This necrotic tissue acts as an irritant and causes the subsequent inflammation of the cornea. A diminution in the secretion of tears further augments this xerotic tendency.

von Hippel strongly favoured this theory, and Ollendorf in the paper already mentioned, partially favours this hypothesis.

His conclusions, briefly, are as follow :

1. In animals, after section of the trigeminus, if no protection is given to the eye against external injury, the neuropathic keratitis is due to infected injuries, the infecting agent being most frequently the staphylococcus.

2. When protected from injury the cause of the corneal inflammation in dogs is the drying of the exposed part of the cornea.

3. In man the results are less constant than in dogs for various reasons, *e.g.*, in man the blinking movements are common to the two eyes and so irritation of the sound eye causes blinking in the affected eye, but the blinking is less frequent, and also there is a diminished tear secretion. He considers on the whole that in man most cases result from infection after mechanical injury.

In opposition to the evaporation theory Senftleben in his experiments fixed the dogs in such a way that they could not injure the eyes, which were not in any way protected against evaporation. Kept in this way no keratitis developed during periods of fourteen days or longer, but when the head was freed the cornea became affected in from six to eight days.

Verhoeff, in a recent paper inclines to the theory of diminished lacrymal secretion. He thinks that in some cases the operation injures the great superficial petrosal, and as a result the secretion of tears is partially inhibited and drying of the cornea results. The corneal changes in his opinion are exactly the same as are those produced in drying of the cornea from other causes, and the cases in which no neuropathic keratitis occurs after operation are cases in which the seventh nerve and its branches have escaped injury.

It must, however, be pointed out that this suggestion of Verhoeff is based on the assumption that the seventh nerve is the main secretory nerve of the lacrymal gland. Krause, basing his opinion mainly on the work of Goldzieher, thought that the diminished tear secretion observed in seven of his cases of gasserectomy resulted from operative injury to the great superficial petrosal, and the existence of such secretory fibres in the facial is supported by the work of Parsons. But that it is the sole or even the main secretory nerve is more than doubtful since in complete paralysis

of one facial involving the uvula and soft palate, tear secretion remained quite undiminished on the affected side. Wilbrand and Saenger suggest that only emotional weeping is innervated from the seventh nerve and not reflex secretion of tears. Reflex tear secretion is dependent on the fifth nerve, and it is the reflex tear secretion not the emotional tear secretion which is mainly responsible for maintaining the surface moisture of the eye. Hartmann, on the other hand, takes the reverse view that reflex weeping is innervated by the facial and emotional by the trigeminal. There is no definite evidence in cases of alcohol injection in which neuropathic keratitis develops of any injury to the seventh nerve, though in operative cases it is quite easy to see that injury may occur to the great superficial petrosal branch, or to the Vidian after the great deep petrosal has joined it.

Clinically, the fact that in all the alcohol injection cases that I see the lids are kept closed and protected against evaporation by moist pads or by strapping, seems to be a strong argument against the xerotic theory. Again, though in many cases ptosis protects the eye, undoubted cases have been recorded in which keratitis develops despite complete ptosis. Further, the main assumptions, on which this xerotic hypothesis is based, have never been proved. First, we do not know that the number of blinking movements is diminished by the insensibility of one eye, nor has it been proved that the secretion of tears is diminished.

The Bacterial Infection Hypothesis

Eberth, in 1871, suggested that the drying of the eyes gave infecting agents a chance to develop and set up inflammation. Balogh's idea was that slight traumatism to the insensitive eye gave a point of entry of infection. Turner, in the course of his work on the fifth nerve in association with Ferrier, thought that in the cases where neuropathic keratitis developed, it was due to unintentional injuries to the cornea becoming subsequently infected. Morrison Davies and Hall in 1908 described a bacillus which they found in all their cases of neuropathic keratitis, and they regarded the presence of this bacillus as one of the essential factors in the production of the keratitis. The bacillus in most of its characteristics closely resembles bacillus xerosis and others of the pseudo-diphtheritic strains, so that it is open to the same doubt as to whether it is really pathogenic or only a saprophyte growing in greater profusion owing to the changed conditions of the eyes. The rapidity with which the condition clears up when the lids are stitched together forces them to admit that there must be some third factor besides the interference with the Gasserian ganglion, and the presence of the bacillus α . The fact

of its constant presence when keratitis develops does not necessarily prove that it is pathogenic, but only that the conditions are favourable for the growth of this particular saprophyte, just as in xerosis conjunctivae where the presence of large quantities of the xerosis bacillus is not the cause of the disease, but the result of the change in the tissues allowing the free development of what is a fairly frequent saprophyte in the conjunctival sac.

The last hypothesis which I shall mention may I think legitimately be ascribed to Sir Wm. Gowers. He lays stress on the continuity of nervous structure from the ganglion cell from which the nerve fibre arises to its ultimate distribution in the tissues in the periphery, so that we must contemplate the possibility of a degeneration in the terminal fibrils distributed as arborescences among the cells of the stratified corneal epithelium, and this degeneration actually spreads into the cells themselves, and produces necrosis. On this hypothesis there is no need to consider the question of surface drying or surface injury. It also will help to explain the iris changes. But it does not explain the rapid regeneration of epithelium resulting from sewing the lids together.

All the hypotheses advanced so far in explanation of neuropathic keratitis seem to be in some one or other respect unsatisfactory, and there always seem to be as many arguments against them as in their favour. It forms one of the many fields in which careful and painstaking research might give a clearer view of the subject than is possible at the present time.

REFERENCES

Wilbrand and Saenger.—Die Neurologie des Auges. Vol. II gives a full bibliography up to 1901.

Those interested will find a very full list of articles on the modern work on "Herpes," etc., in Doerr's articles in the *Zentralbl. f. die gesamt. Ophthal.*, Vols. XIV and XV.

Later references to the subject of Neuropathic Keratitis will be found in Hartmann's book.

1. Arnstein.—"Herpes Zoster und Innere Erkrankungen," *Wien. Arch. f. innere Med.*, Vol. IV, 1922.
2. Balogh.—"Sphärobacterien in der entzündeten Hornhaut" *Centralbl. f. med. Wissensch.*, No. 6, p. 99, 1876.
3. Bernard, Claude.—"Leçons sur la physiologie et la pathologie du système nerveux," Vol. II, Paris, 1858.
4. Bokay.—*Magyar Orvosi Archivum*, November 3, 1892.
5. Bowman, Sir Wm.—*Roy. Lond. Ophthal. Hosp. Repts.*, Vol. VI.
6. Büchner.—*Zeitschr. f. ration. med.*, 3 Reihe, Vol. XV, p. 254, 1862.
7. Cajal, Ramon Y.—"Histologie du syst. nerv. de l'homme et des vertébrés," 1909.
8. Charcot.—"Leçons sur les Maladies du système nerveux," Vol. I.
9. Cipolla.—*Ann. di Clin. med. e di med. speriment.*, Vol. XIII, p. 175, 1923.
10. Cohn.—"Ueber den Herpes Zoster Ophthalmicus." *Arch. f. Augenheilk.*, Vol. XXXIX.

11. **Curschmann and Eisenlohr.**—*Deutsch. Arch. f. Klin. Med.*, Vol. XXXIV, p. 409.
12. **Daguenet.**—"Zona ophtalm. avec nevr. opt. du côté corresp." *Recueil d'Ophtal.*, April, 1877.
13. **Davies, Morrison**—"The Functions of the Trigeminal Nerve." *Brain*, Vol. XXX, 1907.
14. **Davies, Morrison, and Hall.**—"The Bacteriological Aspects of the Problem of Neuropathic Keratitis." *Brit. Med. J.*, January 11, 1908.
15. **Doerr and Vochting.**—"Études sur le virus de l'Herpes fébrile." *Rev. gén. d'Ophtal.*, Vol. XXXIV, p. 409.
16. **Ibid.**—p. 281.
17. **Doerr.**—"Ergebnisse der neueren experim. Forsch. ub. d. Aetiol. des Herp. simp. und des Zoster." *Zentralbl. f. die gesamt. Ophtal. und ihre Grenzgebiete*, Vol. XIV, pp. 705, 833, Vol. XV, pp. 313, 537. A very full review of the modern work on the forms of Herpes.
18. **Doesschate, G. ten.**—Meeting of the Netherlands Ophthalmological Society, December, 1918.
19. **Douglas.**—*Brit. Med. J.*, April 13, 1895.
20. **Dubler.**—*Virchow's Arch.*, Vol. XCVI, p. 195, 1884.
21. **Eberth.**—*Centralbl. f. Med. Wissensch.*, No. 11, 1871.
22. **Feuer.**—*Wiener Med. Presse*, Nos. 43 and 45, 1877.
23. **Goldzieher.**—"Beitrag zur Physiologie der Thränen Secretion." *Arch. f. Augenheilk.*, Vol. XXVIII, p. 9, 1893.
24. **Gaule.**—*Centralbl. f. Physiol.*, Vol. V., Nos. 13 and 16, 1891.
25. **Goodpasture.**—*Amer. Jl. Pathol.*, Vol. I, pp. 1, 11, 29 and 47, 1925.
26. **Goodpasture and Teague.**—*Jl. Med. Res.*, Vol. XLIV, p. 121.
27. **Ibid.**—p. 139, 1923.
28. **Gould.**—"The Polyclinic," 1888.
29. **Gowers, Sir Wm.**—Manual of Diseases of the Nervous System.
30. **Grüter, W.**—"Exper. und klin. Üntersuch. über den sogenannt. Herpes Corneæ." *Ber. der Deutsch. Ophtl. Ges.*, Vol. XLII, 1920, p. 162.
31. **Idem.**—Vol. XLIII, p. 227, 1922.
32. **Idem.**—"Zur Aetiologie der Impetigo contagiosa und anderen herpetischer Erkrankungen." *Ber. der Deutsch. Ophtl. Ges.*, Vol. XLIV, p. 220, 1924.
33. **Idem.**—*Munch. Med. Wochenschr.* p. 1058, 1924.
34. **Idem.**—"Das Rezidiv bei den herpetischen Erkrankungen der Hornhaut." *Ber. der Deutsch. Ophtl. Ges.*, Vol. XLV, pp. 104-107, 1925.
35. **Hartmann.**—"La neurotomie rétro-gassérienne," Paris, 1924.
36. **Haltenhoff.**—*Ann. d'Ocul.*, Vol. CIX, p. 201, 1893.
37. **Hanau.**—*Zeitschr. f. Biologie*, 1897.
38. **Head and Campbell.**—"The Pathology of Herpes Zoster." *Brain*, p. 353, 1900.
39. **Head and Sherren.**—"Injury to the Peripheral Nerves in Man." *Brain*, Vol. XXVIII, p. 262.
40. **Horner.**—*Klin. Monatsbl. f. Augenheilk.*, p. 325, 1871.
41. **Hulke.**—*Roy. Lond. Ophtal. Hosp. Repts.*, Vol. VI.
42. **Hutchinson, Jon.**—*Roy. Lond. Ophtal. Hosp. Repts.*, Vol. V, p. 191, 1866. Vol. VI., p. 48.
43. **Kidd, Leonard.**—"The Mesencephalic Fifth Root. The dorsal vago-pharyngeal nucleus and the question of an endo-neural afferent ganglionic system." *Review of Neurol. and Psych.*, Oct. and Nov., 1910.
44. **Krause.**—*Die Neuralgie des Trigeminus*, Leipzig, 1896.
45. **Kundratitz.**—*Verhand. d. Ges. deutsch Naturforsch u. Aerzte*, Innsbruck, 1924. Also communication to Doerr referred to in article in *Zentralbl.*, q.v.
46. **Lawford, J. B.**—"Neuropathic Keratitis in a child with bilateral congenital paralysis of opht. div. of Trigem." *Trans. Ophtal. Soc. U.K.*, 1907.
47. **Levaditi, C.**—"Ectodermoses Neurotropes." Paris, Masson et Cie., 1922.
48. **Levaditi and Harvier** and other pupils of Levaditi.—Numerous papers in *Ann. de l'Inst. Pasteur, Comptes rendus des séances de la Soc. de Biol.* and *Comptes rendus de l'Acad. des Sciences*, 1920-1925.

49. **Lipschütz.**—"Über Chlamydozoa-Strongyloplasmen, IV Über das Vorkommen von Zelleinschlüssen beim. idiop. Herp. Zost." *Wien Klin. Wochenschr.* Jg. 33, No. 38, p. 836.
50. **Low, Cranston.**—*Brit. Med. Jl.*, 1919.
51. **Loewenstein.**—"Neuere Ergebnisse der Herpesforschung." *Ber. der Deutsch. Ophth. Ges.*, Vol. XLII, p. 167, 1920.
52. **Magendie.**—*Jl. de Physiol.*, experiment. et pathol., Vol. IV, p. 176, 1824.
53. **Marchesani.**—"Neues zur symp. oph. mit besond. Berücksicht der Bedeut. des Herpesvirus." *Ber. d. deutsch. Ophth. Ges.*, Vol. XLV, p. 107, 1925.
54. **Marinesco and Draganesco.**—*Rev. neurol.*, Vol. XXX., p. 30, 1923.
55. **Idem.**—Comptes rendus des séances de la Soc. de Biol., Vol. LXXXVIII, p. 894, 1923.
56. **Idem.**—Ann. de l'Inst. Pasteur, Vol. XXXVII, p. 753, 1923.
57. **May and Horsley.**—"The Mesencephalic Root of the Fifth Nerve." *Brain*, Vol. XXXIII, p. 175.
58. **Meissner.**—*Zeitschr. f. ration. Med.* 3 Reihe, Vol. XXIX.
59. **Merkel.**—*Centralbl. f. d. med. Wissensch.*, No. 5, 1874.
60. **Mitchell, Weir.**—"Injuries of Nerves and their Consequences." Philadelphia, 1872.
61. **Netter and Urbain.**—Comptes Rendus des séances de la Soc. de Biol., Vol. XC, pp. 189, 461 and 997, 1924.
62. **Ollendorf.**—*Arch. f. Ophthal.*, Vol. XLIX, p. 445, 1900.
63. **Orr and Rows.**—*Brain*, Vol. XXXVI, p. 271.
64. **Parsons, J. Herbert.**—The Nerve Supply of the Lacrymal Gland. Roy. Lond. Ophthal. Hosp. Repts., Vol. XV, Pt. II.
65. **Pitres and Vaillard.**—*Arch. de Neurol.*, Vol. V, p. 191, 1883.
- 65a. **Rollet.**—*L'Iritis Zostérienne*, Soc. Franç. d'Opht., p. 442, 1925.
66. **Samuel.**—"Tropho-neuroses." *Eulenberg's Encyclopaedia*, 1860.
67. **Schiff.**—*Zeitschr. f. ration. Med.*, 3rd series, 1867.
68. **Idem.**—*Arch. des Science physiq. et natur.*, 1886.
69. **Senftleben.**—"Ueber die Ursachen und das Wesen der nach der durch Schneidung des Trigemini aufbietenden Hornhautaffection." *Virchow's Arch.*, Vol. LXV, p. 69.
70. **Seydel.**—*Arch. f. Ophthal.*, Vol. XLVIII, p. 142.
71. **Snellen.**—*Holländ Beiträg für Natur u. Heilkunde*, 1857.
72. **Spalitta.**—*Arch. di Ottal.*, Vol. II, p. 37, 1894.
73. **Sulzer.**—*Ann. d'Ocul.*, Vol. CXIX, p. 401, 1898.
74. **Sunde.**—*Deutsch. med. Wochenschr.*, No. 18, 1913.
75. **Turner.**—*Brit. Med. Jl.*, Nov. 23, 1895.
76. **Veasey, Clarence.**—*Amer. Jl. of Ophth.* 1919.
77. **Ibid.**—June, 1919.
78. **Verhoeff.**—"The cause of keratitis after Gasserian ganglion operations." *Amer. Jl. of Ophthal.*, Vol. VIII, p. 273, 1925.
79. **Vogel.**—Ueber Augenmuskellähmungen bei Herpes Zoster Ophth., Inaug. Dissert., Leipzig, 1912.
80. **von Bärensprung.**—*Charité-Annalen*, Vol. IX, pt. 2, and Vol. XI, 1861.
81. **von Gudden.**—*Neurol. Central.*, III, p. 474, 1884.
82. **von Hippel.**—*Arch. f. Ophthal.*, Vol. XXXV.
83. **Wangler.**—Inaugural dissertation at Zürich, 1889.
84. **Wilbrand and Saenger.**—*Die Neurologie des Auges*, Vol. II.
85. **Winkler.**—*Opera Omnia*, Vol. VII. French Edition, Haarlem, 1921.
86. **Wyss.**—Path. exam. of case of herpes, 1871.