



## Dexmedetomidine for sedation in pediatric patients who received more than 20 sessions of radiation therapy -two cases report-

Sun-Key Kim<sup>1</sup>, Myung-Hee Song<sup>1</sup>, Il-Jung Lee<sup>2</sup>, Jae-Hyuk Lee<sup>2</sup>, and In-Cheol Choi<sup>1</sup>

Department of Anesthesiology and Pain Medicine, <sup>1</sup>Asan Medical Center, University of Ulsan College of Medicine, <sup>2</sup>Seoul Medical Center, Seoul, Korea

Dexmedetomidine is a highly selective  $\alpha_2$ -adrenoceptor agonist that demonstrates anxiolytic and analgesic properties without inducing respiratory compromise, which makes it a suitable agent for procedural sedation and imaging studies. In our current case reports, intravenous dexmedetomidine infusion was used to provide sedation to 2 pediatric patients over more than 20 sessions of radiation therapy. On both occasions, dexmedetomidine provided adequate sedation without respiratory depression. However, the required dosage increased with repeated radiation therapy sessions.

**Key Words:** Dexmedetomidine, Pediatrics, Radiotherapy.

Dexmedetomidine (Precedex<sup>®</sup>, Hospira, Lake Forest, IL, USA) is a highly selective  $\alpha_2$ -adrenoceptor agonist that was approved by the US Food and Drug Administration in 1999 as a sedative for adults whose airways are intubated in the intensive care unit, and in 2008 it was approved as a sedative for surgery and other procedures in adults without intubated airways [1]. Dexmedetomidine is currently not approved for use in children

in any country. Although a few reports are available on the use of dexmedetomidine in infants and children, only a few studies have reported its use in pediatric radiation therapy. Because the framing and subsequent radiation therapy requires immobilization, pediatric patients usually require sedation or general anesthesia. Here, we report our experiences of using dexmedetomidine as the primary sedative agent for repeated radiation therapy sessions in 2 pediatric patients.

### Case Reports

#### Case 1

A 41-month-old boy (weight = 21 kg) with brain stem glioma was scheduled to undergo 23 sessions of teleradiotherapy using electrons under sedation. He presented with right leg and hand weakness and difficulty swallowing. Twelve days earlier, he underwent an endoscopic biopsy under general anesthesia with volatile anesthetics. For radiotherapy, the neurosurgical doctors attempted sedation with midazolam (total 4.8 mg) and ketamine

Corresponding author: In-Cheol Choi, M.D., Ph.D.  
Department of Anesthesiology and Pain Medicine, Asan Medical Center, University of Ulsan College of Medicine, 88, Olympic-ro 43-gil, Songpa-gu, Seoul 05505, Korea  
Tel: 82-2-3010-3862, Fax: 82-2-2045-4076  
Email: icchoi@amc.seoul.kr  
ORCID: <http://orcid.org/0000-0002-7386-5043>

Received: February 25, 2016.  
Revised: March 20, 2016 (1st); May 11, 2016 (2nd).  
Accepted: May 27, 2016.

Korean J Anesthesiol 2016 December 69(6): 627-631  
<https://doi.org/10.4097/kjae.2016.69.6.627>

© This is an open-access article distributed under the terms of the Creative Commons Attribution Non-Commercial License (<http://creativecommons.org/licenses/by-nc/4.0/>), which permits unrestricted non-commercial use, distribution, and reproduction in any medium, provided the original work is properly cited.

Copyright © the Korean Society of Anesthesiologists, 2016

Online access in <http://ekja.org>

(total 40 mg), but failed. At first, sedation with propofol infusion was planned. Ramsay Sedation scores (RSS) were used to guide sedation, and a minimum of RSS 4 was the target [2] as the patient needed immobilization during the therapy. The patient entered the radiation therapy unit, and standard monitoring was performed, which included electrocardiography, noninvasive blood pressure monitoring, end-tidal carbon dioxide (ETCO<sub>2</sub>) monitoring, and pulse oxymetry. The patient's head was fixed on the radiation table, and an individually designed mesh-plastic mask was attached over the face. Monitoring was conducted using a video camera. The patient was irradiated at 2 Gy/d in order to receive a total of 50 Gy/25 fractions, and each treatment lasted 10 minutes.

For the first 3 sessions, propofol was used as the sedative, which was administered at a rate of 150–250 µg/kg/min, and the total amount of infused propofol increased every day. On the first day, the patient received a total of 100 mg propofol, and 150 mg of propofol was used the next day as the patient showed agitation. On the third day, the total amount of infused propofol was 170 mg, and 1 mg of supplemental midazolam was administered to treat agitation. It was harder to maintain spontaneous breathing as the propofol dose increased. Therefore, the use of dexmedetomidine was planned for the fourth session.

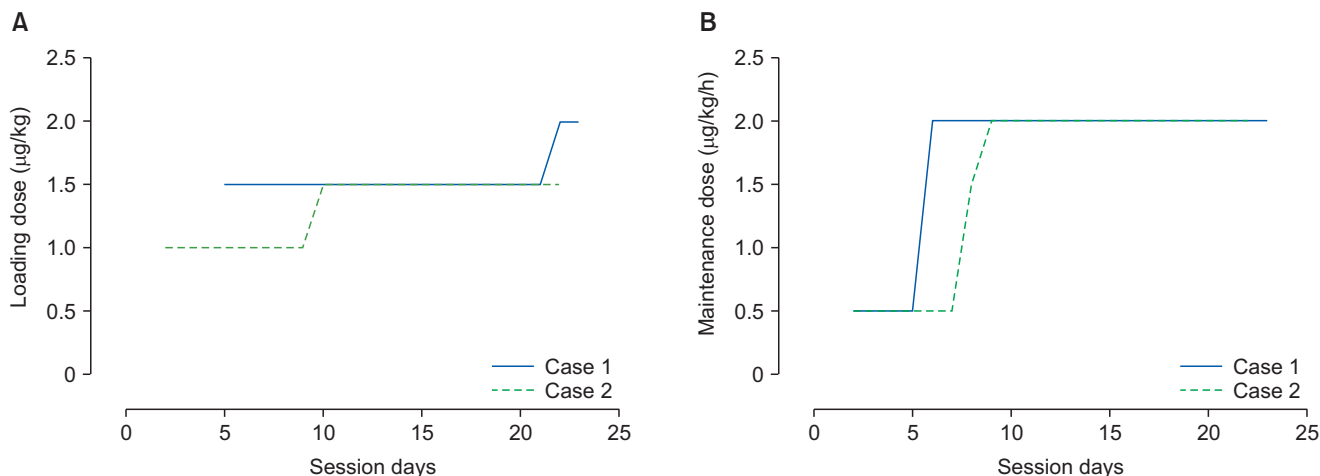
Before the fourth session, informed consent for the off label use of dexmedetomidine was obtained from the patient's parents. For the fourth session, we attempted to administer 3 µg/kg intramuscular dexmedetomidine, but the patient became irritable soon after positioning the facial mesh-plastic mask and intravenous (IV) propofol was administered as a rescue sedative (2 mg/kg bolus and 200 µg/kg/min infusion). IV dexmedetomidine was used as the sole sedative agent in the other 17 procedures. An initial loading dose of 1.5 µg/kg IV dexmedetomidine was

administered over 10 minutes, followed by a maintenance dose of 0.5–1.5 µg/kg/h during the fourth through sixth sessions. From the 7th through to the 21st session, a higher infusion rate was used (2 µg/kg/h) after administering the loading dose of 1.5 µg/kg for 10 minutes. On the days of the 22nd and 23rd sessions, the loading dose was increased to 2 µg/kg and was followed by an infusion of 2 µg/kg/h because the RSS varied from 1 to 4. Despite this higher rate, it was necessary to administer 2 mg midazolam to achieve adequate sedation. These doses were administered by an anesthesiologist. Because the patient did not have a chemoport, an intravenous catheter was inserted every 3 days. The changing doses of loading and maintenance were depicted in Fig. 1.

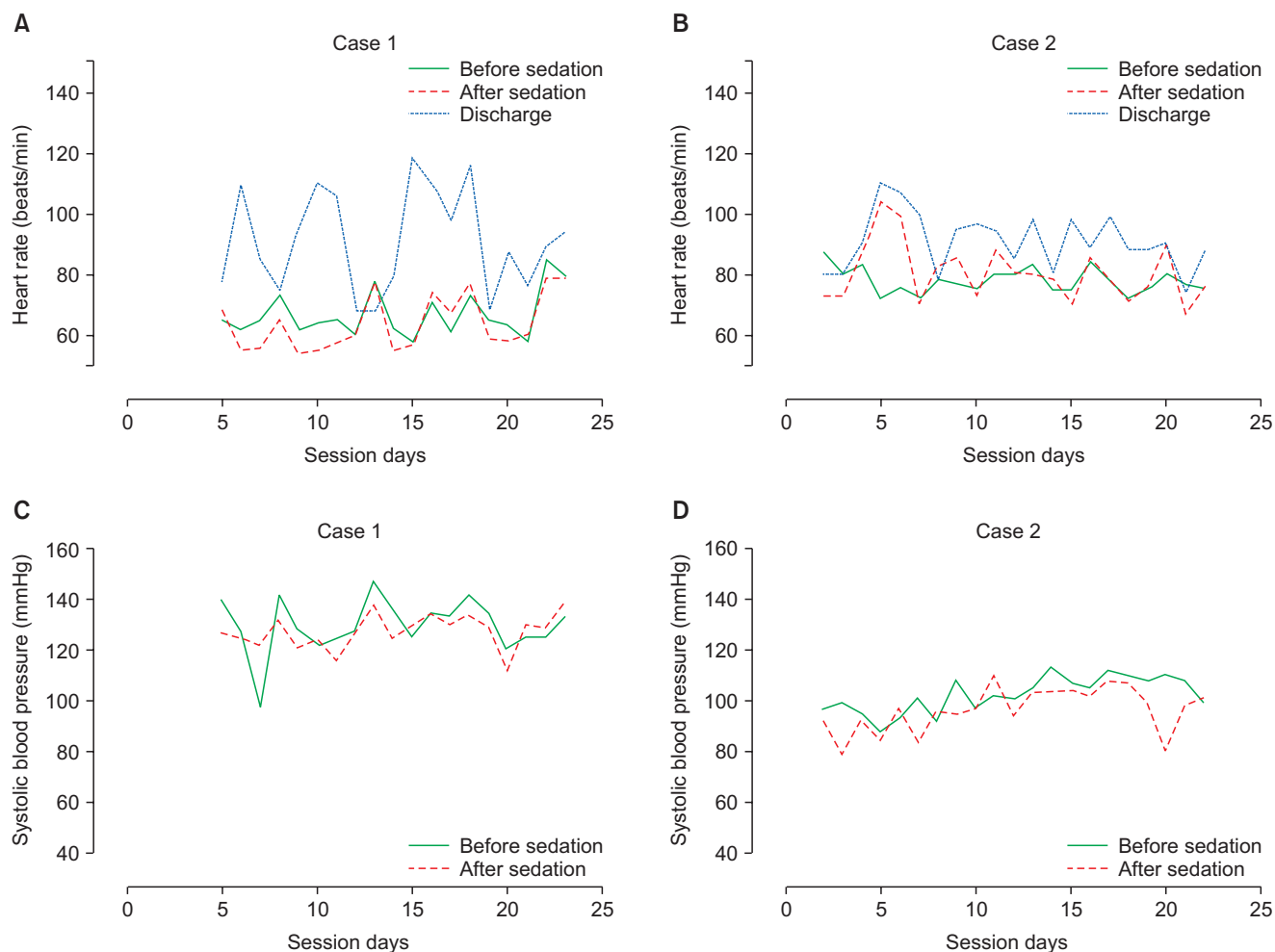
During radiation therapy, the patient's oxygen saturation remained at ≥ 98% via oxygen supplementation through a face-mask, and ETCO<sub>2</sub> was maintained at 28–41 mmHg. Prior to dexmedetomidine infusion, the patient's heart rate varied from 72–132 beats/min with a blood pressure of 100–134/58–94 mmHg. During dexmedetomidine infusion, the patient's heart rate varied from 58–85 beats/min with a blood pressure of 98–142/45–102 mmHg (Fig. 2). We closely observed the patient without treatment because his blood pressure was maintained within normal limits. Other than mild bradycardia, there were no adverse effects such as hypotension, hypertension, or nausea. Following each session, the patient's recovery time was 13–90 minutes (average = 44.6 minutes). The patient was admitted to the recovery room and eventually discharged when his modified Aldrete score was 9–10.

### Case 2

A 38-month-old boy (weight = 13 kg) presented with dysuria



**Fig. 1.** The changes in doses of dexmedetomidine during radiation therapy sessions in two patients. (A) Changes in loading doses. (B) Changes in maintenance doses.



**Fig. 2.** Changes in vital signs before and after sedation in two patients. (A) Heart rate (HR) changes before sedation, after sedation and discharge in case 1 patient. (B) HR changes in case 2 patient. (C) Systolic blood pressure (SBP) changes before and after sedation in case 1 patient. (D) SBP changes in case 2 patient.

and was diagnosed with rhabdomyosarcoma of the prostate gland on biopsy. He received preoperative chemotherapy and tumor resection, however, positive resection margins can develop after resection of the ejaculation duct. We planned to irradiate at 1.8 Gy/d for a total of 45 Gy/25 fractions, and each of the 22 treatments lasted 10 minutes.

After obtaining informed consent, intramuscular dexmedetomidine injection was planned and a single dose of 3  $\mu\text{g}/\text{kg}$  was administered to achieve a minimum RSS of 4. This provided smooth induction after 15 minutes, but this could only be maintained for about 10 minutes. Two IV boluses of 1 mg/kg propofol were administered to complete treatment. For the 2nd through the 7th sessions, a loading dose of 1  $\mu\text{g}/\text{kg}$  for 10 minutes and a maintenance dose of 0.5  $\mu\text{g}/\text{kg}/\text{h}$  were administered to achieve an RSS 4–5. On the 8th and 9th sessions, the same loading dose was used, but the maintenance dose increased to 2  $\mu\text{g}/\text{kg}/\text{h}$  to achieve the desired level of sedation. After that, the loading

dose also increased to 1.5  $\mu\text{g}/\text{kg}$  with a maintenance dose of 2  $\mu\text{g}/\text{kg}/\text{h}$  (Fig. 1). Before sedation, the patient's heart rate varied from 85–110 beats/min with a blood pressure of 88–114/54–74 mmHg. This varied from 72–87 beats/min with a blood pressure of 88–112/42–63 mmHg during dexmedetomidine infusion (Fig. 2). His respiratory rate and  $\text{ETCO}_2$  were within normal ranges. No adverse effects were observed, and his recovery took 13–41 minutes (average = 24.9 minutes).

## Discussion

We here present 2 pediatric patients who were repeatedly administered dexmedetomidine for sedation in order to further administer several sessions of radiation therapy at a remote location. Because treatment was administered in an outpatient setting, at first we tried to administer dexmedetomidine by intramuscular injection, though it went to nothing because of the

need for repetitive injection and the anesthesiologists could not enter the treatment vault during the therapy. Thus, IV dexmedetomidine was administered and used as the sole sedative agent in 17 of the 23 radiation therapy sessions in patient 1, and 21 of 22 sessions in patient 2.

The optimal cancer treatment often requires a combination of surgery, chemotherapy, and/or radiation therapy. While radiation therapy is painless, children can experience considerable anxiety due to unfamiliar and potentially frightening radiation equipment [3]. Nevertheless, children must be made motionless using anesthesia or sedation during this short procedure. Propofol, ketamine, midazolam, and general anesthesia with sevoflurane have been administered as anesthetics or sedatives to pediatric patients [3-5]. Adverse effects, including respiratory depression and excessive sedation, may necessitate endotracheal intubation [6]. Dexmedetomidine can be used as an alternative to these agents with only a minimal risk of respiratory depression. Previously, Shukry and Ramadhani [7] reported using dexmedetomidine during radiation therapy, and they used dexmedetomidine as the sole agent in 9 of 12 procedures. They administered dexmedetomidine at a loading dose of 1 µg/kg over 10 minutes, followed by a maintenance dose of 0.7–0.8 µg/kg/h, and administered additional propofol as extra sedation in 3 cases. In our current cases, we found that the infusion rate with the manufacturer-recommended dosage was insufficient for adequate sedation in pediatric patients. The loading doses were 1–2 µg/kg and the maintenance doses were 0.5–2 µg/kg/h, and both patients needed the dose to be increased as the sessions progressed. These high doses provided adequate sedation, but sudden unpredictable wake-up could not be prevented. As there is no known tolerance from dexmedetomidine so far, there was no clear explanation why the patients needed an increase in the dosing or extra sedation.

The well-known adverse effects associated with dexmedetomidine include hypotension, bradycardia, and transient hypertension [8]. In the present 2 cases, the total number of sessions exceed 20, but all treatment times were very short (5–10 minutes). The lowest heart rate in case 1 sometimes decreased below the age-based normal range for awake children [9]. However, because his noninvasive blood pressure was within the normal

range for awake children, additional treatment for bradycardia was not performed. Also, there are currently no established normal ranges for blood pressure or heart rate in children either during natural sleep or under medication-induced sedation [10]. Despite the use of higher doses and a more rapid infusion rate, our patients completely recovered from sedation within 90 minutes with no adverse events.

Large doses of dexmedetomidine (2–3 µg/kg followed by a continuous infusion of 2 µg/kg/h) were used in a previous pediatric magnetic resonance imaging study [10]. In that study, the authors reported a 16% incidence of bradycardia, with heart rates as low as 30 beats/min and proportionally more bradycardia in younger infants than older children. However, those authors did not treat these children because they maintained mean arterial pressures that were within 20% of the age-adjusted normal ranges. There has been another report on the use large doses of dexmedetomidine during pediatric computed tomography [11]. The authors in that study used a mean loading dose of 2.2 µg/kg with a maintenance dose of 1 µg/kg/h. In that study also, the heart rate and mean arterial pressure decreased by an average of 15%, but there were no significant changes in the respiratory rate or  $\text{ETCO}_2$ . However, if bradycardia occurs in the presence of marked hypotension, aggressive intervention—including stopping dexmedetomidine, stimulating the patient, or administering β-agonists and/or inotropes—is recommended [8].

In summary, we here report our experiences with administering dexmedetomidine to pediatric patients receiving repetitive radiation therapy. The key advantages of dexmedetomidine are that it maintains ventilation and upper airway patency during the sedation. Dexmedetomidine also provides adequate sedation and fast recovery without severe adverse effects, though it requires a significantly higher dosage than has been previously recommended.

## ORCID

Sun-Key Kim, <http://orcid.org/0000-0002-0789-5412>

In-Cheol Choi, <http://orcid.org/0000-0002-7386-5043>

## References

1. Precedex (Dexmedetomidine) package insert. Lake Forest, IL: Hospira, Inc. 2008. Available from [https://www.hospira.com/en/images/EN-4271\\_tcm81-92504.pdf](https://www.hospira.com/en/images/EN-4271_tcm81-92504.pdf)
2. Ramsay MA, Savege TM, Simpson BR, Goodwin R. Controlled sedation with alphaxalone-alphadolone. *Br Med J* 1974; 2: 656-9.
3. McFadyen JG, Pelly N, Orr RJ. Sedation and anesthesia for the pediatric patient undergoing radiation therapy. *Curr Opin Anaesthesiol* 2011; 24: 433-8.
4. Buchsbaum JC, McMullen KP, Douglas JG, Jackson JL, Simoneaux RV, Hines M, et al. Repetitive pediatric anesthesia in a non-hospital

- setting. *Int J Radiat Oncol Biol Phys* 2013; 85: 1296-300.
5. Harris EA. Sedation and anesthesia options for pediatric patients in the radiation oncology suite. *Int J Pediatr* 2010; 2010: 870921.
  6. Phan H, Nahata MC. Clinical uses of dexmedetomidine in pediatric patients. *Paediatr Drugs* 2008; 10: 49-69.
  7. Shukry M, Ramadhani U. Dexmedetomidine as the primary sedative agent for brain radiation therapy in a 21-month old child. *Paediatr Anaesth* 2005; 15: 241-2.
  8. Mason KP, Lerman J. Review article: Dexmedetomidine in children: current knowledge and future applications. *Anesth Analg* 2011; 113: 1129-42.
  9. Hartman ME, Cheifetz IM. Pediatric emergencies and resuscitation. In: *Nelson Textbook of Pediatrics*. 20th ed. Edited by Kliegman RM: Philadelphia, Saunders. 2016, pp 489-506.
  10. Mason KP, Zurakowski D, Zgleszewski SE, Robson CD, Carrier M, Hickey PR, et al. High dose dexmedetomidine as the sole sedative for pediatric MRI. *Paediatr Anaesth* 2008; 18: 403-11.
  11. Mason KP, Zgleszewski SE, Dearden JL, Dumont RS, Pirich MA, Stark CD, et al. Dexmedetomidine for pediatric sedation for computed tomography imaging studies. *Anesth Analg* 2006; 103: 57-62.