



## Review

## The place of nasolabial flap in orofacial reconstruction: A review

Amin Rahpeyma<sup>a</sup>, Saeedeh Khajehahmadi<sup>b, \*</sup><sup>a</sup> Oral and Maxillofacial Surgery, Oral and Maxillofacial Diseases Research Center, School of Dentistry, Mashhad University of Medical Sciences, Mashhad, Iran<sup>b</sup> Oral and Maxillofacial Pathology, Dental Research Center, School of Dentistry, Mashhad University of Medical Sciences, Mashhad, Iran

## HIGHLIGHTS

- Majority of nasolabial flaps have random pattern blood supply.
- Nasolabial flap can have different thicknesses from full thickness cheek to thin dermis and epidermis variants.
- Nasolabial flap for facial reconstruction can transfer in three ways including; advancement, rotation and transposition.

## ARTICLE INFO

## Article history:

Received 16 August 2016

Received in revised form

14 November 2016

Accepted 14 November 2016

## Keywords:

Facial reconstruction

Oral cavity reconstruction

Nasolabial flap

## ABSTRACT

**Background:** The use of Nasolabial flap (NLF) to reconstruct orofacial soft tissue defects is one of the oldest methods for reconstruction in the medical literature. Despite widespread use of this invaluable flap, there are still controversies over the terms used for the description of this flap.

**Materials and methods:** A search was run in PubMed for articles in English language on nasolabial flap in oral cavity/facial reconstruction, between 1960 and 2016. Inclusion criteria was case series that focused on the anatomy, flap design, blood supply, composition, flap motion, and the reconstructed area and donor site complications.

**Results:** 560 articles were found in PubMed search for nasolabial flap (between 1960 and 2016). 84 articles with case series structure and available full text were included. The results of the search in this topic for anatomy, flap design, blood supply, NLF composition, flap motion, reconstructed area and donor site morbidity are presented.

**Conclusion:** Nasolabial flap is an old flap for reconstructive purposes. Over time different modifications have been introduced to expand its usage. Clear definition of the terms used with this flap is given.

© 2016 The Authors. Published by Elsevier Ltd on behalf of IJS Publishing Group Ltd. This is an open access article under the CC BY-NC-ND license (<http://creativecommons.org/licenses/by-nc-nd/4.0/>).

## Contents

1. Introduction .....	80
2. Materials and methods .....	80
3. Results .....	80
3.1. Anatomy .....	80
3.2. Flap design .....	80
3.3. Blood supply .....	80
3.4. Flap composition .....	82
3.5. The flap motion .....	82
3.6. Reconstructed area and indications .....	82
3.7. Donor site complications .....	83
4. Discussion .....	83

\* Corresponding author. Dental Research Center of Mashhad University of Medical Sciences, Vakilabad Blvd, Mashhad, P.O. Box: 91735-984, Iran.

E-mail addresses: [rahpeymaa@mums.ac.ir](mailto:rahpeymaa@mums.ac.ir) (A. Rahpeyma), [khajehahmadis@mums.ac.ir](mailto:khajehahmadis@mums.ac.ir) (S. Khajehahmadi).

5. Conclusion .....	85
Ethical approval .....	85
Sources of funding .....	85
Author contribution .....	85
Conflicts of interest .....	85
Guarantor .....	85
Consent .....	85
Registration of research studies .....	85
References .....	85

## 1. Introduction

Replacement of the soft tissue loss after traumatic injuries or surgical excision requires soft tissue flaps. Nasolabial flap (NLF) cover is one of the oldest techniques to replace orofacial soft tissue defects [1]. Sushruta, an Indian surgeon in 600 BC described a soft tissue flap very similar to what we know today as “Nasolabial flap” [2]. The skin reservoir lateral the nasolabial fold can be used for oral cavity or facial reconstructions. NLF and melolabial flap can be used interchangeably but the latter term is used commonly by the dermatologists.

The ease of surgery, probability of carrying out the procedure under local anesthesia in co-morbid patients and inconspicuous scar are the advantages of this flap [3]. Despite widespread use of this invaluable flap, there are still controversies about the terms used for describing this flap and there is not any comprehensive review about nasolabial flap [4]. In this article, all terms related to nasolabial flap are explained with cases from author's personal experience to clarify this topic.

## 2. Materials and methods

A search was run in PubMed for articles in English language on nasolabial flap in oral cavity/facial reconstruction, between 1960 and 2016. Inclusion criteria was case series that focused on the anatomy, flap design, blood supply, composition, flap motion, and the reconstructed area and donor site complications.

## 3. Results

560 articles were found in PubMed search for nasolabial flap (between 1960 and 2016). 84 articles with case series structure and available full text were included.

### 3.1. Anatomy

The Anatomy of the nasolabial region is complex. Nasolabial crease run obliquely from approximately 1 Cm superior to the lateral alar rim to approximately 1 Cm lateral to the corner of the mouth. Four expression muscles present in this region including part of levator labi superioris, levator labi superioris alaque nasi, zygomatic major and minor muscles (Tan et al., 2013). Facial artery passes deep to the risorius and zygomatic major muscles but superficial to the buccinator muscle. It also gave off a superficial branch to the zygomaticus major muscle and other small perforating branches to the overlying skin [5]. Extensive subdermal vascular plexus in this region supplies from four arteries; facial, angular, infraorbital and transverse facial [6]. The Buccal and zygomatic branches of the facial nerve innervate the expression muscles of the face from below (Fig. 1) [7].

### 3.2. Flap design

This flap can be used unilaterally or bilaterally in the form of superiorly, inferiorly or centrally based pedicle flap (Fig. 2) [8]. The terms upper pedicled and cranially based have also been used for description of superiorly based NLF [9,10].

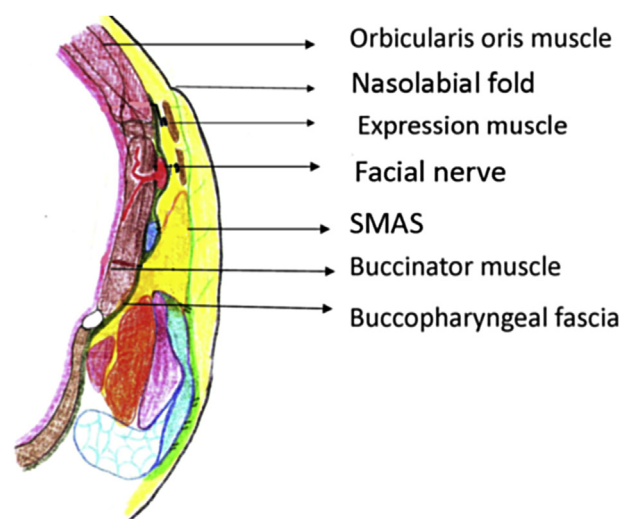
The flap is commonly designed lateral to the nasolabial fold with the medial limit of the flap 2–3 mm lateral to this fold [11].

In the superiorly based NLF, the base of the flap is near the ala and the apex is in line with the oral commissure [12]. Sometimes when an extra length (10–12 cm) is needed, it can be extended to the skin over the mandibular border. This variant of the superiorly based NLF is called extended NLF (Fig. 3) [13]. In the inferiorly based nasolabial flap the apex of the flap is 5–7 mm lateral to the medial canthus [14].

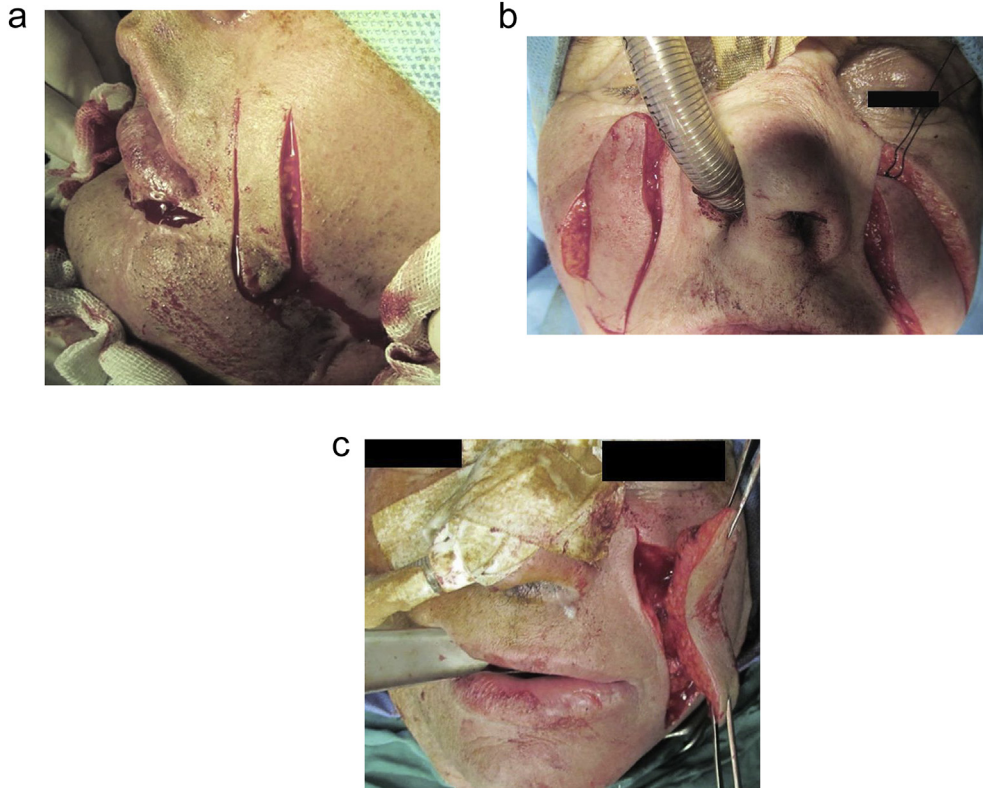
Occasionally NLF is designed medial to the nasolabial fold. This has two indications, first: When the nasolabial flap is used for reconstruction of the upper lip (lateral subunit) and lateral limit of the resected skin falls medial to the nasolabial fold [15] and second: When it is used for nasal floor reconstruction in cleft patients [16].

### 3.3. Blood supply

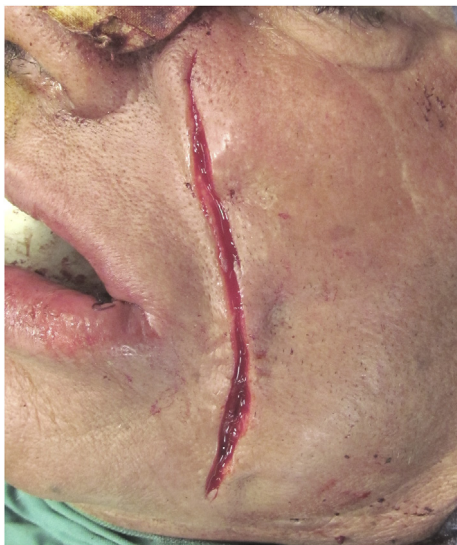The majority of the NLFs are random pattern [17]. Some NLFs can be designed to have an axial pattern blood supply. These include: Inferiorly based axial nasolabial flap that is nourished by facial artery [18]. Superiorly based reverse flow NLF containing angular artery [19]. The other name for this axial pattern flap is



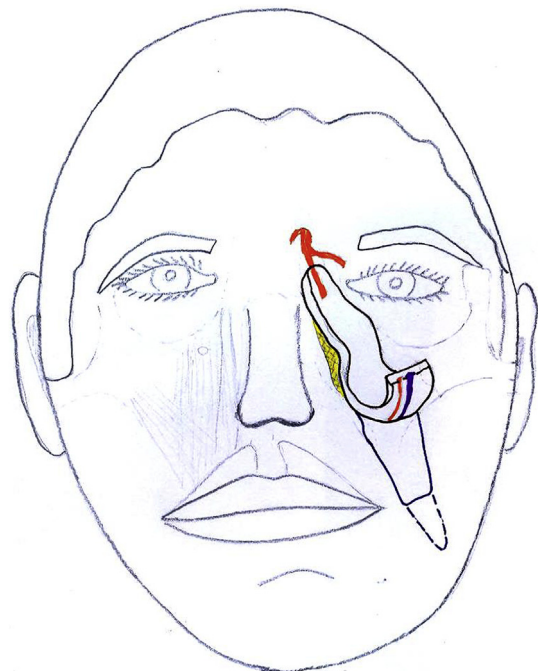
**Fig. 1.** Schematic picture: Anatomy of the nasolabial region. Incisions deep to the expression muscles will cut the end branches of the facial nerve without clinical significance.



**Fig. 2.** Nasolabial flaps based on the location of the pedicle. a, superiorly based. b, Inferiorly based. c, centrally based.



**Fig. 3.** Extended nasolabial flap.



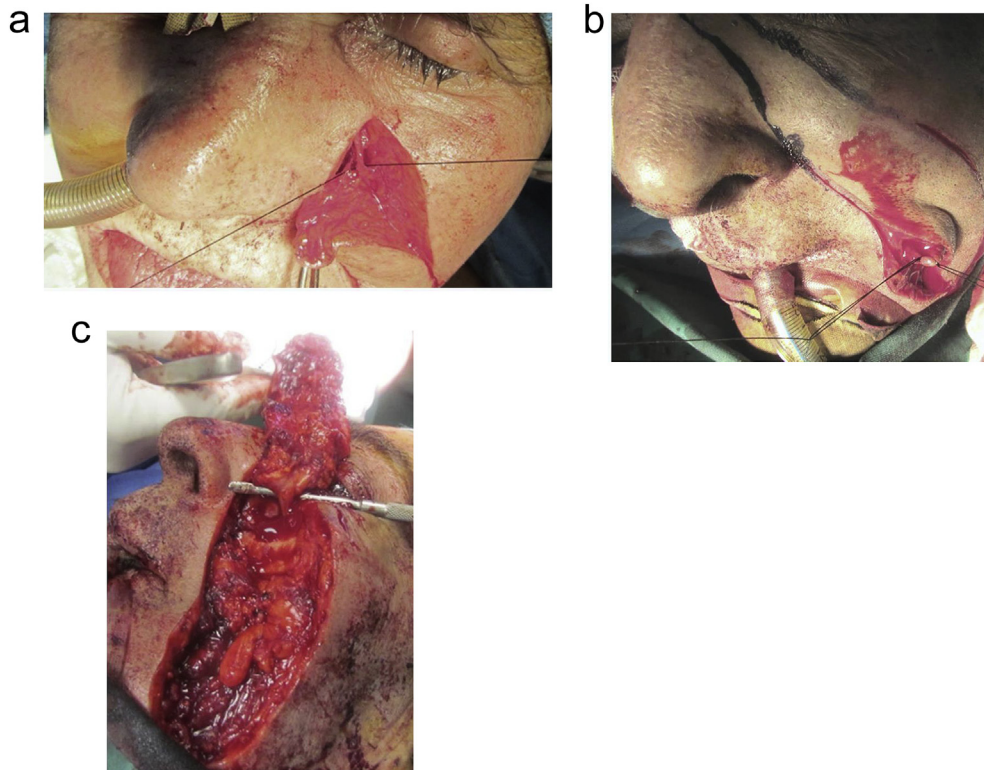
**Fig. 4.** Schematic picture: Orbitonasolabial flap. It is superiorly based, reverse flow flap based on the angular artery. Boundaries of this flap crosses the skin overlying the nasolabial region up to the medial canthus.

retroangular flap [20]. The orbitonasolabial flap falls in this category (Fig. 4) [21].

Another arterialized NLF is medially based horizontal NLF that is nourished by the lateral nasal branch of the facial artery [22]. The last axial pattern NLF mentioned in the articles is based on the infraorbital vessels (Fig. 5) [23]. This flap is nourished by infraorbital artery that is a branch of maxillary artery and has orthograde blood supply despite its superiorly based pedicle.

The facial artery crosses the face below the expression muscle of the face and above the buccinator muscle [24], so the axial-pattern

NLFs are thicker than random-pattern NLFs. The facial artery perforator-based NLF is a versatile flap that has the benefit of axial pattern blood supply through including a perforator branch from



**Fig. 5.** Axial pattern nasolabial flaps. a, Orthograde flow. b, Reverse flow. c, Based on infraorbital vessels.

**Table 1**  
Different types of the nasolabial flap based on flap composition.

Type of NLF	Flap composition	Flap thickness
Buried	Skinless	 Increase flap thickness
Defatted	D + E	
Ordinary	D + E + SQ fat	
Musculocutaneous or Myocutaneous	Skin + Em	
Full-thickness	Skin + Em + buccal mucosa	

D: Dermis; E: Epidermis; SQ: Subcutaneous; Em: Expression muscles.

the facial artery and is thin because it is not necessary to include the facial artery and the expression muscle in the flap [25].

### 3.4. Flap composition

Table 1 summarizes the information obtained from the articles in this topic [26–30].

The composite nasolabial flap is the other variant that was not incorporated into the table. This is ordinary NLF that is lined with the skin and is supported by cartilage [31]. Applications for this variant of NLF is exclusively limited to the nasal reconstruction. Nasolabial gate flap is special inferiorly based musculocutaneous transposition NLF that can be used for functional reconstruction of the lower lip [32].

### 3.5. The flap motion

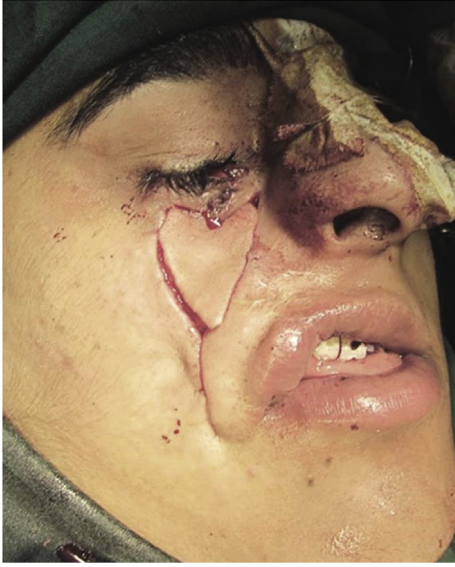NLF can be transferred in three directions: Advancement flap: NLF moves in the direction of the long axis of the flap, mainly in

cephalic direction. This kind of flap is called nasolabial V-Y advancement flap and is mostly used for infraorbital, medial canthus and lateral nasal reconstruction (Fig. 6) [33]. Rotation flap: The pivot point is the base of the NLF and the lateral limit of the defect coincides with the medial margin of the flap. This flap has a sole indication: reconstruction of the upper lip lateral segment [34,35]. Transposition flap: This type of NLF is a variant of rotation flaps. NLF is lifted and rotated to reach the defect [30,36]. If the distance between the nasolabial region and the recipient site is undermined to reach the flap from the donor to the recipient site by this route, this is called tunneled NLF and if the NLF is passed over the intervening segment of intact skin, then the term interpolated NLF is used [37,38]. Reconstructed area should fall inside the rotation radius of NLF.

### 3.6. Reconstructed area and indications

NLF has been reported for the facial skin reconstruction of the ipsilateral infraorbital, cheek and lower eyelid (advancement flap),





**Fig. 6.** Nasolabial V-Y advancement flap.

upper lip (rotation flap), philtrum (tunnelized flap), commissure, lower lip, and chin (transposition flap) [39–44].

Contralateral NLF could be considered for midline defects when ipsilateral flap is not available for reconstruction [45]. Search of Pubmed for “Nasolabial flap and nasal reconstruction” was half the results of “Nasolabial flap” for all applications. This flap is mainly used in face for the reconstruction of the nose (columella, tip, ala, lateral wall), for skin coverage and as nasal lining for nasal vestibule and septum or in the form of a turn-over flap in combination with the forehead flap (Fig. 7) [46–53].

Nasolabial flap perse can be used for nasal lining, and skin coverage when the defect involves the alar rim. Especially named superiorly based NLFs are used exclusively in nasal reconstruction.

These flaps included, folded NLF or bipaddled variant that is used for full-thickness alar defect reconstruction, when the alar rim is intact [54,55]. Bifid NLF is vertically split nasolabial flap that uses in nasal reconstruction when nasal tip and columella are designed to be reconstructed with the same NLF [56]. Spear twisted NLF is medially based nasolabial turn over flap for lining with a distal extension providing the cover with 90° twist of the NLF in between these two parts for full thickness alar defects involving the loss of the lateral alar groove.

For small to moderate intraoral lesions, it is used for buccal, palatal, floor of the mouth, tongue, and maxillary/mandibular alveolar region [57–61].

### 3.7. Donor site complications

Donor site often is closed with direct closure. The width of the flap is determined by the laxity of the tissues in the nasolabial region so it is more useful flap in the elderly patients.

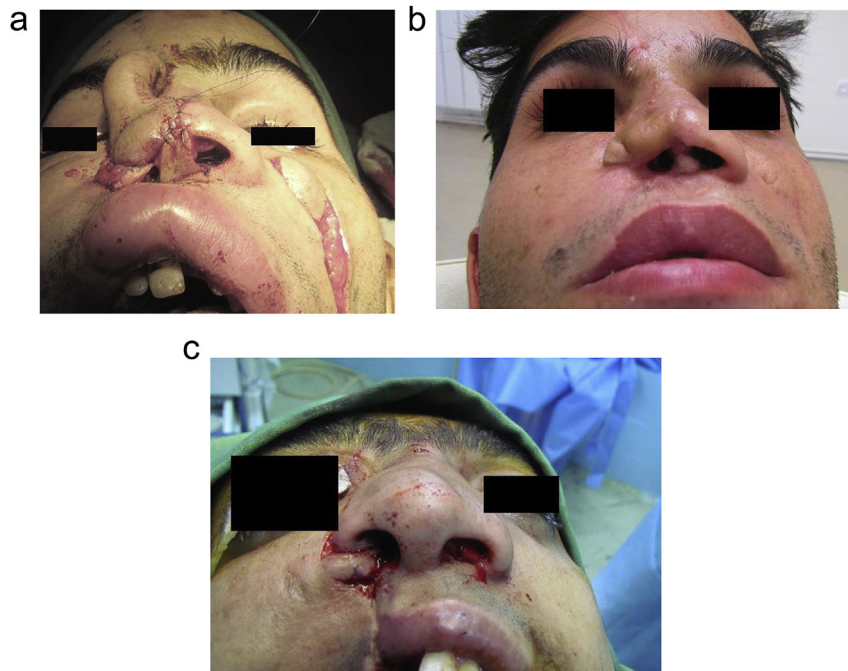
The superiorly based flaps can be longer with extension of the apex of the flap to mandibular inferior border, while inferiorly based NLFs are more limited in length [62,63].

Hypertrophic scars in susceptible individuals and wound dehiscence are two possible complications, when donor site is closed under tension [64].

Subcutaneous plane undermining in the cheek and M plasty are two suggested techniques for reducing the tension during donor site closure [65]. If the simple closure of the donor site is impossible, a cheek rotation flap is mandatory for donor site management. Whenever NLF is used for intraoral reconstruction, the risk of the orocutaneous fistula and iatrogenic dermoid (inclusion) cyst should be considered.

## 4. Discussion

Clinicians should know that the majority of the nasolabial flaps have random-pattern blood supply. Despite this fact, NLF is highly versatile because blood vessels in subdermal layer travel in axial



**Fig. 7.** a, Nasolabial flap for columella reconstruction. b, One year follow up. c, Nasolabial flap for constricted nasal floor reconstruction.

direction, so the length/width ratio can reach near that of the true axial-pattern flaps [66]. This is true that it is not necessary to include facial artery in flap design for flap survival but facial artery preservation at the same side with nasolabial flap will increase the flap reliability.

Axial-pattern nasolabial flaps are thick flaps. They are more reliable and have more pedicle length [67]. They can be orthograde or reverse flow based on the facial and angular artery, respectively. In cases that facial artery is ligated, these flaps are not indicated but infraorbital-based nasolabial flap that is nourished by infraorbital artery (a branch of the maxillary artery) can be used.

Nasolabial flaps can have different thickness based on the reconstructive requirements. It can be thinned at the level of the dermis and epidermis when a thin pliable flap is needed for alar reconstruction or as thick as possible (full-thickness NLF) when it is used for reconstruction of through-and-through lip defects.

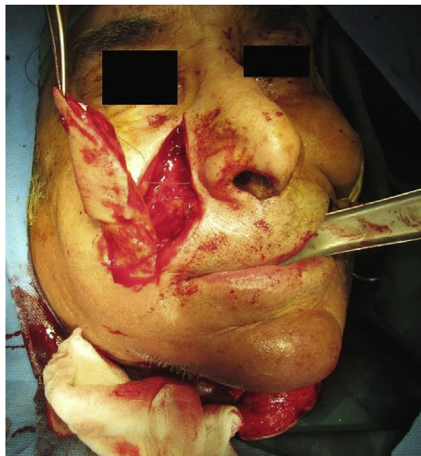For facial skin replacement, NLF can be used in the form of the advancement, rotation or transposition flaps while for oral cavity reconstruction; only available form is the transposition flap.

The skin island variant of the NLF for facial reconstruction is mandatory when advancement or tunnelized NLFs are used for facial skin reconstruction [68]. This strategy in the advancement or V-Y NLF is necessary to allow movement in the direction of the flap long axis and in the tunnelized variant to avoid the second stage surgery for pedicle division.

The skin island nasolabial flap or other synonym term “subcutaneous pedicled NLF” is the only variant of the NLF available for intraoral reconstruction. 1–1.5 Cm de-epithelialization of the skin flap near the base is necessary to prevent iatrogenic dermoid cyst formation when this flap is passed through the *trans*-buccal tunnel to reach the oral cavity (Fig. 8) [69]. The rate of implantation dermoid cysts with this flap is low and is limited to case reports. We have an experience with this unusual complication that occurred three years after usage of tunnelized NLF for philtrum reconstruction in a cleft patient.

It is important that the readers distinguish the vascular island NLF from the nasolabial island flap. The former is axial-pattern NLF that contains a named artery in the pedicle while the latter is a skin flap that is islanded to the subcutaneous pedicle [70,71]. Dermal pedicled NLF is more appropriate description for thin defatted NLFs [72].

The patient's dentition is an important factor for selecting the nasolabial flap for intraoral reconstruction. For soft tissue structures inside the dental arch such as the palate, tongue, and mouth



**Fig. 8.** Nasolabial skin island flap. Deepithelialized part of the flap near the pedicle is necessary for transfer of the flap through transbuccal tunnel.

floor, the presence of the teeth blocks the NLF to reach these regions and even in edentulous patients need to the second stage surgery for pedicle division.

Today for reconstruction of the tongue and palate, even in edentulous patients, there are better options other than the NLF. In the best conditions it replaces the lost mucosa with the skin and if used for mucosal reconstruction inside the edentulous arches, then a second surgery for vestibuloplasty and pedicle division is needed if the patient desires to wear dentures.

The nasolabial flap has been used for small to moderate sized intraoral defects. However, bilateral NLFs for soft tissue reconstruction of large mandibular anterior region (up to 5 × 5 cm) in edentulous patients is encouraged (Fig. 9) [73].

Bilateral NLFs produce less asymmetry in the face while slight iatrogenic nasolabial asymmetry is seen in patients receiving unilateral NLF for intraoral reconstruction.

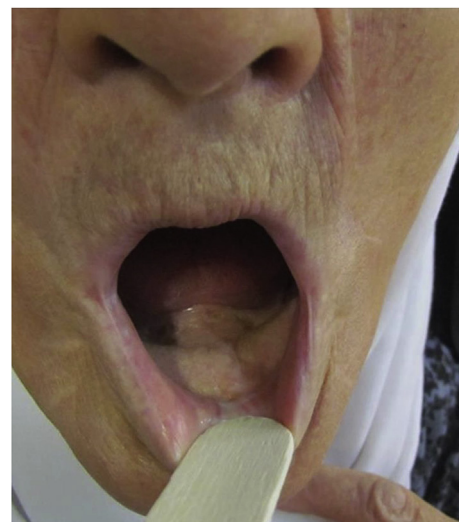
Buccal mucosal reconstruction with NLF in one stage is possible, both in edentulous and dentate patients (Fig. 10). This flap has become popular in the treatment of limitations in mouth opening of patients with oral submucosal fibrosis with vertical mucosal bands in the cheek concomitant with coronoidectomy [74–77].

If the rules present in the anatomic section of this article are strictly adhered, the donor site complications will low.

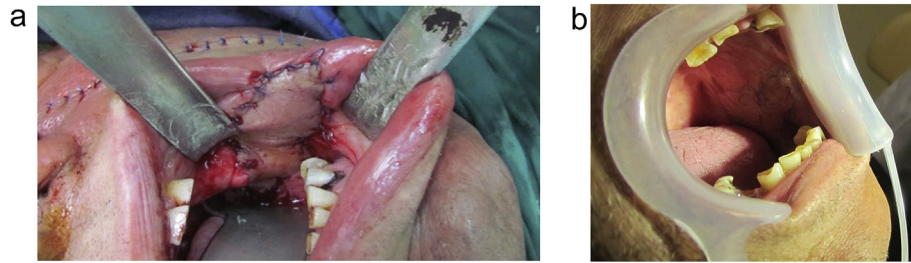Eliminating nasolabial fold is common if this fold is incorporated into the flap. Periosteal suspension sutures and minimal eversion of the skin during closure of donor site is advised to prevent flat cheek formation [78]. In the medial canthal region, if the distance between the apex of the flap and medial canthus is not followed, medial lower eyelid ectropion is the result. Nasolabial rhomboid flap is a NLF with rhomboid design to prevent dog ear formation during closure of donor site.

Delay procedure is a strategy to increase flap survival, that mostly is used with deltopectoral flap but can be applied with the NLF for reducing complications related to the flap blood supply [79]. This variant is suggested when reutilizing NLF or its blood supply is compromised such as in deep burned face or when extra-long NLF is needed [80].

There is a false concept in NLF: The musculomucosal nasolabial island flap is a misnomer and should not be applied for myomucosal flap in buccal region. NLF contains skin and a better term for this flap is FAMM (facial artery myomucosal) flap [81,82].



**Fig. 9.** Bilateral nasolabial flap is used for reconstruction of the mandibular alveolar ridge and anterior floor of the mouth after squamous cell carcinoma resection.



**Fig. 10.** a, Buccal mucosal reconstruction by nasolabial flap. b, Problem of hairs in intraoral reconstruction in a male patient.

Reverse vascular or reverse blood flow NLF are acceptable terms but reverse NLF that means thin, turn over superiorly based NLF with random pattern blood supply is not suitable.

Composite NLF means prelaminated flap with skin graft and cartilage. Applying this term to the any NLF containing expression muscles or buccal mucosa is not justified.

Inherent limitations of NLF other than limited size of the flap pedicle are:

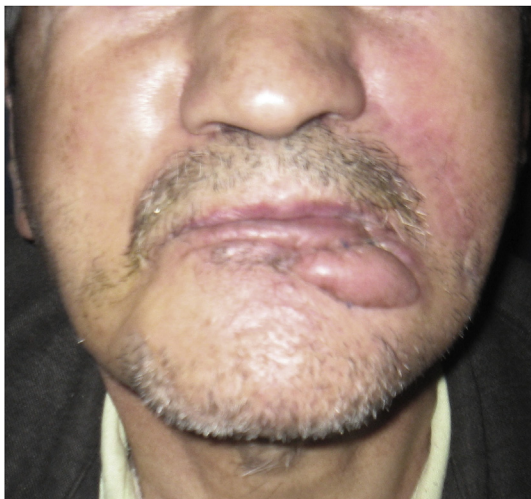The problem of the hair in intraoral reconstruction with NLF is seen in extended NLF in male patients [83].

Trapdoor effect in the NLF is possible complication of this flap when it is used for facial skin reconstruction. It is an elevated and bulging deformity of tissue within the semicircular confines of a U-, C-, or V-shaped scar. This can occur in both superiorly or inferiorly based NLFs (Fig. 11). The trapdoor deformity may be prevented or minimized by peripheral undermining about the recipient site of the flap equal to or greater in area than the recipient site [84]. Management of this deformity is via multiple z-plasty.

Limitation of this review is that all articles with nasolabial flap used for orofacial reconstruction are not included but comprehensive review of this flap with limited number of references is done. However this study is not a meta-Analysis or systematic review.

## 5. Conclusion

Nasolabial flap is an old flap for reconstructive purposes. Over time, different modifications have been introduced to expand its usage. The clear definitions of the terms that used with this flap are



**Fig. 11.** Trapdoor (pincushioning) effect in the inferiorly based nasolabial flap used for lower lip reconstruction.

presented.

## Ethical approval

None.

## Sources of funding

This study was supported by a grant from the Vice Chancellor of Research of Mashhad University of Medical Sciences.

## Author contribution

Study design:Rahpeyma.

Data collections:khajehahmadi.

Data analysis:

Writing: Rahpeyma.

## Conflicts of interest

There are no interests.

## Guarantor

This study was supported by a grant from the Vice Chancellor of Research of Mashhad University of Medical Sciences.

## Consent

Written patient consent has been obtained to publish clinical photographs.

## Registration of research studies

Research registry 1339.

## References

- [1] H.S. Gewirtz, F.R. Eilber, H.A. Zarem, Use of the nasolabial flap for reconstruction of the floor of the mouth, *Am. J. Surg.* 136 (1978) 508–511.
- [2] M.A. Ellabban, W.J. Van Niekerk, T. Shoaib, Sutures to mark the exact site of division of the two-stage nasolabial flap for floor-of-mouth reconstruction, *J. Plast. Reconstr. Aesthet. Surg. JPRAS* 61 (2008) 217–218.
- [3] C. Navarro Cuellar, S.J. Caicoya, J.J. Acero Sanz, I. Navarro Cuellar, C.M. Muela, C. Navarro Vila, Mandibular reconstruction with iliac crest free flap, nasolabial flap, and osseointegrated implants, *J. Oral Maxillofac. Surg. Off. J. Am. Assoc. Oral Maxillofac. Surg.* 72 (2014), 1226.e1-15.
- [4] H. Matsuda, Y. Takahashi, A. Ichinose, H. Miyazaki, H. Kakizaki, Combination of nasolabial v-y advancement flap and glabellar subcutaneous pedicled flap for reconstruction of medial canthal defect, *Case Rep. Ophthalmol.* 5 (2014) 50–53.
- [5] Y.A. Pinar, O. Bilge, F. Govsa, Anatomic study of the blood supply of perioral region, *Clin. Anat. (New York, NY)* 18 (2005) 330–339.
- [6] T.P. Whetzel, S.J. Mathes, Arterial anatomy of the face: an analysis of vascular territories and perforating cutaneous vessels, *Plast. Reconstr. Surg.* 89 (1992) 591–603 discussion 4–5.



- [7] K. Hwang, Surgical anatomy of the facial nerve relating to facial rejuvenation surgery, *J. Craniofacial Surg.* 25 (2014) 1476–1481.
- [8] W.M. Weathers, E.M. Wolfswinkel, H. Nguyen, J.F. Thornton, Expanded uses for the nasolabial flap, *Semin. Plast. Surg.* 27 (2013) 104–109.
- [9] G. Thiery, O. Coulet, L. Guyot, Reconstruction of a transfixing partial loss of substance from the wing of nose with the upper pedicled nasolabial flap, *Rev. Laryngol. Otol. Rhinol.* 129 (2008) 49–51.
- [10] H. Kerem, U. Bali, E. Sonmez, Y.I. Manavbasi, L. Yoleri, The cranially based contralateral nasolabial flap for reconstruction of paranasal and periorbital surgical defects, *J. Plast. Reconstr. Aesthet. Surg. JPRAS* 67 (2014) 655–661.
- [11] H. Bi, X. Xing, J. Li, Nasolabial-alar crease: a natural line to facilitate transposition of the nasolabial flap for lower nasal reconstruction, *Ann. Plastic Surg.* 73 (2014) 520–524.
- [12] L.M. Field, Design concepts for the nasolabial flap, *Plast. Reconstr. Surg.* 71 (1983) 283–285.
- [13] R.M. Borle, P.V. Nimonkar, R. Rajan, Extended nasolabial flaps in the management of oral submucous fibrosis, *Br. J. Oral Maxillofac. Surg.* 47 (2009) 382–385.
- [14] Y. Ducic, M. Burye, Nasolabial flap reconstruction of oral cavity defects: a report of 18 cases, *J. Oral Maxillofac. Surg. Off. J. Am. Assoc. Oral Maxillofac. Surg.* 58 (2000) 1104–1108 discussion 8–9.
- [15] M. Bento, L. Carmo, M. Trigo, N. Rebelo, P. Garcia, The island nasolabial flap in philtrum reconstruction after bite avulsion: a case report, *J. Plast. Reconstr. Aesthet. Surg. JPRAS* 62 (2009) e487–9.
- [16] A. Rahpeyma, S. Khajehahmadi, The last resort for reconstruction of nasal floor in difficult-to-repair alveolar cleft cases: a retrospective study, *J. Cranio Maxillo Facial Surg. off. Publ. Eur. Assoc. Cranio Maxillo-Facial Surg.* 42 (2014) 995–999.
- [17] B. Hynes, J.B. Boyd, The nasolabial flap. Axial or random? *Arch. Otolaryngol. Head Neck Surg.* 114 (1988) 1389–1391.
- [18] E.H. Rose, One-stage arterialized nasolabial island flap for floor of mouth reconstruction, *Ann. Plastic Surg.* 6 (1981) 71–75.
- [19] C. Le-Quang, Reversed vascular full-thickness nasolabial flap, *Ann. de Chir. Plast. Esthet.* 38 (1994) 273–278.
- [20] N. Iida, N. Ohsumi, Y. Tsutsumi, M. Tonegawa, The full-thickness retroangular flap, *Ann. Plastic Surg.* 45 (2000) 544–549.
- [21] G. Dagregorio, F. Baraer, V. Darsonval, Seven reconstructions of the orbital and periorbital region with a contralateral orbitonasolabial flap, *Br. J. Plast. Surg.* 58 (2005) 940–943.
- [22] R.L. Pincus, R.P. Bukachevsky, Medially based horizontal nasolabial flaps for reconstruction of columellar defects, *Arch. Otolaryngol. Head Neck Surg.* 116 (1990) 973–974.
- [23] B. He, J. Song, X. Fan, Clinical application of nasolabial subcutaneous pedicle skin flap with infraorbital artery, *Zhonghua zheng xing shao shang wai ke za zhi = Zhonghua zheng xing shao shang waike [ie waike] zazhi = Chin. J. plastic Surg. burns/[Chung-hua cheng hsing shao shang wai k'o tsa chih pien* 10 (1994) 423–425.
- [24] D. Funt, T. Pavicic, Dermal fillers in aesthetics: an overview of adverse events and treatment approaches, *Clin. Cosmet. Investig. Dermatol.* 6 (2013) 295–316.
- [25] T.H. Yoon, I.S. Yun, D.K. Rha, W.J. Lee, Reconstruction of various perinasal defects using facial artery perforator-based nasolabial island flaps, *Arch. Plast. Surg.* 40 (2013) 754–760.
- [26] H. Steenfos, P. Tarnow, G. Blomqvist, Experience with the modified defatted nasolabial transposition flap in nasal reconstruction, *Scand. J. Plast. Reconstr. Surg. Hand Surg./Nordisk plastikkirurgisk forening Nordisk klubb handkirurgi* 29 (1995) 51–52.
- [27] G. Campus, N. Standoli, C. Alfano, Reconstruction of the lower lip with a full thickness nasolabial island flap, *Scand. J. Plast. Reconstr. Surg. Hand Surg./Nordisk plastikkirurgisk forening Nordisk klubb handkirurgi* 28 (1994) 285–288.
- [28] W.E. Hagan, Nasolabial musculocutaneous flap in reconstruction of oral defects, *Laryngoscope* 96 (1986) 840–845.
- [29] T.R. Vecchione, Use of a buried nasolabial flap to fill a depression over the lower jaw. Case report, *Plast. Reconstr. Surg.* 58 (1976) 375–376.
- [30] K.B. Soh, K.C. Soo, Reconstruction of moderate sized intra-oral defects using the nasolabial flap, *Ann. Acad. Med. Singapore* 23 (1994) 891–895.
- [31] G.D. Goldman, Kakinuma, et al., A composite nasolabial flap for an entire ala reconstruction, *Dermatol. Surg.* 28 (2002) 870–871 official publication for American Society for Dermatologic Surgery [et al].
- [32] R. Fujimori, Gate flap for the total reconstruction of the lower lip, *Bri. J. Plast. Surg.* 33 (1980) 340–345.
- [33] O. Ayeni, O. Ayeni, W. Carey, C. Muhn, Combined advancement and single-lobed nasolabial transposition flaps for a nasal sidewall defect, *Dermatol. Surg.* 38 (2012) 1386–1389 official publication for American Society for Dermatologic Surgery [et al].
- [34] G. Simons, J.M. Greco, V. Darsonval, The naso-cheek or nasolabial rotation flap with subcutaneous pedicle in the repair of tissue loss above the lip, *Ann. de Chir. Plast. Esthet.* 29 (1984) 74–77.
- [35] A. Rahpeyma, S. Khajehahmadi, Unilateral one stage nasolabial flap for reconstruction of the lips, *J. Maxillofac. Oral Surg.* 14 (2015) 234–239.
- [36] J.O. Barlow, The bifurcated nasolabial transposition flap, *Dermatol. Surg.* 37 (2011) 695–699 official publication for American Society for Dermatologic Surgery [et al].
- [37] N.G. Georgiade, R.A. Mladick, F.L. Thorne, The nasolabial tunnel flap, *Plast. Reconstr. Surg.* 43 (1969) 463–466.
- [38] D.B. Pharis, D.J. Papadopoulos, Superiorly based nasolabial interpolation flap for repair of complex nasal tip defects, *Dermatol. Surg.* 26 (2000) 19–24 official publication for American Society for Dermatologic Surgery [et al].
- [39] J.F. Yeo, P. Egyedi, Reconstruction of soft tissues of the chin and lower lip region following excision of a basal cell carcinoma, *J. Cranio Maxillo Facial Surg. Off. Publ. Eur. Assoc. Cranio Maxillo Facial Surg.* 16 (1988) 337–339.
- [40] S. Yildirim, T. Akoz, M. Akan, B. Cakir, The use of combined nasolabial V-Y advancement and glabellar flaps for large medial canthal defects, *Dermatol. Surg.* 27 (2001) 215–218 official publication for American Society for Dermatologic Surgery [et al].
- [41] C.D. Shipkov, Y.K. Anastassov, R.I. Simov, Unilateral superiorly-based nasolabial island flap for the reconstruction of the philtrum, *Scand. J. Plast. Reconstr. Surg. Hand Surg./Nordisk plastikkirurgisk forening [and] Nordisk klubb for handkirurgi* 36 (2002) 177–179.
- [42] A. Aslan, A.C. Ozkan, H. Aydin, T. Koldas, S. Tuncer, Orocutaneous fistula arising secondary to irritation of an external dental prosthesis and its reconstruction using a nasolabial island flap, *Ann. Plast. Surg.* 47 (2001) 95–96.
- [43] J.B. Vannieuwenhuysse, M. Duflos, Nasolabial flaps for repair of defects on the upper lip and lateral aspects of the nose, *J. Dermatol. Surg. oncol.* 8 (1982) 351–355.
- [44] A.W. Walker, J.E. Schewe Jr., Nasolabial flap reconstruction for carcinoma of the lower lip. An eleven year follow-up study, *Am. J. Surg.* 113 (1967) 783–786.
- [45] P. Ponte, J. Goulao, J.R. de Almeida, Contralateral nasolabial flap for a large nasal defect, *Dermatol. Surg.* 35 (2009) 675–678 official publication for American Society for Dermatologic Surgery [et al].
- [46] O.A. Santos, J.C. Pappas, Repair of nostril defect with a contralateral nasolabial flap, *Plast. Reconstr. Surg.* 57 (1976) 704–706.
- [47] D.R. Wesser, G.B. Burt Jr., Nasolabial flap for losses of the nasal ala and columella. Case report, *Plast. Reconstr. Surg.* 44 (1969) 300–302.
- [48] S.S. Kroll, Nasal alar reconstruction using the nasolabial turnover flap, *Laryngoscope* 101 (1991) 1127–1131.
- [49] E. Uchinuma, K. Matsui, Y. Shimakura, K. Murashita, N. Shioya, Evaluation of the median forehead flap and the nasolabial flap in nasal reconstruction, *Aesthet. Plast. Surg.* 21 (1997) 86–89.
- [50] M.T. Edgerton, J.L. Marsh, Uses of the nasolabial flap in the correction of cleft lip nasal deformities, *Plast. Reconstr. Surg.* 60 (1977) 56–67.
- [51] J.A. Burnam, The nasolabial flap in reconstruction of the nose, *J. Fla. Med. Assoc.* 59 (1972) 32–34.
- [52] L.R. McLaren, Nasolabial flap repair for alar margin defects, *Br. J. Plast. Surg.* 16 (1963) 234–238.
- [53] E. Haas, Reconstruction of the ala nasi and the lateral wall of the nose, *Rhinology* 14 (1976) 83–90.
- [54] R.J. Rohrich, M.H. Conrad, The superiorly based nasolabial flap for simultaneous alar and cheek reconstruction, *Plast. Reconstr. Surg.* 108 (2001) 1727–1730 quiz 31.
- [55] M. Jovanovic, M. Colic, L. Rasulic, M. Stojicic, M. Malis, Reconstruction of the alae nasi by folded nasolabial flap, *Acta Chirur. Iugosl.* 54 (2007) 29–32.
- [56] I. Ozkus, D.I. Cek, K. Ozkus, The use of bifid nasolabial flaps in the reconstruction of the nose and columella, *Ann. Plast. Surg.* 29 (1992) 461–463.
- [57] S.G. Ananian, V.M. Bezrukov, Use of a nasolabial flap for correcting defects of the hard palate, *Vestnik khirurgii imeni I I Grekova* 142 (1989) 91–92.
- [58] K.L. Mutimer, M.D. Poole, A review of nasolabial flaps for intra-oral defects, *Br. J. Plast. Surg.* 40 (1987) 472–477.
- [59] B.D. Birt, J.S. Gruss, Intra-oral reconstruction using the nasolabial flap, *J. otolaryngol.* 14 (1985) 233–236.
- [60] R.F. Morgan, R.G. Chambers, D.A. Jaques, J.E. Hoopes, Nasolabial flap in intraoral reconstruction. Review of 55 cases, *Am. J. Surg.* 142 (1981) 448–450.
- [61] I.K. Cohen, S.D. Theogaraj, Nasolabial flap reconstruction of the floor of the mouth after extirpation of oral cancer, *Am. J. Surg.* 130 (1975) 479–480.
- [62] H.H. El-Marakby, The versatile naso-labial flaps in facial reconstruction, *J. Egypt. Natl. Cancer Inst.* 17 (2005) 245–250.
- [63] A.H. Mebeed, H.A. Hussein, T. Saber, Critical appraisal of nasolabial flap for reconstruction of oral cavity defects in cancer patients, *J. Egypt. Natl. Cancer Inst.* 21 (2009) 33–42.
- [64] P. Chitlangia, E. Kumuran, K.S. Sabitha, Use of nasolabial flap in intra and extraoral reconstruction: our experience with 40 cases, *J. of Maxillofac. Oral Surg.* 11 (2012) 451–454.
- [65] D.C. Braasch, D. Lam, E.S. Oh, Maxillofacial reconstruction with nasolabial and facial artery musculomucosal flaps, *Oral and Maxillofac. Surg. Clin. N. Am.* 26 (2014) 327–333.
- [66] D.C. Herbert, J. DeGeus, Nasolabial subcutaneous pedicle flaps, *Br. J. Plast. Surg.* 28 (1975) 90–96.
- [67] S.R. Thaller, S. Kim, M. Wildman, H. Patterson, Microdissection of the nasolabial axial myocutaneous flap, *Ear nose Throat J.* 70 (1991) 93–96.
- [68] A. Rahpeyma, S. Khajehahmadi, Treatment of a unilateral Tessier number 4 facial cleft in an adult: role of nasolabial V-Y advancement flap, *Br. J. Oral Maxillofac. Surg.* 53 (2015) 99–101.
- [69] R.A. Elliott Jr., Use of nasolabial skin flap to cover intraoral defects, *Plast. Reconstr. Surg.* 58 (1976) 201–205.
- [70] N. Lazaridis, I. Tilaveridis, D. Karakasis, Superiorly or inferiorly based “islanded” nasolabial flap for buccal mucosa defects reconstruction, *J. Oral Maxillofac. Surg.* 66 (2008) 7–15 official journal of the American Association of



- Oral and Maxillofacial Surgeons.
- [71] M. Braun Jr., J. Cook, The island pedicle flap, *Dermatol. Surg.* 31 (2005) 995–1005 official publication for American Society for Dermatologic Surgery [et al].
- [72] Y. Chen, Dermal pedicled nasolabial flap with subdermal vascular network for repairing nasolabial skin defects, *Zhongguo xiu fu chong jian wai ke za zhi = Zhongguo xiufu chongjian waike zazhi, Chin. J. Repar. Reconstr. Surg.* 25 (2011) 1459–1461.
- [73] S.S. Deora, M. Nanjappa, S.V. Kumaraswamy, Bilateral pedicled nasolabial flaps for the anterior alveolus mandibular defect: a review, *J. Maxillofac. Oral Surg.* 9 (2010) 385–388.
- [74] S.G. Patel, S. Deshmukh, D.N. Savant, Squamous cell carcinoma arising in a nasolabial flap used in treatment of oral submucous fibrosis, *Br. J. Plast. Surg.* 47 (1994) 388–389.
- [75] A.M. Eckardt, H. Kokemuller, F. Tavassol, N.C. Gellrich, Reconstruction of oral mucosal defects using the nasolabial flap: clinical experience with 22 patients, *Head neck oncol.* 3 (2011) 28.
- [76] M. Agarwal, D.K. Gupta, A.D. Tiwari, Extended nasolabial flaps in the management of oral submucous fibrosis, *J. Maxillofac. Oral Surg.* 10 (2011) 216–219.
- [77] R. Kshirsagar, A. Chugh Modi, A. Rai, Bilateral inferiorly based nasolabial flaps for the management of advanced oral submucous fibrosis, *J. Maxillofac. Oral Surg.* 9 (2010) 22–26.
- [78] J.A. Zitelli, The nasolabial flap as a single-stage procedure, *Arch. Dermatol.* 126 (1990) 1445–1448.
- [79] I. Zilinsky, J. Alcalay, D. Jacobs, J. Tamir, E. Winkler, J. Haik, et al., The versatility of the nasolabial flap enhanced by the delay procedure, *Dermatol. Surg.* 27 (2001) 161–164 official publication for American Society for Dermatologic Surgery [et al].
- [80] S. Haack, H. Fischer, W. Gubisch, Lining in nasal reconstruction, *Fac. Plast. Surg. FPS* 30 (2014) 287–299.
- [81] V. Uglesic, M. Virag, Musculomucosal nasolabial island flaps for floor of mouth reconstruction, *Br. J. Plast. Surg.* 48 (1995) 8–10.
- [82] J. Pribaz, W. Stephens, L. Crespo, G. Gifford, A new intraoral flap: facial artery musculomucosal (FAMM) flap, *Plast. Reconstr. Surg.* 90 (1992) 421–429.
- [83] C.R. Bande, A. Datarkar, N. Khare, Extended nasolabial flap compared with the platysma myocutaneous muscle flap for reconstruction of intraoral defects after release of oral submucous fibrosis: a comparative study, *Br. J. oral Maxillofac. Surg.* 51 (2013) 37–40.
- [84] F.C. Koranda, R.C. Webster, Trapdoor effect in nasolabial flaps. Causes and corrections, *Arch. Otolaryngol. (Chicago, Ill 1960)* 111 (1985) 421–424.