

THE BRITISH JOURNAL
OF
OPHTHALMOLOGY

JULY, 1918

COMMUNICATIONS

DISTURBANCES OF VISION BY CEREBRAL
LESIONS*

BY

GORDON HOLMES, C.M.G., M.D., Lieut.-Col. R.A.M.C.

ABOUT 18 months ago I was able to present to this Section with my colleague, Colonel Lister, certain clinical observations on the disturbances of vision produced by gunshot injuries of the visual cortex and of the optic radiations. From these we drew certain conclusions on the cortical representation of the retina, and particularly on the segmental correspondence of different areas of the retina with separate zones of the visual cortex. Our chief conclusions were:

1. The upper half of each retina is represented in the dorsal, and the lower in the ventral part of each visual area.
2. The centre for macular or central vision lies in the posterior extremities of the visual areas, probably in the margins and the lateral surfaces of the occipital poles. The macular region has not a bilateral representation.
3. The centre for vision subserved by the periphery of the retinae is probably situated in the anterior ends of the visual areas, and the serial concentric zones of the retina from the macula to the periphery

*Read in the Section of Ophthalmology of the Royal Society of Medicine, December 12, 1917.

are probably represented in this order from behind forwards in the visual cortex.

These conclusions agree with those that were previously arrived at by Inouye from his observations on gunshot injuries of the occipital lobes inflicted in the Russo-Japanese War, and they conform with Marie and Chatelin's valuable investigations on men with wounds similar to those of our patients. They have later received support from various observers, and especially from Captain Riddoch.

Since our last communication I have had the opportunity of examining a large number of cases in which various defects or disturbances of vision were produced by local cerebral injuries. Every further individual observation has been in harmony with these conclusions, and I have not met with a single clinical fact that is in any way at variance with them. It is not my intention to place all my later observations before you, though they afford valuable confirmatory evidence of our contentions, but to select a certain number which will fill up some gaps in our previous communication.

Local Defects in the Fields of Vision

The most interesting and important of these are the central and paracentral scotomata. These are extremely common in all superficial and moderate injuries of the occipital lobes. When the poles of both hemispheres are injured central vision may be completely lost, while a unilateral wound produces homonymous scotomata in the opposite halves of the fields. In our previous communication we recorded several cases with central scotomata; since then I have seen very few of these and they have added nothing further to the facts we then presented to you. Paracentral scotomata due to unilateral occipital lesions are much more common, and especially those situated in the lower quadrants; so many of these latter have been already recorded by ourselves, by Marie and Chatelin and by others, that further examples are not necessary. One of the common types is a pure lateral paracentral scotoma, and as but few cases with this condition have been described I may put the following example forthwith:

CASE 1.—Private R—, 15104, was wounded on September 26, 1916, by a shrapnel ball which penetrated his steel helmet. He was unconscious for an hour or so, and stated that he was completely blind till the next day. He never noticed any subjective visual phenomena. He was admitted to a Base Hospital on the day following the infliction of the wound.

Wound.—There was a small penetrating wound from which softened brain extruded, immediately to the right of the middle line of the skull and 1 inch (2.5 cm.) above the inion. A radiograph revealed much depressed bone, but no foreign body. An operation was performed next day, and several fragments of bone as well as clots and pulped brain tissue were removed from the occipital pole. The recovery was rapid and uneventful. His visual fields were taken by a perimeter and a screen scotometer six days after the

infliction of the wound, and again a week later. There was then a large left homonymous paracentral scotoma to an object 7mm.² which reached the fixation point and extended outwards from it to about 25°. Its mesial border coincided with the vertical above the fixation point, but receded from it below this. Peripheral vision was unaffected, and the colour fields were normal in the right halves, but there was no perception of either red or green to the left of the middle line (Fig. 1).

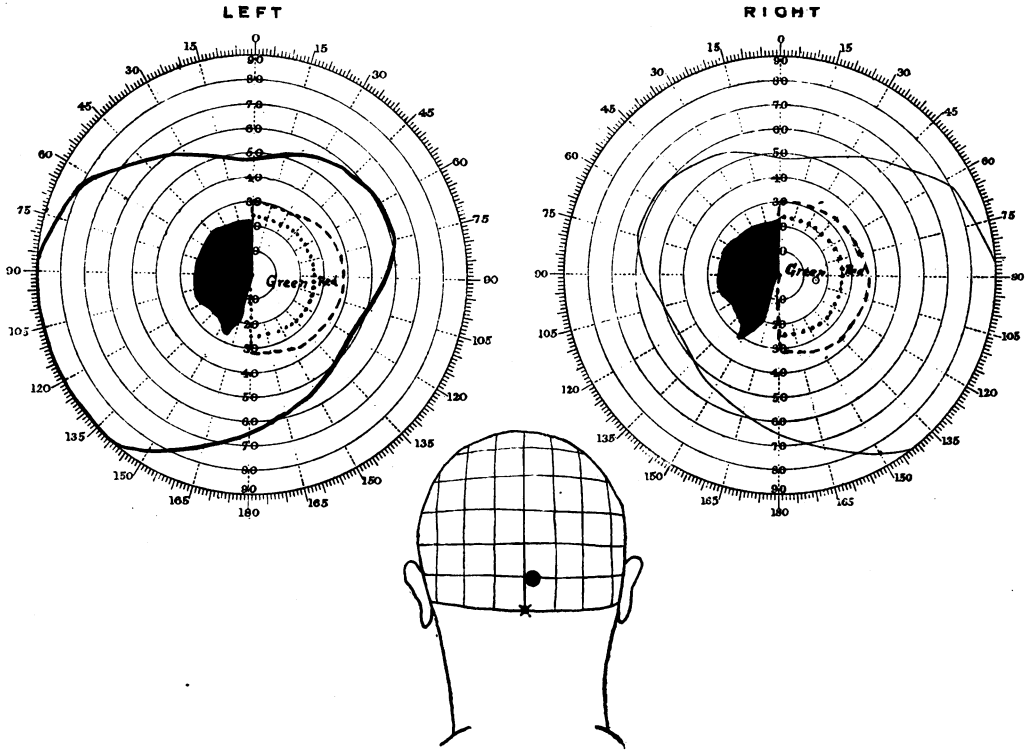


FIG. 1.

In this and the following figures the position of the wound of the skull is represented in a diagram of the head, and when missiles were retained in the brain their positions as seen in radiographic plates are also indicated. The vertical and horizontal lines in the diagrams represent distances in inches (2.5 cm.) from the inion as measured on a normal head.

In this case a lesion of considerable size in the occipital pole at the level of the posterior end of the calcarine fissure consequently produced an homonymous lateral scotoma, and the blind area extended immediately up to the fixation point.

Inferior Paracentral Scotomata

So many cases of unilateral inferior paracentral scotomata have been already recorded that it is unnecessary to describe more at present; in all these patients the injury involved the tip or posterior portion of one occipital lobe at or immediately above the level of the calcarine fissure, and the size of the scotoma generally stood in

close relation to the depth of the wound. Certain cases of bilateral inferior scotomata which I have seen deserve, however, mention, as they afford valuable evidence on the question of cortical localisation.

CASE 2.—Private B.—, 1822, was wounded by a rifle bullet which passed through his steel helmet on July 15, 1916. He did not become unconscious, but noticed almost at once "expanding red rings, like the rings you may see when you throw a stone into a pool," in front of his eyes. These remained only a few minutes. Since then he was aware of a considerable disturbance of vision in the right eye; his left eye had been amblyopic and almost useless since childhood. He complained of, and showed no other symptoms. *The wound* was a shallow gutter 2 inches long, which crossed the middle

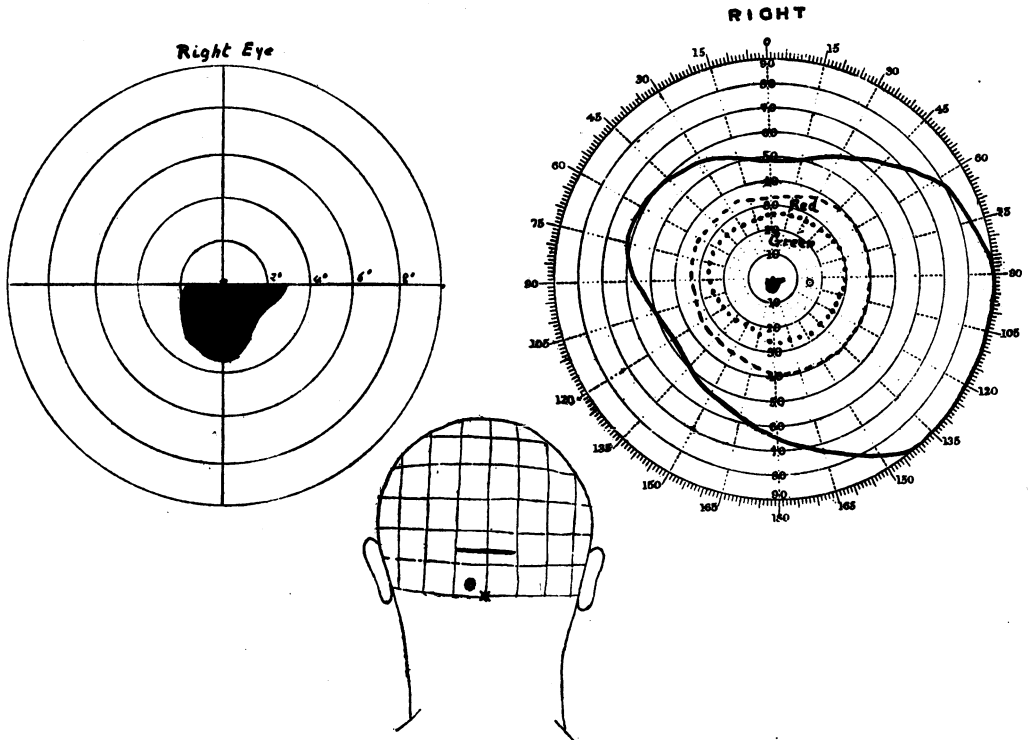


FIG. 2.

White 5 mm.² Red and Green 10 mm.²

line and was bisected by it, $1\frac{1}{2}$ inches (3.7 cm.) above the tip of the inion. A radiograph revealed a fracture and a slight depression of the skull. When he was examined two weeks after he received the wound his visual disturbances were the only abnormal symptoms he presented. On perimetric examination the peripheries of the fields for white (5mm.²) and colours (10mm.²) were found unrestricted, but by the scotometer a small absolute scotoma for white and colours was detected below the fixation point. It extended into both the right and the left halves of the visual fields to about 2°, and downwards to about 3°; it reached exactly to the fixation point (Fig. 2). The borders of this scotoma were remarkably sharp; when a test object was moved from the scotomatous area into the seeing part of the field the patient described it as if "the object suddenly passed from behind a curtain." The areas blind to white and to colours were practically identical.

In this case the lesion obviously involved the margins of both occipital lobes slightly above the level of the calcarine fissures and produced a bilateral inferior scotoma.

CASE 3.—Private L— was wounded on May 12, 1917, by a fragment of shell. He was wearing a steel helmet at the time and the missile passed through it. He was dazed but not unconscious. He states that he was blind for five minutes or so; since then was not aware of any disturbance of vision, but he suffered much from headache and was in a dull irritable state. The wound was a deep gash 3 inches (7.5 cm.) long across the middle line, slightly higher on the right side than on the left, which crossed the middle line $1\frac{1}{2}$ inches (3.5 cm.) above the point of the inion. Stereoscopic X-ray plates showed a depressed fracture under the wound. He was operated upon on the

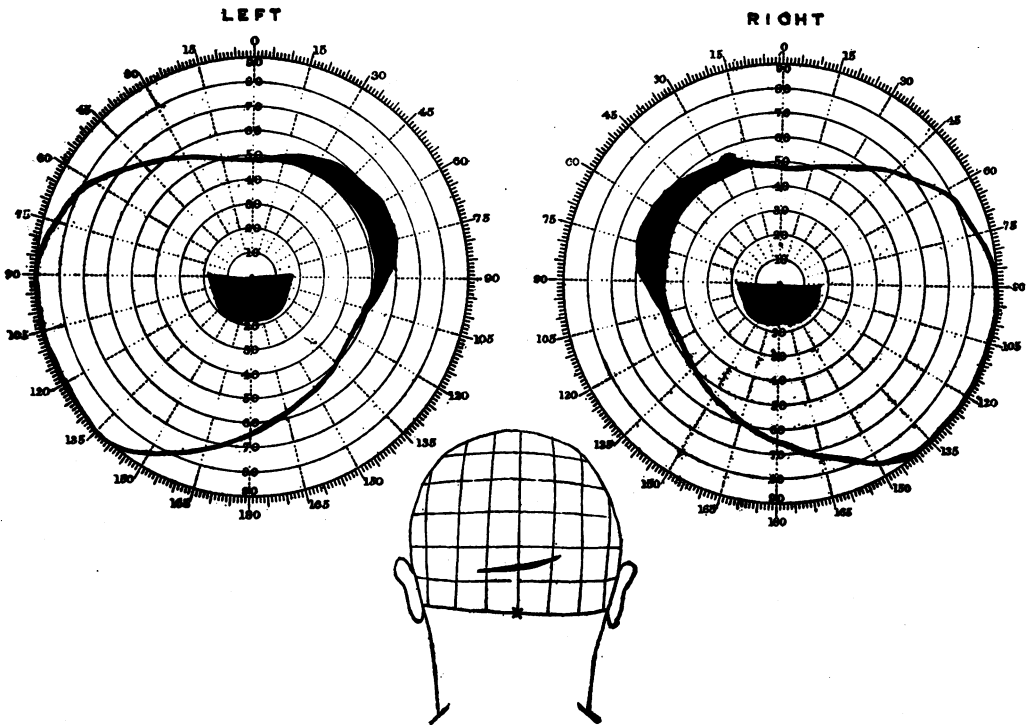


FIG. 3.

White 6 mm.²

third day; the scalp wound was excised, a flap was turned down, a trephine opening made, and a considerable area of depressed inner table was removed. The dura mater was lacerated most extensively on the right side.

He was at first so dull that his vision could not be properly examined, but before the operation he had certainly a large bilateral inferior paracentral scotoma which gradually diminished in size from below upwards. Sixteen days after the infliction of the wound, when he was again bright and intelligent and the operation wound was healed, a perimetric examination revealed only a bilateral inferior paracentral scotoma which reached the fixation point and extended 15° to 17° in every direction. His central vision and the peripheral limits of his visual fields were normal (Fig. 3). He presented no other signs of cerebral disturbance.

In this case, too, the lesion which produced a bilateral inferior scotoma lay above the level of the calcarine fissures, and involved the posterior portions of both hemispheres in this region.

CASE 4.—Private G—, 718, was wounded on June 24, 1916, by a rifle bullet. He was not wearing a steel helmet at the time. He was unconscious for half an hour. Next morning he found his sight very much affected, but he had no subjective visual sensations. He had very little headache, and presented no other symptoms.

The wound was a superficial horizontal gutter, $1\frac{1}{2}$ inches (4 cm.) long, across the middle line, 1 inch (2.5 cm.) above the inion. An X-ray examination showed a fracture

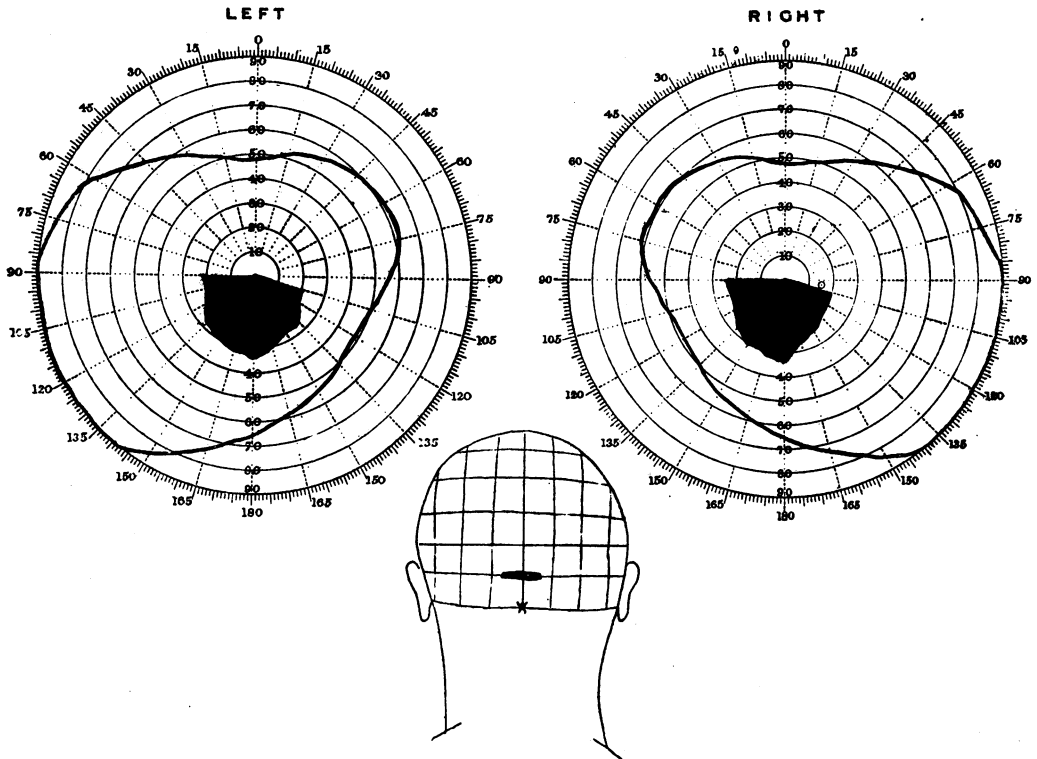


FIG. 4

L. 6/12. R. 6/12.

White 5 mm.²

of the skull, and depression of fragments to a depth of about $\frac{1}{4}$ inch (6 mm.), chiefly on the right side.

When he was examined, 10 days after the infliction of the wound, he was sensible and intelligent, had no headache, and presented no abnormal cerebral symptoms apart from the disturbance of vision. His central vision was 6/12 in each eye. Perimetric examination showed no restriction of the periphery of the visual fields for white (test object 5 mm.²), but it revealed a complete scotoma which extended from the fixation point downwards in each half of the visual fields to about 30° (Fig. 4). It reached upwards exactly to the fixation point.

Here both the position of the wound and the radiographic examination made it obvious that the posterior margins of both

occipital lobes were injured at, or immediately above, the posterior ends of the calcarine fissures.

These three cases support strongly the conclusions we have already arrived at, that the upper halves of the retina are represented in the dorsal parts of the visual areas, and that the macula and the zones of the retina immediately surrounding it are projected on the most posterior part of the area striata. It is impossible to estimate exactly, even when an operation has been performed, the extent or depth of the injury to the brain in any case of gunshot wound of the skull; but in many of my patients, as in Case 2, it was probably small and superficial, and probably did not affect the mesial surfaces of the hemispheres. It is, consequently, likely that the zones of the retina immediately around the macula are represented in that portion of the area striata which extends on to the lateral and posterior surfaces of the hemispheres.

Superior paracentral scotomata

Isolated superior paracentral scotomata are much less common. Lister and I were able to describe only two cases 18 months ago;

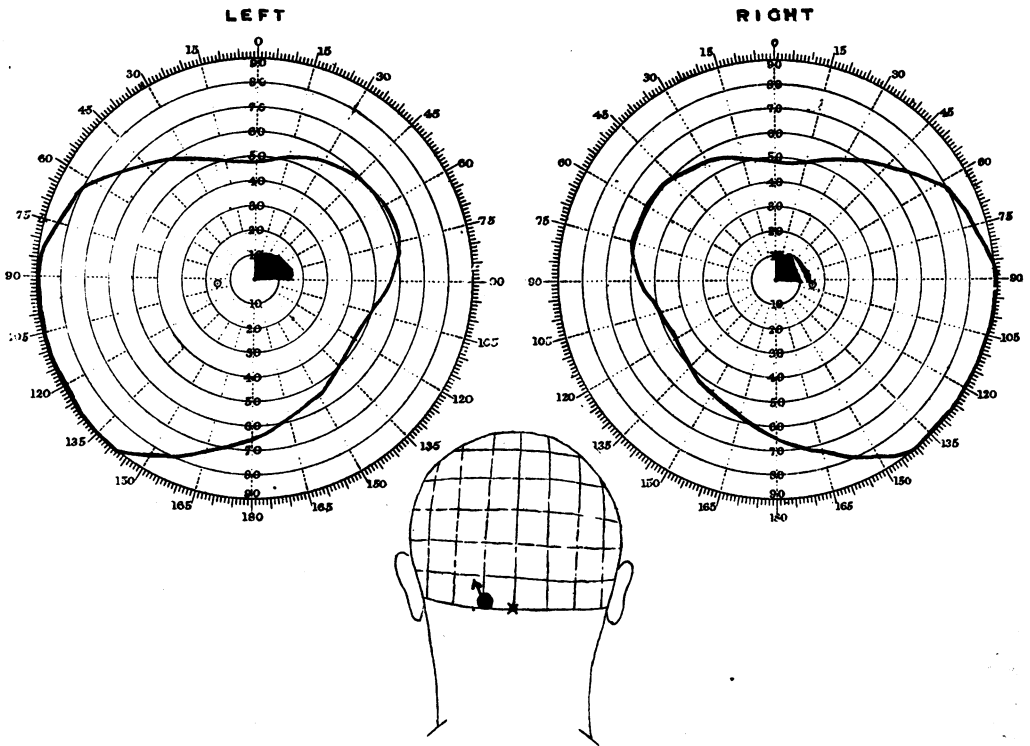


FIG. 5.

Marie and Chatelin have also described two, and Riddoch one other case. In all these patients the lesion, as far as could be determined, involved the lower part of the area striata, and they therefore indicate that the retina immediately below the macula is represented in the lower portion of the calcarine area. The three cases I can now add to these go to confirm this assumption.

CASE 5.—Private W—, 3262, was wounded by a fragment of shell-casing on October 20, 1916. He did not become unconscious, and was able to walk to the dressing station with a little help. There he found he could not see properly; he was unable to recognize the food placed in front of him, but he did not notice any mist in front of his eyes, or other subjective visual phenomena. The disturbance in vision diminished rapidly during the first few days. He had much headache at first, but this soon disappeared. *The wound* was a small puncture over the left lateral sinus, one inch (2.5 cm.) to the left of the middle line. A stereoscopic X-ray examination revealed a defect in the skull over the left lateral sinus, a piece of bone depressed beneath it, and a small fragment of metal under the left parieto-occipital suture, some distance from the middle line. He had also a penetrating septic wound of his left knee-joint which necessitated amputation through the thigh.

There were no local cerebral symptoms apart from his visual disturbance. When he was first examined ten days after the infliction of the wound, he was not aware of any visual defect, and his central vision was 6/6 in each eye. A perimetric examination also showed that the peripheral limits for white and colour vision were normal. A complete scotoma for white, red and green (objects 7.5 mm²) was, however, found in the right upper quadrants; the blindness extended to the fixation point and peripheralwards for about 15°. The visual fields were again investigated by a scotometer three weeks after he received the wound, and then the only difference detected was a slight restriction in the periphery of the scotoma; it still extended up to the fixation point (Fig. 5).

The headache had now disappeared, and he presented no symptoms of an active cerebral lesion.

The course of the missile in this case was such that it must have injured the posterior lower and inner portion of the occipital pole, and consequently it probably involved the lower and posterior part of the area striata.

CASE 6.—Captain T— was wounded by a fragment of shell-casing on July 1, 1916. He was not unconscious. After the first few days he complained of no symptoms, and was unaware of any visual disturbance, but about three weeks later began to suffer with increasing headache, and then a slight degree of optic neuritis developed.

The wound was an oblique gutter, 1½ inches (3.8 cm.) long, which extended from the upper margin of theinion to the right and slightly upwards. A radiograph showed a depressed fracture. This was later operated upon by Captain Burrows, who found an extensive extradural clot. The dura was bruised but not lacerated; it was not incised. He made an uneventful recovery.

When his eyes were examined four weeks after the infliction of the wound, he was not conscious of any visual disturbance, but a small absolute paracentral scotoma, which extended from the fixation point to about 4°, was found in both left upper quadrants. This absolute scotoma reached slightly below the horizontal line, and was here continuous with an area in which vision for small white objects (7 mm²) was very imperfect, and colour vision was lost. The peripheral limits of both white and colour vision were normal in both eyes (Fig. 6).

Here the posterior tip of the right occipital lobe was certainly contused and compressed by the depressed fracture and extradural clot, and from the position of the wound it may be assumed that

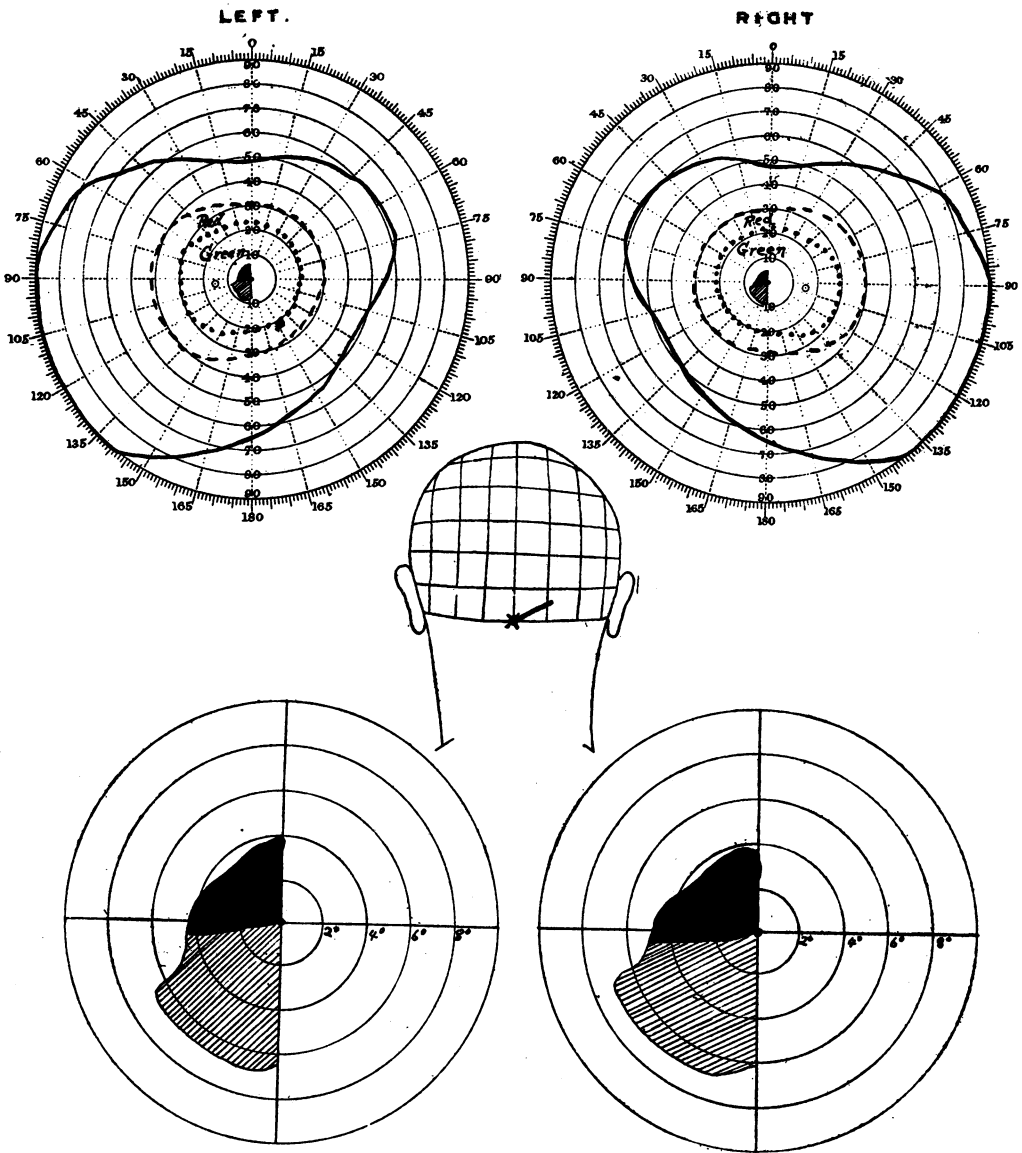


FIG. 6.

the lesion lay mainly below the level of the posterior end of the right calcarine fissure.

CASE 7—Private M—, 3282, was wounded by a fragment of shell, which entered under his steel helmet, on July 26, 1916. He was unconscious for a short time only, and later found that he "could hardly see at all; I could see men, but could not recognize them." There seemed to be a mist in front of his eyes, but he observed no flashes of light or other subjective phenomena. An operation was performed at a

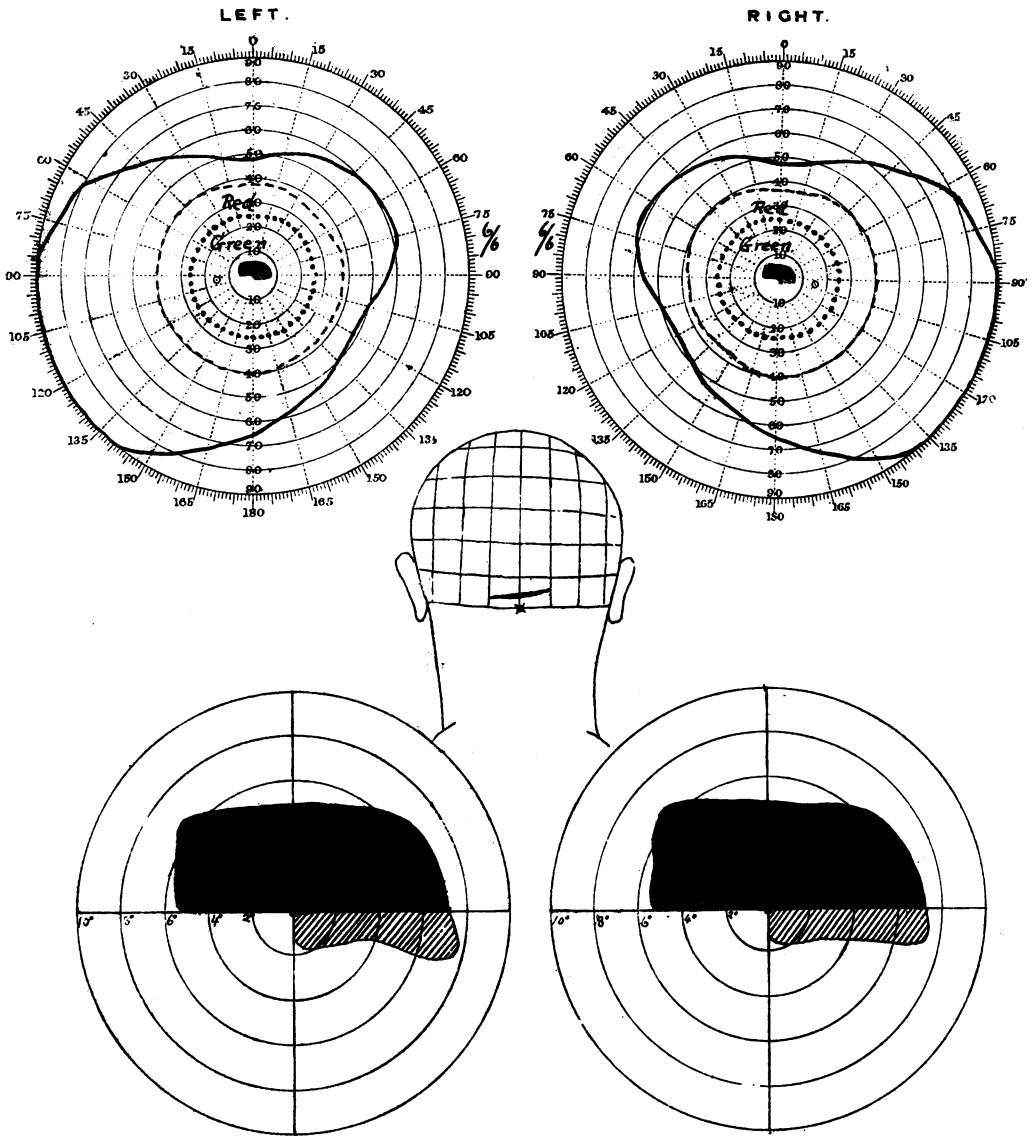


FIG. 7.

L. and R. 6/6. White 7 mm.² Red and Green 10 mm.²

casualty clearing station soon after the infliction of the injury, but the note which accompanied him merely stated "decompression over the occipital region; wound closed with a small drainage tube in its centre." He came under observation four weeks later.

The wound was represented by a healed horizontal scar, 2 inches (5 cm.) in length, which was slightly higher on the right than on the left side, and crossed the middle

line $\frac{3}{4}$ inch (1 cm.) above theinion. A defect in the skull could be felt beneath it on each side of the middle line.

His vision was now 6/6 in each eye, but he had still considerable difficulty in reading. His visual fields were examined by a screen scotometer as well as by a perimeter. The peripheral limits for white, red, and green (test objects 7mm²) were normal, but there was an absolute paracentral scotoma of equal extent for white and colours above the fixation point. This extended to 6° or 7° to the right and left of the fixation point, to 5° above it, and reached exactly to it (Fig. 7). An area of partial blindness to white, and complete to colours, extended from this absolute scotoma below the horizontal line in the right halves of the visual fields.

It was impossible to ascertain the exact degree of the injury in this case, but the position of the wound and the defect in the skull indicate that the brain was damaged superficially on both sides of the middle line, immediately below the posterior ends of the calcarine fissures.

These cases of superior paracentral scotomata were all associated with, as far as can be judged from the position of the wound and from radiographic examination, lesions of the inferior portion of the occipital pole; in each case the local injury was probably small and affected chiefly the cortex, or the cortex and subcortical white matter, below the level of the calcarine fissure. They are consequently evidence that the inferior halves of the retinae are represented in this area.

It is a striking fact that in the majority of paracentral scotomata the blindness extends directly up to or to within 1° or so of the fixation point, but this is not always so. I have seen cases, and Marie and Chatelin have recorded others, in which the scotoma was separated from it by an appreciable zone of vision. The question, however, arises why the area of central vision is so commonly affected by these traumatic injuries. Two explanations might be involved; because the macula is projected on to a part of the visual cortex which is likely to be damaged by all injuries of the occipital region; or because macular vision, being very highly specialized, has a relatively much more extensive cortical distribution than has peripheral, just as the cortical motor areas for the finger and thumb movements are both absolutely, and relatively to the bulk of the muscles they innervate, very much larger than that of other parts of the body. Both explanations are probably correct. The evidence at present available goes to show that the macula is represented at the occipital poles of the hemispheres, and probably on their posterior and lateral surfaces, and this is the region which must be involved by lesions which produce such scotomata as are described here.

Additional evidence that the upper halves of the retina are represented in the dorsal parts of the visual areas is furnished by a case of inferior horizontal hemianopia in whom an autopsy was obtained 7 weeks after the infliction of the wound.

CASE 8.—Sergeant K—, 679270, was wounded by a fragment of shell-casing on July 23, 1917. He was unconscious for some hours and later found his vision much affected, but he could recognize and distinguish persons.

Wound.—There was a small penetrating entrance wound $2\frac{3}{4}$ inches (7 cm.) above theinion and 2 inches (5 cm.) to the right of the sagittal suture, while the exit, which had been operated upon, was a much larger wound with its centre 4 inches (10 cm.) vertically above the tip of the left mastoid. When admitted to the Base Hospital he had marked loss of visual orientation in space; he was unable to recognize accurately the relative and absolute positions and distances of objects by sight alone. This persisted

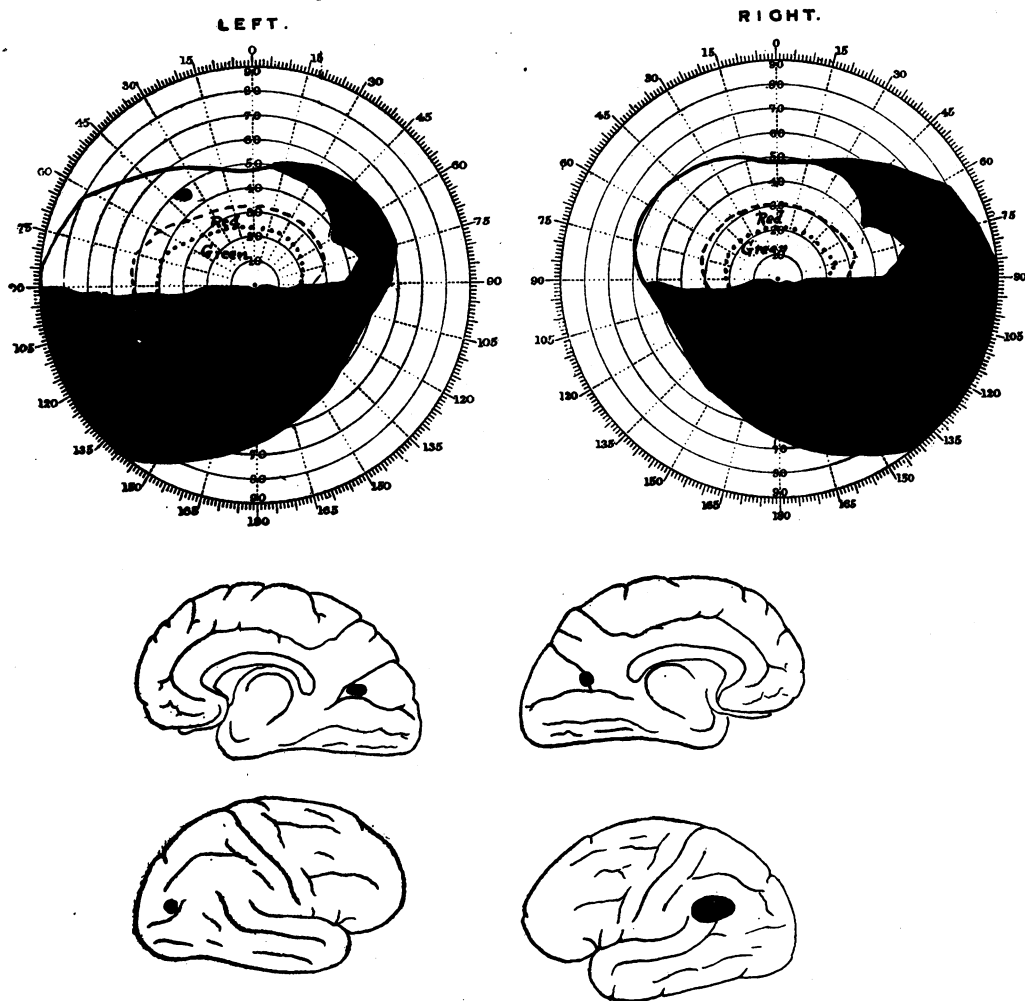


FIG. 8.

L. and R. 6/12 and J. 1.

till his death, and made an accurate exploration of his visual fields difficult. A full record, was, however, obtained 4 weeks after the infliction of the wound, and subsequent perimetric observations showed no change. His central vision was 6/12 in each eye and Jaeger 1. There was complete blindness in both lower quadrants, the blind area terminating sharply at or just below the horizontal line through the fixation point (Fig. 8). The blindness came to within 1° of the latter. In the right upper quadrants peripheral vision was restricted to about 50° , and white and coloured objects were seen

less distinctly in the remaining portions of this quadrant than to the left of the vertical line. The colour fields were, however, normal in both upper quadrants.

He died from other causes seven weeks after his injury. On examination of his brain the entrance wound was found in the middle of the lateral surface of the right occipital lobe some distance behind the level of the parieto-occipital notch. From here the missile passed through the dorsal parts of the optic radiations and emerged on the mesial surface of the hemisphere in the angle between the calcarine and the parieto-occipital fissures. The track of the missile was small and it had produced relatively little softening around it. The missile then entered the mesial surface of the left hemisphere in the parieto-occipital fissure, the destruction it produced reaching to 0.5 cm. of the calcarine fissure, passed through the dorsal portion of the optic radiations, and made its exit through the anterior portion of the gyrus angularis. On this side there was a considerable area of destruction, especially under the operation wound.

In this case the blindness in the inferior quadrants was probably due to destruction of the dorsal portions of the optic radiations, and the defect in the upper right quadrants to additional damage of the left optic radiations by the softening under the gyrus angularis; but the fact that there was no restriction or amblyopia of the left upper quadrants, despite the presence of a lesion in the dorsal and anterior part of the right visual area, permits the assumption that no part of this quadrant is represented in the dorsal portion of the calcarine cortex.

Sector scotomata

We have now, I believe, sufficient evidence to conclude that the upper halves of the retina are projected on to the dorsal parts of the visual areas, and the lower halves on to their ventral portions, while macular and perimacular vision are represented in the most posterior parts of these areas.

Other problems must be, however, considered, and they can be most easily studied in cases with paracentral scotomata. It is not uncommon, for instance, to find sector scotomata, that is isolated homonymous areas of blindness which are more or less accurately limited by two radii of the visual fields. Can we then say which portion of the visual area is injured? Here, again, in the absence of pathological confirmation, the localization of the lesions can be only approximate, and until a certain number of suitable anatomical examinations are available, our conclusions can merely have the value of hypotheses, but by the accumulation of clinical cases these hypotheses can be made more and more probable. As a rule, these sector scotomata lie between the vertical line through the fixation point, and one of the oblique radii, or, as in Case 1, only this area may escape. Patches of blindness bounded by the horizontal line through the fixation point and an adjacent radius are more uncommon. The following cases can, I believe, throw some light on this subject:—

CASE 9.—Private G—, 201700, was wounded by a shrapnel ball on August 12, 1917. He was in a drowsy and unconscious state for two days, and became aware that his sight was affected when he reached a Base Hospital on the third day. He then found

that he could not see sufficiently well to read or write, though he was able to recognize large objects in the ward. He had never any subjective visual phenomena.

Wound.—There was a circular contused wound just to the right of the middle line with its centre 3 cm. above the point of theinion. Radiographic plates showed a whole spherical shrapnel ball within the brain; it had passed to the left, and slightly upwards and forwards, and lay about 1.5 cm. to the left of the middle line, about 2 cm. in front of the occipital bone, with its lower border 5 cm. above theinion. Soon after his admission to the Base Hospital an operation was undertaken; some fragments of depressed bone were removed from the mesial surface of the right hemisphere, but on drawing out one which had penetrated the torcula, severe haemorrhage occurred which made plugging necessary, and prevented further operative interference. Uninterrupted recovery took place.

His visual fields were first carefully examined five weeks after the infliction of the wound. This was then healed completely; he had no headache or cerebral symptoms, apart from the disturbance of vision of which he himself was scarcely aware. His central vision was 6/9 in each eye, but perimetric observation revealed in each eye a complete right-sided inferior quadrantic hemianopia extending to $1\frac{1}{2}^{\circ}$ from the fixation point, and a sector-shaped inferior left paracentral scotoma which lay between the inferior vertical line and the radius at 45° to it; it came to within 4° of the fixation point. The colour fields were normal except in the blind areas (Fig. 9).

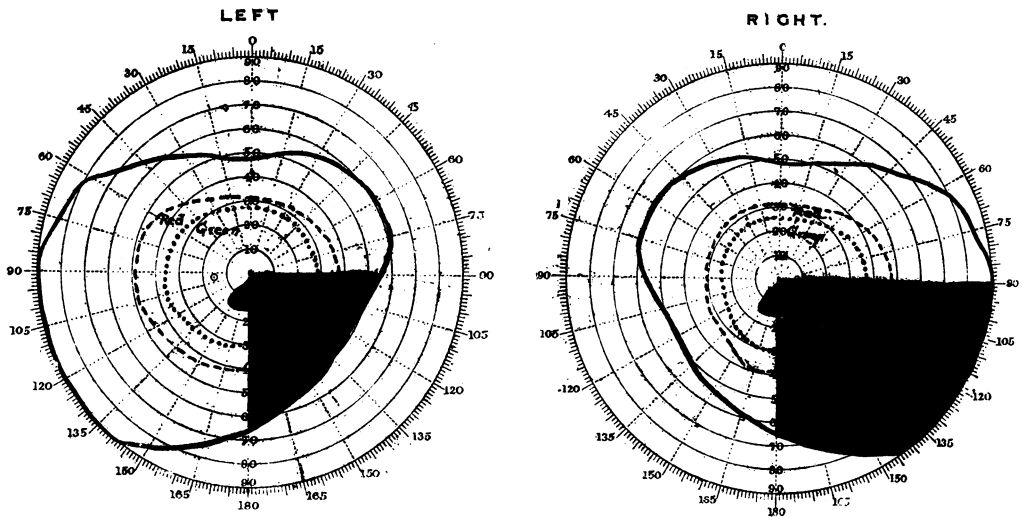


FIG. 9.
White, Red, and Green 7 mm.²

In this case the right lower quadrantic hemianopia was obviously due to the extensive lesion produced by the shrapnel ball in the mesial part of the left occipital pole above the level of the calcarine fissure. As the bullet entered near the middle line and passed obliquely upwards and to the left, the injury to the mesial surface of the right hemisphere was in all probability superficial, and must have affected chiefly the upper and posterior portion of the visual area on this side. The visual cortex buried in the calcarine fissure probably escaped direct injury.

This case consequently suggests that those portions of the retinae which lie along the superior vertical radii send their afferent

impressions to the dorsal portions of the visual areas which lie uncovered on the mesial surfaces of the occipital lobes.

CASE 10.—Private D—, 706542, was wounded by a fragment of shell on August 27, 1917; he did not become unconscious, and at once found he was completely blind, "everything was black in front of my eyes." Twenty hours later he found he could see moving objects to each side, but not directly in front of him. He had never any subjective visual phenomena.

Wound.—The wound lay immediately to the right of the middle line and 1 inch (2 to 3 cm.) above the inion; it was cleaned up and depressed fragments of bone were removed in a Casualty Clearing Station on the same day that he received the wound.

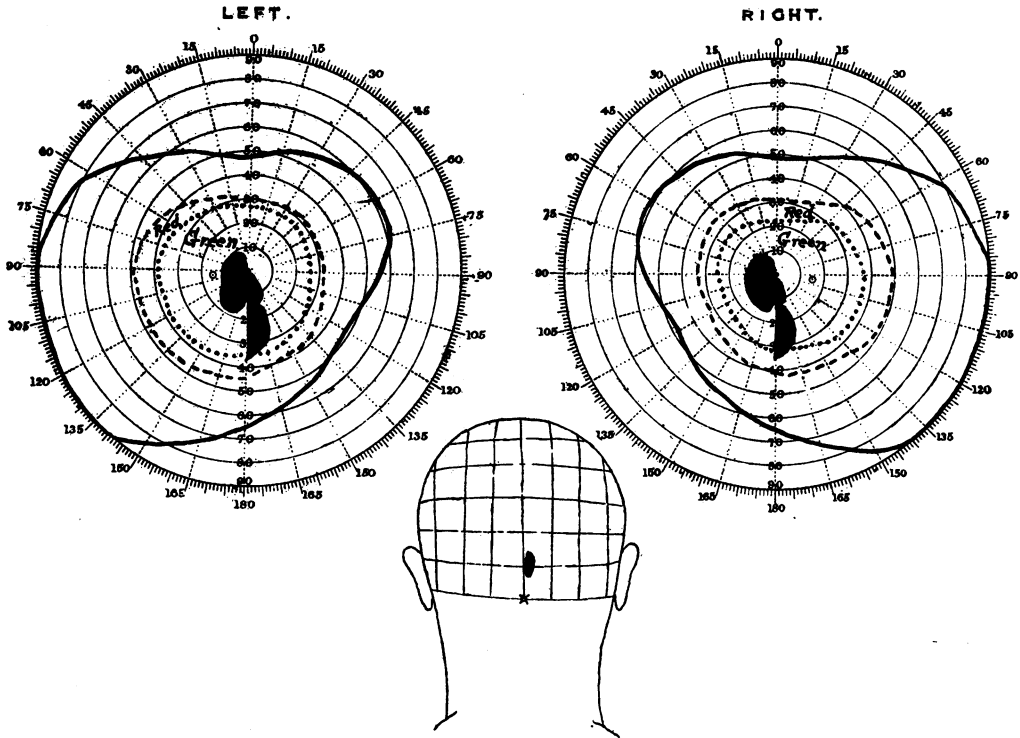


FIG. 10.
White, Red, and Green 7 mm.
L. and R. 6/9.

No missile was found, and a later X-ray examination did not reveal any foreign body within his skull. A second radiograph taken in the Base Hospital revealed a trephine opening immediately to the right of the middle line with its centre 1 inch (2.5 cm.) above the inion, and two fragments of bone which were driven through the falx cerebri across the middle line above the level of the calcarine fissure.

He was first seen in a Base Hospital ten days later. His wound was then almost healed, and he did not complain of headache or any cerebral symptoms. His central vision was, however, defective, and vision was completely absent in the greater part of the left halves of his fields.

On the twenty-second day his central vision had recovered to 6/9 in each eye and there was no contraction of the peripheral fields to either white or colours, but careful examination with the screen scotometer revealed a left-sided paracentral scotoma in both the upper and lower quadrants, and an irregular sector-shaped scotoma in the mesial portion of the right inferior quadrants (Fig. 10).

In this case the left-sided paracentral scotoma was evidently due to the injury to the right occipital pole, while the inferior right scotoma can be most easily explained by the injury which the mesial surface of the left occipital lobe must have received from the fragments of bone which were driven through the falx cerebri. Their position, which could be accurately localized on the radiograph plates, corresponded to the upper margin of the trephine opening, and consequently they probably affected only the most dorsal part of the visual area.

In this case, as in the preceding one, we also find an irregular sector scotoma lying between the inferior vertical radius and a neighbouring one, which was probably produced by a lesion of the most dorsal zone of the visual area.

CASE 11.—Private H—, 31902, received, on June 14, 1917, a gutter wound from a rifle bullet, which passed beneath his helmet. He was unconscious for a time, and later found that he was quite blind; he never noticed flashes of light or other subjective visual phenomena. He became able to see moving objects on the third day, and his vision improved progressively from this day, especially after the operation.

Wound.—There was an apparently superficial gutter wound about 1 inch (2.5 cm.) above his inion, but an X-ray photograph revealed a large depression of the skull on to his occipital poles. An operation was performed, and it was found that the internal occipital protuberance, together with the internal occipital crest and a considerable portion of surrounding bone, was driven into his left occipital lobe, and through the longitudinal sinus and falx cerebri. He made an uninterrupted recovery, but was kept under observation for three months after the infliction of the wound.

His vision was first examined six weeks after he received the wound. Then he had an almost complete right-sided hemianopia, in fact he was able to recognize only moving objects indistinctly in the upper margins of these fields. The hemianopia came exactly to the fixation point. His central vision was only 6/36 in each eye, and there were large paracentral scotomata extending to about 25° outwards from the fixation point in both the upper and lower quadrants, which did not, however, involve vision along the horizontal radii.

His visual fields were repeatedly taken both with the perimeter and the screen scotometer up to three months after the infliction of the wound. At the latter date there was a considerable return of vision in the periphery of the right halves of the fields; but here he was generally conscious only of the movement of the white test object, and saw it only "as through a mist," and as a "dirty grey colour." Central vision was now 6/18 to 6/24, and there were still paracentral scotomata in the left upper and lower quadrants. In the greater part of the lower the blindness was complete, but between the horizontal radius and that 30° below it he could recognize small white, red, and green test objects, but they did not appear distinct to him. The upper scotoma lay between the upper vertical radius and that at 45° to it; here he had no colour vision, and the appreciation of a white test object 8mm². was vague and uncertain (Fig. 11). There was no definite loss of peripheral vision to either white or colours in the left visual fields.

In this case there were, in addition to a large right-sided hemianopic scotoma, areas of complete and partial blindness to the left of the middle line, which, within 18° to 20° from the fixation point, spared only the macula and a triangular strip between the horizontal radius and that which runs upwards at approximately 45° to it.

The right-sided blindness was obviously due to the massive injury to the pole of the left occipital lobe, while the left-sided scotomata were probably produced by the contusion and destruction

of the right visual area by the fragments of bone which penetrated the falx. Macular vision escaped, as the most posterior part of the visual area was probably not severely injured.

If we assume from the two preceding cases that the upper and lower margins of the cortical visual areas receive light impressions from those portions of the retina which lie along the vertical radii, the persistence of vision in the neighbourhood of the horizontal radii might be explained by the escape of that portion of the visual cortex which is contained in the walls of the calcarine fissure, since the damage of the mesial surface of the right occipital lobe was probably superficial.

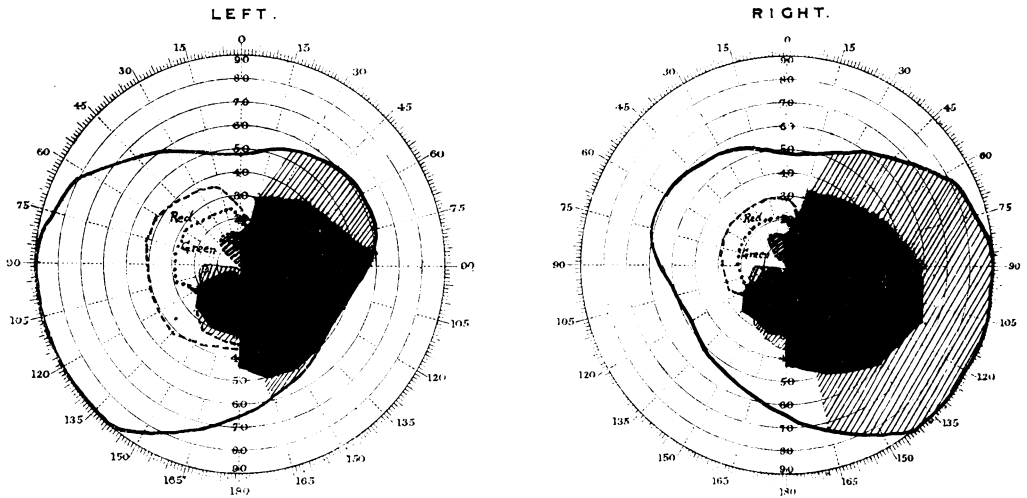


FIG. 11.

White 8 mm.² Red 7 mm.² Green 7 mm.²
L. 6/18-6/24 and R. 6/24.

CASE 12.—Private W.—, 52786, was wounded on September 20, 1917, by a fragment of shell, and is still under observation. He was unconscious for a short time, and on regaining consciousness found he was completely blind. He soon began to see again, but "out of my left eye only"; he noticed no lights, or colours, or other subjective phenomena, but everything he could see seemed to move. He had severe headache during the first few days, but this then subsided completely.

Wound.—There was a small circular scalp wound just to the right of the middle line, and 1 inch (2.5 cm.) above the inion. Radiographs revealed a circular defect in the middle line of the skull, 1 inch (2.5 cm.) above the inion, and a definite track leading from this forwards, slightly upwards and to the left, for a distance of 2½ inches (7 cm.) along which several fragments of depressed bone and metal lay (Fig. 12).

His wound healed rapidly, and all his symptoms, except the affection of vision, disappeared quickly.

His visual fields were repeatedly examined up to eleven weeks after the infliction of the wound; no appreciable change occurred during the last few weeks. His central vision was 6/24. There was a complete and absolute right-sided hemianopia which came directly up to the fixation point. In the left halves of his fields an inferior sector scotoma existed between the vertical and the radius at 15° to it, which came to within 1° of the fixation point and the horizontal radius, and a small isolated superior paracentral scotoma which reached almost to the fixation point. The fields for red and

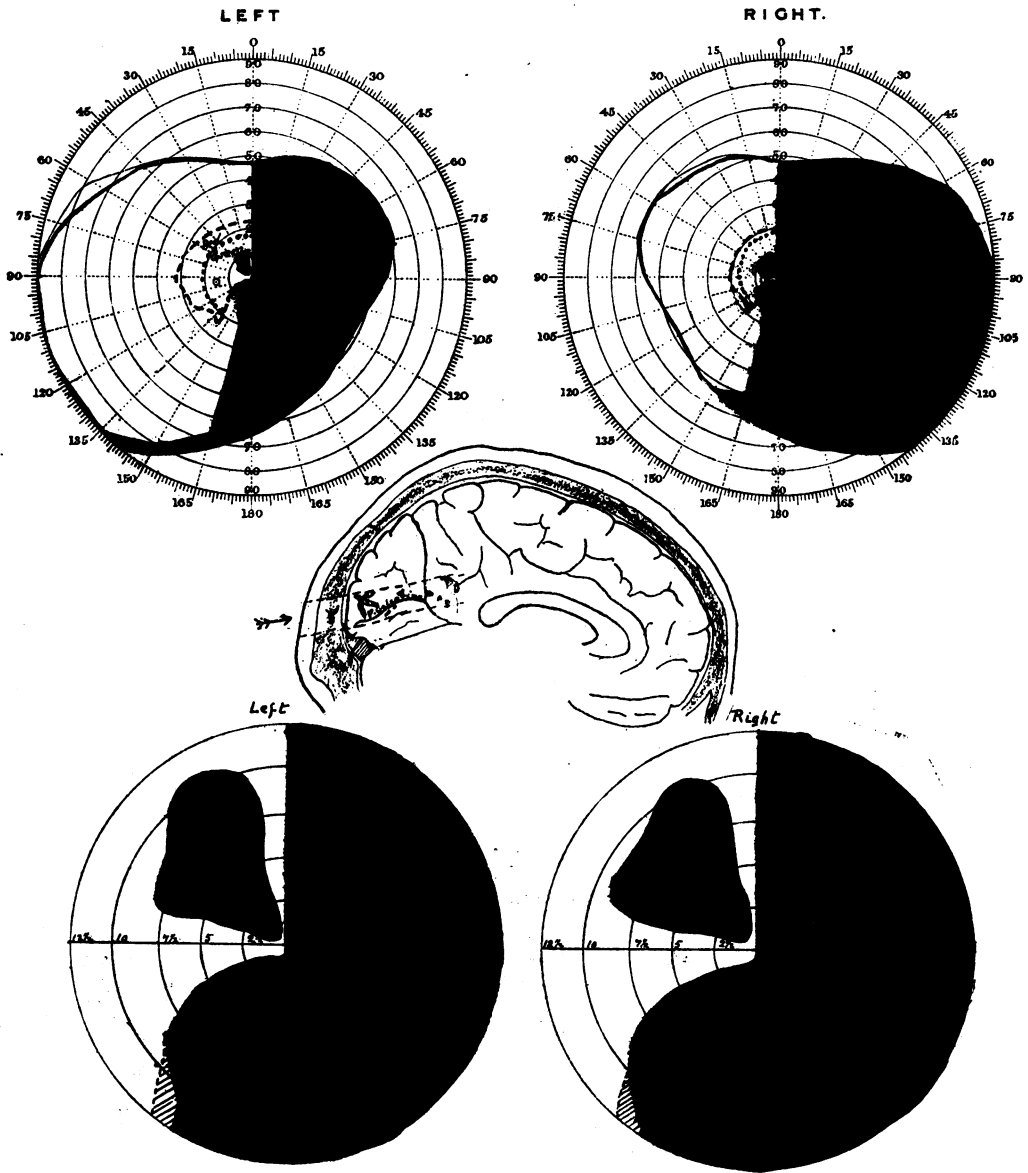


FIG. 12.

green were contracted in the lower quadrants, especially in the neighbourhood of the soft and indefinite borders of the blind areas (Fig. 12).

In this case the missile, which entered in the middle line of the skull, and passed forwards and to the left, produced a considerable injury of the left visual area, and consequently right hemianopia.

When a tracing of a lateral X-ray view of his skull was superimposed on a mesial sagittal section of a normal average head, it was found that the missile must have passed along and parallel to the posterior limb of the calcarine fissure, and must have destroyed both its cortex and its sub-cortical fibres. Owing to the position and the track of the wound, the injury to the right occipital lobe was certainly superficial; in all probability it did not involve the cortex in the walls of the calcarine fissure, and, as it produced an inferior sector scotoma, vision in this part of the field may be probably brought into relation with that portion of the visual area that occupies the upper free surface of the calcarine cortex.

Further, the only useful vision which the patient had to the left and within 10° of the fixation point, was on either side of the horizontal radii; it seems probable that this was dependent on the integrity of the more laterally situated cortex which is buried in the calcarine fissure.

Though these cases cannot, in the absence of anatomical examinations, be regarded as conclusive evidence, they tend to show that those portions of the retinae which lie along the vertical radii are represented on the exposed mesial surfaces of the occipital lobes, and by exclusion one might assume that the retinae on either side of the horizontal radii are projected on to the visual cortex which occupies the walls of the calcarine fissures. I cannot pretend to suggest how much of the retinal representation actually lies on the exposed mesial surface of the hemisphere; it is probable that anteriorly at least the proportion is small.

I have not yet met with a case of sector scotoma along the horizontal radius, excepting a few small paracentral scotomata which occupied this position; but if the hypothesis put forward here is correct, this is what might be expected, as any missile which had such a course that it would destroy the walls and floor of the calcarine fissure only, must injure also the afferent fibres to these portions of the visual area on the free surface of the hemisphere, and consequently produce a hemianopia or large irregular scotoma.

The cortical representation of peripheral vision

In my previous communication with Colonel Lister, we could only by a process of exclusion suggest that vision in the periphery of the fields was represented in the anterior portions of the cortical visual areas. We cannot expect to find many appropriate cases to decide this question definitely, as penetrating or perforating wounds which could injure the anterior portion of the area striata would be very liable to involve the optic radiations too, and cause extensive or irregular areas of blindness.

Riddoch has since then published a case which is of considerable value as positive evidence of the localization of peripheral vision.

In this man, in whom there was considerable peripheral contraction of both visual fields, a rifle bullet and, later, fragments of bone, were removed from the great longitudinal fissure between the two hemispheres, at such a level and depth that they probably injured the anterior portions of the calcarine areas. I have also recently seen a case which bears directly on this question.

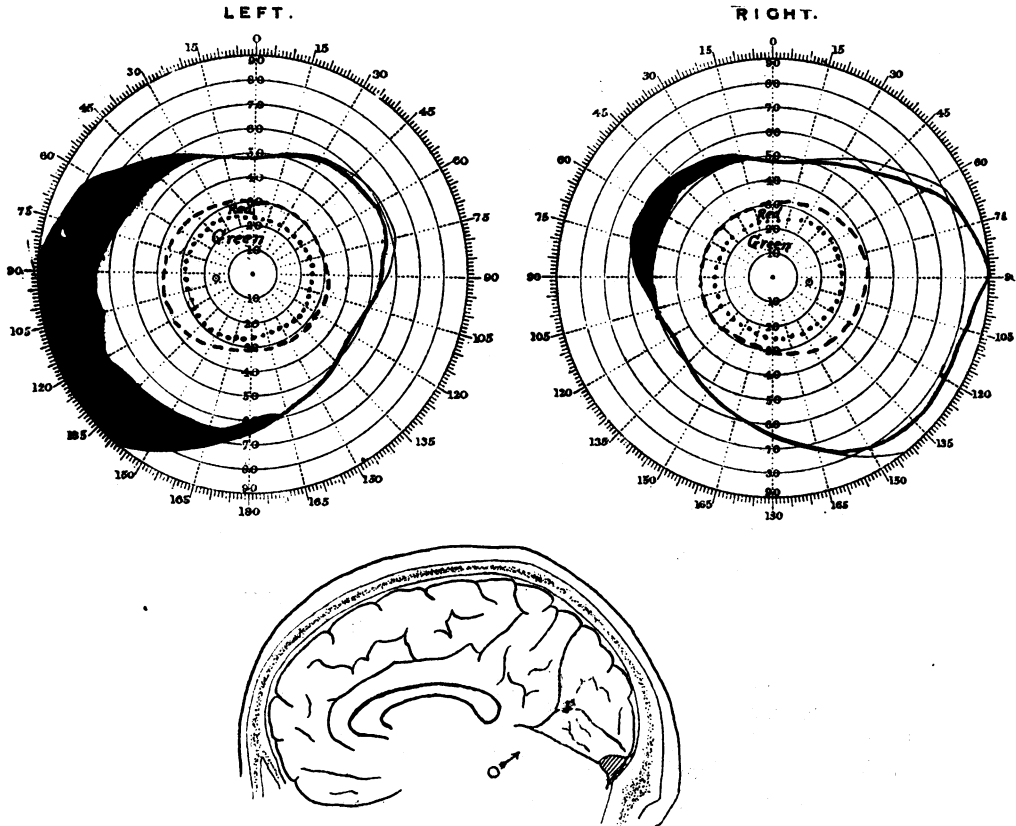


FIG. 13.

CASE 13.—Private M.—, 3841, was wounded by a small piece of shell-casing. He was unconscious for a time and later had considerable headache, but he noticed no affection of his sight.

Wound.—There was a small clean entrance wound just behind the base of his left mastoid. Radiographs showed a small fragment of shell-casing in the occipital region which had just crossed to the right of the middle line; it was probably arrested immediately it had passed through the falx. When a lateral X-ray photograph was superimposed on a mesial sagittal section of an average normal head, the missile was located in the calcarine fissure immediately in front of the parieto-occipital fissure (Fig. 13).

His visual fields were carefully examined on three separate occasions up to three weeks after the date he received the wound, and on each occasion exactly the same condition was found. This was a contraction of the temporal periphery of the left

visual field down to between 60° and 70°, and a slight contraction of the nasal half of the field of the right eye, which cannot be, however, regarded as certainly pathological. The colour fields were unaffected (Fig. 13).

It is true that in this case the peripheral contraction was relatively small, and the methods upon which we have had to rely for the localization of the lesion may give considerable errors. On the other hand, the boundaries of the visual fields were identical on the separate occasions upon which they were examined.

The course of the missile was such that it probably passed under the optic radiations of the left hemisphere and ventral to the visual cortex of this side.

These cases afford at least some positive evidence that peripheral vision is represented in the anterior portions of the calcarine areas; and when associated with the fact that peripheral vision is never affected by local lesions of the posterior part of this area, this hypothesis becomes extremely probable, provided that it is admitted that the visual sphere coincides, or is roughly approximate, with the area striata. Further cases that can furnish any evidence on the cortical representation of peripheral vision will be very valuable.

Visual Defects due to Lesions of the Optic Radiations

Destructive injuries of the optic radiations generally produce a complete hemianopia, in which the blindness may or may not reach the fixation point, or large irregular areas of blindness. Occasionally, however, the form of the visual defect is more regular, and such cases bear on the important question as to whether the fibres of the radiations that carry impressions from the retina and end in definite portions of the visual cortex are arranged in order according to the origin of the impressions they carry and to their exact termination.

I have now seen a considerable number of cases in which quadrantic hemianopias or other regular defects in the fields resulted from lesions of the radiations. The following two cases, in which direct injury of the calcarine cortex can be excluded, may be cited.

CASE 14.—Private S.—, was wounded by a shrapnel ball on April 9, 1917. He became at once unconscious. On regaining consciousness he had much headache and was dull and stupid for some time. He found his vision was affected, and had difficulty in reading: this was, however, not due to his being unable to see the letters, but to the fact that he had to spell them out one by one. No other disturbance of speech was observed.

The wound was circular, about 1 cm. in diameter, just at the attachment of the upper margin of the left helix. An X-ray examination showed a whole shrapnel ball in the left temporo-occipital lobe, probably lying on the upper surface of the tentorium, a short distance within the skull: in a lateral X-ray view it appeared to be midway between the inion and the upper margin of the petrous bone (Fig. 14).

He was first seen three weeks after the infliction of the wound. Then he had for a few days much headache, and ophthalmoscopic examination revealed a moderate degree of optic neuritis. The entrance wound was consequently explored, and some depressed fragments of bone were removed, one of which had penetrated the lateral sinus. From this time his condition improved, and his headache became less severe.

Examined six weeks after the injury, a complete superior right quadrantic hemianopia was found, which with the screen scotometer was seen to come to $2\frac{1}{2}^{\circ}$ from the fixation point, with a 7.5 mm.² object (Fig. 14).

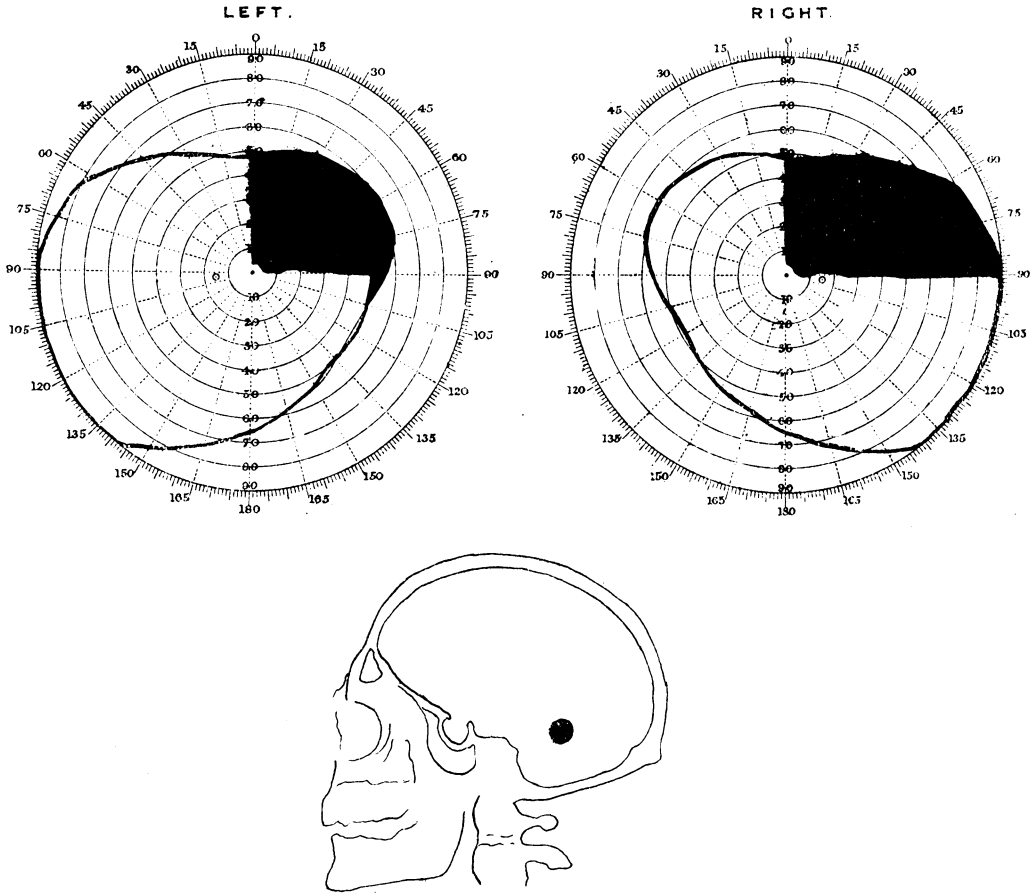


FIG. 14.
L. 6/6. R. 6/6.

In this case it is evident that only the lower portion of the optic radiations could have been injured, and their injury produced a pure superior quadrantic hemianopia.

CASE 15.—Pte. G.—, 3736, was wounded by two fragments of shell-casing on November 24, 1916. He became unconscious at once, and was later confused and disorientated.

He had much headache for a time, but this soon ceased; his temperature and pulse rate were normal from a week after the infliction of the wound.

His right eye was blind since the day on which he was wounded, owing to severe concussion changes in it, but he had been unaware of any disturbance of vision in his left.

Wound.—One wound was situated in the left temporal fossa, about two inches (5 cm.) behind the external angular process; and the second on the lower margin

of the right supra-orbital arch in its inner third. A stereoscopic X-ray examination showed, in addition to the local injuries, two pieces of shell-casing in the right occipito-temporal lobe near the lateral surface of the skull, just above and in front of the lambdoid suture, and 4 cm. in front of the inion. (Fig. 15). These missiles probably entered through the right frontal wound.

A perimetric examination, made four weeks after the infliction of the wound, revealed a complete left superior quadrantic defect in his left eye, which was limited exactly by the vertical and horizontal axes of the visual fields, and a slight restriction of the periphery of the upper part of the left lower quadrant. When a scotometer was employed, the blindness was found to reach exactly up to fixation point (Fig. 15). He was unaware of this large area of blindness; his central vision was 6/9.

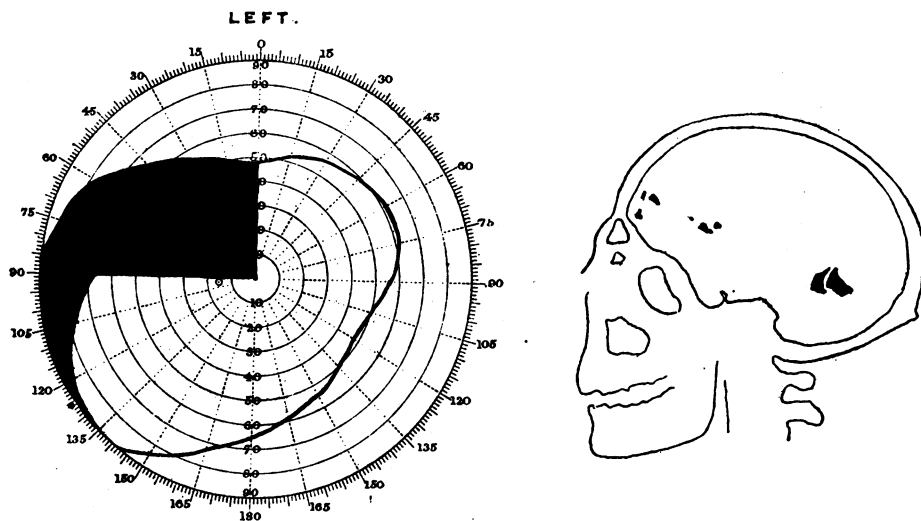


FIG. 15.

L. 6/9.

In this case the penetrating missiles could have damaged only the right optic radiations, and from their position it seems probable that only the lower fibres of these were involved.

In these two cases lesions of the lower parts of the optic radiations of one side produced superior quadrantic hemianopias, and it must be consequently assumed that those fibres of the radiations which carry impressions from the lower halves of the retinae pass through the ventral sections of the optic radiations. I have also seen several other patients in whom defects in the homonymous lower quadrants were associated with damage of the dorsal fibres of the radiations. The case of inferior horizontal hemianopia recorded above (Case 8), in which it was proved by autopsy that the missile actually passed through the dorsal portions of the radiations of both sides, is a good example.

We are consequently forced to the conclusion that the fibres of the radiations are arranged regularly in laminae or series according to the origin of the impulses they carry. The defects in the fields are so frequently quadrantic, despite the gross nature of the injuries,

that it is tempting to assume that even in the main mass of the radiations, those indirectly connected with the upper and the lower halves of the retinae are contained in distinct bundles, separated from each other by an anatomical interval; but this hypothesis seems *a priori* so improbable that it cannot be accepted without further evidence, and unless an anatomical basis for it can be discovered.

The course in the radiations of the fibres concerned with macular vision is another interesting point. Certain observations go to suggest that these have a distinct path of their own, but I have as yet seen no case in which a paracentral scotoma, or an isolated affection of central or pericentral vision, could be attributed to a lesion of the radiations.

The Nature of the Lesions—Concussion

We are now faced with the question, What is the nature of the lesions which have produced the visual defects that have been described above? In many of my patients the defects remained unaltered on repeated examination over considerable periods, but in others a progressive diminution of the blind area was observed, which was sometimes rapid but occasionally slow. In such a highly organized function as cortical vision it is extremely improbable that recovery can be ever due to vicarious representation, or the assumption of the function of the destroyed cortex by other parts; the fact that there is obviously an exact segmental projection of the retina in the visual cortex makes it difficult to understand how such vicarious representation could occur.

In those cases, as in many published by Marie and Chatelin, in which the defects are stationary and persist for a considerable time after the infliction of the wound, there can be no doubt that they are dependent on simple destructive lesions; as far as possible only such cases were selected to illustrate my arguments above.

It is not uncommon, however, in work in France, where the earlier stages of gunshot injuries of the head can be observed, to find a complete hemianopia or a large area of total blindness disappear during the course of a few days or weeks. Captain Hine has recently studied several of these cases with slight gunshot wounds of the parieto-occipital region, and has shown how the recovery of vision takes place. In his cases the visual fields were gradually restored by recovery from the centre to the periphery; and the restoration of function was at first incomplete, colour perception coming after the perception of white, even though the coloured test objects were larger. I have repeatedly observed the same condition, but, on the other hand, there can be no doubt that peripheral vision often reappears before central and pericentral; this is so particularly in cases in which a persisting scotoma remains. Riddoch's statement that "the recovery of the appreciation of movement begins in the

periphery of the field and extends inwards towards central vision" is certainly incorrect, as in both Hine's and my own cases the stimulus was a moving white or coloured object.

To what can these defects that tend to recover more or less quickly be due? We are constantly meeting with similar conditions in the affection of other cerebral functions by gunshot injuries of the head; it is extremely common, for instance, to see a limb paralysed for a few days as the result of a wound in or near the Rolandic region and then recover rapidly and completely. In certain of these cases observation during operation or post-mortem examination reveals a localized softening or pulping of the surface of the brain with more or less destruction of its tissue, but this can be rarely the cause when the recovery of function is rapid. Then the symptoms are generally attributed to the effects of concussion, though the exact connotation of this word is very vague. Kinnier Wilson, in a recent paper on the concussion injuries of the central visual apparatus, accepted contusion as the pathological basis of the condition known clinically as cerebral concussion, that is, temporary organic changes, as capillary haemorrhages, minute lacerations, and disintegrations of the myelin; and he states that after $2\frac{1}{2}$ years he has seen no case in which a blow on the head produced an uncomplicated visual commotio analogous to spinal concussion, or peripheral nerve commotio. I have shown that in the spinal cord this condition is due chiefly to oedematous swelling and degeneration of the myelinated fibres, often, it is true, associated with grosser lesions, as haemorrhages and focal softenings. In my opinion, which is based on a certain amount of pathological experience, analogous changes occur in the brain, and to them, especially to oedema, I would attribute many of the transient and recoverable symptoms. Whether a molecular disturbance which is not demonstrable by our present methods may be a factor, I cannot say, but the rapid and complete restoration of such a complex function as vision, which Hine, for instance, has shown to occur, at least argues in favour of an aetiological process which does not destroy or influence permanently the anatomical integrity of the functioning structures. This condition occurs frequently in the neighbourhood of destructive foci.

In my opinion, the total destruction of a portion of the visual area produces permanent loss of function in the corresponding parts of the visual fields; but part of the visual defects observed early after the infliction of gunshot wounds may be due to local cerebral concussion, using this word in its ordinary acceptation. Further, in these cases peripheral vision does not constantly recover before central, or vice versa, but when recovery takes place it occurs first in the least affected regions, generally in those most distant from the site of the impact, and progresses toward the most seriously concussed parts.

The Nature of the Disturbances of Vision

In all my cases in which the areas of defective vision are represented black on the charts, the blindness was total to both white and colours ; neither the presence nor the movement of any object of reasonable size could be recognized.

It is, however, common to find a zone of indistinct or partial vision around the scotomata or on the borders of a quadrantic or incomplete hemianopia. In these areas white test objects appear "indistinct" or indefinite to the patient, or "as though seen through a mist," or he may describe the test object as a "dirty grey" rather than white. Further, colour vision is almost always disturbed or lost unless very large objects are used, and even small white objects may not be recognized. This condition is frequently found in regions of the fields in which vision has recently recovered.

In the majority of my cases, however, which were examined more than three weeks after the onset of the blindness, the margins of the scotomata were remarkably sharp ; several patients, for instance, said when they first saw the object as it was moved from the blind into the seeing area that "it seemed to come suddenly from behind a screen," and that it was then as distinct and definite as it appeared when placed in the homologous part of the opposite field.

A study of the conditions actually existing in areas of incomplete vision is extremely interesting, especially in view of Riddoch's recent paper, in which he describes a dissociation of visual perception due to occipital injuries. The elementary visual perceptions of light, movement, the shape of an object and its colour, may be, according to him, dissociated in a manner similar to the dissociation of the primary sensory impressions of touch, pain, and temperature by a spinal lesion ; that is, these visual perceptions may represent different modalities of vision ; or they may be analogous to the disturbances of somatic sensibility produced by cerebral injuries.

My own observations on this subject are probably less complete than Riddoch's, and his contentions have raised certain points which I have not yet had time to investigate fully. I can, however, confirm his statements that the presence of a moving object may be recognized in portions of the visual fields in which it is not perceived when stationary, and in which its shape cannot be appreciated. But I have always found that the acuity of vision in these areas is considerably diminished ; the patient may be uncertain of the stimulus, or he may describe it as indistinct, or as if seen through a mist ; and on testing, it frequently happens that he responds only when the movement is abrupt and repeated, but fails to do so when it is slow and gradual. Further, colour vision is invariably affected in these areas.

It has been long known that the extramacular parts of the retinae are especially sensitive to moving objects; movement is, in fact, its specific stimulus. As William James says, "Its main function is that of a sentinel, which, when beams of light move over it, cries: 'Who goes there?' and calls the fovea to the spot." As far as my observations go, I would say that the condition described by Riddoch should not be spoken of as a dissociation of the elements of visual sensation, since it is only a condition of visual hypoaesthesia in which the stronger and more adequate stimuli alone excite sensations. Even in partial blindness, due to disease of the media, of the retina, or of the optic nerve, moving objects may be seen, though the patient does not recognize their presence when they are stationary.

An exact parallel can be found on the skin; when cutaneous sensibility is diminished, whether by a peripheral nerve, a spinal or a cerebral lesion, moving contacts can be often appreciated, although a stimulus of the same strength evokes no sensation, when it does not move over the surface. But this condition cannot be made analogous to the dissociations of the separate modalities of sensation produced, for instance, by spinal lesions.

The recognition of the shapes of objects is, unless they are very large, impossible or very indefinite in the periphery of our visual fields. I have made several observations on the recognition of shape in both normal persons and in patients with disturbances of vision of cerebral origin, employing such test objects as squares, circles, triangles, and hexagons of equal surface area, and I found that they cannot be recognized in the periphery of the fields; white objects of 1 cm.² can be rarely distinguished with certainty at a greater angle than 30° to 40° from the fixation point at a distance of half a metre, and if any local diminution in the acuity of vision exists, they must be approached still nearer to it before their shape can be recognized, though the patient may be aware of their presence when they move, or even while they are stationary. It was owing to hypoaesthesia of the affected parts of the retina, I believe, that the shape of the test objects could not be recognized by Riddoch's patients; occipital lesions do not produce true dissociations of function with intact retinal sensibility, although this may be caused by injuries of other parts of the brain.

Disturbances of colour perception by cerebral lesions

Abolition or diminution of colour vision has been frequently described as a result of cerebral lesions, but, as far as I am aware, it has not been conclusively shown that colour perception may be completely lost in any part of the field when that of light or white is undisturbed. Most of the hemiachromatopsias at least have been instances of hemiamblyopia; when small white test objects are used

the peripheral fields may be found to be restricted, or these objects appear to the patient indistinct or greyish, or they may in places pass out of vision. I have frequently observed among my cases that red and green test objects could not be recognised in certain regions, often in homonymous halves of the visual fields, but in every instance visual sensibility to white test objects of the same size was reduced. This condition was frequently found in a more or less narrow zone around or on one side of a scotoma, or in an area in which vision was recovering. During recovery the restoration of colour vision is frequently delayed, but, in my experience, sensibility to white is then always defective, too.

My observations, which extend over a very large number of cases, consequently tend to show that an isolated loss or dissociation of colour vision is not produced by cerebral lesions.

Congruity of the Visual Defects in the Fields of the Right and Left Eyes

It often happens that when the fields have been charted the defect produced by an occipital injury is found to be not entirely congruous in those of the two eyes. This is particularly common when the patient is suffering from a severe gunshot wound of recent date, and it may be then due to tiring and flagging attention on the part of the patient. In other cases the explanation seems to be that in the region in which the fields are not super-imposable there is a diminution of vision so that the stimulus is sometimes appreciated, sometimes not. When divergencies greater than those that can be explained by a reasonable margin of error in examination exist, I always doubt the accuracy of the observations and examine the patient again. From my experience, I believe that the defects in the fields of vision produced by occipital lesions are always more or less exactly congruous and identical.

We have now studied the forms and types of disturbance of vision produced by wounds of the occipital lobes, but other affections of vision, due to lesions of more anterior portions of the brain, also occur, to which reference may be made here, though time will not permit their detailed study.

Disturbances of Visual Attention

The most common of these is perhaps an affection of visual attention. This is a condition in which, though there is no demonstrable diminution of visual sensibility or restriction of the fields, the patient frequently fails to recognize objects brought into the affected homonymous halves of the fields, though they are perceived at once when introduced into the opposite halves. This

condition is usually associated with lesions of the parietal lobe, which generally involve the supramarginal gyrus or its neighbourhood. The following case illustrates this condition :

CASE 16.—Private A—, 12469, was wounded in June, 1917, by a fragment of shell-casing which entered over the middle of the right parietal lobe and lay embedded deeply in his brain. He was unaware that his vision was affected, and yet when examined on several occasions up to 2½ months after the infliction of the wound, the following disturbance was always found and remained unaltered.

His central vision was 6/6 in each eye ; his visual fields to small white and coloured objects were full, and these objects did not seem to him less distinct or otherwise different in the right and left halves of his fields. Further, he was able to recognize shapes and objects and indicate their position in space by pointing to them equally well on the two sides of the fixation point. When, however, the observer's hands were held up to each side of him equidistant from his visual axes, he always recognized immediately the slightest movement of the fingers of that hand on his right side, but he occasionally failed to reply when the fingers of the other were moved. And if the fingers of the two hands were moved simultaneously, almost invariably he perceived only those to his right.

Similarly if two pieces of white paper were simultaneously moved on his right and on his left sides, only that on the former elicited a sensation. It mattered not how large the moving object to his left was ; he was not aware of its presence or movement if that to the right also claimed attention. On one occasion, for instance, a piece of white paper, 1 by 4 cm., was held to his right side and a card, 10 by 7.5 cm., to his left, and yet when they were simultaneously moved he saw only the smaller one. Even when only the larger object was placed or moved in his left field of vision he frequently failed to recognize it in a long series of tests, but he always succeeded better when his attention was directed to it, either by command or by the statement that the object on this side only would move. And yet in this man there was no disturbance of visual sensibility, no raising of the threshold as far as it could be tested, and no defect in the appreciation of white and coloured objects.

Here we have a condition closely analogous to that described by Head and myself when cutaneous sensibility is affected by parietal lesions. Then there may be no actual loss of sensibility and no raising of the threshold, but when a series of stimuli are applied to the part, only a certain proportion of them is appreciated, and this more or less regardless of the intensity of the stimulus, provided it remains purely tactile. This state we described as "attention loss," and in vision we meet with a similar condition. Attention cannot be normally awakened or directed to the affected region, especially if it is claimed also by another stimulus, and the patient consequently neglects innocuous objects that affect this part. In some of my cases this condition of local visual inattention coexisted with a similar local tactile attention loss on the same side of his body, both being produced by the same parietal lesion.

Loss of Visual Orientation and Appreciation of Depth

Another form of visual disturbance is inability to orientate and localize correctly in space objects that can be perfectly well seen and recognized. I reported one such case with Captain Smith and I have since then seen six others. Riddoch has also described an excellent example due to a gunshot injury. In all these patients there were bilateral lesions of the parietal lobes, produced by

perforating or penetrating missiles; it seems that the condition is dependent on injury of the brain in the neighbourhood of the angular and supramarginal gyri, at least these parts were affected on one or both sides in all my cases.

The most prominent features of this condition, which I hope to describe more fully soon, were the inability of the patient to orientate in space objects which he saw; to recognize the relative and absolute distances of objects; and in some instances inability to appreciate by vision the depth and thickness of objects. These disturbances are frequently associated with difficulty or abnormalities in the movements of the eyes and especially in accommodation, and often with absence of the blinking reflex when an object was suddenly approached to the patient's face.

Visual agnosia, or inability to recognize objects by vision alone, has been also found associated with bilateral lesions of the posterior portions of the hemispheres. I have not seen this condition produced by a gunshot wound, but I have examined a few patients with injuries in the parieto-occipital region, in whom the recognition of objects seen to the opposite side of the fixation point was considerably affected. I have not, however, at present sufficient evidence to discuss this interesting question.

Conclusions

We are now in a position to draw certain conclusions on the localization and organization of the cortical centres of vision, and on the dissociations and disturbances of visual function that may be produced by lesions of different portions of the brain. All these conclusions cannot be regarded as final, but they may at least serve as working hypotheses for further investigations.

(1) The upper half of each retina is represented in the dorsal, and the lower in the ventral, part of each visual area.

(2) The centre for macular or central vision lies in the most posterior part of the visual cortex, probably on the margins and on the lateral surfaces of the occipital poles. The macula has not a bilateral representation.

(3) The centre for vision subserved by the periphery of the retinae is situated in the anterior portions of the visual areas, and the serial concentric zones of the retinae from the macula to the periphery are probably represented in this order from behind forwards in the visual cortex.

(4) Those portions of the retinae adjoining their vertical axes are probably represented in the dorsal and ventral margins of the visual areas, while the retina in the neighbourhood of its horizontal axis is projected on to the walls and the floor of the calcarine fissures (Fig. 16).

(5) Severe lesions of the visual cortex produce complete blind-

ness in the corresponding portions of the visual fields, or if incomplete an amblyopia, colour vision being generally lost and white objects appearing indistinct, or only more potent stimuli, as abruptly moving objects, may excite sensations.

(6) The defects of vision in the fields of the two eyes are always congruous and superimposable, provided that no abnormality of the peripheral visual apparatus exists.

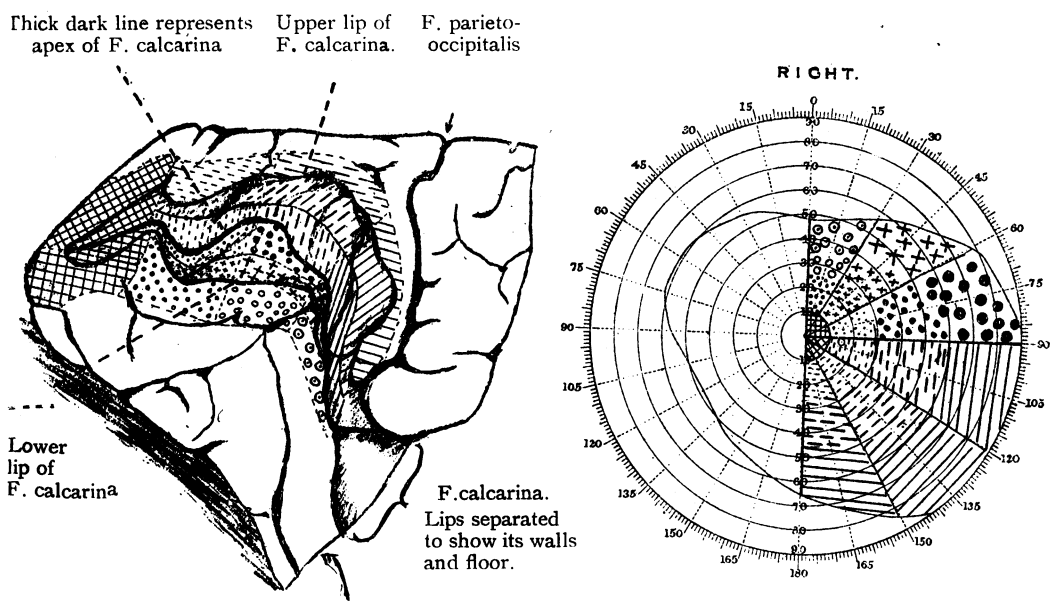


FIG. 16.

A diagram of the probable representation of the different portions of the visual fields in the calcarine cortex. On the left is a drawing of the mesial surface of the left occipital lobe with the lips of the calcarine fissure separated so that its walls and floor are visible. The markings on the various portions of the visual cortex which is thus exposed correspond with those shown on the chart of the right half of the field of vision.

This diagram does not claim to be in any respect accurate; it is merely a schema.

(7) Lesions of the lateral surfaces of the hemispheres, particularly of the posterior parietal regions, may cause certain disturbances of the higher visual perceptual functions with intact visual sensibility, as loss of visual orientation and localization in space, disturbance of the perception of depth and distance, visual attention loss, and visual agnosia.

REFERENCES

Head and Holmes.—*Brain*, 1912, Vol. XXXIV, p. 102.
 Hine.—*British Jl. Ophthalm.*, 1918, Vol. II, No. 1.
 Holmes and Lister.—*Brain*, 1916, Vol. XXXIX, p. 34. *Proc. Roy. Soc. Med.*, 1916, Vol. IX.
 Holmes.—*British Med. Jl.*, Nov. 24, 1917.

Marie et Chatelin.—*Rev. Neurol.*, 1914-15, Vol. XXVIII, p. 882.
 Riddoch.—*Brain*, 1917, Vol. XL, p. 15.
 Smith and Holmes.—*British Med. J.*, March 25, 1916.
 Wilson.—*Lancet*, July 7, 1917.

THRESHOLD TESTS*

BY

GEORGE YOUNG, M.D.,
COLCHESTER.

PART ONE

THE routine determination of the approximate thresholds for light differences and colours often shows striking results. It may prove of diagnostic value. We should all practise it for a time, and compare notes. Though the subject has occasionally been broached, and its probable diagnostic importance pointed out, I believe it is still comparatively untrodden ground.

Obviously only a rapid, but accurate, procedure can become quite popular among our best and busiest workers. I have tried to supply one, and as it seems to answer the purpose, I venture to bring it before you. It is easily contested on scientific grounds; its main object is practical.

The Principle

A brief account of my last experiments will, I think, describe the principle sufficiently to enable others to carry out the test on similar lines with the outfit now obtainable.

On pieces of white blotting paper I produced spots of black, red, green, blue, and yellow in dilutions equalling $1/512$, $1/256$, $1/128$, $1/64$, $1/32$, $1/16$, $1/8$, $1/4$, $1/2$ and 1. Each successive spot thus was double the intensity of the previous one. After trying many dyes and fabrics, I settled on the excellent waterproof inks of Winsor & Newton, commercially known as Indian ink, vermilion, emerald, ultramarine, yellow. The dilutions were made in distilled water. They were dropped from a pipette of 1 mm. drop surface, and from a height of 100 mm. The fifty cards were fastened, in the above order both of colour and dilution, on each grey page of a photograph album. The value of each card was noted in a corner.

The Test

Correction of error and accommodation being sometimes called for, the test is performed after this has been done, with the trial

* Read at the Oxford Ophthalmological Congress, 1917.