

Outcomes Of Cryoballoon Ablation Of Atrial Fibrillation: A Comprehensive Review

Arash Aryana, MS, MD, FHRS, Mark R. Bowers, MS, MD, and Padraig Gearoid O'Neill, MD, FHRS

Mercy General Hospital and Dignity Health Heart and Vascular Institute, Sacramento, California.

Abstract

Over the last decade, cryoballoon ablation has emerged as an effective alternate strategy to point-by-point radiofrequency ablation for treatment of symptomatic atrial fibrillation. There are several reasons for this. First, the acute and long-term safety and efficacy associated with cryoablation appear comparable to that of radiofrequency ablation in patients with both paroxysmal and also persistent atrial fibrillation. Second, cryoablation offers certain advantages over conventional radiofrequency ablation including a gentler learning curve, shorter ablation and procedure times as well as lack of need for costly electroanatomical mapping technologies commonly utilized with radiofrequency ablation. Lastly, with the recent advent of the second-generation cryoballoon, the effectiveness of cryoablation has further improved dramatically. This comprehensive review examines the gradual evolution of the cryoablation tools as well as the rationale and data in support of the currently-available cryoballoon technologies for catheter ablation of atrial fibrillation.

Introduction

Catheter ablation has emerged as a practical approach for treatment of symptomatic atrial fibrillation (AF) in those who fail membrane-stabilizing antiarrhythmic drug (AAD) therapy.¹ AF ablation has been shown to improve patient quality of life² and reduce hospital readmission.³ Additionally, the observed benefits even persist in patients in whom complete freedom from AF cannot be achieved.² As the role for catheter ablation in the management of AF has evolved within the last 2 decades, so have the ablative techniques and strategies. To date, a variety of energy modalities have been utilized for catheter ablation of AF including unipolar radiofrequency (RF),⁴ irrigated⁵ and non-irrigated bipolar RF,⁶ laser,⁷ cryotherapy,⁸ and high-intensity focused ultrasound.⁹ While the long-term safety and efficacy of RF energy has rendered it the mainstay of arrhythmia ablation therapy, there are certain practical and theoretical advantages to using cryoenergy.

The principles of cryobiology were first established with investigations on the treatment of frostbite and tumor destruction.¹⁰ Current data suggests that a temperature of -30°C to -40°C is

necessary to induce cell death.¹⁰ Ice formation is the cornerstone of cellular injury with cryotherapy which occurs both intracellularly and extracellularly. Hypothermy-induced cellular and tissue destruction occurs through immediate and delayed mechanisms.¹⁰ The immediate effects including hypothermic injury and cellular freeze rupture are mediated through tissue freezing/thawing, whereas delayed injury results from vasculature damage and apoptosis or programmed cell death.¹¹

Rationale For Using Cryoenergy For AF Ablation

As a result of technological advances, evolutions in catheter design, and improved energy delivery that have come about in the last two decades, cryoablation is now routinely used in cardiac electrophysiology laboratories. Cryotherapy exploits the Joule-Thomson effect¹² to achieve temperatures between -30°C to -90°C at the catheter-tissue interface.¹³ Furthermore, the use of cryoablation for pulmonary (PV) vein isolation may offer certain advantages. First, tissue-catheter adhesion during cryoablation can result in improved catheter stability. Second, cryoablation is associated with reduced pain and discomfort since the afferent pain fibers are 'frozen' as opposed to stimulated thermally.¹⁴ Third, cryoablation carries a lower risk of thrombus formation and consequently systemic thromboembolization and stroke, since it is associated with decreased activation of platelets and the coagulation cascade as compared with RF.¹⁵ Fourth, cryoablation leaves the connective tissue matrix intact and also avoids the risk of steam pops.¹⁴ Fifth, the lack of circulation, vascular disruption, and endothelial injury at the center of the cryolesion results in uniform tissue necrosis.¹⁴ As a result, unlike with RF, cryolesions consist of a smooth, sharply-demarcated necrotic core corresponding to the frozen volume within the zone of lethality, and they are thought to be associated with reduced likelihood of ulceration, stenosis, and formation of fistulas

Key Words:

Atrial Fibrillation, Catheter Ablation, Cryoablation, Cryoballoon, Outcome.

Disclosures:

Drs. Aryana and O'Neill have received consulting fees, speaker honoraria and a research grant from Medtronic, Inc.

Corresponding Author:

Arash Aryana, MS, MD, FHRS
Vice Chair
Department of Cardiology and Cardiovascular Surgery
Mercy General Hospital and Dignity Health Heart and Vascular Institute
3941 J Street, Suite #350
Sacramento, California 95819

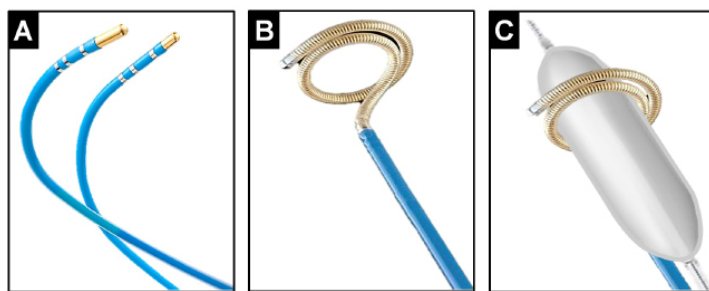


Figure 1:

Cryoablation tools originally used for catheter ablation of AF. Panel A, shown, are a 6-mm and a 4-mm tip focal cryoablation catheter. Panel B, illustrates a curvilinear cryoablation catheter with a 64-mm freezing segment and the ability to expand to a diameter of 18 to 30 mm. This was the first cryoablation catheter specifically designed for PV isolation. Panel C, illustrates the 'block the vein' strategy – through this approach the PV is mechanically occluded using an angioplasty balloon catheter, advanced through the curvilinear cryoablation catheter to diminish PV blood flow and to further enhance the efficacy of cryoablation.

and strictures.¹⁴ Nonetheless, cryoablation can still pose a significant threat to collateral structures such as the esophagus, lungs, coronary arteries, and phrenic and vagus nerves.¹³ Another disadvantage relates to the impact of blood flow on lesion size. That is, increased blood flow surrounding the ablation catheter can significantly attenuate the size of cryolesions. As such, cryoablation is generally more effective in 'low-flow' areas.¹² Meanwhile, thaw time continues to remain the most important determinant of acute and long-term efficacy associated with cryoablation.^{16,17}

Focal Cryoablation Of AF

The safety and feasibility of focal cryoablation (Figure 1-A) for PV isolation was initially studied in 52 patients with paroxysmal and persistent AF who underwent PV isolation using this approach.¹⁸ While 97% of the targeted PVs were successfully isolated, freedom from AF was only 56% at 1 year. Though in this study the long-term clinical efficacy appeared to be lower than conventional RF ablation, post-procedural computed tomographic (CT) surveillance demonstrated no evidence of PV stenosis. Hoyt et al.¹⁹ also reported on the feasibility of focal cryoablation in a cohort of 31 paroxysmal AF patients. Acute PV isolation was attainable in 94% of patients, but freedom from AF was only 58% at 6 months. Once again, no cases of PV stenosis were encountered on serial CT surveillance. Similarly, Kenigsberg et al.²⁰ found that in fact focal cryoablation up to 15 mm inside the PV ostium was not associated with increased risk of PV stenosis. Furthermore, endoscopic studies have reported lack of esophageal ulcerations following focal cryoablation as compared with the cryoballoon or RF.²¹ Nonetheless, the practical application of focal cryoablation for PV isolation appears limited by prolonged ablation times and reduced long-term efficacy. Additionally, there are no data currently on the clinical efficacy of linear focal cryoablation within the left atrium. While clinical studies in patients with atrial flutter (AFL) have shown that linear lesions can be effectively created by point-by-point cryoablation, long-term recovery of cavotricuspid isthmus conduction is generally higher using the latter approach as compared to RF.²² Recently, the feasibility of a novel cryoablation system designed for catheter ablation of AF/AFL using a liquid refrigerant in place of nitrous oxide (used traditionally in catheter-based cryoablation systems), was described in vivo.²³ The latter is capable of achieving lower nadir temperatures and seems to hold

promise for both PV isolation and linear ablations.

Cryoballoon Ablation Of AF

In order to overcome the challenges associated with focal cryoablation for PV isolation, a curvilinear catheter was initially developed in early 2000s. This catheter consisted of a 64-mm freezing segment with the ability to expand to a diameter from 18 to 30 mm (Figure 1-B). Skanes et al.²⁴ reported on the use of this circular cryoablation catheter. Although using this ablation tool, complete PV isolation proved possible in 91% of patients without any cases of PV stenosis, only 22% exhibited freedom from AF at 6 months. On the other hand, in 44% of patients who underwent a repeat procedure, PV reconnection was evident in 93% of the previously isolated PVs. The poor efficacy associated with this catheter was attributed largely to the undesirable effects of PV blood flow on cryoablation using this technology and its suboptimal catheter design. As a result, the 'block the vein' strategy was proposed (Figure 1-C). Eventually, based on this scheme, the first cryoballoon ablation catheter was introduced and subsequently tested in vivo.^{25,26}

First-Generation (Arctic Front) Cryoballoon

The cryoballoon (Arctic Front, Medtronic, Inc, Minneapolis, MN) is a steerable, over the wire, 12-French double-walled balloon catheter system (Figure 2-A). Two sizes are available – a 23 and

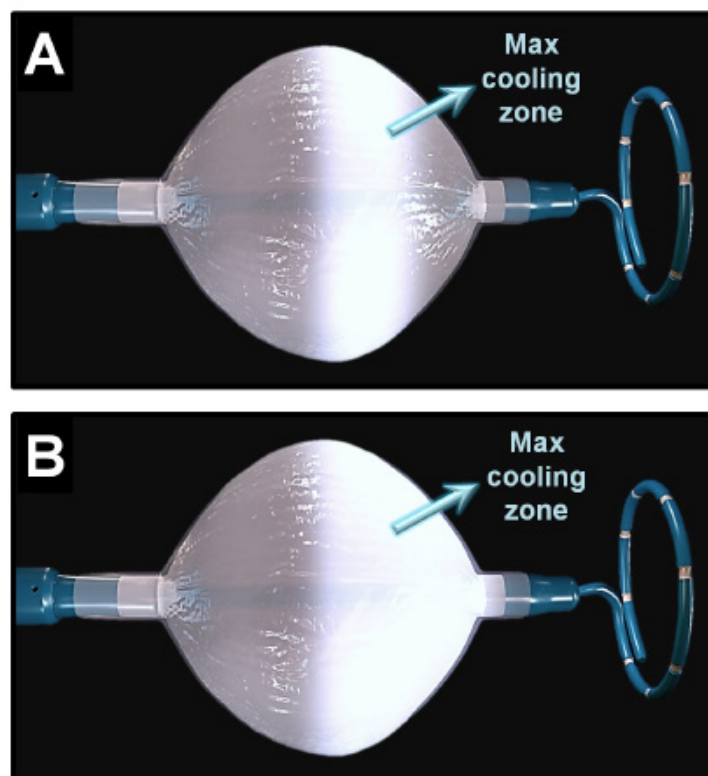


Figure 2:

The designs of the first- and second-generation cryoballoon catheters, both advanced over an octapolar spiral mapping catheter specifically designed for recording PV potentials to guide real-time PV isolation. Panel A, in the first-generation cryoballoon, the maximal cooling zone (arrow) consists of an equatorial band. Accordingly, optimal balloon alignment would be vital to ensure proper circumferential contact between the PV antra and the cooling zone on this balloon. Panel B, due to design modifications made to the second-generation cryoballoon, the maximal cooling zone on this catheter (arrow) now spans the entire distal half of its surface including the distal tip. This in turn offers a greater cooling surface area while minimizing the impact of balloon orientation on optimal tissue contact.

Table 1: Acute and long-term efficacy and safety of PV isolation using the first-generation cryoballoon in non-randomized studies.

Study	n	Paroxysmal AF, n	Acute PV isolation	Procedure time, min	Fluoroscopy time, min	Transient PN palsy	Persistent PN palsy	Freedom from AF during follow-up
Malmborg, et al. ²⁸	43	34 (79%)	91%	239 ± 48	57 ± 21	4.7%	2.3%	52% at 9 months
Neumann, et al. ²⁹	346	293 (85%)	97%	170	40	7.5%	0%	74% at 12 months (paroxysmal AF) 42% at 12 months (persistent AF)
Klein, et al. ³⁰	21	21 (100%)	95%	165 ± 35	39 ± 9	14.3%	4.8%	86% at 6 months
Van Belle, et al. ³¹	141	141 (100%)	99%	207 ± 79	50 ± 28	2.8%	0%	55% at 15 months
Chun, et al. ³²	27	27 (100%)	98% (single application)	220	50	11.1%	0%	70% at 9 months
Defaye, et al. ³³	117	92 (79%)	87% (single application)	155 ± 43	35 ± 15	0.9%	0%	69% at 12 months (paroxysmal AF) 45% at 12 months (persistent AF)
Vogt, et al. ³⁴	605	579 (96%)	91%	156	25	2%	0%	62% at 30 months
Ferrero-de Loma-Osorio, et al. ³⁵	63	40 (63%)	95%	180 ± 32	31 ± 22	4.8%	0%	72% at 2 years (paroxysmal AF) 36% at 2 years (persistent AF)
Aytemir, et al. ³⁶	236	188 (80%)	99%	72 ± 5	14 ± 3	4.6%	0%	81% at 18 months (paroxysmal AF) 50% at 18 months (persistent AF)
Rao, et al. ³⁷	51	51 (100%)	97%	151 ± 30	49 ± 12	5.9%	0%	57% at 36 months

a 28 mm balloon catheter. Early on, a small study comparing the outcomes between the curvilinear cryoablation catheter and the cryoballoon pointed to the superior efficacy associated with the use of the latter in patients with paroxysmal AF.²⁷ Subsequently, acute and long-term safety and efficacy of PV isolation using the cryoballoon was evaluated in several non-randomized studies in patients with paroxysmal AF (Table 1), reporting long-term success rates ranging between 55 and 86%.²⁸⁻³⁷ Neumann et al.²⁹ reported on a prospective, 3-center experience of cryoballoon ablation in 346 patients with symptomatic, drug refractory paroxysmal and persistent AF. Acute PV isolation could be achieved in 97% of the targeted PVs, and freedom from AF was 74% in patients with paroxysmal and 42% in those with persistent AF. No PV stenosis was again encountered during follow-up. However, transient phrenic nerve (PN) palsy occurred in 7.5% of patients; though they all resolved within 1 year. The Sustained Treatment of Paroxysmal Atrial Fibrillation (STOP AF) trial is the only published multicenter, prospective, randomized-controlled trial that evaluated the safety and efficacy of cryoballoon ablation for treatment of AF.⁸ In this study, 245 patients with paroxysmal (78%) or early persistent AF (22%) were randomized to cryoballoon ablation or AAD therapy in a 2:1 randomization scheme. Cryoablation achieved electrical isolation in 98.2% of PVs, in 97.6% of patients. Following a 3-month blanking period, freedom from AF was achieved in 69.9% of patients treated with cryoablation as compared to only 7.3% using AAD therapy ($p < 0.001$). Transient PN palsy was encountered in 11.2% which ultimately persisted in 1.5% of patients at 1 year. Stroke occurred in 2.2% and PV stenosis (defined as a reduction of >75% in cross-sectional area or a 50% reduction in PV diameter) in 3.1% of patients treated with cryoablation. Two patients with PV stenosis were symptomatic and one required PV stenting. Subsequently, a systematic review of 23 studies published on the outcomes of cryoballoon ablation among 1,308 patients with paroxysmal and persistent AF showed a 97.5% acute procedural success (PV isolation) with freedom from AF in 72.8% at 1 year.³⁸ These findings were generally consistent with those reported in STOP AF. More recently, Yorgun et al.³⁹ reported on the additional benefits of cryoballoon-based ablation of AF beyond PV isolation. The authors found that modification of ganglionic plexi as evaluated by occurrence of vagal reactions during cryoablation may serve as an independent predictor of AF recurrence during long-term follow-up.

Second-Generation (Arctic Front Advance) Cryoballoon

Soon after the early experiences with the first-generation cryoballoon it became apparent that ablation using this tool was prone to certain challenges and drawbacks. Due to its number and location of refrigerant injection ports, the maximal cooling zone on the first-generation balloon occurs primarily over its equator (Figure 2-A). Therefore, optimal balloon positioning and orientation at PV antra is often critical when using this catheter, such that balloon mal-alignment can frequently compromise uniform tissue cooling and lesion formation.⁴⁰ This is further supported by more recent data showing that durable PV isolation is directly impacted by the degree of PV occlusion and tissue cooling, which in turn is influenced by the distance from the balloon (cooling zone). These concerns subsequently led to the development of the second-generation cryoballoon (Arctic Front Advance, Medtronic, Inc). The principal modification in the design of this catheter has to do with the expansion of the cooling zone to the entire distal half of its surface (Figure 2-B). Knecht et al.,⁴² analyzed the magnitude of ice formation using this new design as compared to the first-generation cryoballoon and found that the mean covered surface areas were significantly different for the 28-mm but not the 23-mm balloons. Where as the first-generation catheter created non-contiguous ice formation, the second-generation cryoballoon exhibited a rather homogenous ice cap covering the entire distal segment of the balloon including its distal pole (the nose of the balloon). The superior efficacy of the second-generation cryoballoon was subsequently validated in vivo.^{43,44} That is, it was shown that cryoablation of canine PVs through a single 4-min cryoapplication using the second-generation cryoballoon created transmural and circumferential lesions resulting in electrical isolation in 100% of PVs, as compared to only 60% using the first-generation cryoballoon. A more recent clinical study showed that cryoablation using this balloon was wide and circumferential with the level of PV isolation more antral, resulting in generous posterior left atrial debulking which could in part also account for this balloon's improved efficacy.⁴⁵ Furthermore, Reddy et al.⁴⁶ evaluated the outcomes of PV isolation using the second-generation cryoballoon in 21 consecutive patients with paroxysmal AF, all of whom subsequently underwent a second remapping procedure to assess for durability of PV isolation at 3 months. The authors found that acute electrical isolation could be achieved in 83% of PVs using a single cryoapplication, with

Table 2: Acute and long-term outcomes of PV isolation using the first- versus second-generation cryoballoons in non-randomized studies.

Study	n	Acute PV isolation	Cryoballoon temperature at PV isolation, at 60 sec or, at nadir temperature, °C	Time to PV isolation or nadir temperature, sec	Ablation Time, min	Procedure time, min	Fluoroscopy time, min	Transient PN palsy	Freedom from AF at 1 year
Martins, et al. ⁴⁷	66	81%	-36 ± 10*	52 ± 34**	26 ± 14	120 ± 24	29 ± 10	10.6%	N/A
First-generation balloon	81	90%	-32 ± 10*	40 ± 25**	22 ± 7	107 ± 24	25 ± 9	24.4%	N/A
Second-generation balloon		0.003	0.001	0.001	<0.001	0.002	0.020	0.048	N/A
p-value									
Fürnkranz, et al. ⁴⁸	30	100%	-49 ± 6†	79 ± 60**	N/A	128 ± 27	19 ± 7	3.3%	N/A
First-generation balloon	30	100%	-52 ± 6†	52 ± 36**	N/A	98 ± 30	13 ± 5	3.3%	N/A
Second-generation balloon		1.00	0.005	0.049	N/A	<0.001	0.001	1.00	N/A
p-value									
Aryana, et al. ⁴⁹	140	92%	26 ± 23‡	232 ± 77§	61 ± 17	209 ± 58	42 ± 17	12.1%	80%
First-generation balloon	200	98%	-32 ± 16‡	209 ± 68§	47 ± 12	154 ± 47	27 ± 12	16.0%	84%
Second-generation balloon		0.036	<0.001	<0.001	<0.001	<0.001	<0.001	0.311	0.289
p-value									
Straube, et al. ⁵⁰	364	99%	61¶ / -50#	48†† / 76‡‡	60 ± 16	185 ± 49	34 ± 12	20.6%	85%
First-generation balloon	120	100%	-58¶ / -52#	33†† / 52‡‡	58 ± 12	175 ± 45	29 ± 11	27.5%	85%
Second-generation balloon		0.43	<0.001¶ / 0.074#	<0.001†† / <0.001‡‡	0.007	0.038	<0.001	0.121	1.00
p-value									
Fürnkranz, et al. ⁵¹	50	98%	N/A	N/A	52 ± 10	137 ± 33	22 ± 10	8.0%	64%
First-generation balloon	55	100%	N/A	N/A	33 ± 6	94 ± 24	13 ± 4	12.7%	84%
Second-generation balloon		0.48	N/A	N/A	<0.001	<0.001	<0.001	0.434	0.008
p-value									
Di Giovanni, et al. ⁵²	50	100%	-50 ± 10†	69 ± 25**	N/A	115 ± 39	25 ± 6	8.0%	66%
First-generation balloon	50	100%	-52 ± 5†	43 ± 17**	N/A	90 ± 16	18 ± 6	16.0%	84%
Second-generation balloon		1.00	—	<0.05	N/A	<0.01	<0.01	0.218	0.038
p-value									
Liu, et al. ⁵³	57	88%	-42 ± 6†	N/A	37 ± 10	117 ± 26	20 ± 5	0%	60%
First-generation balloon	68	93%	-46 ± 6†	N/A	28 ± 9	103 ± 23	18 ± 5	2.9%	90%
Second-generation balloon		0.352	0.003	N/A	<0.001	0.001	0.011	0.159	<0.001
p-value									

L* Cryoballoon temperature at PV isolation, **Time to PV isolation, †Nadir cryoballoon temperature, ‡Cryoballoon temperature at 60 sec, §Time to nadir temperature, ¶Cryoballoon temperature at PV isolation using the 23-mm cryoballoon, #Cryoballoon temperature at PV isolation using the 28-mm cryoballoon, ††Time to PV isolation using the 23-mm cryoballoon, ‡‡Time to PV isolation using the 28-mm cryoballoon

91% of PVs still durably isolated at 3 months. This provides clinical evidence that in fact the improved thermodynamic characteristics of the second-generation cryoballoon seem to be associated with a higher rate of both single-shot PV isolation and also chronic lesion durability, which may translate into improved clinical outcomes.

Meanwhile, several studies have compared the acute and long-term outcomes of PV isolation using the first- and second-generation cryoballoons in patients with paroxysmal and persistent AF.⁴⁷⁻⁵³ These studies collectively point to the superiority of the second- over the first-generation cryoballoon based upon several major benchmark parameters including acute PV isolation, biophysical characteristics, ablation time, procedure time, fluoroscopic utilization, and long-term freedom from AF (Table 2). As previously shown by our group, in addition to faster balloon cooling rates at 30 and 60 sec, shorter time-to-nadir temperature, and longer interval and total thaw times observed with the use of the second-generation cryoballoon, we also found a significantly lower PV reconnection rate at repeat procedure in those with arrhythmia recurrence during long-term follow-up (30% versus 13%; p=0.037).⁴⁹ Furthermore, these results were independent of operator experience and learning curve. Furthermore, Bordignon et al.⁵⁴ evaluated the magnitude of biomarker release in 66 patients following cryoablation using the first- versus the second-generation cryoballoons and found that despite shorter ablations required using the second-generation cryoballoon, higher levels of cardiac biomarkers such as troponin T, creatine phosphokinase and lactate dehydrogenase could be detected within the first 48 h in patients treated with the latter – possibly suggestive of more effective ablation. Interestingly, these findings also correlated with higher procedural success at 6 months. Table 3, illustrates a summary of mid- and long-term clinical outcomes of AF ablation using the

second-generation cryoballoon as assessed by non-randomized single and multi-center studies.⁴⁶⁻⁵⁸ These studies have consistently reported improved procedural and clinical outcomes associated with the use of the second-generation cryoballoon.

PV Isolation Using The Cryoballoon And Predictors Of AF Recurrence

A more recent feature of cryoballoon ablation of AF is the ability to potentially monitor real-time to PV isolation, also known as time-to-effect via a single transseptal access. That is, the cryoballoon can be advanced into the left atrium either over a conventional guide wire or a specific octapolar spiral mapping catheter/guide wire (Achieve, Medtronic, Inc) designed for monitoring and recording of PV potentials to guide real-time PV isolation (Figure 2). To date, this approach has been validated in several studies.⁵⁹⁻⁶¹ Nonetheless, the main limitation of this catheter has to do with its smaller diameter size (either 15-mm or 20-mm), precluding consistent real-time recording of PV potentials in patients with larger PV antra. Additionally, the wider spacing among the electrodes on the catheter further amplifies far-field electrogram sensing. In a recent publication, Boveda et al.⁶¹ reported a stepwise approach using this catheter which could accurately assess real-time PV isolation in ~98% of the PVs. Though in our experience, we have been unable to duplicate such a high rate of confirmation of PV isolation during cryoablation using this spiral recording catheter, undoubtedly this remains a highly effective tool for measuring time-to-effect providing overall a simpler method for validation of PV isolation as compared to other single-shot ablation systems such as the nMARQ or the pulmonary vein ablation catheter (PVAC).

Meanwhile several other studies have closely examined the predictors of a successful cryoballoon ablation of AF. One report

found an inverse association between the ovality index and the orientation of PV ostia as determined by cardiac CT angiography with the degree of cryoballoon occlusion during catheter ablation.⁶² Similarly, Kubala et al.⁶³ found that in patients undergoing cryoballoon ablation, presence of normal versus atypical PV anatomy such as a common left PV, was associated with improved freedom from AF during long-term follow-up. With respect to biophysical characteristics of cryoballoon ablation, it seems that balloon thaw time and perhaps its secondary derivative, freeze area-under-the-curve, represent significant predictors of PV reconnection during follow-up and long-term freedom from AF post-catheter ablation.^{64,65} On the other hand, cryoablation time and cryoballoon temperature served as poor and unreliable predictors of such endpoints.⁶⁵ It should be emphasized that the freeze area-under-the-curve signifies a comprehensive metric to assess the magnitude of cryoablation.⁴⁹ As such, the computed value collectively reflects a multitude of parameters including duration of cryoapplication, rate of cooling, nadir temperature, and thaw-time. Meanwhile, another study has suggested that very cold minimum balloon temperatures (<-51°C) may in fact be predictive of acute PV isolation.⁶⁶ Conversely, the same study found that a minimum balloon temperature ≥-36°C (for superior PVs) and ≥-33°C (for inferior PVs) predicted failed acute PV isolation with a relatively high specificity (≥95%). But it should be pointed out that in this study no data on long-term outcomes were reported to further corroborate the acute procedural findings with respect to durability of PV isolation or freedom from AF. Collectively, we believe that these findings underscore the importance of the 'quality' as opposed to the 'quantity' of cryoapplications during catheter of ablation when using the cryoballoon.

In the meantime, there remains a lack of consensus on the appropriate ablation dosing when performing an AF ablation using the cryoballoon – that is, with respect to the ideal freezing duration and the number of freeze-thaw-freeze cycles. The current recommendations suggest a 4-min cryoapplication along with a 'double freeze' approach (freeze-thaw-freeze cycle). Though the 'double freeze' method has been shown to result in more extensive tissue destruction and deeper, larger lesions due to the repeated freeze/thaw effects on the cell membrane,¹⁴ it has been argued that this data may

largely pertain to the less potent cryoablation tools such as the focal cryoablation catheter. Indeed, there is cumulative evidence in support of improved acute and long-term efficacy associated with a single PV cryoapplication using the second-generation cryoballoon. Cicone et al.⁵⁷ recently reported their results of a single 3-min cryoapplication using the second-generation cryoballoon in 143 consecutive patients. The authors achieved acute PV isolation in 94% of PVs using a single application and in 100% after 1.1 ± 0.4 freezes. After a 3-month blanking period, freedom from atrial arrhythmias was achieved in 80% of patients at 1 year (82% with paroxysmal versus 73% with persistent AF). Additionally, 10% of patients underwent a repeat procedure. Though this data is subject to selection bias, among these patients 43% of PVs exhibited conduction recovery at redo ablation. Now it should be called to attention that it would be extremely difficult to meaningfully compare such data against those derived from other non-matched series. However, as previously reported by our group,⁴⁹ the same outcome of PV reconnection in patients undergoing repeat procedures following an initial second-generation cryoballoon ablation using ≥2 applications (≥1 freeze-thaw-freeze cycle) was found to be 13%. In the long run, whether a second 'bonus' freeze will in fact prove necessary still needs to be determined.

A recent study has also evaluated the predictive value of early AF recurrence following catheter ablation using the first-generation cryoballoon by analyzing data from the STOP AF trial.⁶⁷ The authors found that over half of the patients (51%) experienced an early recurrence post-ablation within the first 3 months. Moreover, of these recurrences the great majority (85%) had occurred within the first month. Though nearly half of these individuals (44%) remained free of long-term atrial arrhythmias, early recurrence did in fact correlate with late recurrence of AF. Conversely, only 13% of those with early recurrences were found to have recurrent AF during long-term follow-up.

Comparison Of Cryoballoon Versus RF

Though there is limited data on prospective head-to-head comparisons between cryoballoon versus RF catheter ablation of AF, several non-randomized comparative studies^{58,68-76} have been published on the use of the first-generation cryoballoon as compared to open-irrigated, non-force sensing RF (Table 4). The results have

Table 3: Acute and long-term efficacy and safety of PV isolation using the second-generation cryoballoon in non-randomized studies.

Study	n	Paroxysmal AF, n	Acute PV isolation	Ablation time, min	Procedure time, min	Fluoroscopy time, min	Transient PN palsy	Persistent PN palsy	Freedom from AF during follow-up
Kenigsberg, et al. ⁴⁶	43	34 (79%)	100%	22 ± 4	126 ± 23	16 ± 8	N/A	N/A	95% at 6 months
Martins, et al. ⁴⁷	81	81 (100%)	90%	22 ± 7	107 ± 24	25 ± 9	3.3%	0%	N/A
Fürnkranz, et al. ⁴⁸	30	23 (77%)	100%	29 ± 12	98 ± 30	13 ± 5	3.3%	0%	N/A
Aryana, et al. ⁴⁹	200	143 (72 %)	98%	47 ± 12	154 ± 47	27 ± 12	16.0%	0.5%	84% at 1 year
Straube, et al. ⁵⁰	120	63 (52%)	100%	58 ± 12	175 ± 45	29 ± 11	27.5%	1.7%	85% at 1 year
Fürnkranz, et al. ⁵¹	55	55 (100%)	100%	33 ± 6	94 ± 24	13 ± 4	12.7%	5.4%	84% at 1 year
Di Giovanni, et al. ⁵²	50	50 (100%)	100%	N/A	90 ± 16	18 ± 6	16.0%	2%	84% at 1 year
Liu, et al. ⁵³	68	50 (74%)	93%	28 ± 9	103 ± 23	18 ± 5	2.9%	0%	90% at 1 year
Bordignon et al. ⁵⁴	33	26 (79%)	100%	33 ± 6	N/A	N/A	6.1%	0%	85% at 6 months
Chierchia, et al. ⁵⁵	42	42 (100%)	100%	31 ± 4	95 ± 16	20 ± 12	19.0%	0%	83% at 1 year
Metzner, et al. ⁵⁶	50	36 (72%)	100%	35 ± 6	140 ± 28	25 ± 8	2.0%	0%	80% at 1 year
Cicone, et al. ⁵⁷	143	113 (79%)	100%	13 ± 5	95 ± 16	13 ± 8	6.3%	3.5%	80% at 1 year
Aryana, et al. ⁵⁸	633	472 (75%)	98%	40 ± 14	145 ± 49	29 ± 13	7.6%	1.1%	77% at 1 year

been largely mixed without any apparent, significant differences between the two modalities. However, two of the larger series by Kojodjojo et al.⁶⁹ and Mugnai et al.⁷⁵ did in fact illustrate subtle trends towards improved 1-year outcomes with the first-generation cryoballoon as compared to RF (77% versus 72% and 63% versus 57%, respectively). Xu et al.⁷⁷ reported the outcomes from a meta-analysis of 1,104 patients from published studies, who underwent AF ablation using the cryoballoon (n=469) or RF (n=635). They found cryoablation to be associated with a significantly shorter procedure time (by a weighted mean of 30 min) and fluoroscopy exposure (by a weighted mean of 14 min), whereas ablation time was non-significantly longer with cryoablation (by a weighted mean of 12 min). Moreover, cryoablation was also found to be associated with a non-significantly higher rate of long-term success as compared with RF. Recently, our group has reported on the acute and long-term outcomes from a large, non-randomized, multicenter study comparing the second-generation cryoballoon to open-irrigated, non-force sensing RF.⁵⁸ The study included 1,196 patients with AF (76% paroxysmal), and it found that cryoablation was associated with a superior primary endpoint of freedom from atrial arrhythmias at 12 months following a single catheter ablation procedure without the use of AAD therapy (76.6% versus 60.4%; p<0.001), and overall a reduced need for AADs (16.7% versus 22.0%; p=0.024) and fewer repeat ablations (14.6% versus 24.1%; p<0.001), as compared to non-contact force sensing RF. In addition, at redo procedure, fewer patients exhibited PV reconnection if previously ablated using the

cryoballoon (44.2%) as versus RF (65.7%); p=0.002. Cryoablation was also associated with shorter ablation and procedure times, but greater fluoroscopic utilization. Both transient and persistent PN palsy occurred exclusively with cryoablation, whereas all other adverse event rates were similar between the two groups. These findings coupled with the relative safety associated with the use of cryoablation using the second-generation cryoballoon, reproducibility of the results across a number of different centers with variable procedural volume, and suggestion of a similar magnitude of benefit in patients with both paroxysmal and persistent AF, evoked the second-generation cryoballoon a more favorable ablation tool as compared to non-force sensing RF with an AF ablation score⁷⁸ notably greater than that computed for RF. Additional investigations to evaluate the safety and efficacy related to the use of cryoballoon ablation in comparison to the recently made available force-sensing RF ablation catheters seems necessary to identify the most optimal approach to AF ablation. Along these lines, Jourda et al.⁷⁹ reported on a prospective comparison between force sensing RF and the second-generation cryoballoon. The study found that both procedural and fluoroscopic times were shorter with force sensing RF but with similar ablation times, adverse events, and long-term freedom from AF as compared to cryoablation using the second-generation balloon. At this point, a larger, multicenter comparison of these two diverse types of ablation techniques with respect to cost, safety, and efficacy seems relevant.

In addition, Juliá and colleagues⁷⁶ recently reported on the incidence and mechanism of atrial tachycardias following catheter

Table 4: Acute and long-term outcomes of PV isolation using RF versus the cryoballoon in non-randomized studies.

Study	n	Paroxysmal AF	Acute PV isolation	Ablation Time, min	Procedure time, min	Fluoroscopy time, min	PN palsy	Other adverse events	Freedom from AF during long-term follow-up
Linhart, et al. ⁶⁸									
RF	20	20 (100%)	100%	N/A	200 ± 67	55 ± 23	0%	0%	45% at 6 months
Cryoballoon	20	20 (100%)	81%	N/A	166 ± 39	41 ± 13	15%	0%	50% at 6 months
Kojodjojo, et al. ⁶⁹									
RF	53	53 (100%)	99%	N/A	208 ± 58	62 ± 36	0%	3.8%	72% at 1 year
Cryoballoon	90	90 (100%)	83%	N/A	108 ± 28	27 ± 9	2.2%	1.1%	77% at 1 year
Tayebjee, et al. ⁷⁰									
RF	25	25 (100%)	100%	N/A	35	0%	0%	4%	52% at 1 year
Cryoballoon	25	25 (100%)	76%	N/A	45	8%	4%	4%	56% at 1 year
Kühne, et al. ⁷¹									
RF	25	25 (100%)	00%	47	197 ± 52	46 ± 22	0%	4%	92% at 1 year
Cryoballoon	25	25 (100%)	100%	45	166 ± 32	61 ± 25	4%	4%	88% at 1 year
Sorgente, et al. ⁷²									
RF	29	20 (69%)	100%	N/A	N/A	N/A	0%	13.8%	66% at 1 year
Cryoballoon	30	24 (80%)	100%	N/A	N/A	N/A	10%	3.3%	66% at 1 year
Herrera Siklódy, et al. ⁷³									
RF	30	17 (57%)	100%	52 ± 21	200 ± 46	37 ± 16	0%	0%	80% at 1 year
Cryoballoon	30	21 (70%)	100%	44 ± 6	177 ± 30	38 ± 12	6.7%	6.7%	63% at 1 year
Schmidt, et al. ⁷⁴									
RF	2,870	2,870 (100%)	98%	33	165	24	0%	4.6%	N/A
Cryoballoon	905	905 (100%)	97%	45	160	34	2.1%	2.7%	N/A
Mugnai, et al. ⁷⁵									
RF	260	260 (100%)	100%	43 ± 6	192 ± 49	36 ± 14	0%	14.2%	57% at 23 months
Cryoballoon	136	136 (100%)	100%	45 ± 4	112 ± 58	31 ± 17	8.1%	11.0%	63% at 23 months
Juliá, et al. ⁷⁶									
RF†	186	186 (100%)	98%	N/A	190 ± 57	35 ± 19	N/A	N/A	80% at 1 year
Cryoballoon*	100	100 (100%)	100%	N/A	117 ± 59	27 ± 16	N/A	N/A	81% at 1 year
Aryana, et al. ⁵⁸									
RF	422	319 (76%)	99%	66 ± 26	188 ± 42	23 ± 14	0%	2.6%	60% at 1 year
Cryoballoon**	633	472 (75%)	98%	40 ± 14	145 ± 49	29 ± 1	7.6%	1.6%	77% at 1 year
Jourda, et al. ⁷⁹									
RF†	75	75 (100%)	100%	2 ± 13	111 ± 32	21 ± 8	0%	2.7%	88% at 1 year
Cryoballoon**	75	75 (100%)	100%	32 ± 3	134 ± 48	25 ± 10	17.3%	1.3%	85% at 1 year

*Combination of first- and second-generation cryoballoons, **Second-generation cryoballoon only, †Force sensing RF

ablation of paroxysmal AF in 286 consecutive patients using the cryoballoon versus RF. The authors found that the incidence of post-ablation atrial tachycardias was significantly lower with cryoablation as compared to RF (3.0% versus 11.3%; $p = 0.028$). This difference was driven largely by the larger (28-mm) second-generation cryoballoon. Though not entirely clear, the mechanism is believed to be related to the overall reduced atrial ablation and perhaps larger and more homogeneous lesions created using the latter balloon.

Cryoballoon Ablation Of Persistent AF

Since the STOP AF study which originally evaluated the outcomes of cryoablation in patients with paroxysmal and 'early' persistent AF, several non-randomized first-/second-generation cryoballoon studies have evaluated this therapy in those with both paroxysmal and persistent AF.^{46,48-50,53,54,56,58} Specifically, a few additional studies have explicitly examined the efficacy of cryoablation of non-PV triggers using the second-generation cryoballoon.⁸⁰⁻⁸² In a recent multicenter study, the second-generation cryoballoon was shown to be a safe and effective tool for electrical isolation of the superior vena cava and ablation of the left atrial roof, the left lateral ridge and the base of the left atrial appendage throughout both atria in 110 patients with persistent and long-standing persistent AF.⁸² Complications were rare and at 1 year, 78% of patients remained free of AF recurrence following a 3-months blanking period. Obviously, additional data is currently needed to further validate the acute and long-term outcomes using this approach.

'Hybrid' Approach

Recently, a 'hybrid' approach involving a thoracoscopic surgical and a concomitant endocardial cryoballoon PV ablation has been described in patients with persistent AF or in those with paroxysmal AF and a failed prior catheter ablation.⁸³ While in two small studies this approach proved safe and feasible, the long-term efficacy of this strategy has yet to be evaluated.^{83,84} For now, the precise role, applicability and specific advantages of the above-mentioned approach over each of the individual strategies alone, remain unclear.

Safety

Several studies have established the overall safety of cryoballoon ablation of AF.^{8,38,85} While some have suggested fewer major adverse events associated with the use of cryoballoon versus RF including fewer cardiac perforations and fatalities,⁸⁵ these observations have not been entirely consistent. Aside from PN palsy which remains the most frequent complication related to the use of cryoballoon,^{8,85} the same adverse events that in general complicate RF ablation also occur with cryoablation of AF.^{38,58} These consist of groin complications, bleeding, thromboembolism, pericardial effusion, gastroparesis, and atriopharyngeal fistula.^{8,38,85} Though thromboembolism remains rare in the setting of cryoablation,¹⁵ most embolic events as a consequence of cryoablation are believed to represent air embolism related to the handling of the larger sheath inside the left atrium. Neumann et al.⁸⁶ investigated the incidence of micro-embolization immediately after catheter ablation of AF with the cryoballoon versus RF in 89 patients using cerebral magnetic resonance. The authors discovered presence of asymptomatic cerebral lesions one day post-ablation in 8.9% of patients ablated with cryoballoon versus 6.8% with RF. These outcomes did not differ statistically. Meanwhile, PV stenosis may also complicate cryoablation of AF. Though this adverse event has historically been thought to be a rare sequela of cryoablation,¹⁴ there is sufficient evidence to suggest that cryoballoon ablation is

not immune to this type of complication.⁸ Nonetheless, a recent meta-analysis documented the overall incidence of PV stenosis resulting in symptoms or requiring intervention at only 0.17% in patients who underwent cryoballoon ablation of AF.³⁸ Chierchia et al. investigated the incidence and outcomes of pericardial effusion following cryoballoon versus RF ablation, and found no significant difference between the two modalities (11% versus 16%).⁸⁷ The authors concluded that this complication was generally asymptomatic and mild with a benign self-limiting course in nearly all cases. Lastly, persistent iatrogenic atrial septal defect (iASD) following cryoablation has also been described.⁸⁸⁻⁹⁰ Specific concerns surrounding this complication have been raised due to the use of the larger, 15-French transeptal sheath which is required for delivery of the cryoballoon catheter into the left atrium. The incidence of iASD in cryoablation studies varies between 16-31% during short-term follow-up^{88,89} and has been reported as high as 20% at 1 year.⁹⁰ Not surprisingly, this incidence seems to be higher than that which is reported for RF which generally utilizes a smaller transeptal sheath for performing the ablation.⁸⁹ Though most patients with persistent iASD seem to tolerate this entity rather well and without apparent adverse events,⁸⁸⁻⁹⁰ additional studies on larger patient populations with longer follow-up are needed to reach a firm conclusion.

Meanwhile, some of the more important and specific adverse events complicating cryoballoon ablation of AF are reviewed in the ensuing sections.

PN Palsy

PN palsy is by far the most common complication of cryoballoon ablation of AF.^{8,38} Anatomical studies have revealed the close proximity of the right PN to the superior vena cava and the anterior-inferior aspect of the right superior PV, and also the left PN to the left atrial appendage.⁷⁸ Hence, catheter ablation in the vicinity of these structures can potentially yield collateral injury to the adjacent PN. However, PN injury is not unique to cryoablation. In fact, it can also occur as a consequence of catheter ablation using RF as well as other energy modalities.^{91,92} Overall, the prevalence of PN palsy due to AF ablation is estimated between 0.37% and 1.6%.⁹¹ A recent study suggested that the mechanism of PN injury as a result of cryoablation seems to be axonal in nature and characterized by Wallerian degeneration, with great potential for regeneration and neuronal recovery.⁹³ Consistent with this, the short-term outcome of patients with post-ablation PN palsy appears to be favorable with >80% achieving complete resolution by 1 year.⁹¹ As such, PN palsy may be classified as either transient or persistent. While the incidence of transient right PN palsy as a consequence of cryoballoon ablation of AF can reach $\approx 20\%$, persistent PN palsy remains uncommon with a reported incidence of only 0-4% in most studies.^{29,31,34,36,49,50,58,74,75} Moreover, transient but not persistent right PN palsy has been shown to occur more frequently using the second-generation as compared to the first-generation cryoballoon.^{47,49,52,94} This is likely due to the second-generation catheter's increased potency. Furthermore, PN palsy has also been shown to occur more frequently with the use of the 23-mm cryoballoon.^{44,94} In most cases, the latter is believed to be related to the deployment of a relatively undersized cryoballoon deeper inside the PV.⁹⁵ In addition to minimizing the physical distance between the cryoballoon and the PN, cryoablation at a relatively more distal position inside the right PVs may be more conducive to enhanced 'cold' transfer to deeper tissues such as the PN due to reduced convective heating of the balloon by atrial blood

flow.^{94–96} Hence, this may result in deeper penetration of cryoenergy, thereby increasing the risk of collateral injury.

Esophageal Injury

Esophageal thermal injury seems to occur with left atrial ablation virtually using any type of energy modality,^{97,98} including also cryoenergy.^{99–102} Furthermore, it is believed that in some patients this may represent a precursor to atri-esophageal fistula.¹⁰³ Early experiences using the first-generation cryoballoon suggested possibly a lack of esophageal thermal injury associated with cryoablation as assessed on post-procedural endoscopy, despite steep luminal esophageal temperature drops during catheter ablation.¹⁰⁴ Nonetheless, esophageal thermal injury and ulceration were subsequently demonstrated in other clinical studies,¹⁰⁵ particularly with the use of the second-generation cryoballoon which can be associated with esophageal ulcerations in as many as ≈20% of patients.^{106,107} It should be emphasized that this incidence generally remains similar and possibly lower than that reported with RF.¹⁰⁸ Though as with ablation using other energy modalities no precise measures have been identified to mitigate esophageal thermal injury, Fürnkranz et al.¹⁰⁷ found that a luminal esophageal temperature ≤12°C during cryoballoon ablation predicted esophageal ulceration with 100% sensitivity and 92% specificity. In a subsequent study,¹¹¹ these authors reported that by adopting a strategy of luminal esophageal temperature-guided cryoablation through interruption of ablation with esophageal temperatures ≤15°C, the esophageal ulceration rate decreased to 3%. As such, avoidance of ultra-cold luminal esophageal temperatures during cryoablation seems prudent.

Lung Injury

Both cough and hemoptysis have been reported following cryoablation of AF.^{112–118} A persistent dry cough can be detected more commonly in some patients following cryoballoon ablation. However, hemoptysis remains rather uncommon with an incidence ranging between 0–2.1%.^{114–116} Though hemoptysis can also occur in the setting of PV stenosis, most cases of hemoptysis following cryoablation do not seem to accompany such a complication.^{112–118} Furthermore, most overt cases of hemoptysis seem to manifest within hours to days following cryoablation,^{112–114,116} rendering the possibility of PV stenosis once again less likely. Instead, it has been postulated that transient interruption of vascular integrity, perhaps within the pulmonary capillary system due to cryoinjury, may serve as a possible culprit.^{113,114,116} Accordingly, some investigators have attributed this to colder balloon temperatures (<55°C) and deeper balloon positioning inside the PVs during cryoablation.^{112–114,116,117} CT imaging of patients with hemoptysis frequently demonstrates presence of edema surrounding the PV tissue sometimes with erosion,¹¹² with¹¹⁸ or without^{113,114,117} luminal narrowing. Mucosal hyperemia and erosion can also be detected during bronchoscopy.^{113,114} Some investigators have ascribed these findings to pulmonary infarction.¹¹⁶ While this remains unclear based on the reports to date, both the clinical symptoms and findings appear to be self-limiting with a gradual resolution over time.^{112–116} Furthermore, none of these cases have been associated with catastrophic complications such as formation of a fistula.

Conclusions

Over the past decade, cryoballoon ablation of AF has emerged as a practical, alternative strategy to point-by-point RF ablation. There seem to be several reasons for this. First, the acute and long-

term safety and efficacy associated with cryoablation appear to be similar to RF, in patients with both paroxysmal and also persistent AF. Second, this technology also offers certain advantages over conventional RF ablation including a gentler learning curve and relative ease of use, shorter ablation and procedure times, and lack of need for costly electroanatomical mapping equipment commonly used with RF ablation. More recently, with the advent of the second-generation cryoballoon, the effectiveness of cryoablation has further improved remarkably. Given that results from several cryoablation studies strongly suggest a greatly improved efficacy associated with the use of the second-generation cryoballoon, a prospective head-to-head comparison between the latter and force sensing RF seems appropriate. As such, we eagerly await the results of ongoing studies that are currently investigating this topic.

References

1. January CT, Wann LS, Alpert JS, Calkins H, Cigarroa JE, Cleveland JC Jr, Conti JB, Ellinor PT, Ezekowitz MD, Field ME, Murray KT, Sacco RL, Stevenson WG, Tchou PJ, Tracy CM, Yancy CW. 2014 AHA/ACC/HRS Guideline for the Management of Patients With Atrial Fibrillation: A Report of the American College of Cardiology/American Heart Association Task Force on Practice Guidelines and the Heart Rhythm Society. *J Am Coll Cardiol.* 2014;64:e1–e76.
2. Wokhlu A, Monahan KH, Hodge DO, Asirvatham SJ, Friedman PA, Munger TM, Bradley DJ, Bluhm CM, Haroldson JM, Packer DL. Longterm quality of life after ablation of atrial fibrillation the impact of recurrence, symptom relief, and placebo effect. *J Am Coll Cardiol.* 2010;55:2308–2316.
3. Piccini JP, Lopes RD, Kong MH, Hasselblad V, Jackson K, Al-Khatib SM. Pulmonary vein isolation for the maintenance of sinus rhythm in patients with atrial fibrillation: a meta-analysis of randomized, controlled trials. *Circ Arrhythm Electrophysiol.* 2009;2:626–633.
4. Pappone C, Rosanio S, Oreto G, Tocchi M, Gugliotta F, Vicedomini G, Salvati A, Dicandia C, Mazzone P, Santinelli V, Gulletta S, Chierchia S. Circumferential radiofrequency ablation of pulmonary vein ostia: a new anatomic approach for curing atrial fibrillation. *Circulation.* 2000;102:2619–2628.
5. Wilber DJ, Pappone C, Neuzil P, De Paola A, Marchlinski F, Natale A, Macle L, Daoud EG, Calkins H, Hall B, Reddy V, Augello G, Reynolds MR, Vinekar C, Liu CY, Berry SM, Berry DA; ThermoCool AF Trial Investigators. Comparison of antiarrhythmic drug therapy and radiofrequency catheter ablation in patients with paroxysmal atrial fibrillation: a randomized controlled trial. *JAMA.* 2010;303:333–340.
6. Oral H, Pappone C, Chugh A, Good E, Bogun F, Pelosi F Jr, Bates ER, Lehmann MH, Vicedomini G, Augello G, Agricola E, Sala S, Santinelli V, Morady F. Circumferential pulmonary-vein ablation for chronic atrial fibrillation. *N Engl J Med.* 2006;354:934–941.
7. Schmidt B, Metzner A, Chun KR, Leftheriotis D, Yoshiga Y, Fuernkranz A, Neven K, Tiltz RR, Wissner E, Ouyang F, Kuck KH. Feasibility of circumferential pulmonary vein isolation using a novel endoscopic ablation system. *Circ Arrhythm Electrophysiol.* 2010;3:481–488.
8. Packer DL, Kowal RC, Wheelan KR, Irwin JM, Champagne J, Guerra PG, Dubuc M, Reddy V, Nelson L, Holcomb RG, Lehmann JW, Ruskin JN; STOP AF Cryoablation Investigators. Cryoballoon ablation of pulmonary veins for paroxysmal atrial fibrillation: first results of the North American Arctic Front (STOP AF) pivotal trial. *J Am Coll Cardiol.* 2013;61:1713–1723.
9. Neven K, Metzner A, Schmidt B, Ouyang F, Kuck KH. Two-year clinical follow-up after pulmonary vein isolation using high-intensity focused ultrasound (HIFU) and an esophageal temperature-guided safety algorithm. *Heart Rhythm.* 2012;9:407–413.
10. Snyder KK, Baust JG, Baust JM, Gage AA. Mechanisms of cryoablation. In:

- Bredikis A, Wilber D, ed. *Cryoablation of Cardiac Arrhythmias*. Philadelphia, PA: Saunders; 2011:13–21.
11. Gage AA, Baust JM, Baust JG. Principles of cryosurgery. In: Rukstalis D, ed. *Handbook of Urological Cryoablation*. Abingdon, United Kingdom: Informa Healthcare; 2007:1–18.
 12. Lustgarten DL. History of cardiac cryosurgery and cryoablation. In: Bredikis A, Wilber D, ed. *Cryoablation of Cardiac Arrhythmias*. Philadelphia, PA: Saunders; 2011:3–12.
 13. Piccini JP, Daubert JP. Cryoablation of atrial fibrillation. *J Interv Card Electrophysiol*. 2011;32:233–242.
 14. Bredikis A, Wilber D. Factors that determine cryolesion formation and cryolesion characteristics. In: Bredikis A, Wilber D, ed. *Cryoablation of Cardiac Arrhythmias*. Philadelphia, PA: Saunders; 2011:22–39.
 15. Khairy P, Chauvet P, Lehmann J, Lambert J, Macle L, Tanguay JF, Sirois MG, Santoianni D, Dubuc M. Lower incidence of thrombus formation with cryoenergy versus radiofrequency catheter ablation. *Circulation*. 2003;107:2045–2050.
 16. Ghosh JI, Martin A, Keech AC, Chan KH, Gomes S, Singarayar S, McGuire MA. Balloon warming time is the strongest predictor of late pulmonary vein electrical reconnection following cryoballoon ablation for atrial fibrillation. *Heart Rhythm*. 2013;10:1311–1317.
 17. Ciconte G, Chierchia GB, DE Asmundis C, Sicira J, Conte G, Juliá J, DI Giovanni G, Wauters K, Baltogiannis G, Saitoh Y, Mugnai G, Catanzariti D, Tondo C, Brugada P. Spontaneous and adenosine-induced pulmonary vein reconnection after cryoballoon ablation with the second-generation device. *J Cardiovasc Electrophysiol*. 2014;25:845–851.
 18. Tse HF, Reek S, Timmermans C, Lee KL, Geller JC, Rodriguez LM, Ghaye B, Ayers GM, Crijns HJ, Klein HU, Lau CP. Pulmonary vein isolation using transvenous catheter cryoablation for treatment of atrial fibrillation without risk of pulmonary vein stenosis. *J Am Coll Cardiol*. 2003;42:752–758.
 19. Hoyt RH, Wood M, Daoud E, Feld G, Sehra R, Pelkey W, Kay GN, Calkins H; U.S. CryoCor Investigators. Transvenous catheter cryoablation for treatment of atrial fibrillation: results of a feasibility study. *Pacing Clin Electrophysiol*. 2005;28 Suppl 1:S78–S82.
 20. Kenigsberg DN, Wood MA, Alaeddini J, Ellenbogen KA. Cryoablation inside the pulmonary vein after failure of radiofrequency antral isolation. *Heart Rhythm*. 2007;4:992–996.
 21. Ahmed H, Neuzil P, d'Avila A, Cha YM, Laragy M, Mares K, Brugge WR, Forcione DG, Ruskin JN, Packer DL, Reddy VY. The esophageal effects of cryoenergy during cryoablation for atrial fibrillation. *Heart Rhythm*. 2009;6:962–969.
 22. Kuniss M, Vogtmann T, Ventura R, Willems S, Vogt J, Grönefeld G, Hohnloser S, Zrenner B, Erdogan A, Klein G, Lemke B, Neuzner J, Neumann T, Hamm CW, Pitschner HF. Prospective randomized comparison of durability of bidirectional conduction block in the cavotricuspid isthmus in patients after ablation of common atrial flutter using cryotherapy and radiofrequency energy: the CRYOTIP study. *Heart Rhythm*. 2009;6:1699–1705.
 23. Feld GK, Yao B. Evaluation of the safety and effectiveness of the CryoMedix cryoablation catheter system for the treatment of atrial flutter and fibrillation. *J Interv Card Electrophysiol*. 2014;39:37–44.
 24. Skanes AC, Jensen SM, Papp R, Li J, Yee R, Krahn AD, Klein GJ. Isolation of pulmonary veins using a transvenous curvilinear cryoablation catheter: feasibility, initial experience, and analysis of recurrences. *J Cardiovasc Electrophysiol*. 2005;16:1304–1308.
 25. Avitall B, Urboniene D, Rozmus G, Lafontaine D, Helms R, Urbonas A. New cryotechnology for electrical isolation of the pulmonary veins. *J Cardiovasc Electrophysiol*. 2003;14:281–286.
 26. Sarabanda AV, Bunch TJ, Johnson SB, Mahapatra S, Milton MA, Leite LR, Bruce GK, Packer DL. Efficacy and safety of circumferential pulmonary vein isolation using a novel cryothermal balloon ablation system. *J Am Coll Cardiol*. 2005;46:1902–1912.
 27. Doshi SK, Laragy M, Pitchner H, Pitchner HF, Irwin J, Cole C, Neuzil P, Kuniss M, Ruskin JN, Reddy VY. The additive efficacy of a novel balloon cryoablation catheter to standard cryoablation for PV isolation in patients with symptomatic atrial fibrillation. *Heart Rhythm*. 2005;2:S26–S27.
 28. Malmberg H, Lönnerholm S, Blomström P, Blomström-Lundqvist C. Ablation of atrial fibrillation with cryoballoon or duty-cycled radiofrequency pulmonary vein ablation catheter: a randomized controlled study comparing the clinical outcome and safety; the AF-COR study. *Europace*. 2013;15:1567–1573.
 29. Neumann T, Vogt J, Schumacher B, Dorszewski A, Kuniss M, Neuser H, Kurzidim K, Berkowitsch A, Koller M, Heintze J, Scholz U, Wetzel U, Schneider MA, Horstkotte D, Hamm CW, Pitschner HF. Circumferential pulmonary vein isolation with the cryoballoon technique results from a prospective 3-center study. *J Am Coll Cardiol*. 2008;52:273–278.
 30. Klein G, Oswald H, Gardiwal A, Lüsebrink U, Lissel C, Yu H, Drexler H. Efficacy of pulmonary vein isolation by cryoballoon ablation in patients with paroxysmal atrial fibrillation. *Heart Rhythm*. 2008;5:802–806.
 31. Van Belle Y, Janse P, Theuns D, Szili-Torok T, Jordaens L. One year follow-up after cryoballoon isolation of the pulmonary veins in patients with paroxysmal atrial fibrillation. *Europace*. 2008;10:1271–1276.
 32. Chun KR, Schmidt B, Metzner A, Tilz R, Zerm T, Köster I, Fürnkranz A, Koektuerk B, Konstantinidou M, Antz M, Ouyang F, Kuck KH. The 'single big cryoballoon' technique for acute pulmonary vein isolation in patients with paroxysmal atrial fibrillation: a prospective observational single centre study. *Eur Heart J*. 2009;30:699–709.
 33. Defaye P, Kane A, Chaib A, Jacon P. Efficacy and safety of pulmonary veins isolation by cryoablation for the treatment of paroxysmal and persistent atrial fibrillation. *Europace*. 2011;13:789–795.
 34. Vogt J, Heintze J, Gutleben KJ, Muntean B, Horstkotte D, Nölker G. Long-term outcomes after cryoballoon pulmonary vein isolation: results from a prospective study in 605 patients. *J Am Coll Cardiol*. 2013;61:1707–1712.
 35. Ferrero-de Loma-Osorio A, Izquierdo-de Francisco M, Martínez-Brotons A, Sánchez-Gómez JM, Mascarell-Gregori B, Ruiz-Ros V, Cuenca-Romero I, García-Civera R, Chorro-Gascó FJ, Ruiz-Granell R. Medium-term results of cryoballoon ablation of the pulmonary veins in patients with paroxysmal and persistent atrial fibrillation. First experience of a Spanish center. *J Interv Card Electrophysiol*. 2013;37:189–196.
 36. Aytémir K, Oto A, Canpolat U, Sunman H, Yorgun H, Şahiner L, Kaya EB. Immediate and medium-term outcomes of cryoballoon-based pulmonary vein isolation in patients with paroxysmal and persistent atrial fibrillation: single-centre experience. *J Interv Card Electrophysiol*. 2013;38:187–195.
 37. Rao JY, Chierchia GB, de Asmundis C, Casado-Arroyo R, Overeinder I, Sarkozy A, Paparella G, Capulzini L, Sorgente A, Rodriguez-Manero M, Ricciardi D, Namdar M, Brugada P. Cryoballoon ablation as index procedure for paroxysmal atrial fibrillation: long-term results from a single center early experience. *J Cardiovasc Med*. 2014;15:194–198.
 38. Andrade JG, Khairy P, Guerra PG, Deyell MW, Rivard L, Macle L, Thibault B, Talajic M, Roy D, Dubuc M. Efficacy and safety of cryoballoon ablation for atrial fibrillation: a systematic review of published studies. *Heart Rhythm*. 2011;8:1444–1451.
 39. Yorgun H, Aytémir K, Canpolat U, Şahiner L, Kaya EB, Oto A. Additional benefit of cryoballoon-based atrial fibrillation ablation beyond pulmonary vein isolation: modification of ganglionated plexi. *Europace*. 2014;16:645–651.
 40. Fürnkranz A, Chun KR, Nuyens D, Metzner A, Köster I, Schmidt B, Ouyang F, Kuck KH. Characterization of conduction recovery after pulmonary vein isolation using the "single big cryoballoon" technique. *Heart Rhythm*. 2010;7:184–190.
 41. Takami M, Misiri J, Lehmann HI, Parker KD, Johnson SB, Sarmiento RI, Packer

- DL. The Spatial and Time-Course Thermodynamics During Pulmonary Vein Isolation Using the 2nd Generation Cryoballoon in a Canine in Vivo Model. *Circ Arrhythm Electrophysiol.* 2015;8:186–192.
42. Knecht S, Kühne M, Osswald S, Sticherling C. Quantitative assessment of a second-generation cryoballoon ablation catheter with new cooling technology—a perspective on potential implications on outcome. *J Interv Card Electrophysiol.* 2014;40:17–21.
 43. Coulombe N, Paulin J, Su W. Improved in vivo performance of second-generation cryoballoon for pulmonary vein isolation. *J Cardiovasc Electrophysiol.* 2013;24:919–925.
 44. Andrade JG, Dubuc M, Guerra PG, Landry E, Coulombe N, Leduc H, Rivard L, Macle L, Thibault B, Talajic M, Roy D, Khairy P. Pulmonary vein isolation using a second-generation cryoballoon catheter: a randomized comparison of ablation duration and method of deflation. *J Cardiovasc Electrophysiol.* 2013;24:692–698.
 45. Kenigsberg DN, Martin N, Lim HW, Kowalski M, Ellenbogen KA. Quantification of the cryoablation zone demarcated by pre- and postprocedural electroanatomic mapping in atrial fibrillation patients using the 28-mm second-generation cryoballoon. *Heart Rhythm.* 2015;12:283–290.
 46. Reddy VY, Sediva L, Petru J, Skoda J, Chovanec M, Chitovova Z, DI Stefano P, Rubin E, Dukkipati S, Neuzil P. Durability of Pulmonary Vein Isolation with Cryoballoon Ablation: Results from the SUSTAINED PV Isolation with ARctic Front Advance (SUPIR) Study. *J Cardiovasc Electrophysiol.* 2015; 26:493–500.
 47. Martins RP, Hamon D, Césari O, Behaghel A, Behar N, Sellal JM, Daubert JC, Mabo P, Pavin D. Safety and efficacy of a second-generation cryoballoon in the ablation of paroxysmal atrial fibrillation. *Heart Rhythm.* 2014;11:386–393.
 48. Fünkrantz A, Bordignon S, Schmidt B, Gunawardene M, Schulte-Hahn B, Urban V, Bode F, Nowak B, Chun JK. Improved procedural efficacy of pulmonary vein isolation using the novel second-generation cryoballoon. *J Cardiovasc Electrophysiol.* 2013;24:492–497.
 49. Aryana A, Morkoch S, Bailey S, Lim HW, Sara R, d'Avila A, O'Neill PG. Acute procedural and cryoballoon characteristics from cryoablation of atrial fibrillation using the first- and second-generation cryoballoon: a retrospective comparative study with follow-up outcomes. *J Interv Card Electrophysiol.* 2014;41:177–186.
 50. Straube F, Dorwarth U, Schmidt M, Wankerl M, Ebersberger U, Hoffmann E. Comparison of the first and second cryoballoon: high-volume single-center safety and efficacy analysis. *Circ Arrhythm Electrophysiol.* 2014;7:293–299.
 51. Fünkrantz A, Bordignon S, Dugo D, Perotta L, Gunawardene M, Schulte-Hahn B, Nowak B, Schmidt B, Chun JK. Improved 1-year clinical success rate of pulmonary vein isolation with the second-generation cryoballoon in patients with paroxysmal atrial fibrillation. *J Cardiovasc Electrophysiol.* 2014;25:840–844.
 52. Di Giovanni G, Wauters K, Chierchia GB, Sieira J, Levinstein M, Conte G, de Asmundis C, Baltogiannis G, Saitoh Y, Ciconte G, Julia J, Mugnai G, Irfan G, Brugada P. One-year follow-up after single procedure Cryoballoon ablation: a comparison between the first and second generation balloon. *J Cardiovasc Electrophysiol.* 2014;25:834–839.
 53. Liu J, Kaufmann J, Kriatselis C, Fleck E, Gerds-Li JH. Second Generation of Cryoballoons Can Improve Efficiency of Cryoablation for Atrial Fibrillation. *Pacing Clin Electrophysiol.* 2015;38:129–135.
 54. Bordignon S, Fünkrantz A, Dugo D, Perotta L, Gunawardene M, Bode F, Klemm A, Nowak B, Schulte-Hahn B, Schmidt B, Chun KR. Improved lesion formation using the novel 28 mm cryoballoon in atrial fibrillation ablation: analysis of biomarker release. *Europace.* 2014;16:987–993.
 55. Chierchia GB, Di Giovanni G, Ciconte G, de Asmundis C, Conte G, Sieira-Moret J, Rodriguez-Mañero M, Casado R, Baltogiannis G, Namdar M, Saitoh Y, Paparella G, Mugnai G, Brugada P. Second-generation cryoballoon ablation for paroxysmal atrial fibrillation: 1-year follow-up. *Europace.* 2014;16:639–644.
 56. Metzner A, Reissmann B, Rausch P, Mathew S, Wohlmuth P, Tilz R, Rillig A, Lemes C, Deiss S, Heeger C, Kamioka M, Lin T, Ouyang F, Kuck KH, Wissner E. One-year clinical outcome after pulmonary vein isolation using the second-generation 28-mm cryoballoon. *Circ Arrhythm Electrophysiol.* 2014;7:288–292.
 57. Ciconte G, de Asmundis C, Sieira J, et al. Single 3-minute freeze for second-generation cryoballoon ablation: One-year follow-up after pulmonary vein isolation. *Heart Rhythm.* 2015;12:673–680.
 58. Aryana A, Singh SM, Kowalski M, Pujara DK, Cohen AI, Singh SK, Aleong RG, Banker RS, Fuenzalida CE, Prager NA, Bowers MR, d'Avila A, O'Neill PG. Acute and long-term outcomes of catheter ablation of atrial fibrillation using the second-generation cryoballoon versus open-irrigated radiofrequency: a multicenter experience. *J Cardiovasc Electrophysiol.* 2015;26:832–839.
 59. Chierchia GB, de Asmundis C, Namdar M, Westra S, Kuniss M, Sarkozy A, Bayrak F, Ricciardi D, Casado-Arroyo R, Rodriguez Manero M, Rao JY, Smeets J, Brugada P. Pulmonary vein isolation during cryoballoon ablation using the novel Achieve inner lumen mapping catheter: a feasibility study. *Europace.* 2012;14:962–967.
 60. Kühne M, Knecht S, Altmann D, Ammann P, Schaer B, Osswald S, Sticherling C. Validation of a novel spiral mapping catheter for real-time recordings from the pulmonary veins during cryoballoon ablation of atrial fibrillation. *Heart Rhythm.* 2013;10:241–246.
 61. Boveda S, Providência R, Albenque JP, Combes N, Combes S, Hireche H, Casteigt B, Bouzeman A, Jourda F, Narayanan K, Marijon E. Real-time assessment of pulmonary vein disconnection during cryoablation of atrial fibrillation: can it be 'achieved' in almost all cases? *Europace.* 2014;16:826–833.
 62. Sorgente A, Chierchia GB, de Asmundis C, Sarkozy A, Namdar M, Capulzini L, Yazaki Y, Müller-Burri SA, Bayrak F, Brugada P. Pulmonary vein ostium shape and orientation as possible predictors of occlusion in patients with drug-refractory paroxysmal atrial fibrillation undergoing cryoballoon ablation. *Europace.* 2011;13:205–212.
 63. Kubala M, Hermida JS, Nadji G, Quenum S, Traulle S, Jarry G. Normal pulmonary veins anatomy is associated with better AF-free survival after cryoablation as compared to atypical anatomy with common left pulmonary vein. *Pacing Clin Electrophysiol.* 2011;34:837–843.
 64. Ghosh J, Martin A, Keech AC, Chan KH, Gomes S, Singarayay S, McGuire MA. Balloon warming time is the strongest predictor of late pulmonary vein electrical reconnection following cryoballoon ablation for atrial fibrillation. *Heart Rhythm.* 2013;10:1311–1317.
 65. Aryana A, Lim HW, Kowalski M, Hokanson RB, Parikh V, Torbey E, Bowers MR, O'Neill PG. With catheter ablation using the second-generation cryoballoon only thaw time and freeze area-under-the-curve were predictive of long-term freedom from atrial fibrillation. *Heart Rhythm.* 2015;12:S65.
 66. Fünkrantz A, Köster I, Chun KR, Metzner A, Mathew S, Konstantinidou M, Ouyang F, Kuck KH. Cryoballoon temperature predicts acute pulmonary vein isolation. *Heart Rhythm.* 2011;8:821–825.
 67. Andrade JG, Khairy P, Macle L, Packer DL, Lehmann JW, Holcomb RG, Ruskin JN, Dubuc M. Incidence and significance of early recurrences of atrial fibrillation after cryoballoon ablation: insights from the multicenter Sustained Treatment of Paroxysmal Atrial Fibrillation (STOP AF) Trial. *Circ Arrhythm Electrophysiol.* 2014;7:69–75.
 68. Linhart M, Bellmann B, Mittmann-Braun E, Schrickel JW, Bitzen A, Andrié R, Yang A, Nickenig G, Lickfett L, Lewalter T. Comparison of cryoballoon and radiofrequency ablation of pulmonary veins in 40 patients with paroxysmal atrial fibrillation: a case-control study. *J Cardiovasc Electrophysiol.* 2009;20:1343–1348.
 69. Kojodjojo P, O'Neill MD, Lim PB, Malcolm-Lawes L, Whinnett ZI, Salukhe TV, Linton NW, Lefroy D, Mason A, Wright I, Peters NS, Kanagaratnam P, Davies DW. Pulmonary venous isolation by antral ablation with a large cryoballoon for treatment of paroxysmal and persistent atrial fibrillation: medium-term outcomes and non-randomised comparison with pulmonary venous isolation by radiofrequency ablation. *Heart.* 2010;96:1379–1384.

70. Tayebjee MH, Hunter RJ, Baker V, Creta A, Duncan E, Sporton S, Earley MJ, Schilling RJ. Pulmonary vein isolation with radiofrequency ablation followed by cryotherapy: a novel strategy to improve clinical outcomes following catheter ablation of paroxysmal atrial fibrillation. *Europace*. 2011;13:1250–1255.
71. Kühne M, Suter Y, Altmann D, Ammann P, Schaer B, Osswald S, Sticherling C. Cryoballoon versus radiofrequency catheter ablation of paroxysmal atrial fibrillation: biomarkers of myocardial injury, recurrence rates, and pulmonary vein reconnection patterns. *Heart Rhythm*. 2010;7:1770–1776.
72. Sorgente A, Chierchia GB, Capulzini L, Yazaki Y, Muller-Burri A, Bayrak F, Sarkozy A, de Asmundis C, Paparella G, Brugada B. Atrial fibrillation ablation: a single center comparison between remote magnetic navigation, cryoballoon and conventional manual pulmonary vein isolation. *Indian Pacing Electrophysiol J*. 2010;10:486–495.
73. Herrera Siklódy C, Arentz T, Minners J, Jesel L, Stratz C, Valina CM, Weber R, Kalusche D, Toti F, Morel O, Trenk D. Cellular damage, platelet activation, and inflammatory response after pulmonary vein isolation: a randomized study comparing radiofrequency ablation with cryoablation. *Heart Rhythm*. 2012;9:189–196.
74. Schmidt M, Dorwarth U, Andresen D, Brachmann J, Kuck KH, Kuniss M, Lewalter T, Spitzer S, Willems S, Senges J, Jünger C, Hoffmann E. Cryoballoon versus RF ablation in paroxysmal atrial fibrillation: results from the German Ablation Registry. *J Cardiovasc Electrophysiol*. 2014;25:1–7.
75. Mugnai G, Chierchia GB, de Asmundis C, Sieira-Moret J, Conte G, Capulzini L, Wauters K, Rodriguez-Mañero M, Di Giovanni G, Baltogiannis G, Ciconte G, Saitoh Y, Juliá J, Brugada P. Comparison of pulmonary vein isolation using cryoballoon versus conventional radiofrequency for paroxysmal atrial fibrillation. *Am J Cardiol*. 2014;113:1509–1513.
76. Juliá J, Chierchia GB, de Asmundis C, Mugnai G, Sieira J, Ciconte G, Di Giovanni G, Conte G, Baltogiannis G, Saitoh Y, Wauters K, Irfan G, Brugada P. Regular atrial tachycardias following pulmonary vein isolation for paroxysmal atrial fibrillation: a retrospective comparison between the cryoballoon and conventional focal tip radiofrequency techniques. *J Interv Card Electrophysiol*. 2015;42:161–169.
77. Xu J, Huang Y, Cai H, Qi Y, Jia N, Shen W, Lin J, Peng F, Niu W. Is cryoballoon ablation preferable to radiofrequency ablation for treatment of atrial fibrillation by pulmonary vein isolation? A meta-analysis. *PLoS One*. 2014;9:e90323.
78. Chinitz JS, Kulina RA, Gangireddy SR, Miller MA, Koruth JS, Dukkipati SR, Halperin JL, Reddy VY, d'Avila A. Objective quality assessment of atrial fibrillation ablation: A novel scoring system. *Heart Rhythm*. 2013;10:1074–1079.
79. Jourda F, Providencia R, Marijon E, Bouzeman A, Hireche H, Khoueiry Z, Cardin C, Combes N, Combes S, Boveda S, Albenque JP. Contact-force guided radiofrequency vs. second-generation balloon cryotherapy for pulmonary vein isolation in patients with paroxysmal atrial fibrillation—a prospective evaluation. *Europace*. 2015;17:225–231.
80. Torbey E, Parikh V, Agarwal V, Bekheit S, Kowalski M. Treatment of long persistent atrial fibrillation by single cryoballoon ablation of the pulmonary veins, LA roof line and ablation of left lateral ridge from within the appendage. *Heart Rhythm*. 2014; 11:S364.
81. Frazier DW, Barrett KG. Linear lesions with Medtronic cryoballoon – posterior left atrial wall isolation. *AF symposium*. 2015 (abstract).
82. Torbey E, Aryana A, Parikh V, Agarwal V, Bekheit S, O'Neill PG, Kowalski M. Treatment of Long-standing persistent atrial fibrillation by single cryoballoon ablation of the pulmonary veins, left atrial roof and left lateral ridge lesions. 2015; in Press.
83. Kumar N, Pison L, La Meir M, Maessen J, Crijns HJ. Hybrid approach to atrial fibrillation ablation using bipolar radiofrequency devices epicardially and cryoballoon endocardially. *Interact Cardiovasc Thorac Surg*. 2014;19:590–594.
84. Mittal S, Sperling JS, Arshad A, Musat D, Preminger M, Sichrovsky T, Steinberg JS. The efficacy of a novel hybrid ablation procedure in patients with refractory atrial fibrillation. *ESC*. 2014 (abstract); P3343.
85. Bhat T, Baydoun H, Asti D, Rijal J, Teli S, Tantray M, Bhat H, Kowalski M. Major complications of cryoballoon catheter ablation for atrial fibrillation and their management. *Expert Rev Cardiovasc Ther*. 2014;12:1111–1118.
86. Neumann T, Kuniss M, Conradi G, Janin S, Berkowitsch A, Wojcik M, Rixe J, Erkapic D, Zaltsberg S, Rolf A, Bachmann G, Dill T, Hamm CW, Pitschner HF. MEDAFI-Trial (Micro-embolization during ablation of atrial fibrillation): comparison of pulmonary vein isolation using cryoballoon technique vs. radiofrequency energy. *Europace*. 2011;13:37–44.
87. Chierchia GB, Capulzini L, Droogmans S, Sorgente A, Sarkozy A, Müller-Burri A, Paparella G, de Asmundis C, Yazaki Y, Kerkhove D, Van Camp G, Brugada P. Pericardial effusion in atrial fibrillation ablation: a comparison between cryoballoon and radiofrequency pulmonary vein isolation. *Europace*. 2010;12:337–341.
88. Chan NY, Choy CC, Lau CL, Lo YK, Chu PS, Yuen HC, Mok NS, Tsui PT, Lau ST. Persistent iatrogenic atrial septal defect after pulmonary vein isolation by cryoballoon: an under-recognized complication. *Europace*. 2011;13:1406–1410.
89. Cronin EM, Collier P, Wazni OM, Griffin BP, Jaber WA, Saliba WI. Persistence of atrial septal defect after cryoballoon ablation of atrial fibrillation. *J Am Coll Cardiol*. 2013;62:1491–1492.
90. Sieira J, Chierchia GB, Di Giovanni G, Conte G, De Asmundis C, Sarkozy A, Droogmans S, Baltogiannis G, Saitoh Y, Ciconte G, Levinstein M, Brugada P. One year incidence of iatrogenic atrial septal defect after cryoballoon ablation for atrial fibrillation. *J Cardiovasc Electrophysiol*. 2014;25:11–15.
91. Sacher F, Monahan KH, Thomas SP, Davidson N, Adragao P, Sanders P, Hocini M, Takahashi Y, Rotter M, Rostock T, Hsu LF, Clementy J, Haissaguerre M, Ross DL, Packer DL, Jais P. Phrenic nerve injury after atrial fibrillation catheter ablation: characterization and outcome in a multicenter study. *J Am Coll Cardiol*. 2006;47:2498–2503.
92. Cappato R, Calkins H, Chen SA, Davies W, Iesaka Y, Kalman J, Kim YH, Klein G, Packer D, Skanes A. Worldwide survey on the methods, efficacy, and safety of catheter ablation for human atrial fibrillation. *Circulation* 2005;111:1100–1105.
93. Andrade JG, Dubuc M, Ferreira J, Guerra PG, Landry E, Coulombe N, Rivard L, Macle L, Thibault B, Talajic M, Roy D, Khairy P. Histopathology of cryoballoon ablation-induced phrenic nerve injury. *J Cardiovasc Electrophysiol*. 2014;25:187–194.
94. Casado-Arroyo R, Chierchia GB, Conte G, Levinstein M, Sieira J, Rodriguez-Mañero M, Di Giovanni G, Baltogiannis Y, Wauters K, de Asmundis C, Sarkozy A, Brugada P. Phrenic nerve paralysis during cryoballoon ablation for atrial fibrillation: A comparison between the first- and second-generation balloon. *Heart Rhythm*. 2013;10:1318–1324.
95. Andrade JG, Dubuc M, Guerra PG, Macle L, Mondésert B, Rivard L, Roy D, Talajic M, Thibault B, Khairy P. The biophysics and biomechanics of cryoballoon ablation. *Pacing Clin Electrophysiol*. 2012;35:1162–1168.
96. Franceschi F, Dubuc M, Guerra PG, Delisle S, Romeo P, Landry E, Koutbi L, Rivard L, Macle L, Thibault B, Talajic M, Roy D, Khairy P. Diaphragmatic electromyography during cryoballoon ablation: a novel concept in the prevention of phrenic nerve palsy. *Heart Rhythm*. 2011;8:885–891.
97. Pappone C, Oral H, Santinelli V, Vicedomini G, Lang CC, Manguso F, Torracca L, Benussi S, Alfieri O, Hong R, Lau W, Hirata K, Shikuma N, Hall B, Morady F. Atrio-esophageal fistula as a complication of percutaneous transcatheter ablation of atrial fibrillation. *Circulation*. 2004;109:2724–2726.
98. Borchert B, Lawrenz T, Hansky B, Stellbrink C. Lethal atrioesophageal fistula after pulmonary vein isolation using high-intensity focused ultrasound (HIFU). *Heart Rhythm*. 2008;5:145–148.
99. Kawasaki R, Gauri A, Elmouchi D, Duggal M, Bhan A. Atrioesophageal fistula complicating cryoballoon pulmonary vein isolation for paroxysmal atrial fibrillation. *J Cardiovasc Electrophysiol*. 2014;25:787–792.

100. Lim HW, Cogert GA, Cameron CS, Cheng VY, Sandler DA. Atrioesophageal Fistula during Cryoballoon Ablation for Atrial Fibrillation. *J Cardiovasc Electrophysiol.* 2014;25:208–213.
101. Viladés Medel D, Martí-Almor J, Montiel Serrano J, Sionis A, Leta Petracca R. Atrioesophageal fistula secondary to pulmonary vein cryo-ablation. *Eur Heart J Cardiovasc Imaging.* 2014;15:116.
102. Stöckigt F, Schrickel JW, Andrié R, Lickfett L. Atrioesophageal fistula after cryoballoon pulmonary vein isolation. *J Cardiovasc Electrophysiol* 2012; 23:1254–1257.
103. Grubina R, Cha YM, Bell MR, Sinak LJ, Asirvatham SJ. Pneumopericardium following radiofrequency ablation for atrial fibrillation: insights into the natural history of atrial esophageal fistula formation. *J Cardiovasc Electrophysiol.* 2010;21:1046–1049.
104. Fürnkranz A, Chun KR, Metzner A, Nuyens D, Schmidt B, Burchard A, Tilz R, Ouyang F, Kuck KH. Esophageal endoscopy results after pulmonary vein isolation using the single big cryoballoon technique. *J Cardiovasc Electrophysiol.* 2010;21:869–874.
105. Ahmed H, Neuzil P, d'Avila A, Cha YM, Laragy M, Mares K, Brugge WR, Forcione DG, Ruskin JN, Packer DL, Reddy VY. The esophageal effects of cryoenergy during cryoablation for atrial fibrillation. *Heart Rhythm.* 2009;6:962–969.
106. Metzner A, Burchard A, Wohlmuth P, Rausch P, Bardyszewski A, Gienapp C, Tilz RR, Rillig A, Mathew S, Deiss S, Makimoto H, Ouyang F, Kuck KH, Wissner E. Increased incidence of esophageal thermal lesions using the second-generation 28-mm cryoballoon. *Circ Arrhythm Electrophysiol.* 2013;6:769–775.
107. Fürnkranz A, Bordignon S, Schmidt B, Böhmig M, Böhmer MC, Bode F, Schulte-Hahn B, Nowak B, Dignaß AU, Chun JK. Luminal esophageal temperature predicts esophageal lesions after second-generation cryoballoon pulmonary vein isolation. *Heart Rhythm.* 2013;10:789–793.
108. Zellerhoff S, Ullerich H, Lenze F, Meister T, Wasmer K, Mönnig G, Köbe J, Milberg P, Bittner A, Domschke W, Breithardt G, Eckardt L. Damage to the esophagus after atrial fibrillation ablation: Just the tip of the iceberg? High prevalence of mediastinal changes diagnosed by endosonography. *Circ Arrhythm Electrophysiol.* 2010;3:155–159.
109. Di Biase L, Dodig M, Saliba W, Siu A, Santisi J, Poe S, Sanaka M, Upchurch B, Vargo J, Natale A. Capsule endoscopy in examination of esophagus for lesions after radiofrequency catheter ablation: a potential tool to select patients with increased risk of complications. *J Cardiovasc Electrophysiol.* 2010;21:839–844.
110. Schmidt M1, Nölker G, Marschang H, Gutleben KJ, Schibgilla V, Rittger H, Sinha AM, Ritscher G, Mayer D, Brachmann J, Marrouche NF. Incidence of oesophageal wall injury post-pulmonary vein antrum isolation for treatment of patients with atrial fibrillation. *Europace.* 2008;10:205–209.
111. Fürnkranz A, Bordignon S, Böhmig M, Konstantinou A, Dugo D, Perrotta L, Klopffleisch T, Nowak B, Dignaß AU, Schmidt B, Chun JK. Reduced incidence of esophageal lesions by luminal esophageal temperature-guided second-generation cryoballoon ablation. *Heart Rhythm.* 2015;12:268–274.
112. van Opstal JM, Timmermans C, Blaauw Y, Pison L. Bronchial erosion and hemoptysis after pulmonary vein isolation by cryoballoon ablation. *Heart Rhythm.* 2011;8:1459.
113. Martí-Almor J, Jauregui-Abularach ME, Benito B, Vallès E, Bazan V, Sánchez-Font A, Vollmer I, Altaba C, Guijo MA, Hervas M, Bruguera-Cortada J. Pulmonary hemorrhage after cryoballoon ablation for pulmonary vein isolation in the treatment of atrial fibrillation. *Chest.* 2014;145:156–157.
114. Kumar N, Timmermans C, Das M, Dassen W, Philippens S, Maessen J, Crijns HJ. Hemoptysis after cryoablation for atrial fibrillation: truth or just a myth? *Chest.* 2014;146:e173–e175.
115. Vogt J, Heintze J, Noelker G, Gutleben KJ, Horstkotte D. Long Term Efficacy and Side Effects of Antral Isolation of Pulmonary Veins With Cryoballoon Technique in a Large Patient Cohort With Atrial Fibrillation. *Circulation.* 2009;120: S706.
116. Bhagwandien R, Van Belle Y, de Groot N, Jordaens L. Hemoptysis after pulmonary vein isolation with a cryoballoon: an analysis of the potential etiology. *J Cardiovasc Electrophysiol.* 2011;22(9):1067–1069.
117. Weig HJ, Weretka S, Parade U, et al. Cryo-specific complications using the single big cryoballoon technique for pulmonary vein isolation in patients with paroxysmal atrial fibrillation. *Eur Heart J.* 2010 (abstract); 31(suppl 1):556.
118. Malmborg H, Lönnerholm S, Blomström-Lundqvist C. Acute and clinical effects of cryoballoon pulmonary vein isolation in patients with symptomatic paroxysmal and persistent atrial fibrillation. *Europace.* 2008;10:1277–1280.