

MÖBIUS'S SYNDROME*

BY

HOWARD REED† AND WALLACE GRANT‡

Children's Hospital, Winnipeg, Canada

Various terms have been applied to this condition: Möbius's syndrome, congenital facial diplegia, congenital oculo-facial paralysis, nuclear agenesis, and congenital nuclear aplasia. It was originally described by von Graefe (1880), Harlan (1881), and Chisolm (1882). Möbius (1892) collected 43 cases of congenital and acquired cranial nerve palsies and classified them into six groups. One group consisted of six cases of bilateral abducens and facial nerve palsies. Since then Möbius's name has been associated with this condition.

It is relatively uncommon and its bizarre association of lesions may cause affected children to be taken to a paediatrician, an orthopaedic surgeon, an ophthalmologist, or a child psychiatrist. The purposes of the present paper are to record three more cases of this rare condition, to report the absence of any association with Rh incompatibility, and to suggest that the clue to its aetiology may lie in a more detailed investigation of pregnancy histories.

A typical case of Möbius's syndrome shows the following features:

(1) *Bilateral Facial Palsy*.—This is the most obvious feature and it may or may not be complete. If it is not complete the lower part of the face is usually less affected than the upper. This is unlike a supranuclear facial palsy in which the upper part of the face escapes, nor does it resemble a nerve trunk lesion in which the whole side of the face is equally affected.

Another feature characteristic of this condition is the absence of the sagging of the facial tissues, which is so disfiguring a feature of acquired seventh-nerve palsies. If the flesh of the cheek is palpated between finger and thumb it feels peculiarly thin. Contraction of the facial muscles, like that which occurs in cases of Bell's palsy with recovery, is never seen.

Invariably there is a history of sucking and feeding problems in infancy. Dribbling tends to persist into childhood, and when the child is eating, food tends to lodge in the cheeks and has to be pushed out with the fingers.

The orbicularis oculi muscle is defective so that there is incomplete closure of the lids in sleep, infrequent blinking, tearing, and a tendency to a recurrent low-grade kerato-conjunctivitis from exposure.

(2) *Absence of Abduction* of either eye beyond the mid-line, and palsy of the horizontal gaze, so that when looking to either side the child must turn the head.

(3) *Convergence*.—This is usually present but defective. The pupils constrict normally during convergence.

(4) *Vertical Gaze*.—Movements are normal and Bell's phenomenon is intact.

(5) *Convergent Strabismus* is occasionally present.

* Received for publication, June 3, 1957.

† Ophthalmologist, Winnipeg Clinic, Winnipeg, Manitoba.

‡ Medical Director, Out-Patient Department, Children's Hospital, and Associate Professor of Paediatrics, University of Manitoba, Canada.

(6) *Other Cranial Nerves* may be affected. The hypoglossal nerve may be involved so that the tongue is shrunken and relatively immobile. The motor root of the trigeminal nerve may be affected so that the child has a weak bite. The movements of the soft palate may be defective.

(7) *Other Developmental Anomalies* which occur less commonly are micrognathos, polydactyly, talipes, haemangiomata, and absent pectoralis muscle, and absent breast.

(8) *Mental Deficiency* is often present.

Case Reports

Case 1, a girl aged 4 years, was first seen at the Children's Hospital at the age of 20 weeks. This was the mother's first pregnancy at the age of 27. The father was healthy and there was no consanguinity or history of any familial deformities.

During the first 2 months of the pregnancy the mother had considerable nausea and on one occasion in the second month she fell downstairs. The pregnancy and birth were otherwise normal. The birth weight was 6 pounds 13 ounces. No jaundice or convulsions occurred but from birth there were feeding difficulties. Sucking was performed by compressing the nipple between tongue and palate without any use of the lips.

At the age of 5 months she was seen by Dr. I. H. Beckman of the Children's Hospital who reported:

The fundi and media are normal. She has a convergent squint which appears to be due to spasm or fibrosis of the internal recti.

At this time one drop of atropine 0.5 per cent. was instilled into each eye and it caused a severe reaction and a temperature of 101° F.

Examination.—At 4 years of age the visual acuity in each eye was 20/30 by the illiterate E test. The pupillary reactions and fundi were normal. An alternating esotropia of 5° was present. Examination of ocular motility revealed normal vertical elevation and depression. Convergence was present but limited. The patient was unable to abduct either eye beyond the mid-line, and when asked to follow a light to one side she sometimes made a great effort and by exercising convergence was able to follow the light a short way with the adducting eye (Fig. 1a-f, opposite). Bell's phenomenon was normal.

There was no facial expression at all and although the patient laughed, the sounds of laughter were not accompanied by any change in facial expression. There was some paralysis and atrophy of the left side of the tongue. She was considered to be slightly retarded mentally but she was most co-operative for so young a child.

No haemangiomata were seen. The feet tended to adopt a position of excessive pronation in repose but there was no limitation of dorsiflexion of the foot. The parents said that she was unable to run and that she stumbled readily.

Feeding was still a problem. Food tended to stick in the space between teeth and cheeks and chewing was difficult. The parents said that having a meal was an effort for her. There was some micrognathos.

X-ray Examination.—The skull showed no abnormality.

Electro-encephalogram.—Intrusion of abnormal forms into an otherwise normal record were seen. These patterns were readily suppressed by arousal stimuli and probably arose in subcortical systems.

Blood Group: Mother O;CcDee;
Patient, A;CcDee.

No antibodies other than normal anti-A and B were demonstrable in the mother's serum.

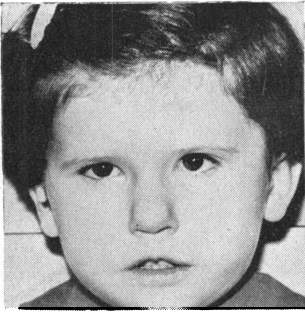


FIG. 1(a).—Case 1, looking straight ahead.

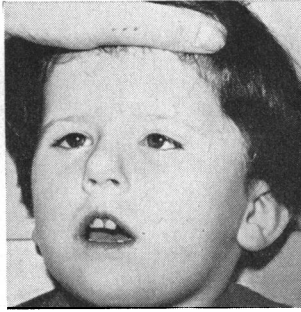

FIG. 1(b).—Case 1, attempted dextroversion, resulting in slight convergence.

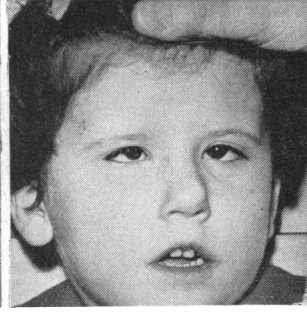


FIG. 1(c).—Case 1, attempted laevoversion, resulting in slight convergence. Some pupillary constriction can be seen.

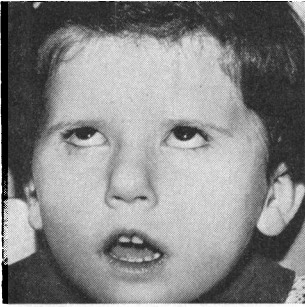


FIG. 1(d).—Case 1, supraversion.

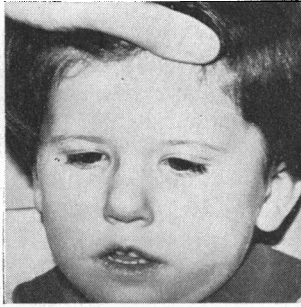

FIG. 1(e).—Case 1, infraversion.

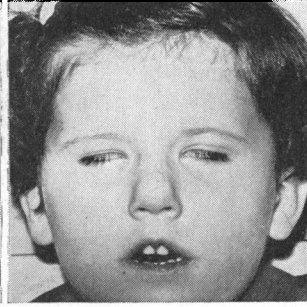


FIG. 1(f).—Case 1, eyes closed. The closure is incomplete and Bell's phenomenon can be seen to be normal.

Case 2, a boy aged 9, was first seen at the age of 5½ years at the Children's Hospital. The mother also had a normal son, 4 years older than the patient, and she herself was 34 years old when the patient was born. There was no consanguinity nor any family history of facial weakness or abnormal eye conditions. The mother stated that she vomited all through this pregnancy but was well all through the first. The birth was normal. No jaundice or convulsions occurred after birth, but there were considerable feeding difficulties.

Examination.—All facial movements were absent. The tongue was small and shrivelled indicating a bilateral hypoglossal palsy. There was some palatal paralysis and moderate micrognathos. A right talipes equinovarus was present and the patient was severely mentally retarded. He was unable to run and walked with a slow gait in which limb movements seemed restricted in range.

The visual acuity could not be recorded because of the poor mentality. The pupillary reactions to light and the ocular fundi were normal. His eyes were almost fixed in a convergent position at about 25° (Fig. 2, overleaf). Neither eye was able to abduct beyond the mid-line and adduction was limited to a few degrees. The eyes appeared to show no power of convergence. Objects in the right field were watched with the left eye, and the right eye was used for the left field. Moving objects were followed by moving the head. Elevation and depression were normal and Bell's phenomenon was present. The parents stated that he blinked infrequently and that tearing was a constant problem.

X-ray Examination.—The skull was normal.

Electro-encephalogram.—Normal.

Blood Group: Mother, A;CcDee;
Patient, A;CcDee.

No antibodies other than normal anti-B were demonstrable in the mother's serum.

The question of surgical correction of the strabismus was discussed. At first it was considered unnecessary because the child was so mentally retarded, but the parents were anxious to have the boy's eyes straightened because his elder brother was constantly being involved in fights with other children who commented on the younger brother's cross-eyed appearance.

On February 18, 1957, under general anaesthesia the forced duction test in both eyes showed that the movements of elevation, depression, and adduction were free, but that abduction was markedly limited by contracture of the medial rectus. When exposed the lateral rectus looked like a fibrous band. The medial rectus was thickened and contracted and had no elasticity. The insertions appeared to be normal in situation, and no anomalous check ligaments were seen.

A 4-mm. recession of the left medial rectus and a 4-mm. resection of the left lateral rectus were performed. The piece of lateral rectus was sent for microscopy.

Dr. J. Hoogstraten, pathologist to the Children's Hospital, reported that microscopical examination showed "fascicles of dense fibrous tissue resembling tendon or fascia. No muscle fibres were seen. There was no inflammatory infiltrate."

On April 23, 1957, the right eye was operated upon. When the right medial rectus was exposed, it was found to be tightly contracted. No abnormal fascial bands were seen. A 5-mm. recession was performed.

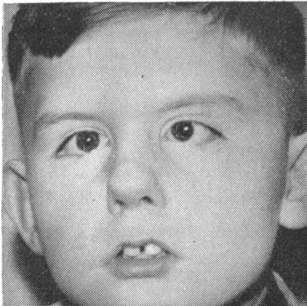


FIG. 2.—Case 2, the patient was too mentally defective to be able to co-operate in any way.

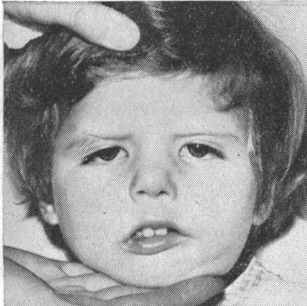

FIG. 3(a).—Case 3, looking straight ahead.

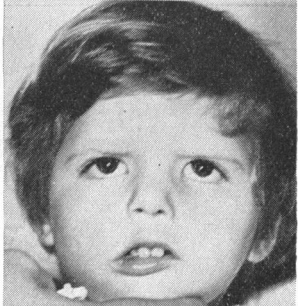

FIG. 3(b).—Case 3, supraversion. The patient would not co-operate for other photographs.

Case 3, a girl aged 2½ years, was first seen at the age of 4 months. She was the mother's second child but by a different father from the first child. The older child was normal. There was no consanguinity. Attacks of vaginal bleeding lasting about 2 days had occurred every 10 to 14 days during the first 4 months of pregnancy. No other illnesses occurred during the pregnancy.

The birth was normal. Feeding difficulties were experienced from the beginning, but there was no jaundice and no convulsions.

Examination.—The child had bilateral facial palsy, but when she cried or laughed a faint naso-labial fold appeared on the right side. The tongue was small, relatively immobile, and shrivelled on the left side.

No strabismus was present. She was unable to perform ocular conjugate movements to either side or to abduct either eye beyond the mid-line, but vertical elevation and

depression and some power of convergence were present. The pupillary reactions and Bell's phenomenon were normal (Fig. 3a, b).

She was moderately mentally retarded. She had difficulty in chewing and had a "cross-bite" to the right suggesting some weakness of the motor division of the trigeminal nerve. Micrognathos was marked and she had bilateral talipes equinovarus. Four haemangiomas were present in the following situations: the right side of the neck, the left side of the trunk, the right buttock, and the left big toe.

X-ray Examination.—The skull was normal.

Electro-encephalogram.—Normal.

Blood Group: Mother, A;CcDEe;
Patient, O;CcDe.

No antibodies other than normal anti-B were demonstrable in the mother's serum.

Discussion

The site of the primary lesion and the aetiology of Möbius's syndrome are still not known, although the condition has been recognized for 75 years. Kunn (1895) advanced the view that these lesions were due to failure of the nuclei to develop, *i.e.* nuclear aplasia.

It is obvious that Möbius's syndrome is an intra-uterine developmental defect, but it is not known whether hypoplasia of the muscles of the face and other affected sites is the primary defect so that the poor development of the nerves and cranial nuclei are secondary, or whether the cranial nuclear maldevelopment is the primary lesion and the muscular hypoplasia is secondary (Leszynsky, 1897).

Pathological Findings.—Four pathological studies have been reported (Huebner, 1900; Rainy and Fowler, 1903; Spatz and Ullrich, 1931; Balint, 1936). All four cases showed hypoplasia of the affected cranial nerve nuclei and nerve trunks.

Huebner (1900) reported a finding in his case which may be of significance: that the posterior longitudinal bundle was absent or at least very hypoplastic.

Henderson (1939) considered that the first three cases suggested primary nuclear hypoplasia, whilst Balint's case might have been due to intrapartum haemorrhage. But these studies do not necessarily indicate that cranial nuclear hypoplasia is the primary lesion because failure of development of the muscles would give rise to a secondary degeneration of the cranial nuclei and nerves supplying them.

Relation to Duane's Retraction Syndrome.—Ford (1952) considers that Möbius's syndrome is related to Duane's syndrome and that it is a primary muscle defect. Bedrossian and Lachman (1956) operated upon a patient with this condition and found that the medial and lateral recti were inserted more posteriorly than is normal and that Tenon's capsule was abnormally thickened. They therefore concluded that in their case the primary lesion was a peripheral muscular defect. But the finding of peripheral abnormalities

does not necessarily indicate that the peripheral lesion is the primary defect, for it may be secondary to a primary central defect.

Duane's syndrome is typically unilateral and usually affects the left eye. The patient can rotate both eyes in conjugate gaze to the side opposite to the affected eye, and even in the rare cases of bilateral Duane's syndrome the patient can rotate or adduct each eye towards the opposite side. At operation it has been shown that the condition is due to abnormal tissue bands tethering the eyeball or to fibrosis of the lateral rectus muscle.

Gundersen (1957) has operated on a number of these cases. At operation he found that the lateral rectus appeared to be normal whilst the medial rectus was adherent to the medial wall of the orbit. Histologically, both recti were normal.

Scobee (1952) classified Duane's syndrome into two types:

- (1) The lateral rectus is replaced with fibrous tissue.
- (2) The medial rectus has abnormal fascial bands which tether the eyeball and prevent abduction.

There is general agreement that Duane's syndrome is due to a primary local anomaly of muscle and fascia. No other muscles supplied by cranial nerves are affected nor are other general developmental anomalies or mental deficiency associated with this condition, as they are with Möbius's syndrome.

In the typical case of Möbius's syndrome, there appears to be a horizontal gaze palsy. Looking to either side is achieved by movements of the head although convergence and elevation and depression are present. Bell's phenomenon is always normal.

It is true that several cases of Möbius's syndrome have been reported in which there has been marked strabismus resembling a strabismus fixus. In our Case 2, there was a marked contracture of each medial rectus muscle, but there were no anomalous fascial bands. Abnormal tethering is the rule in Duane's syndrome, but it does not appear to be so in Möbius's syndrome. Bilateral hypoplasia of numerous muscles supplied by cranial nerves is characteristic of Möbius's syndrome, whilst in Duane's syndrome only one muscle is usually affected.

Breinin (1957a, b) carried out electromyography in two cases of Duane's syndrome, and found almost complete absence of electrical response in the affected lateral rectus in each case. He also carried out electromyography in one case of Möbius's syndrome and was unable to obtain any electrical response from the affected muscles. We consider that these facts support the orthodox view that cranial nuclear agenesis is the essential lesion in Möbius's syndrome.

Relation to Ocular Motor Apraxia.—This interesting condition has only recently been recognized. It has a slight resemblance to Möbius's syndrome in that there is a palsy of voluntary horizontal gaze. Conjugate horizontal movements, however, can be made involuntarily.

Alfano (1955) thought that in this condition the lesion was situated in the middle frontal gyrus. But he argued this on theoretical grounds and, in fact, his case had an occipital encephalocoele which was removed. Reed and Israels (1956) did not accept his localization. They pointed out that the condition resembled the type of horizontal gaze palsy classified as the Oppenheim type by Kestenbaum (1947), who considered that there was no anatomical or pathological basis for deciding the localization of the lesion in this type of palsy.

However, the child reported by Reed and Israels had a normal intelligence quotient and the electro-encephalogram indicated "involvement of sub-cortical systems associated with the occipital areas". It seems, therefore, that the lesion in ocular motor apraxia is a supranuclear one, probably in the mid-brain in the medial longitudinal bundle (posterior longitudinal fasciculus).

It is perhaps significant that Huebner reported an almost complete absence of the medial longitudinal bundle in his case of Möbius's syndrome.

This structure is unlikely to degenerate to the point of being almost absent as a result of a primary muscle hypoplasia with secondary degeneration of the nerve trunks. This finding of Huebner gives further support to the theory that nuclear agenesis is the essential feature of Möbius's syndrome and to the clinical impression that the defective horizontal movements of these patients are more of the nature of gaze palsies than due to local musculo-fascial anomalies.

In addition to the ocular anomaly the case of ocular motor apraxia reported by Reed and Israels exhibited generalized defects of coordination. We consider that ocular motor apraxia is more closely related to Möbius's syndrome than is Duane's syndrome.

Site of Primary Lesion in Möbius's Syndrome.—The fact that the term nuclear agenesis has been so generally applied to Möbius's syndrome is an indication of the general belief that the muscular manifestations are due to a failure of development of the cranial nuclei.

Duke-Elder (1949) considers that this condition is due to developmental defects of the cranial nuclei and the posterior longitudinal bundle, and we feel there is no reason to question this widely-held opinion.

The cranial nuclei affected in Möbius's syndrome are those of the abducens, facial, motor division of the trigeminal, and the hypoglossal nerves. These nuclei all lie in close proximity in the floor of the fourth ventricle. It is difficult to accept so close an association as being merely fortuitous. It is easy to conceive a noxious influence acting upon the motor nuclei in such a relatively restricted area. But the association with anomalies such as talipes, haemangiomas, and absent breast is more difficult to understand.

Action of Noxious Influences upon the Embryo.—During the last three decades it has been shown repeatedly that the tissues which grow most rapidly in the embryo are those which are most likely to be affected by noxious influences. Stockard (1921) suggested that it was the time of action rather than the type of noxa which decided the nature of the resulting lesions. For three decades this has been the accepted teaching. But recently Duraiswami (1955) injected different substances, such as insulin, cortone acetate, 3-acetylpyridine, and lead nitrate, into developing hens' eggs. He found that although the technique, time of injection, and method of incubation were the same, different malformations were produced. These experiments suggest that, although they may act at the same stage of development, different teratogenic agents may produce different specific anomalies.

It appears that the cranial nuclei which are affected in Möbius's syndrome undergo their most rapid development about the fourth and fifth weeks of intra-uterine life, *i.e.* at the 10-mm. stage (Keibel and Mall, 1912). It seems likely therefore that Möbius's syndrome may be caused by the action of a noxious agent at this period when the mother is barely aware that she is pregnant and hence less likely to remember a minor illness when questioned after the birth of the child.

It is perhaps significant that so few of the reports of Möbius's syndrome in the literature include any mention of a pregnancy history.

Noxa causing Multiple Defects in the Embryo.—It has been shown that irradiation and injection of pitressin or adrenaline to pregnant female mice may cause the development of subcutaneous blebs in the embryos. These blebs result from cerebro-spinal fluid escaping from the fourth ventricle and travelling along planes of least resistance to the subcutaneous tissues of the back and limbs and so causing multiple scattered lesions throughout the body (Bagg and Little, 1924; Bagg, 1929; Ullrich, 1949; Jost, 1953).

The multiple congenital defects which may result from maternal rubella have become well known since they were first recognized by Gregg (1944). It has been shown that measles and possibly influenza in the mother at the appropriate time of pregnancy may produce a rubella-like association of lesions. Reed, Briggs, and Martin (1955) reported a similar case following attempted abortion by taking an excessive quantity of quinine at about the end of the third month of pregnancy.

Ingalls (1956) mentioned three cases in which a mongoloid child followed trauma towards the end of the second month of pregnancy. In one case the mother suffered carbon monoxide poisoning, another was involved in a head-on car accident, and the third had a tooth extraction under gas-oxygen anaesthesia. He pointed out that in mongolism, the nasal bones, the phalanges of the little finger, and the cardiac septum are characteristically stunted, all widely diverse tissues.

Möbius's syndrome may be associated with club feet, haemangiomas,

micrognathos, absent breast, and mental retardation. Other cranial nerves besides the abducens and facial nerves may also be involved. The fact that this condition has so many diverse manifestations is therefore no argument against its being caused by noxa acting upon the embryo.

Other Aetiological Factors.—Heredity appears to play no part in this condition despite a suggestive history in a few cases (Danis, 1945).

Unger, Bork, and Marget (1956) have recently described three cases of congenital abducens palsy which followed neonatal jaundice due to Rh-incompatibility. In our cases, however, there was no history of neonatal jaundice and the blood tests showed that no Rh-incompatibility was present.

Pregnancy History.—It seems probable that if a syndrome of this type is to occur, the noxa must act upon the embryo at about the end of the first month or the beginning of the second month. In our three cases the pregnancy histories seem to be significant. The mother of the first child had a severe fall during the second month. Vomiting occurred throughout the pregnancy in the second case and the mother emphasized that it was unlike her first pregnancy in this respect. In the third case, vaginal bleeding occurred during the first 4 months. These facts may or may not be of significance, but it seems to us that the study of the pregnancy history offers the best hope of discovering the cause of this condition.

Summary

- (1) The essential features of Möbius's syndrome are reviewed.
- (2) Three cases of the condition are reported.
- (3) The essential nature of the lesions are discussed. It is concluded that cranial nuclear agenesis is the most acceptable concept.
- (4) The aetiology of the condition is discussed.
- (5) It is suggested that more careful pregnancy history-taking may shed light on this problem.

Dr. Bruce Chown of the Rh Laboratory of Winnipeg kindly supplied the information concerning the blood groups of patients and mothers. The electro-encephalographic reports were obtained through the courtesy of Dr. M. G. Saunders of the E.E.G. Department of the Winnipeg General Hospital.

We wish to thank Dr. Walter Zingg of the Surgical Department of the University of Manitoba for much help in translating original articles and Mr. John Teal for his kindness in taking the photographs of our patients.

REFERENCES

- ALFANO, J. E. (1955). *Amer. J. Ophthalm.*, **40**, 724.
 BAGG, H. J. (1929). *Amer. J. Anat.*, **43**, 167.
 ——— and LITTLE, C. C. (1924). *Ibid.*, **33**, 119.
 BÁLINT, A. (1936). *Jb. Kinderheilk.*, **147**, 256.
 BEDROSSIAN, E. H., and LACHMAN, B. E. (1956). *Amer. J. Ophthalm.*, **41**, 304.
 BONNEVIE, K. (1934). *J. exp. Zool.*, **67**, 443.

- BREININ, G. M. (1957a). *A.M.A. Arch. Ophthal.*, **57**, 165.
 ——— (1957b). Personal Communication.
- CHISOLM, J. M. (1882). *Arch. Ophthal. (N. Y.)*, **11**, 323.
- DANIS, P. (1945). *Ophthalmologica (Basel)*, **110**, 113.
- DUKE-ELDER, S. (1949). "Text-book of Ophthalmology", vol. 4, p. 4092. Kimpton, London.
- DURAIWAMI, P. K. (1955). *J. Bone Jt Surg.*, **37A**, 277.
- FORD, F. R. (1952). "Year Book of Pediatrics", p. 347. Year Book Publishers, Chicago.
- GRAEFE, A. VON (1880). In "Handbuch der gesammten Augenheilkunde", vol. 6, p. 60. Engelmann, Leipzig.
- GREGG, N. MCALISTER (1944). *Trans. ophthal. Soc. Aust.*, **4**, 119.
- GUNDERSEN, T. (1956). Personal Communication and "Duane's Syndrome", a paper read before the New York Academy of Medicine. Jan. 16, 1956.
- HARLAN, G. C. (1881). *Trans. Amer. ophthal. Soc.*, **3**, 216.
- HENDERSON, J. L. (1939). *Brain*, **62**, 381.
- HEUBNER, O. (1900). *Charité Ann.*, **25**, 211.
- INGALLS, T. H. (1956). *J. Amer. med. Ass.*, **161**, 1047.
- JOST, A. (1953). *Arch. Paediat.*, **10**, 865.
- KEIBEL, F., and MALL, F. P. (1912). "Manual of Human Embryology", vol. 2, p. 44-46. Lippincott, Philadelphia.
- KESTENBAUM, A. (1947). "Clinical Methods of Neuro-ophthalmologic Examination", p. 208. Heinemann, London.
- KUNN, C. (1895). *Beitr. Augenheilk.*, **2**, 711. [Heft 19, p. 1.]
- LESZYNSKY, W. M. (1897). *N. Y. med. J.*, **65**, 291.
- MÖBIUS, P. J. (1892). *Münch. med. Wschr.*, **39**, 17.
- RAINY, H., and FOWLER, J. S. (1903). *Rev. Neurol. Psychiat.*, **1**, 149.
- REED, H., BRIGGS, J. N., and MARTIN, J. K. (1955). *J. Pediat.*, **46**, 182.
- and ISRAELS, S. (1956). *British Journal of Ophthalmology*, **40**, 444.
- SCOBEE, R. G. (1952). "The Oculorotary Muscles", 2nd ed., p. 266. Mosby, St. Louis.
- SPATZ, H., and ULLRICH, O. (1931). *Z. Kinderheilk.*, **51**, 579.
- STOCKARD, C. R. (1921). *Amer. J. Anat.*, **28**, 115.
- ULLRICH, O. (1949). *Amer. J. hum. Genet.*, **1**, 179.
- UNGER, H. H., BORK, U., and MARGET, W. (1956). *Klin. Mbl. Augenheilk.*, **128**, 657.