

Coffee worker's lung

A new example of extrinsic allergic alveolitis

D. W. VAN TOORN

Institute of Pathology, State University of Utrecht, The Netherlands

A man who worked for more than 20 years in a coffee-roasting factory developed lung lesions. By immunological investigations it was proven that there were circulating antibodies against coffee-bean dust in the patient's serum. Immunofluorescence of the lung biopsy demonstrated deposits of IgG and complement along the alveolar capillaries. The histological features are described.

The morphological changes that may occur in the group of diseases that were labelled 'idiopathic chronic interstitial fibrosis of the lung', better named 'chronic diffuse fibrosing alveolitis', are by now well known. In the majority of cases the aetiology remains obscure, but it has become increasingly clear that in many cases (particularly when granulomatous lesions are present) the changes that occur are the result of an antigen-antibody reaction provoked by inhalation of some form of organic dust or some component of a fungus, functioning as an antigen. Emanuel, Wenzel, Bowerman, and Lawton (1964) and Seal, Hapke, Thomas, Meek, and Hayes (1968) have pointed out that the features suggestive of extrinsic allergic alveolitis are less obvious as the disease becomes chronic, and the picture seen in the later stages cannot be distinguished from those of the so-called idiopathic forms of the disease. Therefore in every case of diffuse fibrosis of the lungs a detailed inquiry must be made into the exact occupation of the patient and also into any possible significant aetiological environmental factor. Although many of these factors are now known, probably there are a number of substances which may initiate diffuse pulmonary diseases.

The purpose of this paper is to describe a patient, sensitized by coffee bean dust, on whom immunopathological investigations as well as histological studies have been performed.

CASE REPORT

In August 1969 a 46-year-old man attended the Department of Lung Diseases of the St. Antonius Hospital in Utrecht, complaining that for three

months there had been dyspnoea, especially on exertion, and also fatigue and listlessness. Except for a morning cough for several years there was no history of lung disease. The patient had previously had yearly chest radiographs taken, and 1969 was the first time it had been abnormal: because of this he was sent to the Department of Lung Diseases. For about six weeks there had been some vague joint symptoms in the left and right shoulders and hands. On admission he had psoriasis, there was some orthopnoea, but the patient had no fever. The percussion note was impaired over both lower lobes, and the breath sounds were vesicular with crepitations in both bases.

The PA chest film showed macronodular mottling in both lungs; in the basal parts of the lungs areas of consolidation were observed (Fig. 1). The radiographs of the oesophagus were normal apart from a hiatus hernia; sarcoidosis was not supported by the negative findings in the lymph nodes obtained by mediastinoscopy. An ECG showed disturbances of the repolarization. Repeated lung function tests showed a decrease in vital capacity, a subnormal oxygen saturation at rest (92.5, 91, and 94%) which increased on exertion (79, 73, and 82%). The PCO_2 showed a rise on exertion. ESR was 14 mm. in the first hour, and haemoglobin was 14 g./100 ml. A white blood cell count on several occasions was between 8,400 and 11,600/cu. mm., with 4 to 7% eosinophils, 53 to 59% neutrophils, and 33 to 37% lymphocytes.

An intracutaneous test to several allergens, including pollen, housedust, feathers, fungi, hairs, bacteria, drinks, egg, meat, and fruits, was negative. The patient's serum was tested in the Laboratory of Public Health at Nijmegen; there were no precipitations to *Aspergillus fumigatus*, *Thermopolyspora polyspora* or to pigeon serum. An antinuclear factor (ANF) was negative. The Rose-test for rheumatoid factors was positive 1 : 512. The liver and renal function tests were normal. Total serum proteins were

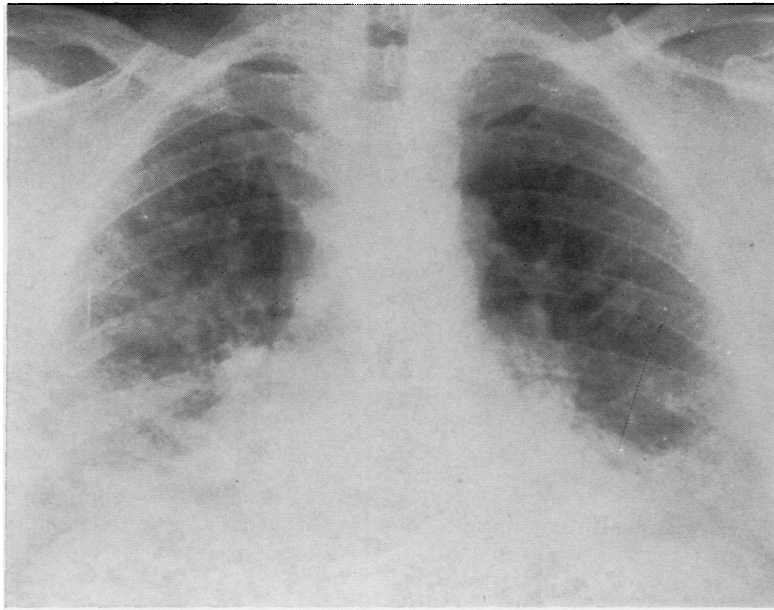


FIG. 1. *Chest radiograph taken during first admission to hospital shows diffuse shadowing at both bases.*

6.9 g./100 ml., with 59.4% albumin, 7.3% α_1 globulin, 10.1% α_2 globulin, 8.7% β globulin, and 14.5% γ globulin.

For diagnostic reasons a direct lung biopsy was performed. Microscopically the alveolar walls were broadened by oedema and infiltration of lymphocytes, larger mononuclear cells, plasma cells, fibroblasts, and some eosinophilic leucocytes (Fig. 2). Locally the alveolar epithelium seemed to be lined by granular pneumocytes (Fig. 3). In the adventitia surrounding the walls of many arterioles and venules there was infiltration by chronic inflammatory cells (Fig. 4). There were no true granulomatous lesions, but there were some giant cells. After staining for elastic tissue we saw degenerative changes in the elastic layers of some arterioles and fragmentation of the elastic skeleton of the lung. There was no proliferation of collagen fibres or smooth muscle fibres. Immunofluorescence of the biopsy specimen showed depositions of IgG and complement along the alveolar capillaries and the alveolar basal membrane; there was some perivascular deposition of all serum proteins (Figs 5 and 6).

For the time being we made the diagnosis of diffuse fibrosing alveolitis. Since we knew that the patient had worked for more than 20 years in a coffee-roasting factory, we tried to demonstrate antibodies against coffee-bean dust in the serum. We made a coffee-bean dust extract of the dust collected in the factory where the patient worked, using the following procedure: 2 g. of the dust was shaken in

100 ml. of a Tris buffer (pH 8.3) at room temperature; after one hour the liquid was sucked through a Millipore-filter. An agar-gel diffusion test showed a precipitation reaction between the undiluted serum of the patient and the undiluted and 1:1 diluted extract. No precipitation reaction could be demonstrated between the extract and the sera of several arbitrarily chosen donors of the blood transfusion service. Immunoelectrophoresis of the serum showed that the extract reacted with the IgG fraction of the gamma-globulins.

The same extract was used for a skin test; 0.1 ml. of the undiluted and the 1:1 diluted extract were injected intracutaneously. Within 10 minutes after the injection there was a weal, 14 mm. in diameter, with an extensive surrounding erythema. The histological picture of the biopsy taken 15 minutes after the injection showed oedema of the cutis. Immunofluorescence showed a vascular deposition of the β_1C component of complement, a perivascular granular deposition of IgG, and a diffuse deposition of albumin and fibrinogen (Fig. 7).

For technical reasons only one biopsy specimen could be obtained. Meanwhile the patient was treated with corticosteroids. The abnormal changes on the chest radiographs have diminished and subjectively the patient is much better.

DISCUSSION

According to Pepys (1969), inhaled organic dusts can produce different allergic diseases of the lung,

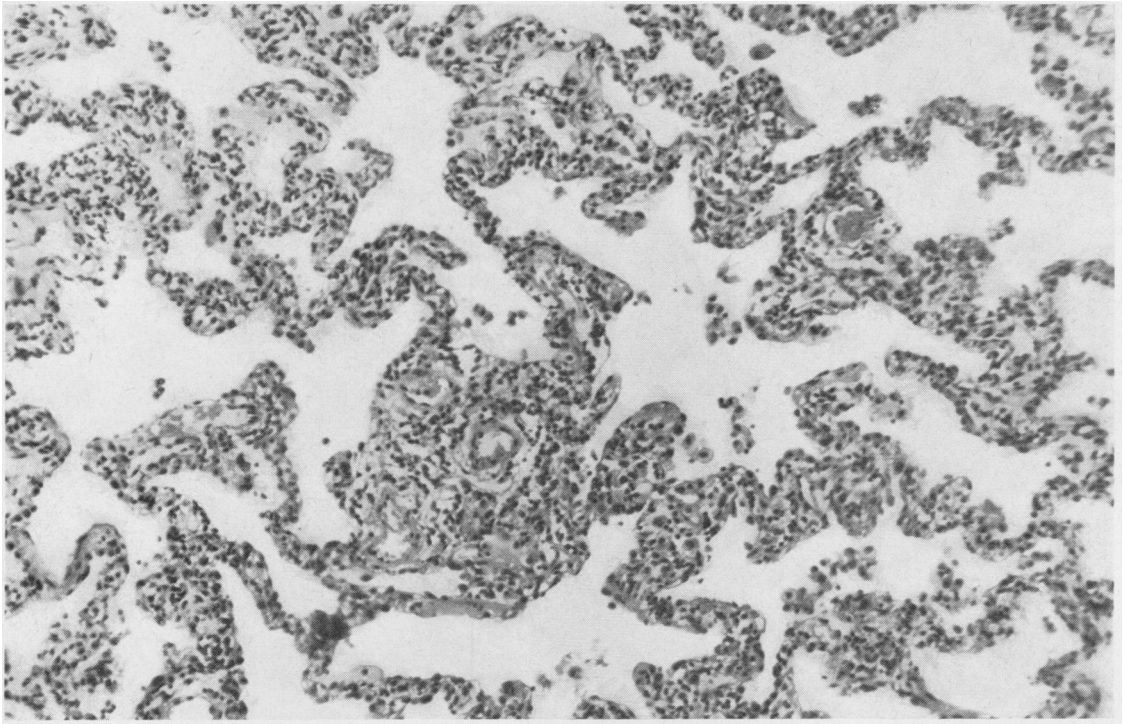


FIG. 2. *Thickening of the alveolar walls by oedema and cellular infiltration. H. and E. × 250.*

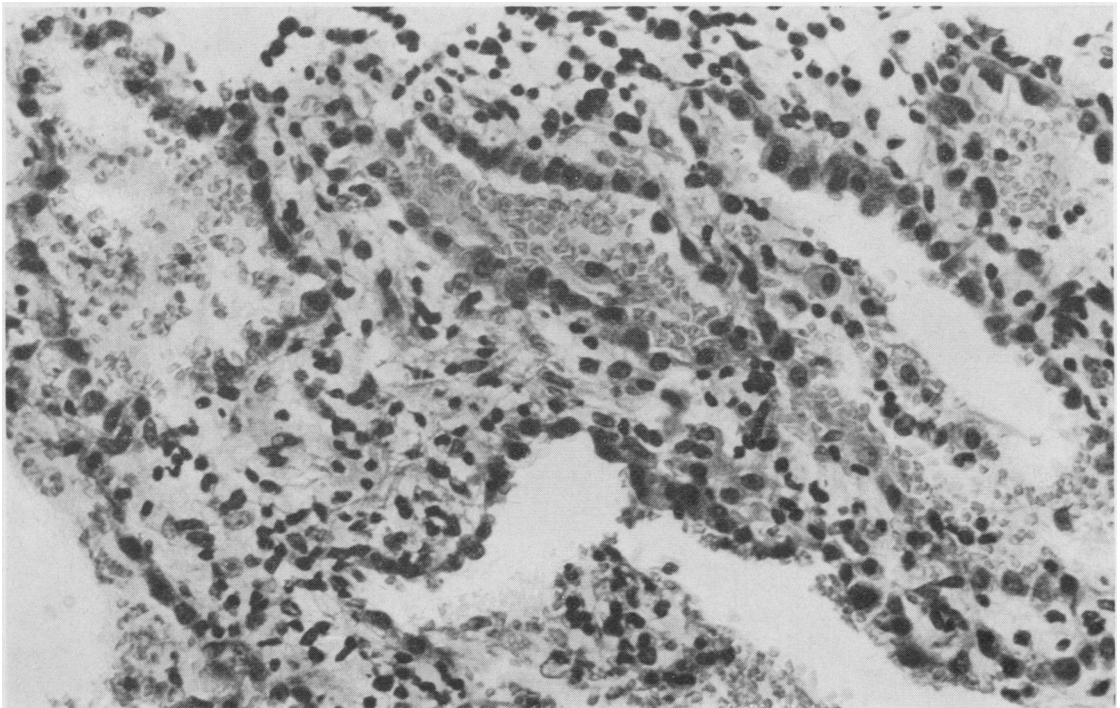


FIG. 3. *The alveolar epithelium seemed to be lined by granular pneumocytes. H. and E. × 400.*

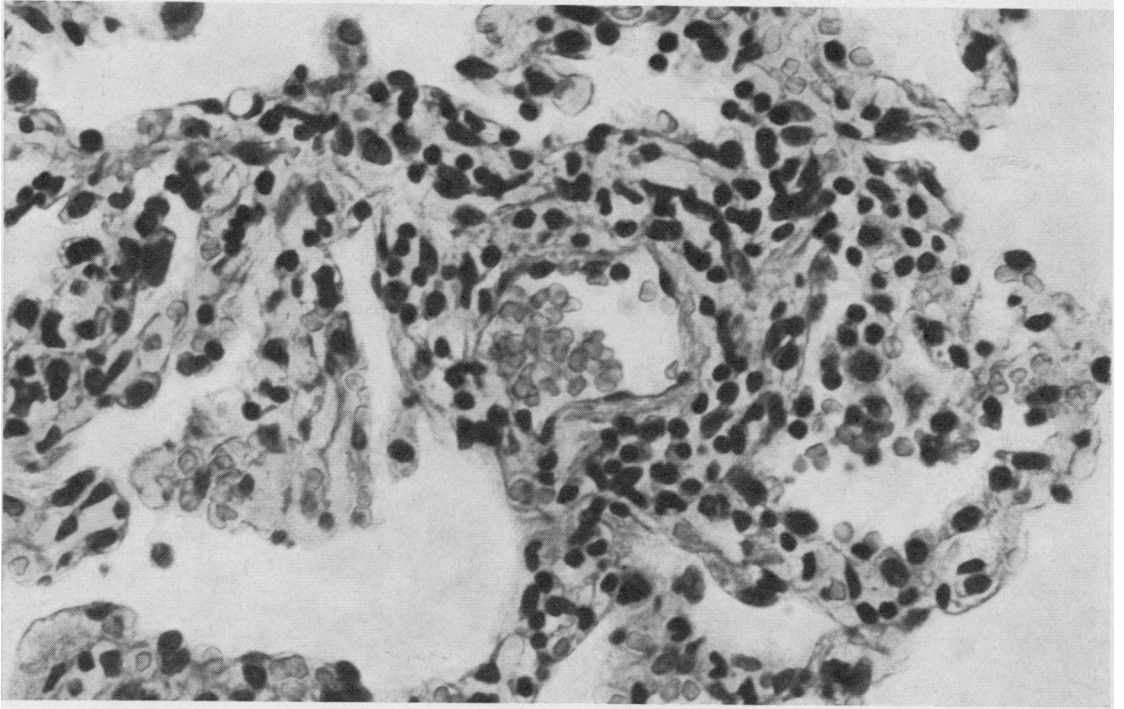


FIG. 4. *Infiltration by chronic inflammatory cells in the wall of a blood vessel. H. and E. \times 250.*

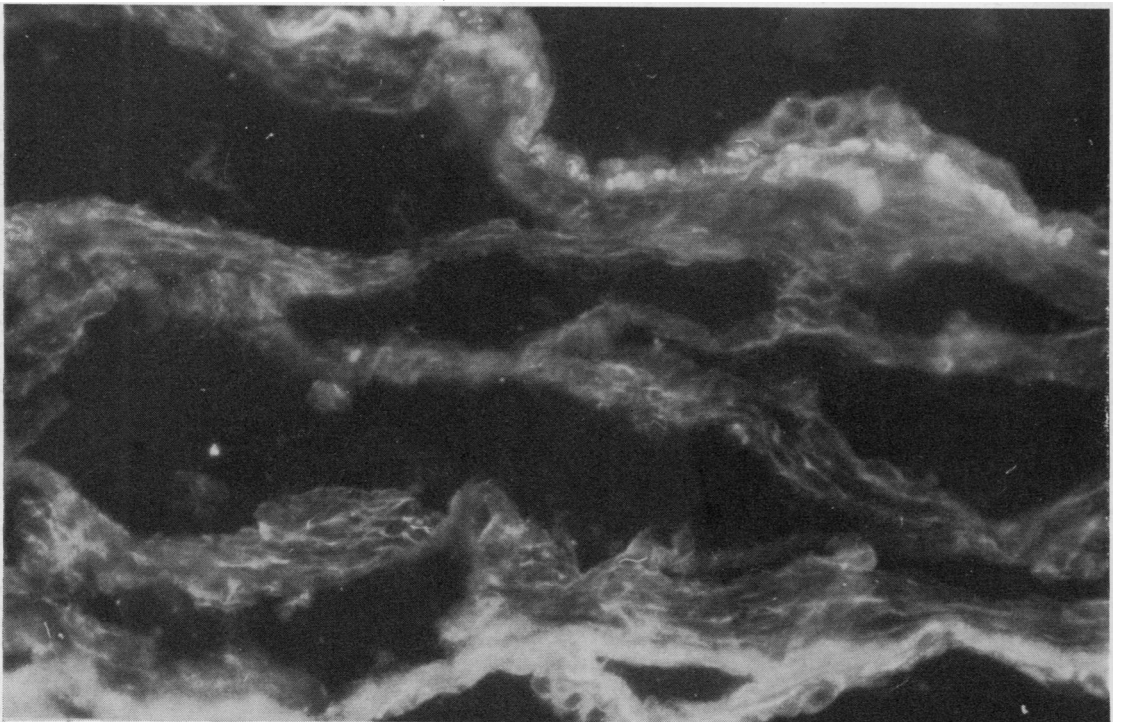


FIG. 5. *Immunofluorescence in the lung biopsy specimen. Depositions of IgG along alveolar capillaries. Rabbit-antihuman IgG - horse antirabbit/FITC (sandwich technique) \times 250.*

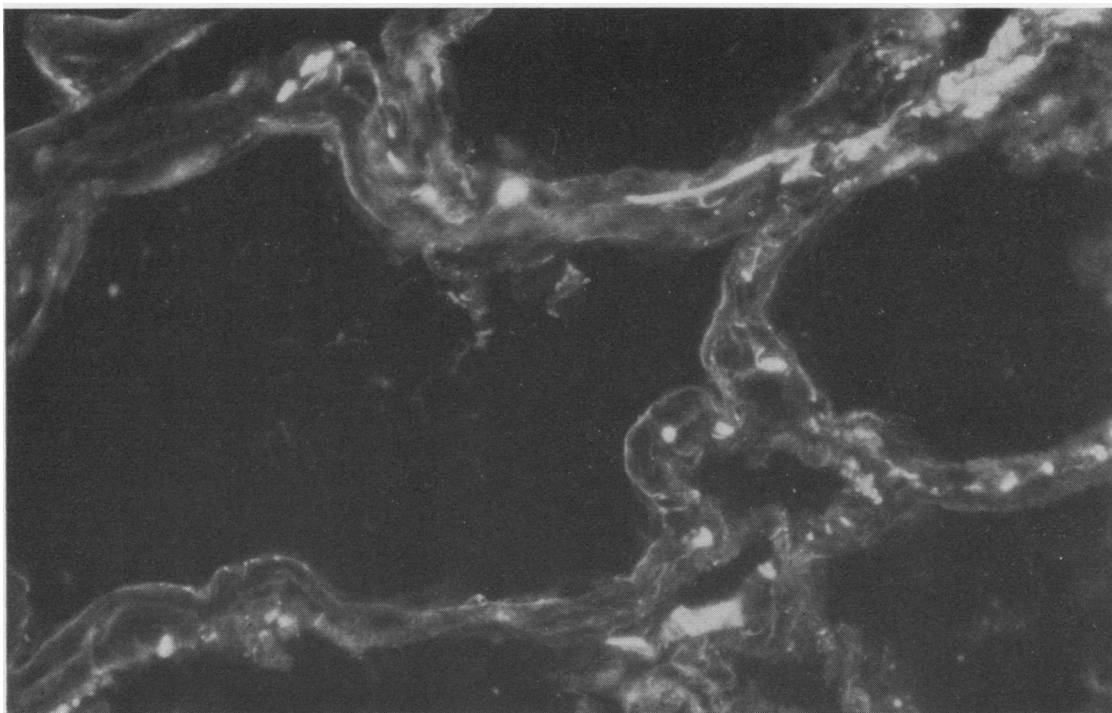


FIG. 6. *Immunofluorescence in the lung biopsy specimen. Depositions of complement along the alveolar capillaries. Rabbit-antihuman β_1C - horse antirabbit/FITC (sandwich technique) $\times 250$.*

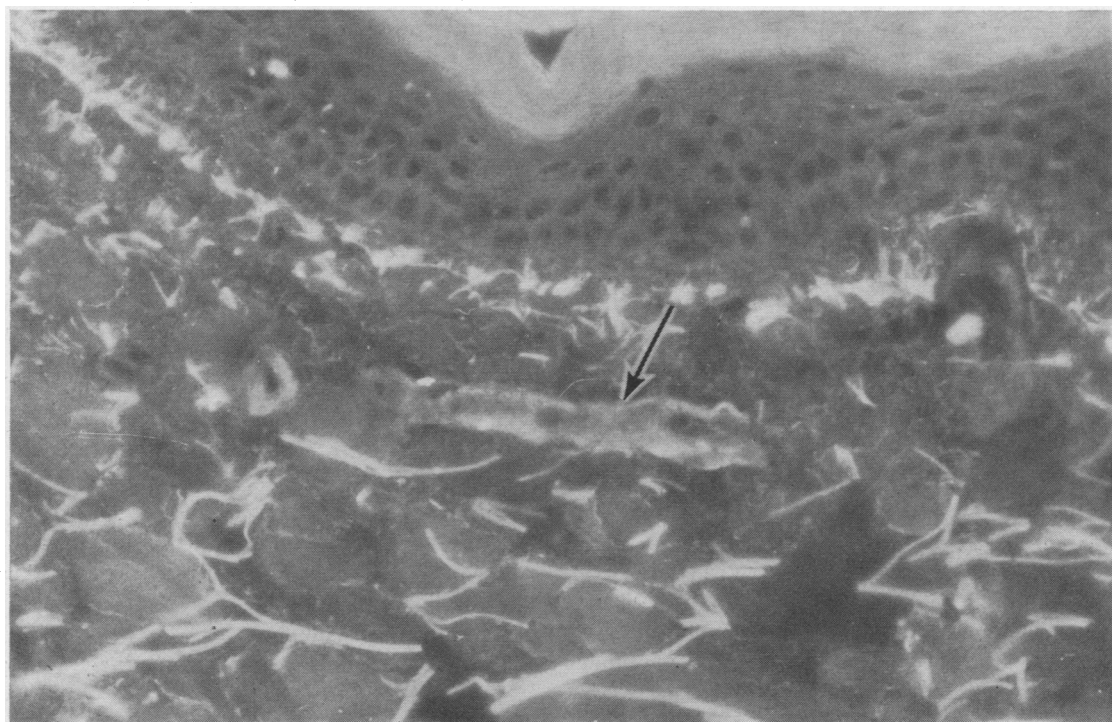


FIG. 7. *Immunofluorescence of the skin biopsy specimen taken after skin testing. Note sharp deposition of complement in the wall of an arteriole (arrow). Rabbit-antihuman β_1C - horse antirabbit/FITC (sandwich technique) $\times 250$.*

depending upon whether the subject is atopic or not. Inhalation of the dust in atopic patients leads to the well-known reaginic type hypersensitivity reaction. In non-atopic persons inhalation of organic dusts can evoke precipitating antibodies against the dust or a dust component. Once these antibodies have been established in the circulation, inhalation of the dust will cause a type III (Arthus-type) hypersensitivity reaction in the lungs, and the result of repeated reactions of this type can be severe damage to the lungs. This picture is now called extrinsic allergic alveolitis, a term coined in 1967 by Grant (Riddle and Grant, 1967; Riddle, Channell, Blyth, Weir, Lloyd, Amos, and Grant, 1968).

At the moment several examples of extrinsic allergic alveolitis are known, farmer's lung (Pepys, Riddell, Citron, and Clayton, 1962) being the most important one. Others are pigeon breeder's lung (Reed, Sosman, and Barbee, 1965) or bird fancier's lung, bagassosis (Salvaggio, Seabury, Buechner, and Jundur, 1967), pituitary snuff disease (Mahon, Scott, Ansell, Manson, and Fraser, 1967), wheat weevil disease (Lunn and Hughes, 1967), malt worker's lung (Riddle *et al.*, 1968), maple-bark stripper's disease (Emanuel, Wenzel, and Lawton, 1966), and New Guinea lung disease (Blackburn and Green, 1966). Probably the smallpox handler's lung (Morris Evans and Foreman, 1963), the paprika splitter's lung (Hunter, 1969), the vineyard sprayer's lung (Pimentel and Marques, 1969), and the furrier's lung (Pimentel, 1970) are other examples.

In all of these diseases, except in the smallpox handler's and paprika splitter's lung, precipitins have been demonstrated against a specific antigen. In sisal workers and in coffee workers specific precipitins have been demonstrated against extracts of sisal and coffee bean dust (Pepys, 1969). However, no histological description of allergic alveolitis has so far been published in subjects exposed to sisal dust or coffee bean dust.

Clinically exposure to the specific antigen in patients suffering from extrinsic alveolitis sometimes causes a biphasic reaction—an acute reaginic type I hypersensitivity reaction followed some hours later by a type III Arthus-hypersensitivity reaction. The first reaction is probably caused by antibodies of the IgE class of gamma-globulins, the second almost certainly by antibodies of the IgG class characterized clinically by dyspnoea, crepitations, and unproductive cough. In pulmonary function tests there is an impairment of diffusion, but usually no evidence of an obstructive disease

of the airways. In the chest radiograph there are diffuse micronodular opacities.

In this patient, histologically, we saw the picture of extrinsic allergic alveolitis (interstitial inflammation of the alveolar walls, vasculitis, and giant cells); clinically, there was an impairment of diffusion. In the serum of our patient there were precipitating antibodies against an extract of coffee-bean dust; there was a 20-year exposure to the dust before lung complaints became manifest.

In our material we have demonstrated that deposits of IgG, complement, and fibrinogen may occur along the alveolar capillaries in other examples of extrinsic allergic alveolitis (pigeon breeder's disease and farmer's lung) but not in other forms of fibrosing alveolitis. The immunofluorescence pattern is identical in the early stages of all cases of extrinsic allergic alveolitis that we have examined so far.

It is not very likely that the positive test for rheumatoid factors has anything to do with the origin of the lung changes in this case. The interstitial fibrosis or diffuse fibrosing alveolitis (Scadding and Hinson, 1967) which is seen in some patients complaining of rheumatoid arthritis is different in the early stages of the disease from the picture seen in our case, or in the early stages of other forms of extrinsic allergic alveolitis. Only in the later phases of both types of diseases, when there is an abundant fibrosis, are the histological pictures often indistinguishable from each other. The immunofluorescence of the lung biopsy also showed no sign of rheumatic lung disease.

The weal arising after testing the skin with a coffee-bean dust extract developed so fast that it did not seem likely that we were dealing with an Arthus-type reaction. Probably this skin reaction was caused by antibodies of the IgE class of gamma-globulins. Histologically, there was no sign of inflammation in the skin biopsy taken 15 minutes after the intracutaneous injection of the extract; using the immunofluorescence technique we saw a sharp vascular deposition of complement as a sign of an antigen-antibody reaction in the vascular walls.

By analogy to farmer's lung and pigeon breeder's lung it seems justified to call this type of extrinsic allergic alveolitis 'coffee worker's lung'.

The author wishes to thank Professor J. Swieringa, of the Department of Lung Diseases, St. Antonius Hospital, Utrecht, for allowing him to study the clinical data of this patient.

REFERENCES

- Blackburn, C. R. B., and Green, W. (1966). Precipitins against extracts of thatched roofs in the sera of New Guinea natives with chronic lung disease. *Lancet*, 2, 1396.
- Emanuel, D. A., Wenzel, F. J., Bowerman, C. I., and Lawton, B. R. (1964). Farmer's lung. Clinical, pathologic and immunologic study of twenty-four patients. *Amer. J. Med.*, 37, 392.
- and Lawton, B. R. (1966). Pneumonitis due to cryptostroma corticale (maple-bark disease). *New Engl. J. Med.*, 274, 1413.
- Hunter, D. (1969). *The Diseases of Occupations*. 4th ed. The English Universities Press, London.
- Lunn, J. A., and Hughes, D. T. D. (1967). Pulmonary hypersensitivity to the grain weevil. *Brit. J. industr. Med.*, 24, 158.
- Mahon, W. E., Scott, D. J., Ansell, G., Manson, G. L., and Fraser, R. (1967). Hypersensitivity to pituitary snuff with miliary shadowing in the lungs. *Thorax*, 22, 13.
- Morris Evans, W. H., and Foreman, H. M. (1963). Smallpox handler's lung. *Proc. roy. Soc. Med.*, 56, 274.
- Pepys, J. (1969). Hypersensitivity diseases of the lungs due to fungi and organic dusts. *Monographs in Allergy*. Vol. 4. Karger, Basel.
- Riddell, R. W., Citron, K. M., and Clayton, Y. M. (1962). Precipitins against extracts of hay and moulds in the serum of patients with farmer's lung, aspergillosis, asthma, and sarcoidosis. *Thorax*, 17, 366.
- Pimentel, J. C. (1970). Furrier's lung. *Thorax*, 25, 387.
- and Marques, F. (1969). 'Vineyard sprayer's lung'. *Thorax*, 24, 678.
- Reed, C. E., Sosman, A., and Barbee, R. A. (1965). Pigeon-breeder's lung. *J. Amer. med. Ass.*, 193, 261.
- Riddle, H. F. V., and Grant, I. W. B. (1967). Allergic alveolitis in a maltworker. *Thorax*, 22, 478.
- Channell, S., Blyth, W., Weir, D. M., Lloyd, M., Amos, W. M. G., and Grant, I. W. B. (1968). Allergic alveolitis in a maltworker. *Thorax*, 23, 271.
- Salvaggio, J. E., Seabury, J. H., Buechner, H. A., and Jundur, V. G. (1967). Bagassosis: demonstration of precipitins against extracts of thermophilic actinomycetes in the sera of affected individuals. *J. Allergy*, 39, 106.
- Scadding, J. G., and Hinson, K. F. W. (1967). Diffuse fibrosing alveolitis (diffuse interstitial fibrosis of the lungs). *Thorax*, 22, 291.
- Seal, R. M. E., Hapke, E. J., Thomas, G. O., Meek, J. C., and Hayes, M. (1968). The pathology of the acute and chronic stages of farmer's lung. *Thorax*, 23, 469.