

## Cardiac Arrest From Asystole During Endoscopic Retrograde Cholangiopancreatography: A Rare But Fatal Complication

Ajay Vallakati, MD,MPH<sup>1</sup>, Madhu Reddy, MD<sup>1</sup>, Mojtaba Olayee, MD<sup>2</sup>, Dhanunjaya Lakkireddy, MD<sup>1</sup>

<sup>1</sup> Division of Cardiovascular Diseases, Cardiovascular Research Institute, University of Kansas Hospital and Medical Center, Kansas City, Kansas. <sup>2</sup> Division of Gastroenterology, University of Kansas Hospital and Medical Center, Kansas City, Kansas.

### Abstract

We present a rare complication of cardiac arrest from asystole in the setting of prolonged endoscopic retrograde cholangiopancreatography (ERCP) procedure. Cardiopulmonary complications of ERCP are rare but can be fatal. Therefore it is essential to closely monitor the patient during ERCP. Immediate access to resuscitation equipment facilitating prompt intervention in the unlikely event of fatal cardiovascular collapse should be a part of standard ERCP protocol to ensure life threatening complications are appropriately managed.

### Introduction

A 70 year old female with non obstructive coronary artery disease, hypertension, hyperlipidemia underwent endoscopic sphincterotomy and biliary stent placement for papillary stenosis. Follow up studies revealed migration of the stent to right hepatic duct. The patient was then scheduled for repeat endoscopic retrograde cholangiopancreatography (ERCP) for stent removal. Her home medications included aspirin 81 mg daily, amlodipine 5 mg daily, simvastatin 20 mg daily and multivitamins. Laboratory studies revealed low levels of serum potassium (3.4 mmol/L (normal 3.5-5.1 mmol/L). Remaining tests were unremarkable. Baseline electrocardiogram revealed sinus rhythm with left bundle branch block (LBBB) pattern (Figure 1). She did not take any home medications on the day of procedure. She did not have any oral intake for 12 hours prior to the procedure. Induction of anesthesia and intubation were uneventful (150 mg of propofol, 100 mg of lidocaine and 100 mg of succinylcholine). Initially the patient was hemodynamically stable. Thirty minutes into the procedure as the

biliary stent was being extracted, the patient became bradycardic (heart rate dropped from 52 to 32 beats per minute) and hypotensive. The end tidal carbon dioxide levels dropped from 30 to 10 mm Hg and rhythm changed from severe bradycardia changed to asystole (Figure 2). Cardiopulmonary resuscitation was initiated using ACLS protocol. The patient went into pulseless electrical activity. After three 1 mg doses of epinephrine and 50 mEq of intravenous sodium bicarbonate, spontaneous perfusion was restored. Electrocardiogram (ECG) showed complete atrio-ventricular block with ventricular rate of 66 beats per minute and ST segment elevation in leads III and aVF with reciprocal changes in lateral leads (Figure 3). The patient was emergently transferred to cardiac catheterization laboratory. Temporary transvenous pacemaker was placed and cardiac catheterization showed moderate disease in right coronary artery and 1st diagonal branch of left anterior descending artery. Computed tomography angiogram did not reveal any evidence of pulmonary embolism. Two-dimensional echocardiogram showed left ventricular ejection fraction of 35% and septal hypokinesis. Serum electrolytes were unremarkable apart from low serum potassium (3.2 mmol/L). The patient was closely monitored in intensive care unit. Third-degree atrioventricular block resolved spontaneously and transvenous pacemaker was removed next day. The patient was successfully extubated on the fourth day after the procedure. Rest of the hospital stay was uneventful.

### Key Words:

Cardiac Asystole, Endoscopic Retrograde Cholangiopancreatography

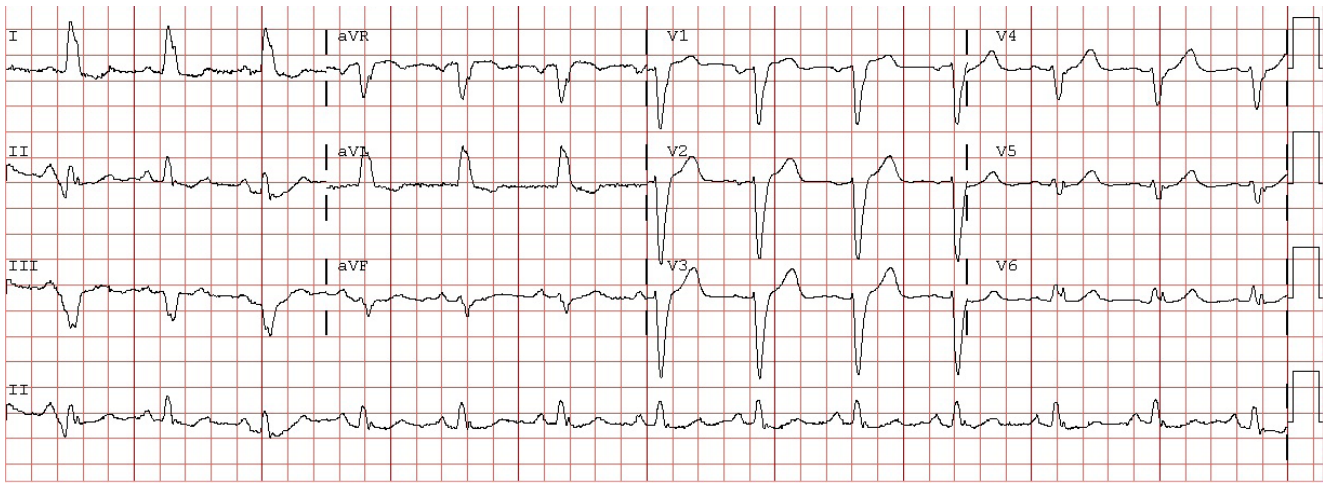
Disclosures:  
None.

### Corresponding Author:

Ajay Vallakati  
3901 Rainbow Boulevard,  
Kansas City,  
KS 66160-7200  
United States

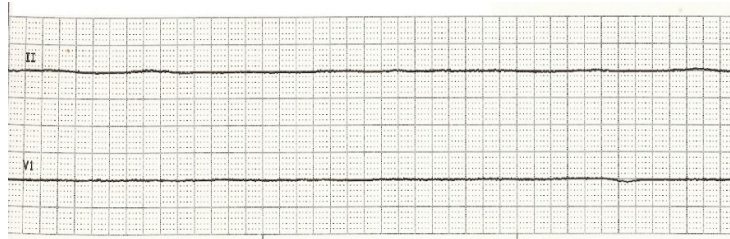
### Discussion

We describe a patient with non-ischemic cardiomyopathy who developed a vasovagal event which led to asystole during a prolonged procedure under anesthesia. Case reports describing sudden cardiac arrest during ERCP due to possible air embolism have been



**Figure 1:** Electrocardiogram showing sinus rhythm with left bundle branch block pattern

published in the past.<sup>1,2</sup> Goins et al<sup>3</sup> described a case of 72-year-old lady who developed pulseless electrical activity during ERCP. Emergent trans-esophageal echocardiogram revealed large amount of air in the right ventricle, which was immediately aspirated with a pulmonary artery catheter and spontaneous circulation was restored. However, in our patient neither computed tomography angiogram



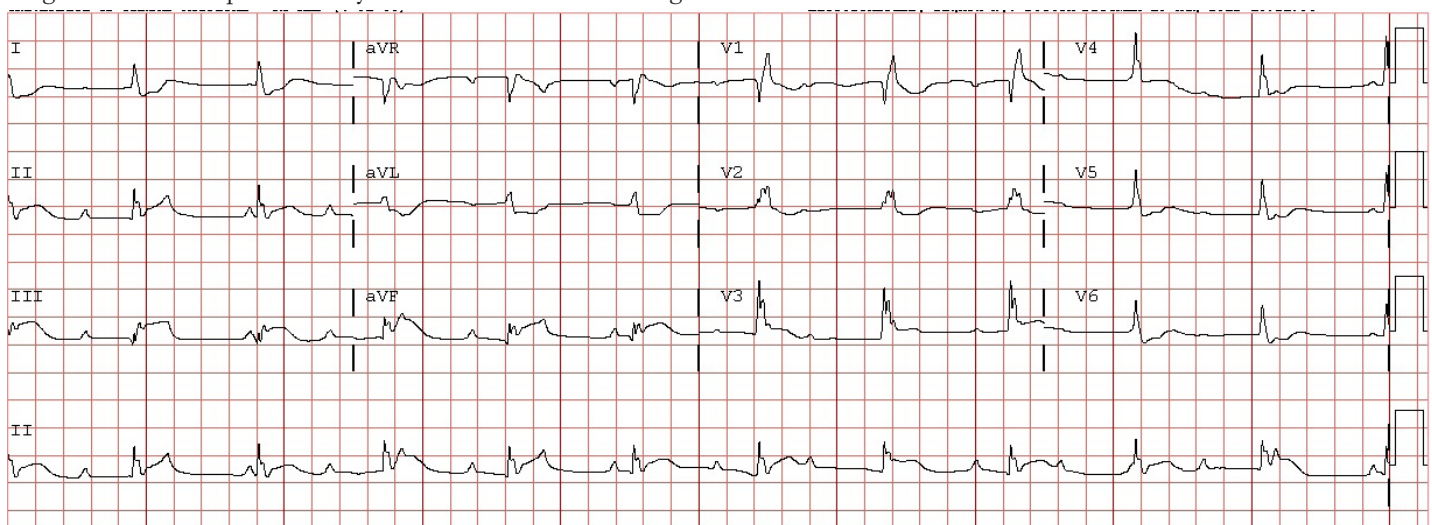
**Figure 2:** Electrocardiogram showing asystole

nor echocardiography showed any trapped air. Heart block with propofol administration in a 9-year-old child has also been reported.<sup>4</sup> Propofol may have contributed to bradycardia in our patient. Supra-physiologic activation of sensory nerve endings of vagal nerve by prolonged ERCP manipulation may have resulted in intense vagal

tone leading to bradycardia. Gonclaves described a patient who developed pulseless electrical activity leading to asystole during prolonged ERCP procedure (60 minutes).<sup>5</sup> Our patient had severe left ventricular dysfunction (EF 35% and LBBB, non-ischemic). The combination of impaired LV function, prolonged ERCP procedure and sedation probably resulted in bradycardia which led to cardiac asystole. EKG changes noted following resuscitation were most likely due to the non-significant RCA lesion which became significant in the setting of profound hypotension and use of epinephrine. In summary, we describe a rare complication of cardiac arrest from asystole in the setting of prolonged ERCP. In this case, cardiopulmonary resuscitation was immediately initiated and the patient survived without neurological deficits.

### Conclusions:

Cardiopulmonary complications of ERCP are rare but can be fatal. Therefore it is essential to closely monitor the patient during ERCP. Immediate access to resuscitation equipment facilitating prompt intervention in the unlikely event of fatal cardiovascular collapse should be a part of standard ERCP protocol to ensure life threatening complications are appropriately managed.



**Figure 3:** Electrocardiogram showing complete atrio-ventricular (AV) block with ventricular rate of 66 beats per minute and ST segment elevation in leads III and aVF with reciprocal changes in lateral leads

**References:**

1. Bisceglia M, Simeone A, Forlano R, Andriulli A, Pilotto A. Fatal systemic venous air embolism during endoscopic retrograde cholangiopancreatography. *Advances in anatomic pathology* 2009;16:255-62.
2. Kennedy C, Larvin M, Linsell J. Fatal hepatic air embolism following ERCP. *Gastrointestinal endoscopy* 1997;45:187-8.
3. Goins KM, May JM, Hucklenbruch C, Littlewood KE, Groves DS. Unexpected cardiovascular collapse from massive air embolism during endoscopic retrograde cholangiopancreatography. *Acta anaesthesiologica Scandinavica* 2010;54:385-8.
4. Sochala C, Deenen D, Ville A, Govaerts MJ. Heart block following propofol in a child. *Paediatric anaesthesia* 1999;9:349-51.
5. Goncalves D. Endoscopic procedure hazard--vagovagal syncope with heart standstill due to ERCP. *Arquivos de gastroenterologia* 1979;16:200-2.