

careful research. The results we have so far experienced have so strikingly confirmed McConkey's results that I think it only right that doctors in India should have an opportunity of trying out a treatment so simple that every practitioner can use it and can bring, in many cases, much relief to patients suffering from all the distressing symptoms of intestinal tuberculosis.

The treatment as described* by McConkey consists of placing in a small tumbler three ounces of strained tomato juice or the juice squeezed from an ordinary-sized orange. On the surface of the juice is floated half of an ounce of ordinary cod-liver oil. The whole is served immediately after meals three times daily.

When it was demonstrated that artificial heliotherapy is of value in the treatment of intestinal tuberculosis McConkey began to think that cod-liver oil might be of equal value, especially as ultraviolet radiation and cod-liver oil are equally effective in the treatment of rickets and practically interchangeable as anti-rachitic remedies. He began therefore to give cod-liver oil to patients suffering from intestinal tuberculosis, but was disappointed as he was not able to observe any improvement by its administration. While trying the effect of cod-liver oil, certain very sick patients were given orange juice with their oil in an effort to make the dose more palatable, and it was observed that these patients did better than those less seriously ill who were receiving cod-liver oil without the orange juice. Acting on this hint orange juice, and later the cheaper, but equally efficacious tomato juice, was added to the cod-liver oil in the routine treatment.

Very careful research work was then inaugurated and carried on for three years: 128 patients suffering from intestinal tuberculosis complicating disease of the lungs were observed: 28 patients, who had entered the hospital before the value of ultraviolet radiation was appreciated and who had received only ordinary palliative treatment, served as a control. Fifty patients were given ultraviolet radiation and 50 similar cases received cod-liver oil and tomato juice.

There was no outstanding difference in the severity of the intestinal symptoms or of the general condition of the patients in the three groups at the time they entered the hospital. The pulmonary lesion was either in the moderately advanced or in the advanced stage; cavities were present in 90 per cent. of the cases, and tubercle bacilli were found in the sputum of all but two. The diagnosis of intestinal tuberculosis was in all cases supported by positive radiographic findings.

It would carry us too far here to record all the different findings of this research. It is

sufficient to mention the condition of the 128 patients at the time of writing. Of the 28 control cases 71 per cent. were dead and 14.5 per cent. alive (14.5 per cent. could not be traced). Of the 50 patients who received artificial heliotherapy, 24 per cent. were dead and 42 per cent. alive (34 per cent. untraced). Of the 50 patients treated with cod-liver oil and tomato juice 10 per cent. were dead and 86 per cent. alive (4 per cent. untraced).

The improvement in the condition of the patients began within a few days or weeks. The patients gained steadily in weight and more rapidly than those treated with ultraviolet radiation; the intestinal symptoms usually disappeared promptly and completely, and the gastro-intestinal tract became normal on radiographic examination.

It should be pointed out that the patients often complain, as we have also observed in our cases, of slight gaseous eructations savouring of cod-liver oil for the first week or so.

McConkey has not observed any contra-indications as he has not so far seen any gastro-intestinal tract becoming worse after the treatment. He continues the treatment for several months to a year after the tract becomes radiographically normal, or for a similar period after all intestinal symptoms have disappeared.

In closing one deviation from the method described by McConkey must be mentioned. He lays great stress on serving the cod-liver oil and juice ice-cold, but owing to the difficulty of getting ice we have been unable to do this. When using absolutely fresh orange or tomato juice, before there is any possibility of fermentation, the serving of the oil and juice ice-cold would seem unnecessary. We have had the most encouraging results in spite of this deviation from the original method.

THE ARTERIAL SUPPLY OF THE APPENDIX.

(From the Department of Anatomy, University Medical College, Mysore.)

By T. SESHACHALAM, L.R.C.P., M.R.C.S.,

Professor of Anatomy,

and

S. R. GORUR, M.B., B.S.,

Lecturer in Anatomy.

THE arterial supply of the appendix is derived from the ileo-cæcal branch of the ileocolic branch of the superior mesenteric artery. The appendicular artery passes behind the terminal part of the ileum, enters between the two layers of the mesentery of the appendix, and runs in its free border giving a variable number of branches to the appendix. This is the description in the commonly used textbooks in anatomy. Thompson and Miles' *Manual of Surgery* says "with its single artery of supply

* *The American Review of Tuberculosis*, May 1930, Vol. XXI, No. 5.

.....which if occluded.....at once shuts off the whole of the appendicular blood supply." Beesely and Johnston in their *Manual of Surgical Anatomy* say "it does not anastomose with any other artery."

Having seen variations from this description in some cases both in the dissection rooms and in the operation theatre, we investigated the arterial supply of the appendix in the dissection room of the Mysore University Medical College.

The present series includes 21 cases. Of these eleven cases contained one artery supplying the appendix (Fig. 1), conforming with the textbooks in anatomy. In seven cases there

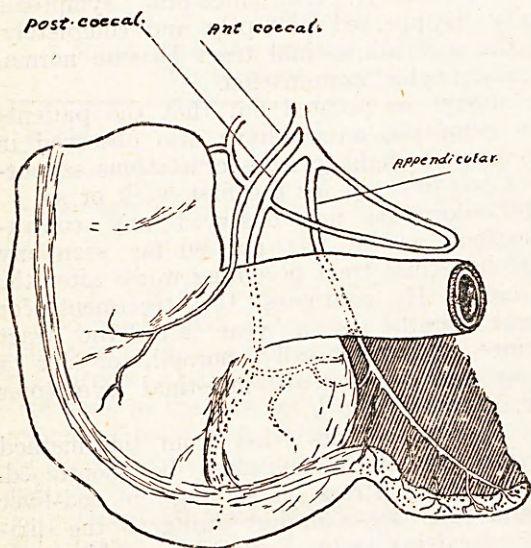


Fig. 1.

was a dual supply. An independent branch from the posterior caecal entered the appendicular mesentery and supplied the proximal part of the appendix. In two cases there was a double supply (as in Fig. 2) but the two arteries

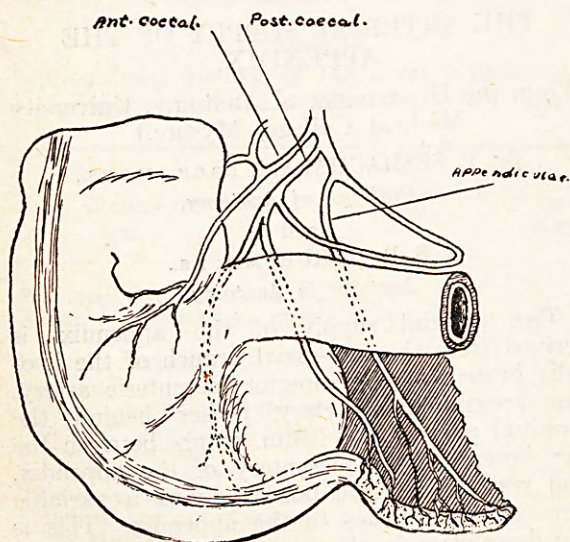


Fig. 2.

anastomosed with each other forming a regular arch within the mesentery from which branches were given off to the appendix (Fig. 3). Invariably in these cases, where the appendix

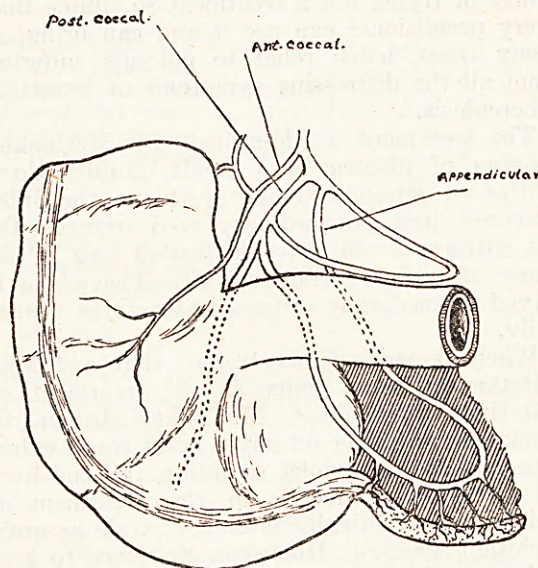


Fig. 3.

received a double supply, the appendix was longer than four inches in length indicating the necessity for a richer blood supply. In one case the appendix was bound down by adhesions and it could not be studied.

This investigation is interesting to the anatomist in establishing the variations in the blood supply of the appendix and also classifying them. It is of interest to the pathologist, for in cases of kinking or thrombosis the whole of the appendicular blood supply need not be shut off, at least in cases receiving a double blood supply. Many surgeons must have had the experience of applying an extra ligature near the stump of the appendix after the main artery has been ligatured in the mesentery. This little artery that troubles the surgeon is the independent branch from the posterior caecal.

This series of twenty cases is no doubt too small to draw any conclusions from but it serves to point out that the arterial supply is not so simple as is described in the ordinary textbooks in anatomy.

Summary.

- (1) The artery supplying the appendix is not always a single artery.
- (2) In some cases there are two arteries supplying it and in a small percentage of cases the two arteries form an arch.
- (3) The classification is interesting to the anatomist, useful to the pathologist, and a safeguard to the surgeon.