

## Three simultaneous cases of hypersensitivity pneumonitis and acute lung injury caused by dichloromethane

Kei Takamura<sup>1</sup>, Takahiro Ogi<sup>1</sup>, Makoto Yamamoto<sup>1</sup> & Keisuke Kikuchi<sup>2</sup>

<sup>1</sup>First Department of Medicine, Obihiro Kosei General Hospital, Obihiro, Japan.

<sup>2</sup>Department of Pathology, Obihiro Kosei General Hospital, Obihiro, Japan.

### Keywords

Acute lung injury, dichloromethane, hypersensitivity pneumonitis, simultaneous occurrence.

### Correspondence

Kei Takamura, First Department of Medicine, Obihiro Kosei General Hospital, West 6 East 8, Obihiro 080-0016, Japan. E-mail: keitak@hokkaido.med.or.jp

Received: 5 April 2016; Revised: 13 June 2016; 19 July 2016; 9 August 2016 and 30 August 2016; Accepted: 8 September 2016; Associate Editor: Tamera Corte.

*Respirology Case Reports*, 4 (6), 2016, e00193

doi: 10.1002/rcr2.193

### Abstract

Three middle-aged male patients were admitted to our hospital complaining of dry cough, dyspnoea, and fever. All three of them had cleaned a refrigerator at a Chinese noodle mill using paint remover containing dichloromethane (90%) the previous day. Chest X-rays revealed bilateral diffuse infiltrative shadows on the lungs. We performed transbronchial lung biopsies and bronchoalveolar lavage (BAL) via bronchoscopy for each patient. Bronchoalveolar lavage showed increased total cell count as well as lymphocyte and neutrophil fraction. Transbronchial lung biopsy revealed Masson bodies and slight lymphocyte infiltration into the alveolar septa. We diagnosed all three patients with hypersensitivity pneumonitis and acute lung injury caused by exposure to the paint remover containing dichloromethane. Two of these patients ultimately went into respiratory failure, requiring the administration of a corticosteroid. The third patient improved without the need of steroid therapy.

### Introduction

We studied the simultaneous occurrence of three cases of hypersensitivity pneumonitis (HP) and acute lung injury (ALI) caused by exposure to dichloromethane in paint remover. To our knowledge, there have been no reports in the literature on HP and ALI caused by dichloromethane exposure. So this is the first paper to study this subject.

### Case Report

The patients were three males aged 44, 48, and 56 years, respectively. They had worked in the closed environment of a new refrigerating room for 3 h to remove glue from the floor using a paint remover containing dichloromethane (90%), methyl alcohol (<5%), and vinyl chloride (<10%), without a mask over their nose and mouth for protection. On the day following exposure, two patients (Case 1: 44 years and Case 2: 48 years) were admitted to our hospital complaining of a dry cough, dyspnoea, and fever. Although the 56-year-old male (Case 3) had only a mild dry cough, he was also admitted for an investigation because he had worked with the other two patients under

the same conditions. None of the patients had a history of smoking.

Case 1 was alert and normotensive but tachypneic. Laboratory investigation revealed that white blood cell (WBC) count 11,200  $\mu$ /mL and C-reactive protein (CRP) 7.2 mg/mL were above the upper limit of the reference range. Also, the concentration of KL-6, which is a diagnosis index of interstitial lung disease, was 668 U/mL (normal <500 U/mL), that is, it was also higher than the normal value (Table 1). Arterial blood gas analysis performed under the administration of oxygen (4 L/min, nasal prong) indicated that the patient's partial pressure of oxygen (PaO<sub>2</sub>) was 91.6 mmHg. Chest X-ray showed bilateral diffuse patchy shadows with a ground glass appearance and chest computed tomography (CT) showed bilateral diffuse ground glass-like infiltrate, which was predominant in the lower zone of the lungs (Fig. 1, left). Moreover, bronchoalveolar lavages (BALs) revealed that the patient had abnormally high total cell count (TCC), lymphocytic fraction, and neutrophilic fraction in the BAL fluid (Table 1).

Case 2 also showed tachypnoea and elevation in WBC (12,800  $\mu$ /mL), CRP (2.4 mg/mL), and concentrations of

**Table 1. Laboratory findings**

	Case 1	Case 2	Case 3
<i>Haematology</i>			
WBC ( $\mu\text{mL}$ , 3600–9000)	11,200 $\uparrow$	12,800 $\uparrow$	6600
Neu (%)	94	89	74.3
<i>Serology</i>			
CRP (mg/dL, 0–0.3)	7.2 $\uparrow$	2.4 $\uparrow$	1.3 $\uparrow$
LD (IU, 119–229)	311 $\uparrow$	391 $\uparrow$	280 $\uparrow$
KL-6 (U/mL, <500)	668 $\uparrow$	692 $\uparrow$	560 $\uparrow$
<i>Blood gas analysis</i>			
	(O <sub>2</sub> 4 L/ min)	(O <sub>2</sub> 5 L/ min)	(RA)
pH	7.43	7.41	7.42
PaCO <sub>2</sub>	40.2	36.1	40.2
PaO <sub>2</sub>	91.6	82.3	72.9
HCO <sub>3</sub>	25.8	22.2	25.3
P/F ratio	254 $\downarrow$	205 $\downarrow$	347
<i>Bronchoalveolar lavage</i>			
Total cell count ( $\mu\text{L}$ , 20–100)	739 $\uparrow$	1040 $\uparrow$	448 $\uparrow$
Neu (% <3.0)	34.0 $\uparrow$	54.2 $\uparrow$	1.0
Lym (% 4–25)	43.2 $\uparrow$	39.2 $\uparrow$	12.2 $\uparrow$
Eos (% <1.0)	4.4 $\uparrow$	2.8 $\uparrow$	0.2
M $\Phi$ (% 75–95)	5.8 $\downarrow$	0.6 $\downarrow$	82.8
CD4/8 (1.5–3.2)	0.8 $\downarrow$	1.53	3.18 $\uparrow$

WBC, white blood cell; CRP, C-reactive protein; Neu, neutrophil; PaCO<sub>2</sub>, partial pressure of carbon dioxide; PaO<sub>2</sub>, partial pressure of oxygen; HCO<sub>3</sub>, bicarbonate; Lym, lymphocyte; Eos, eosinophil; LD, Lactate dehydrogenase; KL-6, Sialylated carbohydrate antigen; CD4/8, CD4-CD8 ratio; P/F ratio, PaO<sub>2</sub>-FiO<sub>2</sub> ratio.

KL-6 (692 U/mL) (Table 1). The patient's PaO<sub>2</sub> was 82.3 mmHg. His CT scan also showed ground glass-like shadows bilaterally (data not shown). The BAL fluid of Case 2 also revealed a rise in TCC with elevation in lymphocytic and neutrophilic fractions (Table 1).

Although the clinical symptom of Case 3 (56 years) was mild dry cough, his laboratory tests showed mild inflammation and a slight rise in KL-6 value (Table 1) and his PaO<sub>2</sub> was 72.9 mmHg. A CT scan of Case 3 revealed patchy reticular shadows on both lower lobes (Fig. 1, right). The BAL fluid of this patient also showed an increase in total cell count with increasing lymphocyte fraction.

Histopathological examination was performed in all three cases. For Cases 1 and 2, we could not detect significant change in lung tissue. However, the transbronchial lung biopsy of Case 3 showed slight lymphocyte infiltration into the alveolar septa (Fig. 2, arrow) and formation of Masson bodies was detected (Fig. 2, arrowhead).

From these clinical and laboratory findings, it was determined that these patients had simultaneous development of HP and ALI due to exposure to paint remover which contains dichloromethane.

Initially, methylprednisolone was initiated for Cases 1 and 2, and then we prescribed prednisolone (60 mg/day for a week and then reduced to 10 mg/day every week). The steroid treatment was successful and they were discharged from the hospital 7 days later. Patients 1 and 2 were discharged from the hospital on a prescription of prednisolone 50 mg, which was reduced to 10 mg/week for 1 week and eventually stopped after the administration of 10 mg. Patient 3 recovered without the need of treatment.

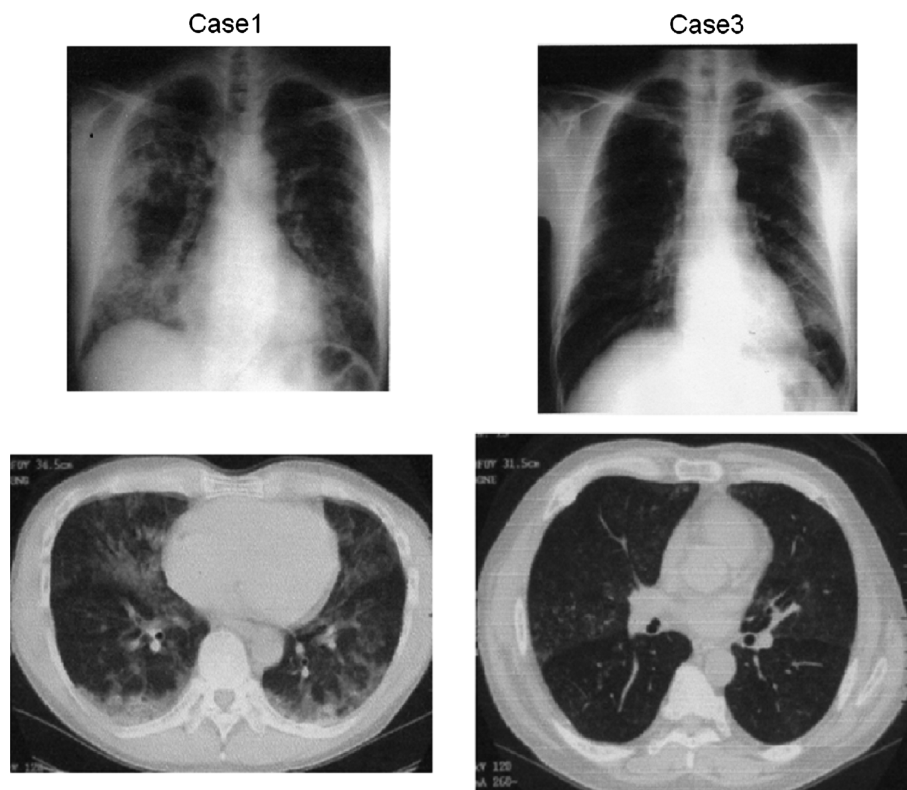
## Discussion

Generally, HP is characterized by a granulomatous pneumonia caused by sensitization to organic mineral dust in the respiratory tract. However, it is possible for low molecular weight compounds such as inorganic isocyanate to bind to amino acids in proteins forming hapten, with the subsequent development of HP [1,2]. Vandenas et al. reported on the occurrence of HP in at least 8 of 167 workers potentially exposed to diphenylmethane diisocyanate [1]. In this report, however, the duration of individual exposure ranged from 2 to 10 weeks, which differed from the rapid onset that occurred in our patients. Takazakura et al. also reported on several cases of HP following exposure to isocyanate [2].

Another case of HP due to exposure to an organic solvent was reported by Yoshitaka et al. [3]. This study examined a case of ALI caused by exposure to high concentration of trichloroethylene vapour. In addition, Kunimasa et al. reported on chemical pneumonitis and ALI caused by inhalation of nickel fumes [4].

In this case, the paint remover consisted of dichloromethane, methyl alcohol, and vinyl chloride. Dichloromethane and methyl alcohol have been identified as hazardous substances by the Department of Labor Safety and Health, indicating a necessity for workers using these chemicals to wear protective gear (e.g., a respirator and gloves) and to ensure proper ventilation at the workspace. Of these three chemical substances, dichloromethane is the most harmful. Recently, another toxicity of dichloromethane exposure reported to increase risk of occupational cholangiocarcinoma among workers of a Japanese printing company by Kubo et al. [5].

To the best of our knowledge, HP and ALI resulting from dichloromethane exposure have not been reported. So this is the first report on HP and ALI caused by inhalation of this particular chemical.



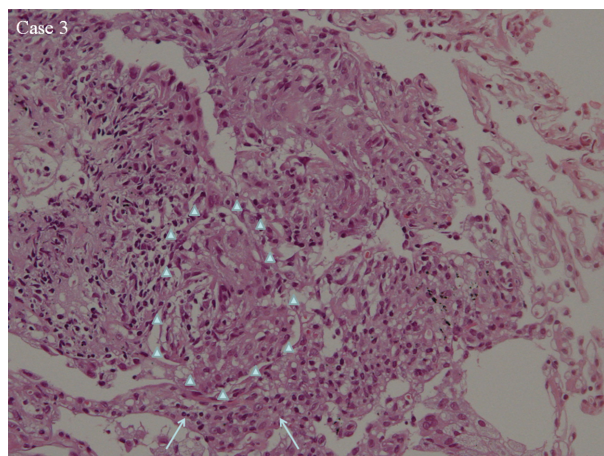
**Figure 1.** Chest X-ray and computed tomography scan of Cases 1 and 3.

To prevent such injuries, personal protective equipment must be provided to the workers, and in the case of accidental exposure, careful clinical observation should be made mandatory.

#### Disclosure Statements

No conflict of interest declared.

Appropriate written informed consent was obtained for publication of this case report and accompanying images.



**Figure 2.** Pathological findings of Cases 1–3. Cases 1 and 2 had no significant change in lung tissue. However, transbronchial lung biopsy of Case 3 showed slight alveolitis (arrow), and formation of Masson bodies or granuloma was detected (arrowhead).

#### References

1. Vandenplas O, Malo JL, Dugas M, et al. 1993. Hypersensitivity pneumonitis-like reaction among workers exposed to diphenylmethane [correction to piperonylbutoxide] diisocyanate (MDI). *Am. Rev. Respir. Dis.* 147:338–346.
2. Takazakura E, Tsuji H, Makino H, et al. 1987. Two cases of hypersensitivity pneumonitis due to isocyanate in foundry castworkers. *Nihon Kyobu Shikkan Gakkai Zasshi* 25:924–928.
3. Yoshitaka M, Ishikawa R, Yokosuka K, et al. 2013. A case of acute lung injury due to exposure to high concentration of vapor trichloroethylene. *Kokyu To Junkan* 51:1167–1170.
4. Kunimasa K, Machiko A, Hiromasa T, et al. 2011. Chemical pneumonitis and acute lung injury caused by inhalation of nickel fumes. *Intern. Med.* 50:2035–2038.
5. Kubo S, Kinoshita M, Takemura S, et al. 2014. Characteristics of printing company workers newly diagnosed with occupational cholangiocarcinoma. *J. Hepatobiliary Pancreat. Sci.* 10:13.