

Decision Making in Bowel Obstruction: A Review

ASWINI KUMAR PUJAHARI

ABSTRACT

Over the last century there have not been significant changes in the anatomical location of obstruction. The age of presentation has increased along with age related co-morbidity. Management has consequently been challenging as risks keep on increasing with advanced age. Hence, clear decision making has become essential in its management. A selective review of the literature pertaining to common age related aetiologies, diagnosis methods leading to standard decision making and treatment of acute intestinal obstruction was done. The same is obtained from randomized controlled studies, meta-analysis and other related evidence based publications. Predicting the conservative or operative management of Bowel Obstruction (BO) is difficult. BO in young age, in unscarred abdomen and Large Bowel Obstruction (LBO) needs early surgery. Decision on surgery should be taken in paediatric patient by second day and preferably between 3-5 days of admission in adults. Higher American Society of Anaesthesiologists (ASA) grade correlates well with the mortalities. In this article, the timing of surgery, methods to avoid bowel resection and type of surgery in various causes are stressfully analysed and discussed.

Keywords: Adhesive obstruction, Non adhesive obstruction, Virgin abdomen, Intestinal obstruction, Timing of surgery

INTRODUCTION

Over the last 100 years, the anatomical location of Bowel Obstruction (BO) has remained unchanged; however, the aetiological factors in small and large BO have changed significantly. With advance of time more and more elderly patients are presenting with BO [1]. But still, BO continues to be one of the most common surgical emergencies [2] encountered in general surgery units and it continues to be a major cause of morbidity and financial expenditure [3]. Peritoneal adhesions and hernia were the most common causes of BO and contributing 42.3% [4]. All patients of BO are potential candidates for major abdominal surgery with long term morbidity and possible mortality. Hence, the decision of surgery and its timing is vital.

Various factors are considered for taking the decision on operative or non-operative management. The factors considered are age of the patients, duration of obstruction, volume of nasogastric aspirate, findings on the radiological imaging, previous abdominal surgeries and malignancy.

Decision in Small Bowel Obstruction (SBO)

Clinical presentation of pain, vomiting, distension and constipation, laboratory and radiographic factors should all be considered when making a decision about treatment of BO [5]. One must rule out an abdominal wall hernia as a cause of BO, which is seen in 26.8% of cases in virgin abdomen [4]. Plain radiograph should be an integral part of management of patients with clinical suspicion of BO and gastrointestinal perforation [6] [Table/Fig-1]. The diagnosis in most cases will be confirmed by further imaging studies such as ultrasound, contrast studies or most commonly in contemporary practice, the Computed Tomography (CT) [7].

The CT scan, besides confirming the diagnosis of BO, it gives information on partial or complete obstruction, its location, it also provides specific type like closed loop type and helps in deciding early surgery. Contrast Enhanced Computed Tomography (CECT) give enough information on ischemic bowel and bowel oedema, which requires emergency surgery and luminal gastrograffin helps in relieving the BO [8,9].

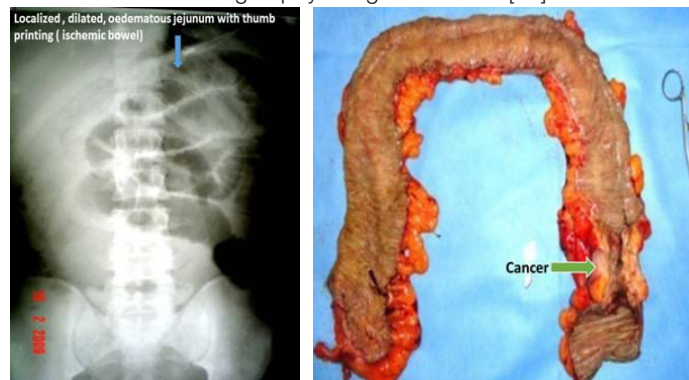
Surgeons find coronal images more helpful than axial images for management [10]. The radiographic transition zone alone does not increase the likelihood of surgical intervention or identify patients who will fail non-operative management [11]. The four cardinal features

– intra peritoneal free fluid, mesenteric oedema, presence of the "small bowel faeces sign" and history of vomiting - are predictive of requiring immediate emergency operative intervention [5].

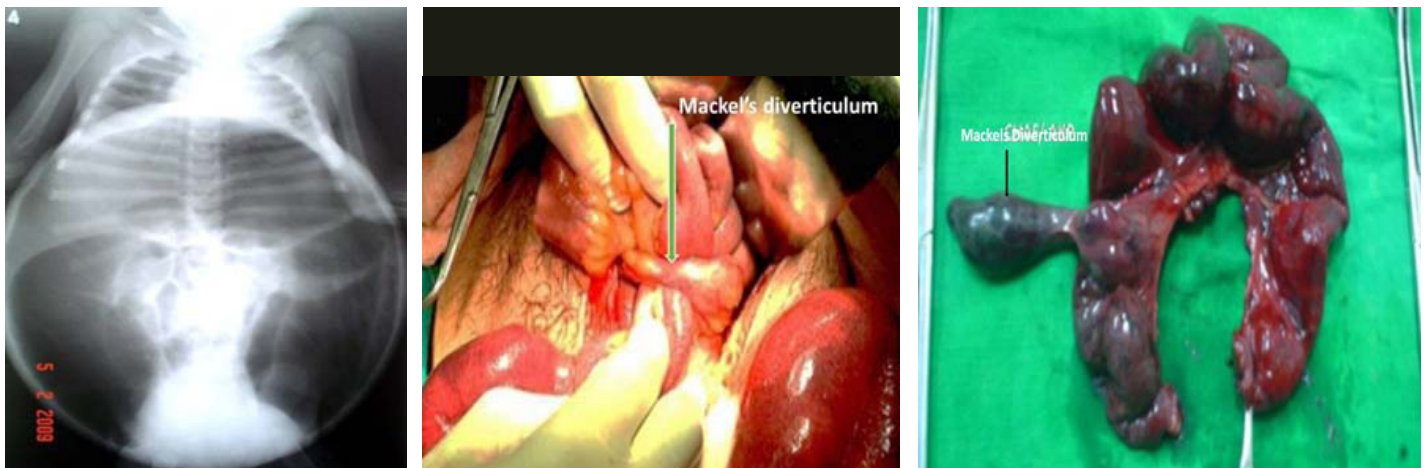
Decision in large bowel obstruction

In Indian scenario, two common types of Large Bowel Obstructions (LBO) are seen. They are: (a) Acute obstruction due to Sigmoid volvulus (SV); and (b) Sub-acute or chronic obstruction due to cancer of colon. In suspected volvulus, plain X-rays may help with diagnosis but MRI is more reliable. However, flexible endoscopy is always diagnostic as well as therapeutic [12]. Once diagnosed flatus tube, hydrostatic enema or colonoscopic reduction attempt is the choice in vascularized bowel. No endo-luminal reduction to be attempted with the sign of gangrenous SV. If the above methods succeed, later an elective sigmoidopexy or preferably sigmoid colectomy is required to avoid recurrence. When the endoscopic methods fail, emergency laparotomy is indicated, where it is untwisted, the definitive and standard therapy, sigmoid resection and primary anastomosis is the choice [13]. The non-resective alternatives have also been widely used with mixed success, but a large, randomized controlled trial is needed to compare their efficacy with resection and primary anastomosis. Laparoscopic surgery in SV management is unwarranted and costly. Complications of SV include haemorrhagic infarction, perforation, septic shock, and death (14-45%) [14].

Colorectal cancer presents as an emergency with LBO in up to 29% of cases. These patients are often elderly with multiple co-morbidities and deranged physiological function [15].



[Table/Fig-1]: Plain X-ray abdomen- localized dilated bowel (ischemic). **[Table/Fig-2]:** Subtotal colectomy specimen in left sided cancer colon with obstruction.



[Table/Fig-3]: Neglected megacolon. **[Table/Fig-4]:** Meckel's Diverticulum causing obstruction. **[Table/Fig-5]:** Meckel's related BO needing resection.

Almost 42% of such patients will have anaemia preoperatively [16] and showed worse prognosis [17]. Haematological work up and time permitting iron therapy is useful [16,17]. Pre-operative ferric carboxymaltose treatment in patients with colon cancer and iron deficiency anaemia significantly reduced RBC transfusion requirements and hospital length of stay, reaching higher response rates and percentages of normalized haemoglobin levels both at hospital admission and at 30 days post-surgery [16,17]. But, in an emergency setting it may not be of much value.

Due to the deranged physiological setting in elderly, staged surgical procedures were advised, but recent trends have moved towards a primary resection and anastomosis [15].

However, the following options may be considered [18]-

- Temporary relief by metal stent, bowel preparation and surgery;
- Primary resection and anastomosis- with or without on table preparation;
- Initial proximal diversion and staged cancer surgery;
- Primary resection of the cancer, loaded proximal colon colectomy, end colostomy and Hartman's pouch
- Subtotal colectomy [Table/Fig-2] and ileo-rectal anastomosis.

Self-Expanding Metal Colonic Stent (SEMS) is found to be safe and effective in obstructing colorectal cancer and effective method of alleviating acute and impending BO [18]. The same can be used in LBO either as palliation or bridge to surgery. They are associated with an overall better outcome and improved quality of life of patients. Surgery is indicated where SEMS are unavailable or have failed [19]. It gives a better chance of primary anastomosis and reduce the need for stoma creation and post procedural complications without any effect on peri-operative morbidity, mortality and long-term survival [20,21]. Delaying the surgery after patency by colonic stent is found to be having higher local recurrence rate in comparison to emergency subtotal colectomy [22].

One stage primary resections with anastomosis of the large bowel can be performed safely in case of emergency whenever patient comorbidities and local conditions do not stand as major restrictions [23]. Possibly due to gross faecal loading this is not suitable in South East Asia. Options with stomas are not preferred by the patients and also give poor quality of life more so in elderly people. The last option of subtotal colectomy and primary ileo-rectal anastomosis in a semi-emergency basis is a safe and efficient procedure in the management of acutely obstructed neoplasm of the left colon [24]. Despite the difficult pre-operative conditions, subtotal colectomy for left colonic obstruction is found to have lower anastomotic leak rate than the segmental colectomy [25]. The advantages of the last options are many: (a) No bowel preparation, as all the loaded bowel are removed and per anal rectal wash can be given to clean the rectum; (b) It allows to treat in one stage the cancer and the

obstruction [24]; (c) Biggest advantage is no stoma; (d) Pre-surgery chronic constipation get relieved; (e) No need of follow up repeated screening colonoscopy; (f) Proximal Synchronous lesions are taken care of. The disadvantages are: (a) Technically difficult surgery in presence of grossly dilated and loaded colon [26]. This can be made easier once the mobilized right colon is kept outside the abdomen; (b) Increased frequency of motion for 6-8 months and peri-anal excoriation. In spite of frequent loose motions many patients become happy, because it is a great relief for them after a long period of chronic constipation.

Laparoscopic resectional surgery in acute LBO is feasible and safe option with a low complication rate that enables early hospital discharge [27]. In view of the various alternatives and the lack of high-grade evidence, the treatment of distal colonic obstruction should be individually tailored to each patient [28].

Age related – Decision making in newborn, young and old

Age is one of the important factors in decision making in BO. Extremes of age have a low body reserve and are liable for higher morbidity and mortality and hence, an early decision is needed for surgery or otherwise [4]. BO in the newborn is a common reason for admission to neonatal ICUs. The incidence is estimated to be approximately 1 in 2000 live births. There are 4 cardinal features of intestinal obstruction in new-borns: (1) Pre-natal maternal polyhydramnios; (2) Bilious vomiting; (3) No passage of meconium; and (4) Abdominal distension. Massive abdominal distension with respiratory distress and cardiovascular collapse is common in neglected megacolon [Table/Fig-3]. A detailed history from the mother and periodic physical examination and X-ray abdomen clinches the diagnosis [29]. Internal hernia and Meckel's diverticulum related BO [Table/Fig-4] is rare but important. Meckel's diverticulum can be overlooked in many cases hence, it is recommended that the small bowel be assessed in all cases of appendectomy [30]. 16.4% of children and adolescents undergoing operative management require bowel resections [Table/Fig-5]. To avoid potentially increasing risk for bowel loss, intervention should be considered by the second day in patients who do not exhibit signs of improvement [31].

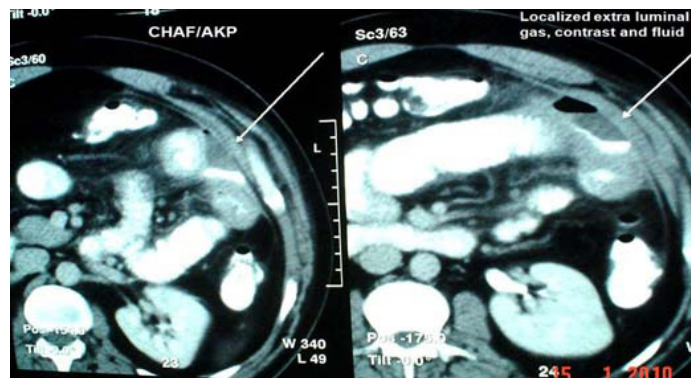
As old age is significantly associated with an increased incidence of strangulation, operative mortality and complications, this group of patients should be managed with extra caution to avoid unfavourable outcome of surgery [4]. Electrolyte imbalance, mostly hyponatraemia and hypokalaemia needs correction before any decision.

Virgin abdomen vs. scarred abdomen

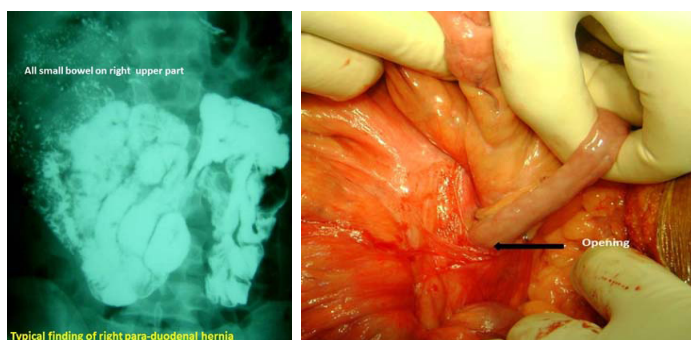
BO in a virgin abdomen is non-adhesive and mostly due to congenital bands and internal hernia. It is rare but, may be a life-threatening surgical emergency. A high index of suspicion based on the patient's history and response to conservative management

Congenital	Acquired
Internal hernia	Post-operative adhesion
Para-duodenal Rt & Lt	Tubercular strictures
Para-caecal	Luminal worms/ polyp Bezoars
Mesenteric and mesocolic defect hernia	GJ intussusception
Cong adhesion	Bezoars
Vitelline duct related	Pseudo obstruction
Caecal and sigmoid volvulus	Luminal worms/ polyp
	Radition enteritis Endometriosis Gall stone ileus Talk granuloma related

[Table/Fig-6]: Common causes of recurrent bowel obstruction.



[Table/Fig-9]: Localized leak as a cause of ileus.



[Table/Fig-7]: Barium enema study showing all small bowel to right (right para-duodenal hernia). [Table/Fig-8]: Bowel coming out of internal hernia.

is required to achieve early diagnosis so that surgical treatment can be rapidly instituted [32]. Peritoneal adhesions causing SBO is the commonest cause contributing 42.3% [4]. The rate of recurrent obstruction is around 15.9% and 5.8% requiring surgical management [33]. The general impression is that laparoscopic surgery causes less adhesions. But a single centre study has reported no difference in the incidence of post-operative adhesive intestinal obstruction between laparoscopic and open colorectal resection [34]. Surgically treated patients had a lower frequency of recurrence and a longer time interval to recurrence; at the cost of longer hospital stay. There is no predictor of adhesive BO either before or after surgery or any variables predicting the success of a particular treatment [35]. However, patients with matted adhesions have a higher recurrence rate than those with band adhesions. Non-operative treatment for adhesions in stable patients results in a shorter hospital stay and similar recurrence and re-operation rates, but a reduced interval to re-obstruction when compared with operative treatment [3]. These patients need close observation and repeated abdominal examination for evidence of impending bowel ischemia, in the form of raised C-Reactive Protein (CRP) serum lactate, raised total leucocytes count besides guarding.

Recurrent BO

Recurrent bowel obstruction- common causes are given in [Table/Fig-6]. Recurrent BO is seen in three clinical scenario. The first is on an unscarred abdomen, mostly due to internal hernia, secondly during an early post-operative period, where there is likely confusion of post-operative ileus/ BO. The third scenario being adhesive obstruction. All these three situations are discussed below.

a. Recurrent BO in virgin abdomen

Often, they present at recurrent BO and keep resolving on conservative management. A CT scan with oral contrast and even a barium study of small bowel is usually diagnostic. Para-duodenal hernia constitute 50% of internal herniation [Table/Fig-7] [36,37]. A small bowel barium study/ CT-scan may be diagnostic [38]. Laparoscopy continues to be a safe diagnostic and therapeutic tool in the management of pediatric initial BO and recurrent small BO [39]. In case of any difficulty, an open surgical reduction [Table/Fig-8] can be undertaken.

b. Early post-operative BO or early recurrence BO after relieve of BO/ paralytic ileus

This is the most serious condition, as the patients has been fasting and still vomiting. This leads to malnutrition and electrolyte imbalance. When this state of post-operative ileus remains longer than usual, patient continues to have distended abdomen and continues to vomit. It is important to rule out any intestinal leak. It is mostly localized due to the adhesion [Table/Fig-9] and rarely leads to peritonitis. Any form of drainage will lead to a faecal fistula and, hence the critical decision can be taken on laparotomy and closure or create a fistula. Whatever may be the decision, parenteral nutrition must be instituted in this state of bowel failure. In case a stoma is created in jejunum or mid bowel, the distal bowel can be utilized in the way of distal feeding of the output [40]. This type of chyme re-infusion or enteroclysis are less expensive, well tolerated, and easy-to-use nutrition support techniques, which may allow reducing parenteral nutrition-related healthcare costs and lifesaving [40].

The next step is to differentiate between prolonged paralytic ileus and mechanical BO. One should suspect mechanical obstruction when: Patient had passed flatus/stool and then it stopped again, noisy peristalsis and no flatus, colicky pain, X-ray/CT-scan/contrast study abdomen suggests obstruction [41]. The incidences of re-surgery are given in [Table/Fig-10]. Once it is established as mechanical obstruction and bowel is non gangrenous, a gastrograffin trail can be given and if it fails, then surgery can be done as per the algorithm.

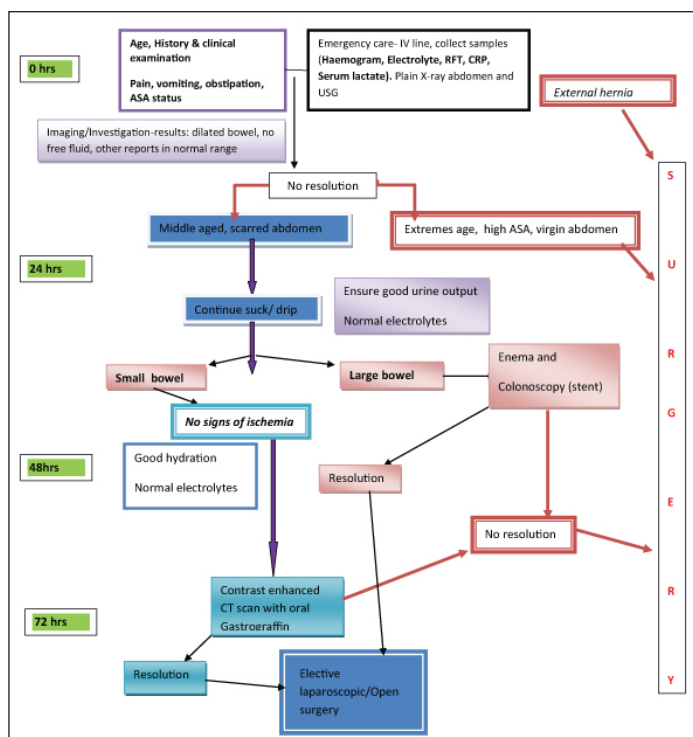
Then only one can think of using alvimopan and methylantrexone, the peripherally acting μ -opioid receptor antagonists can be used to accelerate gastrointestinal recovery. In another randomized trial administration of Bisacodyl demonstrated significantly earlier bowel movements than those who received placebo (25 h vs. 56 h) [42]. Even in early post-operative adhesion the management protocol should follow the algorithm [Table/Fig-11].

S. No	Number of operation	Cases of relaparotomy	Relaparotomy due to ileus condition	%	Reference
1	4908		57	1.161	[43]
2	71588	1049	411	0.57	[44]
3	1795	30	24	1.331	[41]

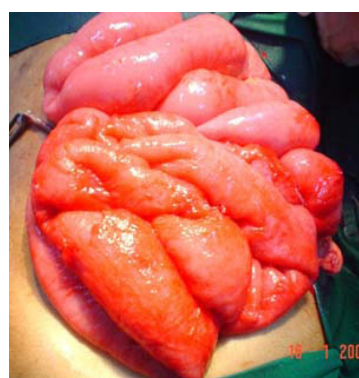[Table/Fig-10]: Incidence of re-laparotomy in ileus like condition [41,43,44].

c. Late post-operative recurrence

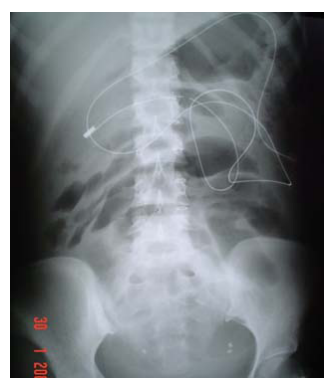Recurrent BO is a real challenge in adhesive type. The common causes are given in [Table/Fig-6]. There are many more rare and uncommon causes besides given in the table. The initial management remains the same as applicable in the algorithms. In recurrent adhesive SBO, not resolving even after gastrograffin trail, surgery is indicated. During surgery, after adhesiolysis, it is better to do a plication of the bowel to avoid next attack [Table/Fig-12] [45]. The plication can be done by fixing the mesentery (The Noble plication) by Protective fibrin-sealed application [46]. Trans- mesenteric plication can also be done in a state of peritonitis [47]. But in the



[Table/Fig-11]: Management protocol.

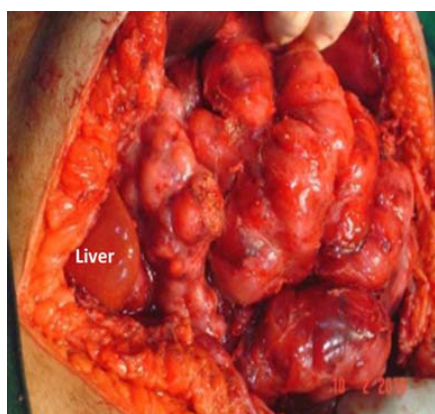


[Table/Fig-12]: Plicated bowel.



[Table/Fig-13]: Stenting the bowel.

[Table/Fig-9] only sero-muscular suturings are used for plication to avoid mesenteric vascular accident. This patient has not had the 4th attack of BO after this plication. A long intra-luminal tube and or a long intestinal luminal tube [Table/Fig-13], as a stent may add the luminal patency even with serosal adhesion and can be given early feeding with multiple holes throughout the intra-luminal part of the tube and lower post-operative complications [48]. Studies are on to find an anti-adhesive intraperitoneal fluid or surface application like 4DryField(®) PH and Seprafilm(®). Only the surface application of 4DryField(®) PH and Seprafilm(®) showed significant adhesion prevention capabilities. 4DryField(®) PH achieved the highest



[Table/Fig-14]: Undilated bowel in advanced ovarian cancer.

adhesion prevention effectiveness without restrictions concerning mode of application and compatibility and, thus, is a promising strategy to prevent abdominal adhesions [49].

However, In a cochrane database systematic review, the positive results are refuted [50]. Similar, negative result is reported for icodextrin as an anti-adhesive intraperitoneal fluid [51]. In fact the cause of the recurrent obstruction must be found out and addressed once the acute obstruction resolves. Such cases are common in internal hernias. A barium study or CT scan with enteral contrast clinches the diagnosis. If both go without a diagnosis, a diagnostic laparoscopy will culminate to therapy as well.

If surgery is needed during the acute attack, laparotomy the not only gives the diagnosis but curative surgery can be done. The case of abdominal cocoon is challenging to the surgeon plain X-ray shows hardly any dilated small bowel to the inquisitive surgeon. At times it might be cocoon which covers the entire small bowel. It is mostly due to tuberculosis in India [52]. Occasionally it may be due to fibrosis of the peritoneum [53]. Tricky adhesiolysis by an experienced surgeon is needed.

Gastrografin trial

Data showed that, the use of gastrografin in adhesive small intestine obstruction is safe and reduces the operative rate and the time to resolution of obstruction. One study has reported the resolution of obstruction in 81.5% after a mean time of 6.4 hours [54]. When it resolves, it reduces the hospital stay with adhesive SBO [54-56] and failure to resolve is an effective indication in predicting the need for surgery [55]. It is better to do a CT scan with oral contrast to know the location and cause of obstruction so that it can be dealt with during this attack or be prepared in case of any recurrence.

Ovarian cancer related bowel obstruction

Ovarian cancer needs special mention due to the high incidence of BO in these patients. Nearly 20% of women developed BO after they are diagnosed with cancer. There is associated increased risk of subsequent obstructions [57]. Un-dilated bowel in presence of features of SBO does not benefit from operative intervention [Table/Fig-14]. Estimation of CA-125 may be helpful. Diligent discussion with the primary team and frank discussions with the patient and his or her family are essential to formulate an appropriate plan [58].

Timing and decision for surgery

Timing is crucial to avoid gangrenous bowel resection and obvious electrolyte imbalance. Identifying patients who may safely undergo non operative management remains difficult [59]. In a large study of 1613 patients 56.6% required surgery and 43.4% could be managed non-operatively [59]. There was an associated higher incidence of bowel resection in patients who took increased time to reach the operating room. Among the patients in whom the admission to operating room was less than 24 hours, 12% patients had bowel resection as compared to 29% in patients who took greater than 24 hours [59]. To avoid potentially increasing risk for bowel loss, intervention should be considered by the second day in a paediatric patient with low threshold in those who do not exhibit signs of improvement [31] and no more than 5 days in adults [60]. BO in young age and patients having virgin abdomen are more likely to under go operation [59]. Patients with a CT reading of complete obstruction, dilated small bowel and free fluid were operated on 77%, 66%, and 65% of the time, respectively [61].

Patients on conservative treatment for BO, where drainage volume through the nasogastric tube on day 3 is > 500mL, mostly required surgery [62]. CT scan of abdomen with oral gastrografin not only gives the location of BO but also adds to the gastrografin trial and avoids an abdominal surgery [63]. When a procedure is needed for adhesiolysis, laparoscopic adhesiolysis in expert hand in selected patients, reduced overall complication rate. It is found to be advantageous in studies [64]. The post-operative hospital stay was

significantly shorter in the Laparoscopic Adhesiolysis (LA) group compared to converted (3 vs. 9 days). LA is safe and feasible for the management of BO and should be offered to all patients with BO unless there is an absolute contraindication to laparoscopic surgery [65,66]. It is also suitable in paediatric age group [67]. It is an excellent diagnostic tool and, in most cases, a therapeutic modality in patients with SBO. However, a significant number of patients will require conversion [66]. Open adhesiolysis is faster than laparoscopic adhesiolysis (LA) [68]. A previous upper abdominal surgical incision and a transition zone outside of the pelvis on CT scan were pre-operative predictors of a successful laparoscopic adhesiolysis. The laparoscopic group had shorter length of stay [69]. LA in presence of dilated bowel leads to less colmen for the play of the instruments and hence, it is not advisable. It is ideal, where BO caused by post-operative adhesion had resolved earlier on conservative management and the patient comes with recurrence, where LA to be attempted early before gross dilatation of the bowel [70]. Conversion to mini-laparotomy or laparotomy should be considered in patients with dense or pelvic adhesion [71].

Once the diagnosis of BO is established clinically and confirmed by radiological investigation; then comes the decision. There are two decisions conservative or operative. If conservative is chosen, the responsibility of the treating team is to operate before the bowel becomes gangrenous. Hence, repeating X-ray/CT scan and radiating the patient looks non-academic. Secondly clinical diagnosis of resolution of BO is quite evident clinically.

Palliation in BO

In palliative care patients with nausea and vomiting, 5HT₃ receptor antagonists can be used if treatment with other antiemetics, such as metoclopramide and neuroleptics is not sufficient.

There is a trend that steroids in combination with other antiemetic improve symptom relief.

Cannabinoids have a status as a second line antiemetic. As a palliative care in malignant obstruction, long acting octreotide remains the first choice and butyl-scopolammonium bromide, the second to palliate the symptoms [72]. In a small study of only 12 cases, (patients with malignant BO/ bowel dysfunction), most of the patients improved with combination of anti-inflammatory (Dexamethasone), anti-secretory (Octreotide), and prokinetic (metoclopramide).

Post-operative prognosis

The early post-operative mortality is strongly linked with the age and the American Society of Anesthesiologists (ASA) grade and the long-term mortality with post-operative complications [73]. More frequent bowel resections might be suggested for patients featuring 10 or more obstructive strictures and an intestinal wall injury, especially when associated with a reversible intestinal ischemia [74].

CONCLUSION

Predicting the conservative or operative management in BO is difficult. Decision on surgery should be taken in paediatric patient by 24 hours, in young age, in virgin abdomen and large BO by 48hrs and within 3-5 days of admission in adults, if the oral gastrografin fails to resolve the BO more so the adhesive obstruction with high (>500ml) gastric tube aspirate (Algorithm). In recurrent BO some form of plication may be considered during surgery. The early post-operative mortality is strongly linked with the age and the ASA grade whereas the long-term mortality is associated with post-operative complications.

REFERENCES

- [1] Drozdd W, Budzynski P. Change in mechanical bowel obstruction demographic and aetiological patterns during the past century: observations from one health care institution. *Arch Surg*. 2012;147:175-80.
- [2] Ciocchi R, Abraha I, Farinella E, Montedori A, Sciannone F. Laparoscopic versus open surgery in small bowel obstruction. *Cochrane Database Syst Rev*. 2010;17(2):CD007511.
- [3] Miller G, Boman J, Shrier I, Gordon PH. Natural history of patients with adhesive small bowel obstruction. *Br J Surg*. 2000; 87:1240-47. PMID: 10971435
- [4] Lo OS, Law WL, Choi HK, Lee YM, Ho JW, Seto CL. Early outcomes of surgery for small bowel obstruction: analysis of risk factors. *Langenbecks Arch Surg*. 2007;392:173-78.
- [5] Zielinski MD, Eiken PW, Bannon MP, Heller SF, Lohse CM, Huebner M, Sarr MG. Small bowel obstruction-who needs an operation? A multivariate prediction model. *World J Surg*. 2010;34:910-19.
- [6] Loughborough W. Development of a plain radiograph requesting algorithm for patients presenting with acute abdominal pain. *Quant Imaging Med Surg*. 2012;2:239-44.
- [7] Musson RE, Bickle I, Vijay RK. Gas patterns on plain abdominal radiographs: a pictorial review. *Postgrad Med J*. 2011;87:274-87.
- [8] Qalbani A, Paushter D, Dachman AH. Multidetector row CT of small bowel obstruction. *Radiol Clin North Am*. 2007;45:499-512.
- [9] Desser TS, Gross M. Multidetector row computed tomography of small bowel obstruction. *Semin Ultrasound CT MR*. 2008;29:308-21.
- [10] Shah ZK, Uppot RN, Wargo JA, Hahn PF, Sahani DV. Small bowel obstruction: the value of coronal reformatted images from 16-multidetector computed tomography a clinicoradiological perspective. *J Comput Assist Tomogr*. 2008;32:23-31.
- [11] Colon MJ, Telem DA, Wong D, Divino CM. The relevance of transition zones on computed tomography in the management of small bowel obstruction. *Surgery*. 2010;147:373-77.
- [12] Atamanalp SS. Sigmoid volvulus: diagnosis in 938 patients over 45.5 years. *Tech Coloproctol*. 2013;17:419-24.
- [13] Oren D, Atamanalp SS, Aydinli B, Yildirman MI, Basoglu M, Polat KY, et al. An algorithm for the management of sigmoid colon volvulus and the safety of primary resection: experience with 827 cases. *Dis Colon Rectum*. 2007;50:489-97.
- [14] Osiro SB, Cunningham D, Shoja MM, Tubbs RS, Gielecki J, Loukas M. The twisted colon: a review of sigmoid volvulus. *Am Surg*. 2012;78:271-79.
- [15] McCullough JA, Engledow AH. Treatment options in obstructed left-sided colonic cancer. *Clin Oncol (R Coll Radiol)*. 2010;22:764-70.
- [16] Calleja JL, Delgado S, del Val A, Hervás A, Larraona JL, Terán Á, et al. Ferric carboxymaltose reduces transfusions and hospital stay in patients with colon cancer and anaemia. *Int J Colorectal Dis*. 2016;31:543-51.
- [17] An MS, Yoo JH, Kim KH, Bae KB, Choi CS, Hwang JW, et al. T4 stage and preoperative anaemia as prognostic factors for the patients with colon cancer treated with adjuvant FOLFOX chemotherapy. *World J Surg Oncol*. 2015;13:64.
- [18] Blake P, Delicata R, Cross N, Sturgeon G, Hargest R. Large bowel obstruction due to colorectal carcinoma can be safely treated by colonic stent insertion--case series from a UK district general hospital. *Colorectal Dis*. 2012;14:1489-92.
- [19] White SI, Abdool SI, Frenkiel B, Braun WV. Management of malignant left-sided large bowel obstruction: a comparison between colonic stents and surgery. *ANZ J Surg*. 2011;81:257-60.
- [20] Zhang Y, Shi J, Shi B, Song CY, Xie WF, Chen YX. Self-expanding metallic stent as a bridge to surgery versus emergency surgery for obstructive colorectal cancer: a meta-analysis. *Surg Endosc*. 2012;26:110-19.
- [21] Ciocchi R, Farinella E, Trastulli S, Desiderio J, Listorti C, Boselli C, et al. Safety and efficacy of endoscopic colonic stenting as a bridge to surgery in the management of intestinal obstruction due to left colon and rectal cancer: a systematic review and meta-analysis. *Surg Oncol*. 2013;22:14-21.
- [22] Gorissen KJ, Tuynman JB, Fryer E, Wang L, Uberoi R, Jones OM, et al. Local recurrence after stenting for obstructing left-sided colonic cancer. *Br J Surg*. 2013;100:1805-09.
- [23] Zaharie F, Mocan L, Mocan T, Tomus C, Hodor V, Al Hajjar, et al. Surgical management of malignant large bowel obstructions]. *Chirurgia (Bucur)*. 2011;106:479-84.
- [24] Tohmé C1, Chakhtoura G, Abboud B, Noun R, Sarkis R, Ingea H, et al. Subtotal or total colectomy as surgical treatment of left-sided occlusive colon cancer. *J Med Liban*. 2008;56:198-202.
- [25] Käser SA, Glauser PM, Künzli B, Dolanc R, Bassotti G, Maurer CA. Subtotal colectomy for malignant left-sided colon obstruction is associated with a lower anastomotic leak rate than segmental colectomy. *Anticancer Res*. 2012;32:3501-05.
- [26] Shimura T, Joh T. Evidence-based Clinical Management of Acute Malignant Colorectal Obstruction. *Journal of Clin Gastroenterol*. 2016;50:273-85.
- [27] Gash K, Chambers W, Ghosh A, Dixon AR. The role of laparoscopic surgery for the management of acute large bowel obstruction. *Colorectal Dis*. 2011;13:263-66.
- [28] Frago R, Ramirez E, Millan M, Kreisler E, del Valle E, Biondo S. Current management of acute malignant large bowel obstruction: a systematic review. *Am J Surg*. 2014;207:127-38.
- [29] Juang D, Snyder CL. Neonatal bowel obstruction. *Surg Clin North Am*. 2012;92:685-711.
- [30] Mohiuddin SS, Gonzalez A, Corpron C. Meckel's diverticulum with small bowel obstruction presenting as appendicitis in a pediatric patient. *JLS*. 2011;15:558-61.
- [31] Lautz TB, Raval MV, Reynolds M, Barsness KA. Adhesive small bowel obstruction in children and adolescents: operative utilization and factors associated with bowel loss. *J Am Coll Surg*. 2011;212:855-61.
- [32] Sule AZ, Bada D, Nnamonu MI. Postoperative non-adhesive mechanical intestinal obstruction: a review of seven cases. *Niger J Med*. 2009;18:63-7. PMID:19485151

- [33] Duron JJ, Silva NJ, du Montcel ST, Berger A, Muscari F, Hennem H, et al. Adhesive postoperative small bowel obstruction: incidence and risk factors of recurrence after surgical treatment: a multicenter prospective study. *Ann Surg.* 2006;244:750-57.
- [34] Farid S, Iqbal A, Gechev Z. Re: Adhesive intestinal obstruction In laparoscopic versus open colorectal resection. *Colorectal Dis.* 2012;15.
- [35] Williams SB, Greenspon J, Young HA, Orkin BA. Small bowel obstruction: conservative vs. surgical management. *Dis Colon Rectum.* 2005;48:1140-46.
- [36] Moran JM, Salas J, Sanjuan S, Amaya JL, Rincon P, Serrano A, et al. Paramesocolic hernias: consequences of delayed diagnosis. Report of three new cases. *J Pediatr Surg.* 2004;39:112-16.
- [37] Brigham RA. Paraduodenal hernia. In: LM Nyhus, RE Condon 50(ed.) Hernia. 4th ed. Philadelphia: Lippincott Williams and Wilkins, 1995.
- [38] Pujahari AK, Rohit M. Two cases of Right para-duodenal hernia and review of literature. *Gastroenterology Report.* 2014;1-4.
- [39] Alemayehu H, David B, Desai AA, Iqbal CW, St Peter SD. Laparoscopy for small bowel obstruction in children--an update. *J Laparoendosc Adv Surg Tech A.* 2015;25:73-6.
- [40] Thibault R, Picot D. Chyme reinfusion or enteroclysis in nutrition of patients with temporary double enterostomy or enterocutaneous fistula. *Curr Opin Clin Nutr Metab Care.* 2016. [Epub ahead of print]
- [41] Pujahari AK. (chapter) postoperative ileus in Springer publication Edtr TK Chottopadhyaya's GI Surgery annual. 1999,6,26-33.
- [42] Zeinali F, Stulberg JJ, Conor P, Delaney, *Pharmacological management of postoperative ileus Can J Surg.* 2009;52: 153-57.
- [43] Krasil'nikov DM, Skobelkin OK, Fedorov VV, Tverskov SV, Zariipov NZ. [Early postoperative adhesion ileus] *Vestn Khir Im II Grek.* 1994;152:17-21 .
- [44] Bondarenko IN. Relaparotomy in the surgical treatment of early acute postoperative ileus. *Klin Khir.* 1997;(7-8): 19-21.
- [45] Dinstl K, Lechner G, Riedl P, Schiessel R. [Late results of The Noble operation. Clinical and radiological follow-up examination]. *MMW Munch Med Wochenschr.* 1976;118:29-30.
- [46] Holland-Cunz S, Boelter AV, Waag KL. Protective fibrin-sealed plication of the small bowel in recurrent laparotomy. *Pediatr Surg Int.* 2003;19:540-43.
- [47] Sclabas G, Heller G, Lüdín A, Odstroiclik E, Ammann J. Late results of Childs-Phillips mesenteric plication for therapy and prevention of small intestine ileus. *Chirurg.* 1997;68:693-99.
- [48] Li M, Ren J, Zhu W, Li Y, Zhao Y, Jiang J, et al. Retrograde long intestinal tube splinting: a safe and effective treatment for preventing recurrent adhesive small bowel obstruction. *Hepatogastroenterology.* 2014;61:1287-91.
- [49] Poehner D, Grethe L, Maegel L, Jonigk D, Lippmann T, Kaltenborn A, et al. Evaluation of the Effectiveness of Peritoneal Adhesion Prevention Devices in a Rat Model. *Int J Med Sci.* 2016;13:524-32. eCollection 2016.
- [50] Hindocha A, Beere L, Dias S, Watson A, Ahmad G. Adhesion prevention agents for gynaecological surgery: an overview of Cochrane reviews. *Cochrane Database Syst Rev.* 2015.
- [51] Sakari T, Sjödahl R, Pählman L, Karlborn U. Role of icodextrin in the prevention of small bowel obstruction. Safety randomized patients control of the first 300 in the ADEPT trial. *Colorectal Dis.* 2016;18:295-300.
- [52] Anantha RV, Salvadori MI, Hussein MH, Merritt N. Abdominal cocoon syndrome caused by *Mycobacterium bovis* from consumption of unpasteurised cow's milk. *Lancet Infect Dis.* 2015;15:1498.
- [53] Abid S, Arisar FA, Memon WA. Abdominal Cocoon: Primary Sclerosing Encapsulating Peritonitis. *Am J Gastroenterol.* 2016;111:923. doi: 10.1038/ajg.2016.72.
- [54] Di Saverio S, Catena F, Ansaloni L, Gavioli M, Valentino M, Pinna AD. Water-soluble contrast medium (gastrografin) value in adhesive small intestine obstruction (ASIO): a prospective, randomized, controlled, clinical trial. *World J Surg.* 2008;32:2293-304.
- [55] Branco BC, Bamparas G, Schnüriger B, Inaba K, Chan LS, Demetriades D. Systematic review and meta-analysis of the diagnostic and therapeutic role of water-soluble contrast agent in adhesive small bowel obstruction. *Br J Surg.* 2010;97:470-78.
- [56] Abbas S, Bissett IP, Parry BR. Oral water soluble contrast for the management of adhesive small bowel obstruction. *Cochrane Database Syst Rev.* 2007;18:CD004651.
- [57] Mooney SJ, Winner M, Hershman DL, Wright JD, Feingold DL, Allendorf JD, et al. Bowel obstruction in elderly ovarian cancer patients: a population-based study. *Gynecol Oncol.* 2013;129:107-12.
- [58] DeBernardo R. Surgical management of malignant bowel obstruction: strategies toward palliation of patients with advanced cancer. *Curr Oncol Rep.* 2009;11:287-92.
- [59] Leung AM, Vu H. Factors predicting need for and delay in surgery in small bowel obstruction. *Am Surg.* 2012;78:403-07.
- [60] Schraufnagel D, Rajaei S, Millham FH. How many sunsets? Timing of surgery in adhesive small bowel obstruction: a study of the nationwide inpatient sample. *J Trauma Acute Care Surg.* 2013;74:181-87; discussion 187-9.
- [61] Jones K, Mangram AJ, Lebron RA, Nadalo L, Dunn E. Can a computed tomography scoring system predict the need for surgery in small-bowel obstruction? *Am J Surg.* 2007;194:780-83; discussion 783-4.
- [62] Sakakibara T, Harada A, Yaguchi T, Koike M, Fujiwara M, Kodera Y, et al. The indicator for surgery in adhesive small bowel obstruction patient managed with long tube. *Hepatogastroenterology.* 2007;54:787-90.
- [63] Wilson MS, Ellis H, Menzies D, Moran BJ, Parker MC, Thompson JN. A review of the management of small bowel obstruction. Members of the Surgical and Clinical Adhesions Research Study (SCAR). *Ann R Coll Surg Engl.* 1999;81:320-28.
- [64] Li MZ, Lian L, Xiao LB, Wu WH, He YL, Song XM. Laparoscopic versus open adhesiolysis in patients with adhesive small bowel obstruction: a systematic review and meta-analysis. *Am J Surg.* 2012;204:779-86.
- [65] Qureshi I, Awad ZT. Predictors of failure of the laparoscopic approach for the management of small bowel obstruction. *Am Surg.* 2010;76:947-50.
- [66] Kirshtein B, Roy-Shapira A, Lantsberg L, Avinoach E, Mizrahi S. Laparoscopic management of acute small bowel obstruction. *Surg Endosc.* 2005;19:464-67.
- [67] Lee J, Tashjian DB, Moriarty KP. Surgical management of pediatric adhesive bowel obstruction. *J Laparoendosc Adv Surg Tech A.* 2012;22:917-20.
- [68] Okamoto H, Wakana H, Kawashima K, Fukasawa T, Fujii H. Clinical outcomes of laparoscopic adhesiolysis for mechanical small bowel obstruction. *Asian J Endosc Surg.* 2012;5:53-8.
- [69] Simmons JD, Rogers EA, Porter JM, Ahmed N. The role of laparoscopy in small bowel obstruction after previous laparotomy for trauma: an initial report. *Am Surg.* 2011;77:185-87.
- [70] Wang Q, Hu ZQ, Wang WJ, Zhang J, Wang Y, Ruan CP. Laparoscopic management of recurrent adhesive small-bowel obstruction: Long-term follow-up. *Surg Today.* 2009;39:493-99.
- [71] Tsumura H, Ichikawa T, Murakami Y, Sueda T. Laparoscopic adhesiolysis for recurrent postoperative small bowel obstruction. *Hepatogastroenterology.* 2004;51:1058-61.
- [72] Benze G, Geyer A, Alt-Epping B, Nauck F. Treatment of nausea and vomiting with 5HT3 receptor antagonists, steroids, antihistamines, anticholinergics, somatostatinantagonists, benzodiazepines and cannabinoids in palliative care patients: a systematic review. *Schmerz.* 2012;26:481-99.
- [73] Jeffrey B, Paula L, Lucan R. Medical Therapy of malignant bowel obstruction with Octreotide, Dexamethasone, and Metoclopramide. *Am J Hosp & Palliat care.* 2016.33:407-10.
- [74] Duron JJ, du Montcel ST, Berger A, Muscari F, Hennem H, Veyrieres M, et al. French federation for surgical research. Prevalence and risk factors of mortality and morbidity after operation for adhesive post-operative small bowel obstruction. *Am J Surg.* 2008;195:726-34.

PARTICULARS OF CONTRIBUTORS:

1. Professor, Department of Surgery and Surgical Gastroenterology, Vydehi Institute of Medical Sciences and Research Institute, Whitefield, Bangalore, India.

NAME, ADDRESS, E-MAIL ID OF THE CORRESPONDING AUTHOR:

Dr. Aswini Kumar Pujahari,
Department of Surgery, Vydehi Medical College, Whitefield, Bangalore-560066, India.
E-mail: akpuja@rediffmail.com

FINANCIAL OR OTHER COMPETING INTERESTS: None.

Date of Submission: **Jun 24, 2016**

Date of Peer Review: **Jul 19, 2016**

Date of Acceptance: **Sep 06, 2016**

Date of Publishing: **Nov 01, 2016**