

Randomized trial of calcipotriol combined with 5-fluorouracil for skin cancer precursor immunotherapy

Trevor J. Cunningham,^{1,2} Mary Tabacchi,² Jean-Pierre Eliane,³ Sara Moradi Tuchayi,¹ Sindhu Manivasagam,² Hengameh Mirzaalian,⁴ Ahu Turkoz,⁵ Raphael Kopan,⁵ Andras Schaffer,⁶ Arturo P. Saavedra,¹ Michael Wallendorf,⁷ Lynn A. Cornelius,² and Shadmehr Demehri^{1,2}

¹Center for Cancer Immunology and Cutaneous Biology Research Center, Department of Dermatology and Center for Cancer Research, Massachusetts General Hospital and Harvard Medical School, Boston, Massachusetts, USA. ²Division of Dermatology, Department of Medicine, Washington University School of Medicine, St. Louis, Missouri, USA. ³Department of Pathology, Massachusetts General Hospital and Harvard Medical School, Boston, Massachusetts, USA. ⁴Department of Radiology, Boston Children's Hospital and Harvard Medical School, Boston, Massachusetts, USA. ⁵Division of Developmental Biology, Cincinnati Children's Hospital Medical Center, Cincinnati, Ohio, USA. ⁶Department of Pathology and Immunology and ⁷Division of Biostatistics, Washington University School of Medicine, St. Louis, Missouri, USA.

BACKGROUND. Actinic keratosis is a precursor to cutaneous squamous cell carcinoma. Long treatment durations and severe side effects have limited the efficacy of current actinic keratosis treatments. Thymic stromal lymphopoietin (TSLP) is an epithelium-derived cytokine that induces a robust antitumor immunity in barrier-defective skin. Here, we investigated the efficacy of calcipotriol, a topical TSLP inducer, in combination with 5-fluorouracil (5-FU) as an immunotherapy for actinic keratosis.

METHODS. The mechanism of calcipotriol action against skin carcinogenesis was examined in genetically engineered mouse models. The efficacy and safety of 0.005% calcipotriol ointment combined with 5% 5-FU cream were compared with Vaseline plus 5-FU for the field treatment of actinic keratosis in a randomized, double-blind clinical trial involving 131 participants. The assigned treatment was self-applied to the entirety of the qualified anatomical sites (face, scalp, and upper extremities) twice daily for 4 consecutive days. The percentage of reduction in the number of actinic keratoses (primary outcome), local skin reactions, and immune activation parameters were assessed.

RESULTS. Calcipotriol suppressed skin cancer development in mice in a TSLP-dependent manner. Four-day application of calcipotriol plus 5-FU versus Vaseline plus 5-FU led to an 87.8% versus 26.3% mean reduction in the number of actinic keratoses in participants ($P < 0.0001$). Importantly, calcipotriol plus 5-FU treatment induced TSLP, HLA class II, and natural killer cell group 2D (NKG2D) ligand expression in the lesional keratinocytes associated with a marked CD4⁺ T cell infiltration, which peaked on days 10–11 after treatment, without pain, crusting, or ulceration.

CONCLUSION. Our findings demonstrate the synergistic effects of calcipotriol and 5-FU treatment in optimally activating a CD4⁺ T cell-mediated immunity against actinic keratoses and, potentially, cancers of the skin and other organs.

TRIAL REGISTRATION. ClinicalTrials.gov NCT02019355.

FUNDING. Not applicable (investigator-initiated clinical trial).

Introduction

Thymic stromal lymphopoietin (TSLP) has emerged as a potent inducer of antitumor immunity in barrier-defective skin, as it has the potential to significantly improve the treatment of skin cancers (1–3). TSLP is an epithelium-derived cytokine and a master regulator of allergic inflammation in the skin (4). We and others have demonstrated that TSLP released by barrier-defective skin in mice blocks cancer development by recruiting T cells to mount robust antitumor immunity in the skin (1–3). The adaptive immune response mounted by TSLP against cancer can eliminate cancerous lesions in the skin and prevent new lesions from developing

(1). These findings are consistent with epidemiological data suggesting that patients with allergic skin inflammation are protected from skin cancer (5–8). TSLP expression and its immune effects in the skin can be induced by calcipotriol (calcipotriene), an FDA-approved topical medication for psoriasis (9–11). To determine the efficacy of TSLP induction as a novel immunotherapeutic approach for cancer, we investigated the effect of calcipotriol on skin carcinogenesis in genetically engineered mouse models and in patients with actinic keratosis.

Premalignant lesions of cutaneous squamous cell carcinoma (SCC) are identified clinically as actinic keratoses (12, 13). Several field-directed treatments including 5-fluorouracil (5-FU), diclofenac, ingenol, and imiquimod have been approved for the treatment of sun-damaged skin with multiple actinic keratoses (13–15). However, the long treatment duration and the severity

Conflict of interest: The authors have declared that no conflict of interest exists.

Submitted: July 27, 2016; **Accepted:** October 6, 2016.

Reference information: *J Clin Invest.* 2017;127(1):106–116. doi:10.1172/JCI189820.

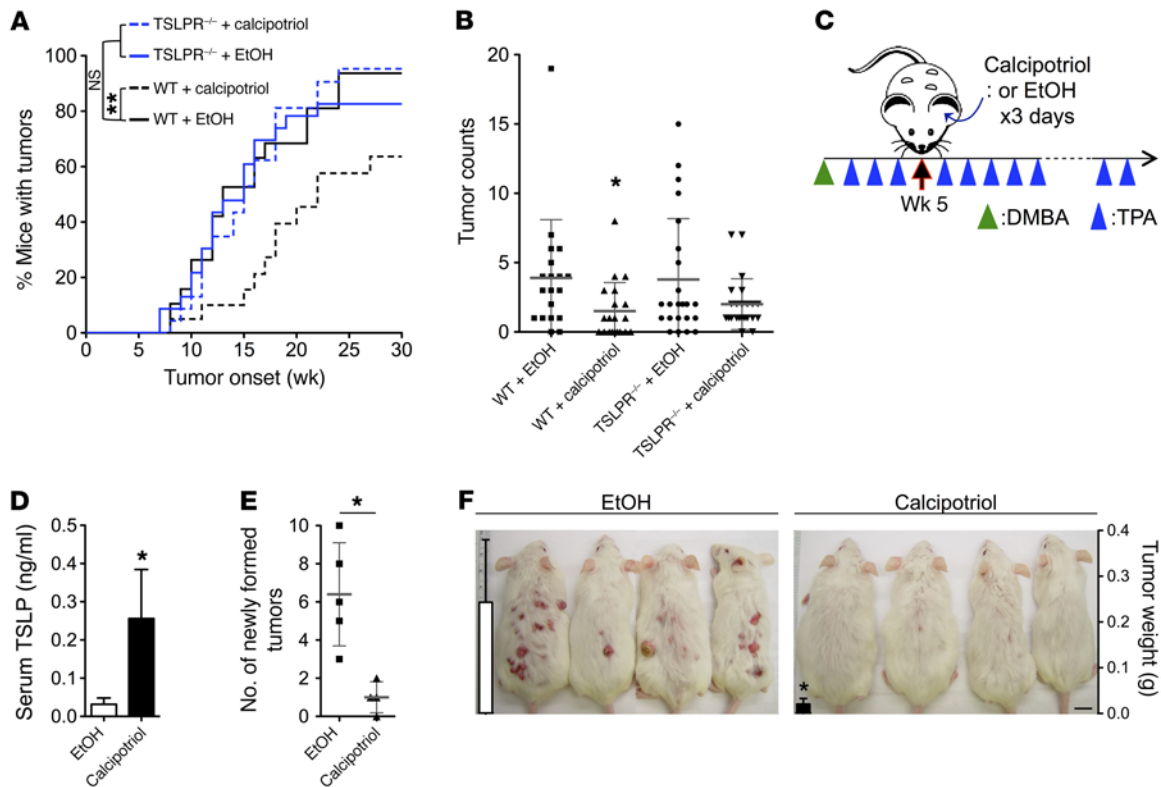


Figure 1. Mechanistic studies on the TSLP-dependent antitumor effect of calcipotriol against skin carcinogenesis. (A and B) WT (TSLPR^{+/+}) and TSLPR^{-/-} sex-matched littermates were treated with the standard DMBA-TPA skin carcinogenesis protocol. Animals received calcipotriol (80 nmol) or EtOH (carrier only) on the back skin 3 times per week during the 15-week TPA treatment period ($n \geq 19$ for each group). ** $P < 0.01$, by log-rank test (A) and * $P < 0.05$ versus the WT plus EtOH group, by Student's t test (B). (C) Scheme used to investigate the role of transient TSLP induction by calcipotriol in skin cancer development. Age- and sex-matched WT mice were treated on their back skin with the standard DMBA-TPA protocol. At the first sign of tumor development (week 5), the animals were randomized into 2 groups and received calcipotriol (80 nmol) or EtOH in their ears for 3 consecutive days. Thereafter, the animals continued to receive TPA biweekly and were analyzed at 15 weeks ($n \geq 4$ for each group). (D) Serum TSLP levels after 3 days of topical treatment with calcipotriol versus EtOH. * $P < 0.05$, by Student's t test. (E) Number of tumors developed on each mouse after calcipotriol/EtOH treatment. * $P < 0.05$, by Student's t test. (F) Representative pictures of the tumor-bearing mice and average weight of the 7 largest tumors in each group. Scale bar: 1 cm.

of the side effects associated with these topical treatments have limited patient compliance and, consequently, therapeutic efficacy. Considering that actinic keratoses constitute the third most common reason for consulting a dermatologist (12) and incur an annual cost of over \$900 million in the United States (16), the development of an effective treatment to eliminate actinic keratoses and prevent progression to skin cancer with fewer applications and side effects would have a major impact on healthcare.

Here, we investigated the effect of topical calcipotriol treatment on skin cancer development in mouse models of skin carcinogenesis. Using genetic engineering and innovative topical application paradigms in mice, we determined the mechanism of calcipotriol action against skin carcinogenesis. Next, we performed an investigator-initiated, randomized, double-blind clinical trial to determine the efficacy and safety of a combination of 0.005% calcipotriol ointment and 5% 5-FU cream compared with Vaseline (petroleum jelly) plus 5-FU for a 4-day treatment of actinic keratoses on the face, scalp, and upper extremities.

Results

Mechanism of calcipotriol's effect on skin cancer development. Previous studies have demonstrated that TSLP establishes a robust

antitumor immunity against skin cancer development (1–3). We examined the efficacy of topical TSLP induction by calcipotriol (9, 10, 17) in blocking skin cancer development in a standard chemical skin carcinogenesis model in mice (18). Three times weekly application of calcipotriol to the back skin during skin cancer induction led to TSLP expression ($P < 0.05$; Supplemental Figure 1A; supplemental material available online with this article; doi:10.1172/JCI89820DS1) and a significant delay in skin tumor development compared with EtOH (carrier) treatment in WT animals ($P < 0.01$; Figure 1A). In addition, significantly fewer tumors developed in the calcipotriol-treated mice ($P < 0.05$; Figure 1B), and the tumors that developed were significantly smaller than those of the EtOH-treated animals ($P < 0.01$; Supplemental Figure 1B). Of note, calcipotriol did not protect TSLP receptor-deficient (Tslpr-deficient, referred to herein as TSLPR^{-/-}) mice from skin cancer development (Figure 1, A and B, and Supplemental Figure 1). These results demonstrate that topical calcipotriol treatment blocks skin cancer development by inducing TSLP expression in the skin.

Impact of transient TSLP induction by calcipotriol on skin carcinogenesis. To determine the efficacy of a short TSLP-inductive regimen for skin cancer treatment, we devised an experimental

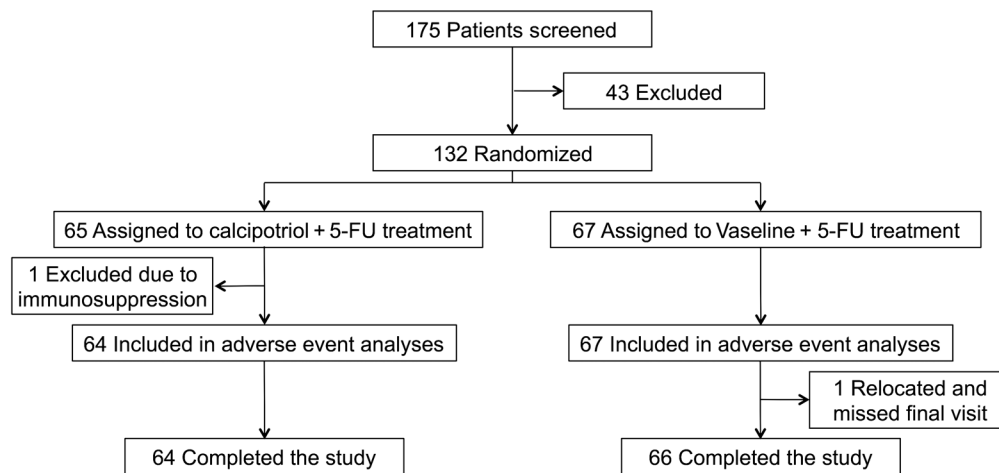


Figure 2. CONSORT diagram of the clinical trial. Flow chart shows the number of patients who were screened, randomized into the treatment groups, completed the study, and included in the final analysis.

paradigm in which calcipotriol was applied as a short pulse during the initial phase of tumor development in DMBA-TPA-treated (7,12-dimethylbenz[α]anthracene-12-*O*-tetradecanoylphorbol-13-acetate-treated) animals (Figure 1C). In this study, calcipotriol was applied to the animals' ears daily for 3 consecutive days at the time point when the first tumors started to appear on the back skin of the animals (Figure 1C). The short calcipotriol treatment regimen led to significantly elevated serum TSLP levels ($P < 0.05$; Figure 1D). The transient elevation in circulating TSLP levels led to a long-lasting antitumor effect in the animals' back skin as shown by a significant reduction in new tumor formation and the growth arrest among the remaining tumors in the calcipotriol-treated animals compared with the EtOH-treated controls ($P < 0.05$; Figure 1, E and F). This discovery highlights the potential of calcipotriol as an effective and safe topical agent for skin cancer immunotherapy and prevention.

Clinical trial. To determine the efficacy of TSLP induction as a cancer immunotherapeutic approach in humans, we focused on the use of topical calcipotriol for the treatment of actinic keratosis. Calcipotriol is a well-tolerated topical medication for psoriasis (19). However, the low concentration of calcipotriol in the clinically available formulation (0.005% ointment) dampened its effect against skin cancer development in mice (Supplemental Figure 2). In addition, 0.005% calcipotriol monotherapy has shown modest efficacy in actinic keratosis clearance after a 12-week application, accompanied by a lack of inflammation at the treatment sites, suggesting the absence of immune activation with 0.005% calcipotriol alone (20). Therefore, we hypothesized that combining 0.005% calcipotriol ointment with 5% 5-FU cream would heighten the immune-activating potential of calcipotriol. 5-FU is the standard of care for field treatment of actinic keratosis (21). As a monotherapy, 5-FU is used twice daily for 2 to 4 weeks in order to be effective (21); however, a shorter duration of 5-FU treatment may still induce the immunostimulatory signals (22) needed to fully activate the adaptive immune cells responding to a lower dose of calcipotriol. Hence, in a randomized, double-blind clinical trial, we examined the efficacy and safety of treatment with

0.005% calcipotriol ointment (final concentration, 0.0025%) in combination with 5% 5-FU cream (final concentration, 2.5%), twice daily for 4 days, as a novel immunotherapeutic regimen for actinic keratosis.

Study population. Patients with actinic keratosis who met the eligibility criteria were referred to the study from several clinical sites within our academic center. A total of 132 patients (of 175 screened) were enrolled and underwent randomization (Figure 2). Sixty-five participants were randomized to receive calcipotriol plus 5-FU; all completed the study, but 1 participant was excluded from the final analysis due to a recent diagnosis of immunosuppression. Sixty-seven participants were randomized to receive Vaseline plus 5-FU; 66 completed the study, but 1 relocated and missed the final clinical visit (Figure 2). All the participants completed the treatment course and underwent clinical evaluation before treatment (day 0), immediately after treatment (day 5), and 8 weeks after treatment (Supplemental Figure 3).

Demographics, skin type, clinical parameters, and amount of medication used per anatomical site were similar between the 2 groups (Table 1). All participants in the study had a history of cryotherapy. Nearly half of the participants also had a history of actinic keratosis field treatment in the past (Table 1). The median baseline number of actinic keratoses for all anatomical sites was 12 or more in both groups (Table 1).

Study outcomes. Topical calcipotriol plus 5-FU combination versus Vaseline plus 5-FU twice-daily treatment for 4 days led to a mean reduction in the number of actinic keratoses of 87.8% versus 26.3% on the face, 76.4% versus 5.7% on the scalp, 68.8% versus 9.6% on the right upper extremity (RUE), and 79% versus 16.3% on the left upper extremity (LUE) by week 8 ($P < 0.0001$ for all anatomical sites; Figure 3). Interestingly, the only participant who was excluded from the final analysis due to immunosuppression belonged to the calcipotriol plus 5-FU group and showed a 19% reduction in the number of actinic keratoses on his face after treatment (red circle; Figure 3). The greater efficacy of calcipotriol plus 5-FU versus Vaseline plus 5-FU treatment in eliminating actinic keratoses remained highly significant after controlling for the baseline actinic keratosis count, age, and sex of the

Table 1. Demographic and baseline clinical characteristics of the trial participants

	Calcipotriol + 5-FU (n = 64)	Vaseline + 5-FU (n = 67)	P value
Age, mean (SD), yr	69 (7)	70 (9)	0.42
Range	(51–88)	(52–89)	
Sex, n (%)			0.82
Male	51 (80)	55 (82)	
Female	13 (20)	12 (18)	
Drug amount used, mean (SD), g (per anatomical site)	7.06 (3.38)	7.72 (3.05)	0.24
Anatomical sites treated, n (%)			0.96
Face	45 (70)	50 (75)	
Scalp	34 (53)	34 (51)	
RUE	23 (36)	26 (39)	
LUE	32 (50)	31 (46)	
Baseline actinic keratosis count on each anatomical site, median (IQR)			
Face	16 (11)	15 (11)	0.085
Scalp	22.5 (17)	22.5 (17)	0.56
RUE	13 (12)	15.5 (19)	0.26
LUE	12 (11.5)	12 (23)	0.49
Skin type, n (%)			0.46
I	9 (14)	15 (22)	
II	46 (72)	43 (64)	
III	9 (14)	9 (14)	
History of actinic keratosis field treatment			
Field treatment, n (%)			0.26
Yes	33 (52)	28 (42)	
No	31 (48)	39 (58)	
5-FU, n			
1 time	12	12	0.82
>1 time	13	11	
PDT, n			
1 time	7	9	0.89
>1 time	12	13	
5-FU and PDT, n	11	17	0.25

IQR, interquartile range. Listed skin types refer to Fitzpatrick Skin Types.

participants ($P < 0.0001$ for all anatomical sites; Supplemental Figure 4). In addition, the anatomical site of the treatment did not impact the efficacy of calcipotriol plus 5-FU combination treatment in eliminating actinic keratoses (Supplemental Figure 5).

In the calcipotriol plus 5-FU group, 27% of participants had complete clearance of actinic keratoses on the face compared with 0% of participants in the Vaseline plus 5-FU group ($P < 0.0001$; Supplemental Figure 6). Participants in the calcipotriol plus 5-FU group had 80%, 56%, 30%, and 56% partial clearance of actinic keratoses on the face, scalp, RUE, and LUE, respectively, compared with 0%, 0%, 4%, and 3% of participants in the Vaseline plus 5-FU group ($P < 0.0001$ for face, scalp, and LUE; $P < 0.01$ for RUE; Supplemental Figure 6). All participants in the calcipotriol plus 5-FU group experienced a reduction in actinic keratosis counts on all their treated anatomical sites compared with 80%, 71%, 65%, and 77% on the face, scalp, RUE, and LUE, respectively, for participants in the Vaseline plus 5-FU group ($P < 0.01$ for all anatomical sites; Supplemental Figure 6).

Although the primary and secondary endpoints of the study were focused on the elimination of the actinic keratoses, participants with hypertrophic actinic keratoses in the calcipotriol plus 5-FU group experienced marked reductions in the size of their hypertrophic lesions after treatment (Supplemental Figure 7). Among the participants in the calcipotriol plus 5-FU group who had a previous history of actinic keratosis field treatment, 82% found the current treatment to be more effective than their previous treatments compared with 11% of participants in the Vaseline plus 5-FU group ($P < 0.0001$; Supplemental Table 1).

Skin reaction. The high efficacy of calcipotriol plus 5-FU treatment was associated with marked erythema centered around the actinic keratoses after treatment (day 5; Figure 4A). Grading the skin reaction using a clinical erythema scale (Supplemental Table 2) revealed a significantly higher erythema score among the participants in the calcipotriol plus 5-FU group compared with those in the Vaseline plus 5-FU group for all the anatomical sites by day 5 ($P < 0.0001$ for face and scalp, $P < 0.01$ for RUE and LUE; Figure 4B and Supplemental Table 3). The extent and intensity of the erythema on color-normalized images from day 5 (Supplemental Figure 8 and Supplemental Figure 9A) revealed a significantly greater extent and intensity of erythema on the face and scalp in the calcipotriol plus 5-FU-treated group compared with the Vaseline plus 5-FU-treated group, with the forehead scoring the highest (Supplemental Figure 9B). According to the participants' reporting at week 2, two distinct patterns of erythema resolution emerged: (a) worsening of the erythema after the end of the treatment, with its peak on days 10–11, accompanied by peeling of the affected skin before complete resolution (delayed pattern); and (b) a gradual resolution of erythema immediately after the end of the treatment (fast pattern; Supplemental Figure 10). Ninety-one percent of the participants in the calcipotriol plus 5-FU treatment group reported a delayed pattern of erythema resolution, while only 6% of the participants in the Vaseline plus 5-FU treatment group experienced delayed resolution of their skin erythema ($P < 0.0001$; Table 2). The only participant in the calcipotriol plus 5-FU group who did not show any erythema on the face on day 5 (erythema score = 0) went on to develop significant erythema with exfoliation by day 11 (Supplemental Figure 11). All skin reactions, including the severe cases of erythema in the calcipotriol plus 5-FU group, resolved around week 2 after the treatment (Supplemental Figures 11 and 12).

Adverse events. Consistent with the clinical erythema scores on day 5, a significantly higher percentage of the participants in the calcipotriol plus 5-FU group reported skin redness during the treatment period ($P < 0.0001$; Table 2). In addition, 39% of the participants in the calcipotriol plus 5-FU group experienced a burning sensation on the treated skin compared with 13% of the participants in the Vaseline plus 5-FU group ($P < 0.001$; Table 2). A similar percentage of participants in both groups reported scaling and itching of the treated skin during the 4-day treatment period (Table 2). No crusting or wounding was observed on the skin of the study participants, whereas such morbidities are common in response to 2 to 4 weeks of 5-FU cream treatment (Supplemental Figure 13) (21). No pain, scarring, oozing, vesiculation, pustulation, pigmentary changes, or

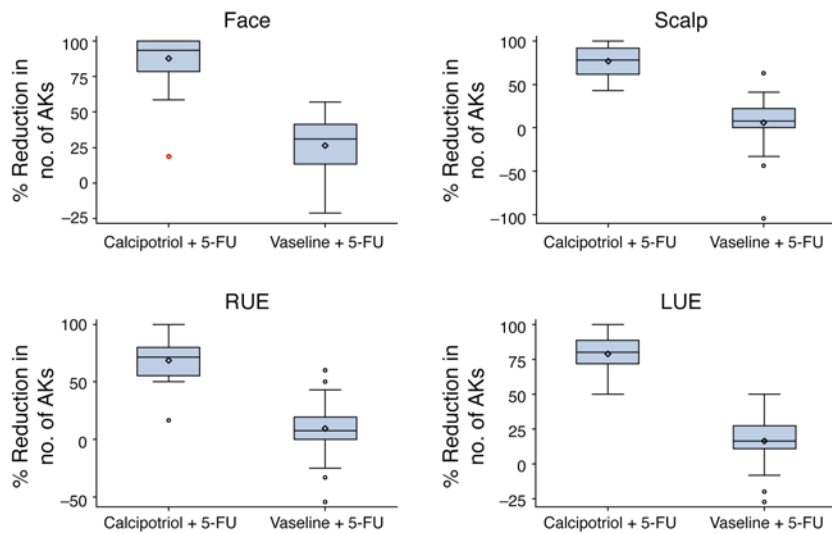


Figure 3. Reduction in the number of actinic keratoses by week 8 after treatment. Box-and-whisker plots demonstrate twice-daily application of calcipotriol plus 5-FU versus Vaseline plus 5-FU for 4 days efficacy in eliminating actinic keratoses (AKs) on the face, scalp, RUE, and LUE. *P* values were determined by Student's *t* test. The percentage of reduction in the number of actinic keratoses for the participant who was excluded from the analysis due to immunosuppression is shown as a red circle on the face plot.

skin infection was detected in the study participants. None of the study participants reported any systemic side effects.

Calcipotriol plus 5-FU induction of CD4⁺ T cell immunity against actinic keratosis. The severe erythema caused by calcipotriol plus 5-FU treatment was associated with a massive accumulation of lymphocytes at the sites of actinic keratosis and evidence of immune-mediated tumor rejection including lymphocyte exocytosis, epidermal spongiosis, and dyskeratosis (Figure 5A and Supplemental Figure 14). The majority of the lymphocytes infiltrating the lesions were CD4⁺ T cells, with a much smaller population of CD8⁺ T cells present (Figure 5A and Supplemental Figures 14 and 15). The lymphoid infiltrate largely lacked B cells, NK cells, neutrophils, mast cells, and eosinophils (Figure 5A and Supplemental Figure 15). Evaluation of the biopsied specimens before and after treatment by a dermatopathologist blinded to the treatment groups proved the histological evidence of actinic keratosis in the specimens and revealed that 6 of 21 lesions in the calcipotriol plus 5-FU group showed a severe lesional epidermis rejection pattern following treatment that was absent (0 of 20) in the Vaseline plus 5-FU group (*P* = 0.03; Figure 5B and Supplemental Table 4). The inflammation in the calcipotriol plus 5-FU-treated actinic keratoses was notable for specifically targeting the sites of actinic damage, without involving the histologically normal adjacent epidermis. The mild-to-moderate inflammation found in a subgroup of actinic keratoses in the Vaseline plus 5-FU group was indistinguishable from the baseline immune infiltrate present in the untreated actinic keratoses (*P* = 0.4; Supplemental Table 4D).

TSLP, HLA class II, and cellular stress signal synergism in mediating the immunotherapeutic effects of calcipotriol plus 5-FU against actinic keratosis. Calcipotriol plus 5-FU treatment induced TSLP expression in actinic keratosis keratinocytes (Figure 6A and Supplemental Figure 15) (11). Evaluation of TSLP protein levels across biopsy specimens in a blinded manner revealed that lesional keratinocytes in the calcipotriol plus 5-FU group had significantly higher TSLP expression levels than did those in the Vaseline plus 5-FU group (*P* < 0.0001, Supplemental Table 5). A large number of HLA-DP-DQ-DR⁺ antigen-presenting

cells were present together with CD4⁺ T cells in calcipotriol plus 5-FU-treated lesions, including HAM-56⁺CD11c⁻ dermal macrophages (Figure 6A and Supplemental Figure 15). HLA class II expression was also detectable on lesional keratinocytes, indicative of an immune rejection of actinic keratoses in the calcipotriol plus 5-FU group (Figure 6A and Supplemental Figure 16). Among chemotherapy-induced damage-associated molecular pattern molecules (HMGB1, S100A8 and S100A9, and IL1B) (23), cellular DNA damage sensors (IFNB1, MX1, and CXCL10) and surface stress signals (MICA, MICB, and ULBP1, -2, -3), the natural killer cell group 2D (NKG2D) ligand MICB was found to be significantly upregulated in actinic keratoses after calcipotriol plus 5-FU treatment (*P* = 0.0016, paired Student's *t* test; Figure 6B and Supplemental Figure 17).

Discussion

Actinic keratoses represent an early stage of the malignant transformation of keratinocytes, which harbor oncogenic driver mutations and can progress to SCC (24). We believe our findings establish calcipotriol plus 5-FU combination as a novel immunotherapeutic agent for the treatment of actinic keratoses that has a great potential to prevent skin cancer development. Our mechanistic studies using murine models of skin carcinogenesis revealed that topical calcipotriol treatment blocks skin cancer development by inducing TSLP expression in the skin. The long-lasting skin cancer suppression observed in the back skin of the animals treated with a short course of calcipotriol in the ear demonstrates the role of circulating TSLP and immune memory response in mediating this antitumor effect. Consistent with the dominant role of CD4⁺ T cells in mediating TSLP-induced antitumor immunity (1, 2, 25), calcipotriol plus 5-FU treatment resulted in a specific induction of CD4⁺ T cell immune response against actinic keratoses, which is distinct from the CD8⁺ T cell immunity commonly studied in the context of metastatic cancers. The low actinic keratoses clearance in the immunosuppressed participant excluded from the calcipotriol plus 5-FU group supports the role of an intact immune response in mediating the therapeutic effect of calcipotriol plus 5-FU treatment.

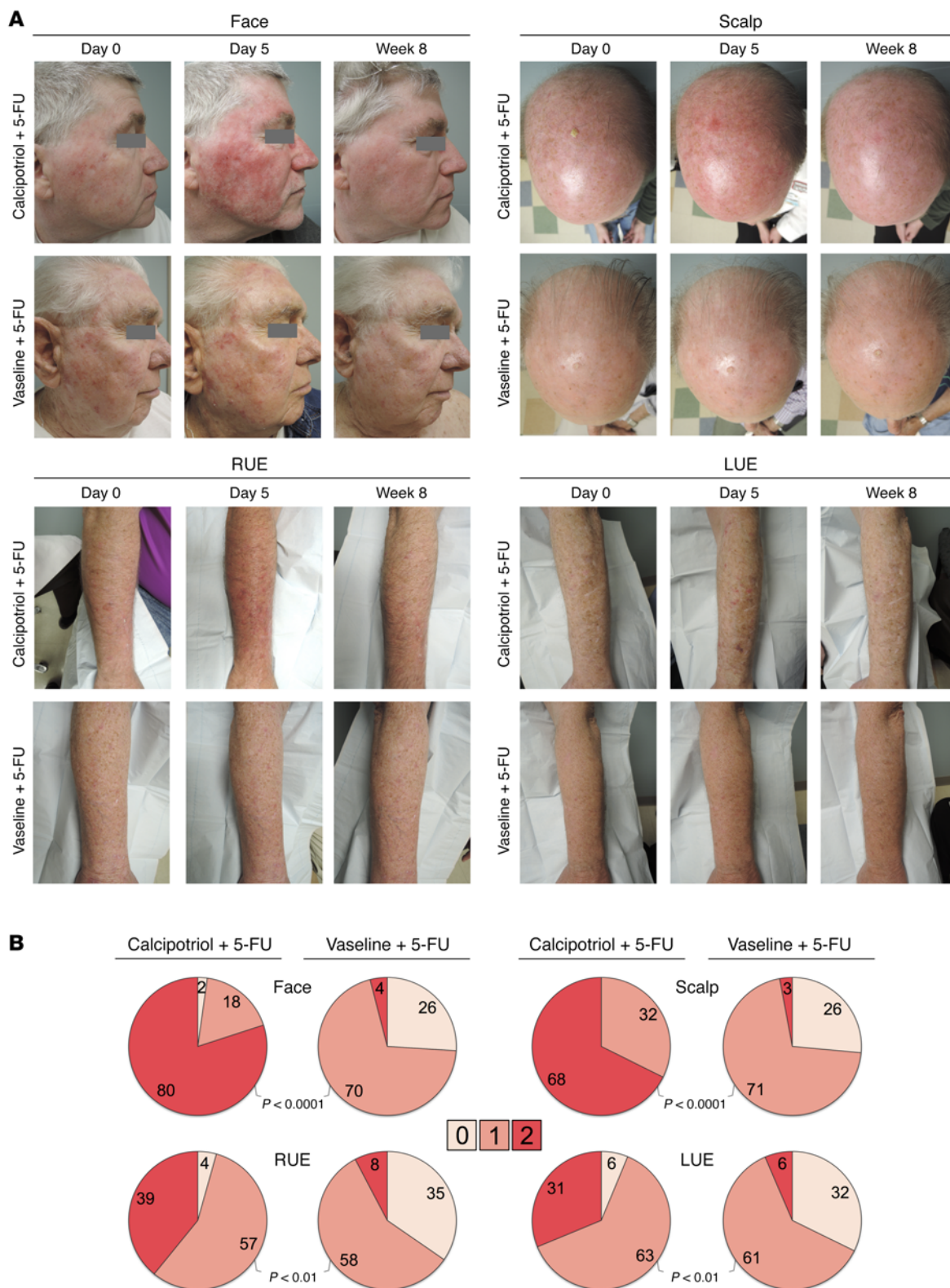


Figure 4. Photographs and clinical evaluation of skin reactions. (A) Representative photographs of the 4 anatomical sites treated with calcipotriol plus 5-FU versus Vaseline plus 5-FU. Photographs are of 8 participants before (day 0) and after treatment (day 5 and week 8). (B) Pie charts demonstrate the percentage of distribution of the participants' erythema scores (defined in Supplemental Table 2) for the 4 treated anatomical sites in the calcipotriol plus 5-FU and Vaseline plus 5-FU groups immediately after treatment (day 5). P values were determined by Fisher's exact test.

Table 2. Adverse events

	Calcipotriol + 5-FU (n = 64)	Vaseline + 5-FU (n = 67)	P value
Participant self-reporting			
[During 4-day treatment period]			
Skin redness, n (%)	44 (69)	17 (25)	< 0.0001
Redness onset, n (%)			
Day 1	3 (7)	1 (6)	0.89
Day 2	10 (23)	4 (24)	
Day 3	17 (39)	5 (29)	
Day 4	14 (32)	7 (41)	
Skin scaling, n (%)	9 (14)	5 (7)	0.22
Skin itching sensation, n (%)	16 (25)	15 (22)	0.73
Skin burning sensation, n (%)	25 (39)	9 (13)	0.0008
[After treatment]			
Erythema resolution pattern ^a			<0.0001
D (delayed)	58 (91)	4 (6)	
F (fast)	6 (9)	63 (94)	

^aDefined in Supplemental Table 10.

The quick appearance of inflammation and its delayed peak in the calcipotriol plus 5-FU group suggest that both the activation of tissue-resident T cells (26) and the recruitment of naive circulating T cells contributed to the observed antitumor immune response. The extent of the inflammation on the forehead and temples of the calcipotriol plus 5-FU-treated participants suggests an extension of T cell immunity against highly mutated but normal-appearing skin on chronically sun-damaged skin (27). The immune response induced by calcipotriol plus 5-FU against actinic keratoses resembled skin allograft rejection (28), accompanied by HLA class II and MICB expression on the malignant keratinocytes. HLA class II expression by lesional keratinocytes signifies their role as antigen-presenting cells in the context of the adaptive immune response induced by calcipotriol plus 5-FU treatment (29) and provides evidence that CD4⁺ T cells infiltrating the actinic keratoses can directly target these malignant keratinocytes. Notably, NKG2D ligand induction on keratinocytes by calcipotriol plus 5-FU treatment has been shown to synergize with TSLP to suppress skin cancer development (3, 30). This synergism can explain the high efficacy of a 4-day calcipotriol plus 5-FU treatment against actinic keratoses compared with 5-FU treatment alone.

The short treatment duration and minimal side-effect profile highlight the advantages of calcipotriol plus 5-FU combination as an optimal treatment for patients with actinic keratosis compared with the currently approved treatments. Twice-daily application of 5% 5-FU cream for 4 weeks was found to reduce the number of actinic keratoses on the face and ears by 73% compared with 24% in the vehicle-treated group (31). The mean baseline number of actinic keratoses in this study was 11.1 in the 5-FU-treated group versus 10.7 in the vehicle-treated group (31). Imiquimod is a TLR7 agonist used for actinic keratosis treatment (32, 33). Unlike the direct effect of calcipotriol plus 5-FU treatment on adaptive immunity, the innate immune activation by imiquimod lacks tumor specificity. Imiquimod (3.75%) treatment once daily for two 3-week treatment cycles led to an 80% median reduction in actinic keratosis counts on the face and scalp compared with

23.6% in the placebo group (32). Median baseline lesion counts in this trial were 9–10 (32). Diclofenac is another topical treatment for actinic keratosis. Treatment with 3% diclofenac in 2.5% hyaluronan gel twice daily for 60 days led to a 54% to 64% reduction in actinic keratosis counts on the face, scalp, and dorsal hands compared with 23% to 34% in the placebo group 30 days after treatment (34). Mean baseline actinic keratosis numbers were 7 and 7.4 for the diclofenac and placebo groups, respectively (34). The most recently approved topical treatment for actinic keratosis is ingenol mebutate. Application of ingenol once daily to only 25-cm² contiguous areas on the face or scalp (0.015% for 3 days) and to the trunk or extremities (0.05% for 2 days) led to an 83% and 75% median reduction, respectively, in the number of actinic keratoses by day 57 after treatment (35). Baseline actinic keratosis counts in this study were less than 9 on the treated sites (35). Given the exceptionally high baseline numbers of actinic keratoses in our trial (median baseline counts in the calcipotriol plus 5-FU group: 16 [face], 22.5 [scalp], 13 [RUE], and 12 [LUE]; Table 1), together with the inclusion of hypertrophic actinic keratoses, calcipotriol plus 5-FU treatment for 4 days appears to be more effective than the currently approved topical field treatments for actinic keratoses. Nonetheless, future head-to-head clinical trials are required to fully address the efficacy of calcipotriol plus 5-FU combination compared with current treatment regimens. To address this and in order to make calcipotriol plus 5-FU combination accessible to a large number of patients with actinic keratosis, the development of this combination of agents into a single topical product is essential.

The ultimate objective in treating actinic keratosis is to prevent the development of skin cancer. Although the approved cytotoxic therapies for actinic keratosis have shown long-term benefit in reducing actinic keratosis counts (31), their impact on preventing new SCC development remains uncertain. Importantly, as an inducer of T cell-mediated immunity against actinic keratosis, calcipotriol plus 5-FU combination may have a unique potential to establish an antitumor immune memory in the skin, which is maintained by skin-resident T cells (26) and is capable of preventing skin cancer development in the long term. In fact, the effective skin cancer suppression in mice long after a brief course of calcipotriol treatment in their ears strongly suggests that TSLP induction can establish a lasting antitumor immune memory response in the skin. A limitation of the current study is its focus on actinic keratosis clearance and lack of data on skin cancer prevention in the study population. This limitation will be addressed in follow-up studies. In addition, the current study focused on the clearance of lesions on each anatomical site; however, reductions in the size and severity of large and hypertrophic actinic keratoses are important therapeutic parameters that will also be examined in follow-up studies. The expression of TSLP, HLA class II, and NKG2D ligand by lesional keratinocytes and the massive infiltration of CD4⁺ T cells into the precancerous skin lesions provide a mechanistic insight into the therapeutic effect of calcipotriol plus 5-FU combination. Understanding the precise characteristics of the tumor-infiltrating CD4⁺ T cells, the nature of the tumor antigens, and the effector mechanism that results in such a high tumor clearance rate remain active areas of our research. In summary, we believe

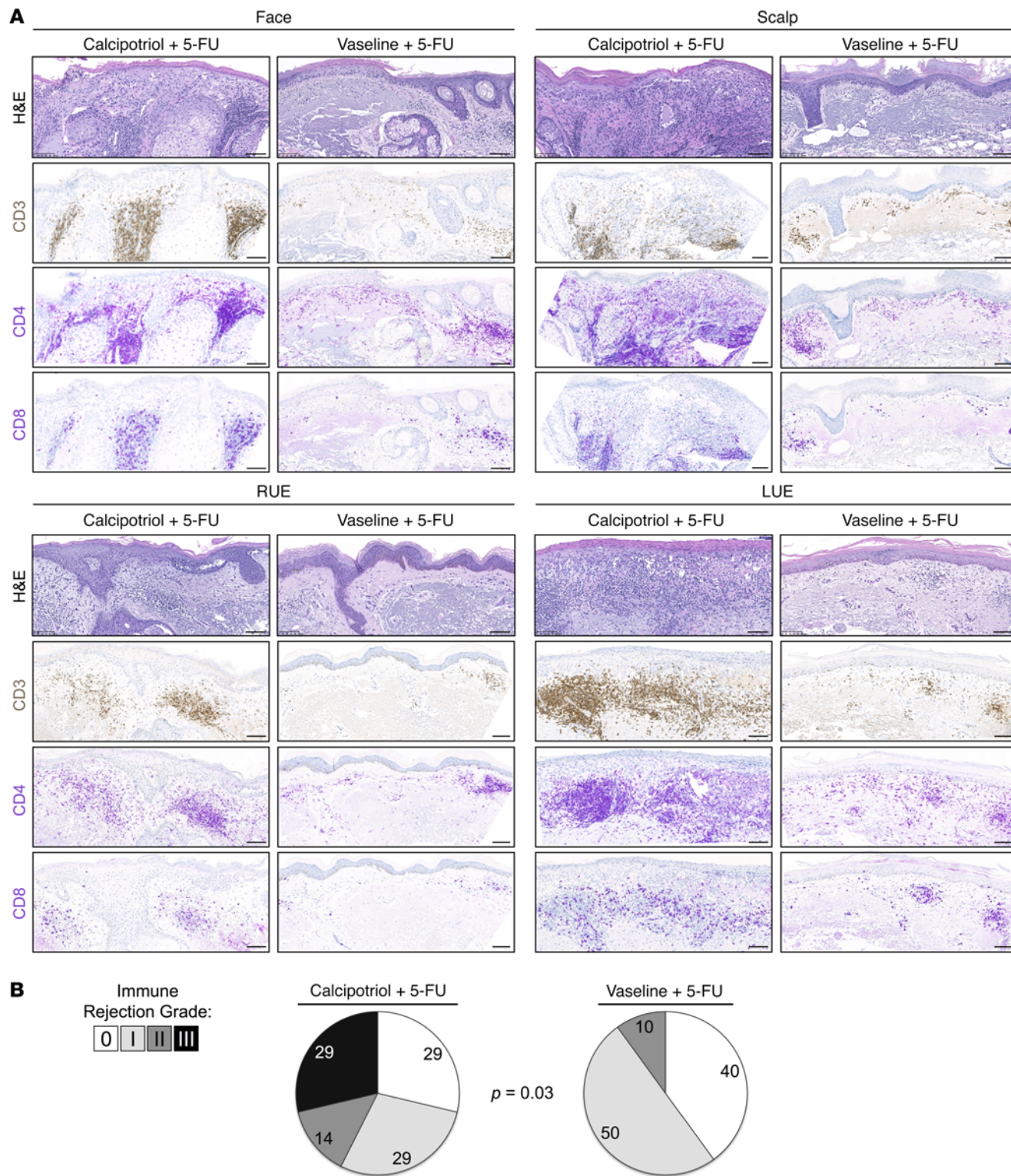


Figure 5. Therapy-induced histological changes in actinic keratosis. (A) Histological images of the actinic keratoses after treatment (day 5) demonstrate the magnitude of actinic keratosis inflammation, including CD4⁺ and CD8⁺ T cell infiltration into the lesions in the calcipotriol plus 5-FU versus Vaseline plus 5-FU groups. Note the degree of dermal and epidermal immune infiltrate and epidermal spongiosis and dyskeratosis present in the H&E-stained images. Tissue staining was performed on adjacent sections, and representative images of actinic keratoses on all 4 anatomical sites are shown. (B) Pie charts show the percentage of distribution of the immune-mediated actinic keratosis rejection grades (defined in Supplemental Table 4) in the calcipotriol plus 5-FU ($n = 21$) and Vaseline plus 5-FU ($n = 20$) groups after treatment (day 5). The significant difference between the 2 treatment groups was independent of the anatomical site of the actinic keratoses. P value was determined by type III test of means in a mixed random effects ANOVA.

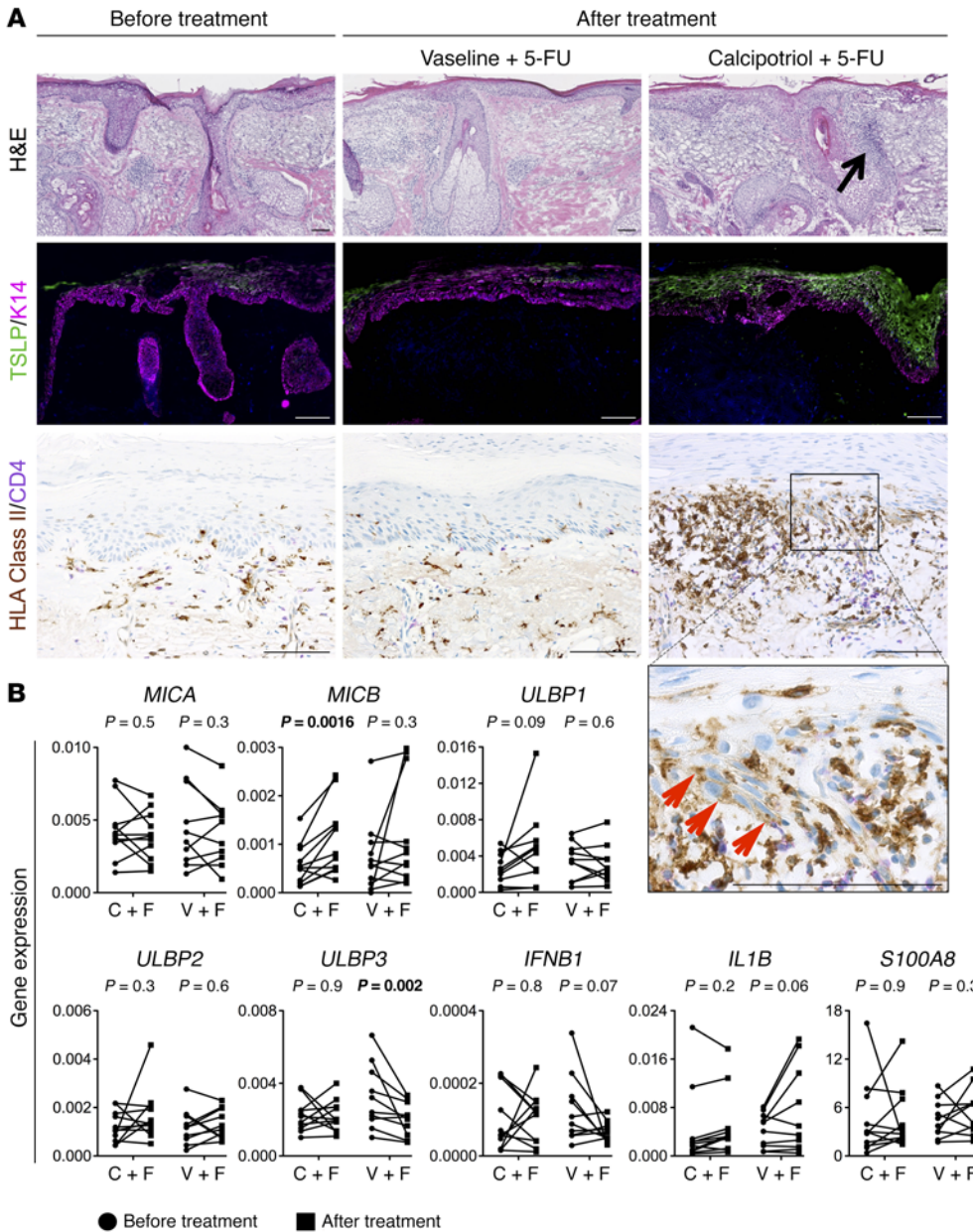


Figure 6. Induction of TSLP, HLA class II, and NKG2D ligand in response to calcipotriol plus 5-FU combination therapy. (A) Representative images of actinic keratoses stained with H&E, TSLP and keratin 14 (K14), and HLA DP/DQ/DR (class II) and CD4, before and after treatment. K14 staining marks the proliferative keratinocytes of actinic keratoses. Black arrow points to the site's lymphocytic aggregate at the epidermal-dermal junction, and red arrows point to lesional keratinocytes that expressed HLA class II in the calcipotriol plus 5-FU-treated actinic keratoses. (B) Graphs demonstrate the expression of the cellular stress genes relative to *GAPDH* in actinic keratoses before and after treatment with calcipotriol plus 5-FU (C+F, $n = 11$) or Vaseline plus 5-FU (V+F, $n = 10$). P values are shown in each graph and were determined by paired Student's t test. Note that the gene expression analysis was performed on actinic keratosis biopsies that were obtained before and after treatment from the same anatomical site on the face or scalp from each participant. Scale bars: 100 μ m.

that the combined results from our mechanistic studies in animal models of skin carcinogenesis and our randomized, double-blind clinical trial in patients with multiple actinic keratoses establish calcipotriol plus 5-FU combination as a highly effective immunotherapeutic regimen for the treatment of actinic keratosis, with potential implications for the treatment of cancers of the skin and perhaps other organs.

Methods

Animal studies. For skin cancer induction, the back skin of the animals was treated with a single dose of DMBA (50 μ g DMBA; Sigma-Aldrich), followed by a twice-weekly application of TPA (6 μ g; Sigma-Aldrich) for 15 weeks. Animals were randomized into treatment and control groups, and the investigators monitoring skin tumor development were blinded to the treatment groups. Refer to the Supplemental Material for a further description of the experimental procedures.

Clinical study design. In this randomized, double-blind study, participants with actinic keratoses on the face, scalp, RUE, and/or LUE were randomly assigned to a regimen of twice-daily self-application of topical calcipotriol plus 5-FU (test group) or Vaseline (petroleum jelly, vehicle; Fougera) plus 5-FU (control group) treatment for 4 days. Actinic keratoses were clinically defined as pink, scaly papules on sun-damaged skin. A 4-day treatment duration was chosen, because 5-FU monotherapy has minimal impact on actinic keratosis clearance after 4 days (21). The drug combinations were prepared by mixing 0.005% calcipotriol ointment (Taro Pharmaceuticals) with 5% 5-FU cream (Taro Pharmaceuticals) or Vaseline with 5% 5-FU cream at a 1:1 weight ratio in accordance with United States Pharmacopeial Convention 795 (USP 795) guidelines for compounding topical medications and under the supervision of the investigational drug pharmacies of Washington University and Massachusetts General Hospital.

The trial was conducted at Washington University Medical Center between October 2013 and March 2015. Inclusion criteria included age of at least 50 years and presence of 4 to 15 clinically visible and discrete actinic keratoses in a 25-cm² contiguous area on any of the 4 anatomical sites. Exclusion criteria included immunosuppression and a recent (within 1 month) use of medications that could hinder assessment of the treated skin (Supplemental Figure 3A). If a participant had 2 or more qualified anatomical sites, 1 was selected as the primary anatomical site solely for the purpose of randomization. At the initial visit (day 0), the number and anatomical location of actinic keratoses were documented and photographed, and the patient was assigned to a study medication on the basis of the randomization schedule corresponding to the participant's primary anatomical site of treatment. Participants applied the study medication to the entirety of their qualified anatomical sites twice daily for 4 consecutive days, starting the day after their first visit. Participants underwent evaluation on day 5 and at weeks 2, 4, and 8 (Supplemental Figure 3B). Optional skin biopsies were obtained before (day 0) and after treatment (day 5). Biopsies were performed on a randomly selected lesion among the actinic keratoses of each participant. The dermatologist assessing the actinic keratoses and performing the biopsies was blinded to the treatment groups.

Clinical study assessment. The primary endpoint for the study was the percentage of change from baseline of the total number of actinic keratoses by week 8 at each anatomical site (face, scalp, RUE, and LUE). The secondary endpoints were the complete and partial (>75%) clearance of actinic keratoses by 8 weeks and the evaluation of the differences in response to the treatment among the 4 anatomical sites by week 8 after treatment. The clinical assessment of the primary and secondary endpoints was performed by a single dermatologist in order to avoid any interobserver variation in assessments. Adverse event reporting included participants' self-reported side effects of erythema, scaling, burning, and pruritus during the 4-day treatment period, which were documented on a standard diary form. In addition, skin reactions were assessed, photographed, and scored clinically on day 5 using an erythema scale (Supplemental Table 2). Participants were also surveyed after treatment for other skin or systemic reactions including infection, pain, scarring, pigmentary changes, fever, headache, and eye symptoms on day 5 and weeks 2, 4, and 8. Refer to the Supplemental Material for a detailed description of the tissue analysis.

Statistics. All clinical study analyses were performed using SAS 9.4 (SAS Institute) for 2-sample Student's *t* tests, Pearson's χ^2 tests, Fisher's exact test on proportions in contingency tables, McNemar's test for marginal proportions on paired categorical data, and Spearman's correlation. For the percentage of relative reduction, we used a mixed random-effects model on location, drug, and location by drug interaction as fixed effects, and subject within drug and location by subject interaction as random effects. All error bars represent the mean \pm SD. A *P* value of less than 0.05 was considered significant.

Randomization was performed according to 4 primary anatomical sites: face, scalp, RUE, and LUE in order to capture an adequate

number of treatments for all 4 anatomical sites and to account for site-specific differences. Participants were assigned treatment with calcipotriol plus 5-FU or Vaseline plus 5-FU at a 1:1 ratio. Upon recruitment, each participant received the next available treatment from the random assignment schedule for his or her primary anatomical site; this treatment was applied to all of the qualified anatomical sites. This schedule was created in blocks of 10, with random ordering of treatments using random numbers generated in SAS 9.3.

Study approval. All the animal experiments were performed in accordance with the IACUCs of Washington University and Massachusetts General Hospital in pathogen-free facilities. The clinical study protocol was approved by the academic IRBs of Washington University and Massachusetts General Hospital. All participants provided written informed consent to participate in the study. All participants agreed to having their treatment areas photographed, and written informed consent was provided for pictures appearing in this article. Written informed consent was obtained from those participants who opted to undergo biopsy procedures. The study was conceived, designed, initiated and performed by the academic investigators. The authors confirm the accuracy and completeness of the data and analysis and the fidelity of the study to the protocol. All the authors agreed to submit the article for publication.

Author contributions

SD conceived and designed the clinical trial. SD, TJC, SMT, SM, AT, and RK designed and performed the preclinical experiments. SD, MT, and LAC conducted the clinical trial and handled the related data collection. SD, LAC, and TJC interpreted the data and wrote the manuscript. SMT, JPE, HM, AS, and APS contributed to the analysis of the experimental and clinical data. MW performed the statistical analyses.

Acknowledgments

We thank Caroline Mann, Milan Anadkat, Amy Musiek, Ian Hornstra, David Sheinbein, Guadalupe Sanches, Laurin Council, and Eva Hurst at Washington University for referring patients to this study. We thank Ethan Lerner, David Fisher, Barbara Gilcrest, Nir Hacohen, and Keith Flaherty (Massachusetts General Hospital, Boston, MA, USA) for critically reading the manuscript. We also thank Warren Leonard (NIH, Bethesda, MD, USA) for the TSLPR^{-/-} mice. SD and TJC were supported by grants from the American Skin Association, the Dermatology Foundation, the Burroughs Wellcome Fund, the American Philosophical Society, the La Roche-Posay Research Foundation, and the NIH (1DP5OD021353). RK, AT, and SM were supported by NIH grant RO1GM055479 (to RK).

Address correspondence to: Shadmehr Demehri, Department of Dermatology and MGH Cancer Center, Building 149 13th Street, 3rd floor, Charlestown, Massachusetts 02129, USA. Phone: 617.643.6436; E-mail: sdemehri1@mgh.harvard.edu.

1. Demehri S, Turkoz A, Manivasagam S, Yockey LJ, Turkoz M, Kopan R. Elevated epidermal thymic stromal lymphopoietin levels establish an antitumor environment in the skin. *Cancer Cell*. 2012;22(4):494-505.

2. Di Piazza M, Nowell CS, Koch U, Durham AD, Radtke F. Loss of cutaneous TSLP-dependent immune responses skews the balance of inflammation from tumor protective to tumor promoting. *Cancer Cell*. 2012;22(4):479-493.

3. Cipolat S, Hoste E, Natsuga K, Quist SR, Watt FM. Epidermal barrier defects link atopic dermatitis with altered skin cancer susceptibility. *Elife*. 2014;3:e01888.

4. Ziegler SF, Artis D. Sensing the outside world:

- TSLP regulates barrier immunity. *Nat Immunol*. 2010;11(4):289–293.
5. Wang H, Diepgen TL. Atopic dermatitis and cancer risk. *Br J Dermatol*. 2006;154(2):205–210.
 6. Wang H, Diepgen TL. Is atopy a protective or a risk factor for cancer? A review of epidemiological studies. *Allergy*. 2005;60(9):1098–1111.
 7. Van Hemelrijck M, et al. Immunoglobulin E and cancer: a meta-analysis and a large Swedish cohort study. *Cancer Causes Control*. 2010;21(10):1657–1667.
 8. Hwang CY, et al. Cancer risk in patients with allergic rhinitis, asthma and atopic dermatitis: a nationwide cohort study in Taiwan. *Int J Cancer*. 2012;130(5):1160–1167.
 9. Li M, Hener P, Zhang Z, Kato S, Metzger D, Chambon P. Topical vitamin D3 and low-calceic analogs induce thymic stromal lymphopoietin in mouse keratinocytes and trigger an atopic dermatitis. *Proc Natl Acad Sci U S A*. 2006;103(31):11736–11741.
 10. Li M, Hener P, Zhang Z, Ganti KP, Metzger D, Chambon P. Induction of thymic stromal lymphopoietin expression in keratinocytes is necessary for generating an atopic dermatitis upon application of the active vitamin D3 analogue MC903 on mouse skin. *J Invest Dermatol*. 2009;129(2):498–502.
 11. Sato-Deguchi E, Imafuku S, Chou B, Ishii K, Hiromatsu K, Nakayama J. Topical vitamin D(3) analogues induce thymic stromal lymphopoietin and cathelicidin in psoriatic skin lesions. *Br J Dermatol*. 2012;167(1):77–84.
 12. Salasche SJ. Epidemiology of actinic keratoses and squamous cell carcinoma. *J Am Acad Dermatol*. 2000;42(1 Pt 2):4–7.
 13. Fenske NA, Spencer J, Adam F. Actinic keratoses: past, present and future. *J Drugs Dermatol*. 2010;9(5 Suppl ODAC Conf Pt 1):s45–s49.
 14. Stockfleth E, et al. Development of a treatment algorithm for actinic keratoses: a European Consensus. *Eur J Dermatol*. 2008;18(6):651–659.
 15. Stockfleth E, et al. Physician perceptions and experience of current treatment in actinic keratosis. *J Eur Acad Dermatol Venereol*. 2015;29(2):298–306.
 16. Warino L, Tusa M, Camacho F, Teuschler H, Fleischer AB, Feldman SR. Frequency and cost of actinic keratosis treatment. *Dermatol Surg*. 2006;32(8):1045–1049.
 17. Zhang Z, et al. Thymic stromal lymphopoietin overproduced by keratinocytes in mouse skin aggravates experimental asthma. *Proc Natl Acad Sci U S A*. 2009;106(5):1536–1541.
 18. Abel EL, Angel JM, Kiguchi K, DiGiovanni J. Multi-stage chemical carcinogenesis in mouse skin: fundamentals and applications. *Nat Protoc*. 2009;4(9):1350–1362.
 19. Ito K, Koga M, Shibayama Y, Tatematsu S, Nakayama J, Imafuku S. Proactive treatment with calcipotriol reduces recurrence of plaque psoriasis. *J Dermatol*. 2016;43(4):402–405.
 20. Seckin D, Cerman AA, Yildiz A, Ergun T. Can topical calcipotriol be a treatment alternative in actinic keratoses? A preliminary report. *J Drugs Dermatol*. 2009;8(5):451–454.
 21. Kaur RR, Alikhan A, Maibach HI. Comparison of topical 5-fluorouracil formulations in actinic keratosis treatment. *J Dermatolog Treat*. 2010;21(5):267–271.
 22. Khallouf H, et al. 5-Fluorouracil and interferon- α immunochemotherapy enhances immunogenicity of murine pancreatic cancer through upregulation of NKG2D ligands and MHC class I. *J Immunother*. 2012;35(3):245–253.
 23. Kroemer G, Galluzzi L, Kepp O, Zitvogel L. Immunogenic cell death in cancer therapy. *Annu Rev Immunol*. 2013;31:51–72.
 24. Ratushny V, Gober MD, Hick R, Ridky TW, Seykora JT. From keratinocyte to cancer: the pathogenesis and modeling of cutaneous squamous cell carcinoma. *J Clin Invest*. 2012;122(2):464–472.
 25. Demehri S, et al. Thymic stromal lymphopoietin blocks early stages of breast carcinogenesis. *J Clin Invest*. 2016;126(4):1458–1470.
 26. Clark RA. Resident memory T cells in human health and disease. *Sci Transl Med*. 2015;7(269):269rv1.
 27. Martincorena I, et al. Tumor evolution. High burden and pervasive positive selection of somatic mutations in normal human skin. *Science*. 2015;348(6237):880–886.
 28. Lian CG, et al. Biomarker evaluation of face transplant rejection: association of donor T cells with target cell injury. *Mod Pathol*. 2014;27(6):788–799.
 29. Black AP, et al. Human keratinocyte induction of rapid effector function in antigen-specific memory CD4⁺ and CD8⁺ T cells. *Eur J Immunol*. 2007;37(6):1485–1493.
 30. Strid J, Sobolev O, Zafirova B, Polic B, Hayday A. The intraepithelial T cell response to NKG2D-ligands links lymphoid stress surveillance to atopy. *Science*. 2011;334(6060):1293–1297.
 31. Pomerantz H, et al. Long-term Efficacy of Topical Fluorouracil Cream, 5%, for Treating Actinic Keratosis: A Randomized Clinical Trial. *JAMA Dermatol*. 2015;151(9):952–960.
 32. Hanke CW, Beer KR, Stockfleth E, Wu J, Rosen T, Levy S. Imiquimod 2.5% and 3.75% for the treatment of actinic keratoses: results of two placebo-controlled studies of daily application to the face and balding scalp for two 3-week cycles. *J Am Acad Dermatol*. 2010;62(4):573–581.
 33. Drobets B, et al. Imiquimod clears tumors in mice independent of adaptive immunity by converting pDCs into tumor-killing effector cells. *J Clin Invest*. 2012;122(2):575–585.
 34. Rivers JK, Arlette J, Shear N, Guenther L, Carey W, Poulin Y. Topical treatment of actinic keratoses with 3.0% diclofenac in 2.5% hyaluronan gel. *Br J Dermatol*. 2002;146(1):94–100.
 35. Leibold M, Swanson N, Anderson LL, Melgaard A, Xu Z, Berman B. Ingenol mebutate gel for actinic keratosis. *N Engl J Med*. 2012;366(11):1010–1019.