

# Stercoral colitis: diagnostic value of CT findings

Emre Ünal  
Mehmet Ruhi Onur  
Sinan Balcı  
Ayşegül Görmez  
Erhan Akpınar  
Medine Böge

## PURPOSE

We aimed to evaluate the CT findings of stercoral colitis (SC).

## METHODS

Forty-one patients diagnosed with SC between February 2006 and April 2015 were retrospectively reviewed.

## RESULTS

Rectosigmoid colon was the most frequently involved segment (100%, n=41). CT findings can be summarized as follows: dilatation >6 cm and wall thickening >3 mm of the affected colon segment (100%, n=41), pericolonic fat stranding (100%, n=41), mucosal discontinuity (14.6 %, n=6), presence of free air (14.6%, n=6), free fluid (9.7%, n=4), and pericolonic abscess (2.4%, n=1). The sign most related with mortality was the length of the affected colon segment >40 cm.

## CONCLUSION

CT has an important role in SC, since life-threatening complications can be easily revealed by this imaging modality. Increased length of involved colon segment (>40 cm) is more likely to be associated with mortality.

**S**tercoral colitis (SC) is an inflammatory colitis caused by increased intraluminal pressure from impacted fecal material in the colonic segments (1). SC may present with a spectrum ranging between impacted fecaloma associated with inflammation to colonic perforation. Most important complication of SC is colonic perforation, reported to be associated with a mortality rate of 32%–57% (1).

Patients with SC almost always present with chronic constipation, medical comorbidity, and advanced age, which may facilitate occurrence of life-threatening complications (2). Chronic constipation aggravated by physical inactivity leads to a vicious cycle with constipation leading to more and harder stool impaction and the impaction leading to blockage of colonic movement. Neurologic and psychiatric comorbid disorders may delay the diagnosis of SC by preventing optimal history taking and masking physical examination. Lack of definitive clinical evidence of SC, makes imaging based diagnosis essential. Late diagnosis of SC can lead to severe complications and even mortality (3, 4).

The aim of this study was to investigate CT findings in the diagnosis of SC. We also intended to define CT features related to severe life-threatening complications of SC.

## Methods

This retrospective study has been approved by the local ethics committee and conducted in accordance with the Declaration of Helsinki (2000). Informed consent was waived because of the retrospective nature of the study.

## Patients

Between February 2006 and April 2015, 45 patients were diagnosed with SC. An imaging based diagnosis of SC was established when the following criteria were met: distention of the affected colon segment >6 cm with fecal material; wall thickening >3 mm of the affected colon segment; and pericolonic fat tissue stranding. One patient with Ogilvie syndrome and three patients diagnosed on abdominal scans of pulmonary artery embolism CT proto-

From the Department of Radiology (E.Ü. ✉ emreunal.rad@gmail.com, M.R.O, S.B., A.G., E.A.), Hacettepe University School of Medicine, Ankara, Turkey; Department of Radiology (E.Ü), Zonguldak Atatürk State Hospital, Zonguldak, Turkey; Department of Radiology (M.B.), Koç University School of Medicine, İstanbul, Turkey.

This study was presented as a poster at ESGAR 2015.

Received 4 January 2016; revision requested 5 February 2016; last revision received 28 April 2016; accepted 23 May 2016.

Published online 2 December 2016.  
DOI 10.5152/dir.2016.16002

col were excluded from the analysis. CT images and medical records of the remaining 41 patients were retrospectively reviewed.

### CT technique

All patients underwent CT examinations of the abdomen and pelvis with two-detector CT (Somatom Emotion Duo, Siemens Medical Systems). CT images were acquired with following parameters: slice thickness, 5 mm; reconstruction interval, 5 mm; pitch, 1.5–2; tube voltage, 120–130 kV; and tube flow, 200–240 mA/s.

Five patients were scanned for the diagnosis of urinary tract stone; thus, neither intravenous (IV) nor oral contrast material was used for the CT examinations of these patients. In 36 of 41 patients, 100 mL of IV contrast material at a flow rate of 4 mL/s (Ultravist 300/100 mg/mL; Bayer Schering Pharma) was routinely used in accordance with our radiology department's abdominal imaging protocols. The venous phase abdominal CT scans were automatically started 70 s after the triggering threshold of the abdominal aorta (100 HU) was reached. All patients received oral administration of diluted nonionic contrast material approximately one hour before the beginning of scanning. Abdominal CT scan area included the body region between the level of the lower thorax and femur necks.

### Image analysis and description of CT signs

CT findings were reviewed retrospectively by two independent radiologists with 12 and 10 years of experience in abdominal radiology. Reviewers were blinded to the physical examination findings, laboratory results, radiology reports and diagnosis of SC. In case of discrepancy, consensus was reached by two reviewers.

#### Main points

- Impacted fecal material in colonic segments is the main cause of stercoral colitis (SC).
- Clinical and laboratory findings are not sufficient for the diagnosis of SC, since patients with long standing constipation have a high rate of comorbidities.
- CT is essential for the diagnosis, demonstrating complications and differential diagnosis of SC.
- Early diagnosis is crucial, since SC may present with a spectrum ranging from impacted fecaloma associated with localized inflammation to colonic perforation.
- Involved colon segment >40 cm at CT exam may indicate poor prognosis.

**Table 1.** Description of CT features in stercoral colitis

CT findings	Description
Fecal impaction	Colon lumen filled with hard stool material
Colon dilatation	Colon segment with increased cross-sectional diameter (>6 cm) secondary to stool impaction
Colon wall thickening	Wall thickness >3 mm at the impacted site
Mucosal discontinuity	Lack of mucosal enhancement due to pressure
Pericolonic fat stranding	Increased density and streaks of fat caused by the inflammation
Extraluminal free air	Air migrating from colon lumen into (pneumatosis coli) or beyond (pneumoperitoneum or air in veins) the wall of the colon

**Table 2.** Associated medical conditions

	n (%)
Chronic comorbid disease <sup>a</sup>	9 (21.9)
Dementia, Alzheimer, Parkinson disease	9 (21.9)
Bedridden due to cerebrovascular accident	6 (14.6)
Malignancy <sup>b</sup>	6 (14.6)
Bedridden due to orthopedic surgery	4 (9.7)
Operated for intracranial mass	1 (2.4)
Phenylketonuria	1 (2.4)
Congenital ichthyosis	1 (2.4)
Rectovaginal fistula	1 (2.4)

Three of 41 patients had no comorbid diseases.  
<sup>a</sup>Diabetes mellitus, hypertension, renal failure; <sup>b</sup>Breast, lymphoma, lung, stomach, ovary.

The location and length of the colon segment affected by fecal impaction and cross-sectional luminal diameter and thickness of the affected colon segment wall were determined on CT images. Axial CT images were used to measure wall thickness and lumen diameter. Coronal and sagittal reformat images were used to measure length of the affected colon segment accurately. Stranding of pericolonic fat, mucosal discontinuity, presence of free air, free fluid and pericolonic abscess were also reviewed separately by two blinded radiologists. CT signs that were used as diagnostic criteria are defined in Table 1.

### Statistical analysis

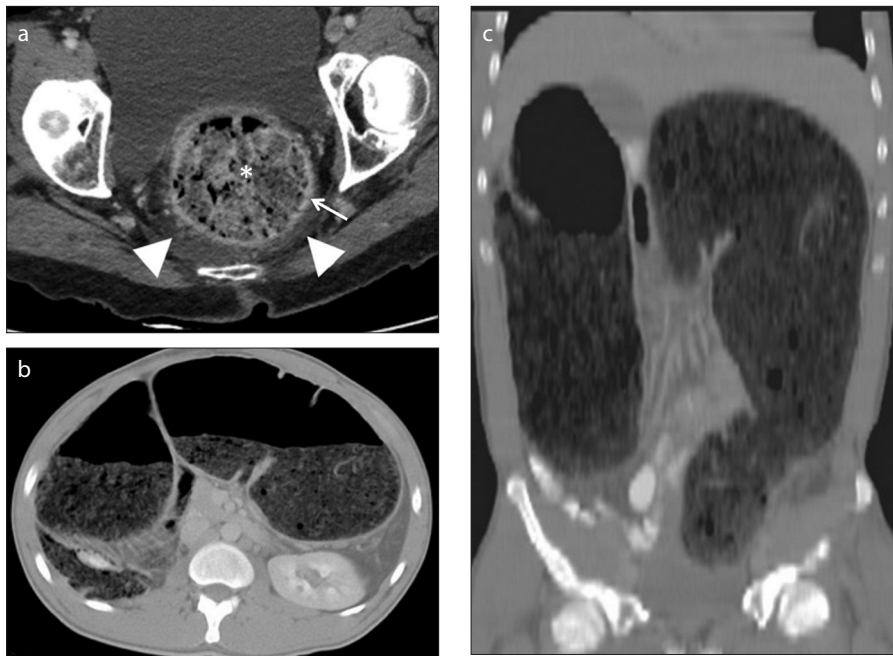
Statistical Package for Social Sciences (SPSS) version 15.0 (SPSS Inc.) was used for statistical analysis. Descriptive statistics were given as median (minimum–maximum) and mean ± standard deviation. Distribution of numbers representing age, mortality, and CT findings were determined by Kolmogorov-Smirnov test and Shapiro-Wilk test. The relationship between age and mortality was evaluated by using the

Mann-Whitney U test. Relationships between mortality and CT findings (length of involved colon segment, free air, and free fluid) were evaluated with chi-square test and Fischer's exact test. Statistical significance was set at  $P < 0.05$ .

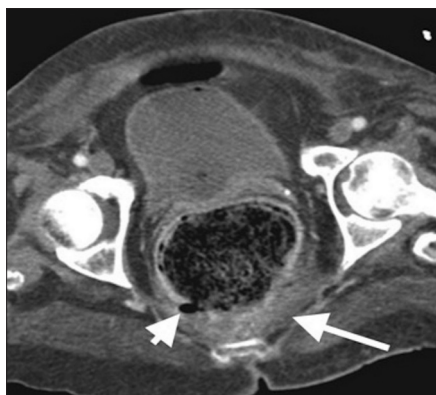
## Results

Patients included 19 men and 22 women with a median age of 74 years (range, 16–93 years). Five men (26.3%) and five women (22.7%) died. There was no significant relationship between sex and mortality ( $P = 1.000$ ). Patients with mortality related to stercoral colitis, had a median age of 67 years (range, 21–88 years), and patients without mortality had a median age of 74 years (range, 16–93 years). There was no significant relationship between the age of the patients and mortality ( $P = 0.632$ ). All patients had long-standing constipation. The burden of comorbid diseases was high in the study cohort ( $n=38$ ; 92%) (Table 2).

All patients experienced abdominal discomfort accompanying acute nonspecific abdominal pain. Fifteen patients had fever (>38°C), 12 patients tachycardia, 16 patients



**Figure 1. a–c.** Fecal impaction and colon dilatation. Axial contrast-enhanced CT image (a) demonstrates dilatation of the rectum resulting from fecal impaction (asterisk). Perirectal inflammation manifests with perirectal fat stranding (arrowheads). Thickening of the rectum wall is also noted (arrow). Axial (b) and coronal (c) CT images demonstrate diffuse dilatation of colonic segments.



**Figure 2.** Mucosal discontinuity and rectal ulcer in stercoral colitis. Axial contrast-enhanced CT of a 65-year-old female reveals mucosal discontinuity, free air (arrowhead), and perirectal stranding (arrow).

high blood pressure, and 17 patients high acute phase reactants. However, the vital signs were not reliable because of accompanying diseases. Increased acute phase reactants and leukocytosis were the most common laboratory findings. Nine patients (21.9%) had hard fecalomas found on physical examination and were treated by enemas and manual disimpaction. In one patient (2.4%), a rectal tube was placed to relieve colonic dilatation. Two patients underwent surgery due to failure of conservative therapy (manual disimpaction and rectal tube placement). They had no comor-

bid diseases that could preclude surgery. In addition to increased abdominal distension, they had leukocytosis and increased levels of acute phase reactants. Therefore surgery was indicated. One of these patients had surgical fecaloid disimpaction and was discharged uneventfully. Presurgical CT scan of the other patient demonstrated extensive colonic involvement (>40 cm) without any signs of perforation (free air or fluid). However, after the surgery, patient suffered from anastomosis leakage and died because of sepsis. The remainder of the patients (70%, n=29) could not tolerate any invasive procedures including rectal enema. Therefore, these patients were monitored with manual disimpaction and oral laxatives. In patients with more extensive colonic involvement (17%, n=7) more aggressive treatment options were considered; however, accompanying several comorbid diseases precluded this approach. Moreover, most of the patients could not tolerate rectal tube placement. Only one of the seven patients with extensive colonic involvement was able to undergo surgery; however, this patient died because of sepsis. Three of seven patients also died due to sepsis. Nevertheless, manual disimpaction and oral laxatives were successful to relieve colonic inflammation and dilatation in the remaining three patients.

Three patients (7.3%) had involvement of the entire colon. The mean length of colitis

was  $16.03 \pm 10.83$  cm. In seven patients (17%), the length of the affected colon segment was >40 cm. The mean diameter and wall thickness of segments with colitis were  $91 \pm 20.1$  mm and  $4.43 \pm 1.71$  mm, respectively.

The number and percentages of CT signs and accompanying mortality rates are summarized in Table 3. CT findings in patients with SC included fecal impaction (Fig. 1a), colon dilatation (Fig. 1b, 1c), thickening of the colon wall (Fig. 1a), pericolonic fat stranding (Fig. 1a), mucosal discontinuity associated ulcer formation (Fig. 2), free air (Fig. 3), free fluid, and perirectal abscess. There was no sign of significant stenosis, occlusion, or thrombosis affecting superior and inferior mesenteric arteries and veins in any of the patients. Ten patients (24.4%) died of sepsis within 1–20 days of CT exam. Three patients died long after the hospital discharge due to reasons unrelated to stercoral colitis (i.e., myocardial infarction, pulmonary failure, and pressure ulcers due to bedridden condition). These deaths were not attributed to SC. There was no other cause of sepsis apart from SC in the above-mentioned ten patients; thus, sepsis and resulting death were attributed to SC in these patients. There was a statistically significant relationship between the length of the affected colon segment >40 cm and mortality ( $P = 0.010$ ). No significant relationship was found between mortality and free air, mucosal discontinuity, or free fluid (Table 3).

## Discussion

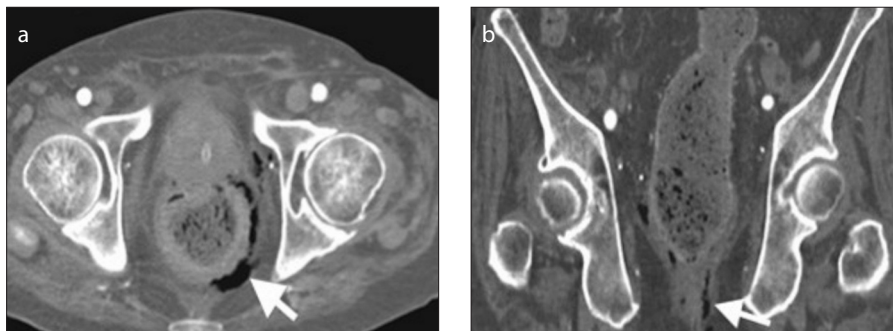
The term stercoral colitis refers to a condition that mainly depends on the presence of fecal impaction material in colonic lumen associated with inflammation and distention of the affected colon segment. Fecaloid formation is predominantly related to chronic constipation, which is seen primarily in elderly patients (often bedridden in consequence of dementia, stroke, or orthopedic surgery). Less frequently, SC can be seen in young patients who have metabolic disorders or neurologic/muscular deficits causing constipation. Chronic diseases such as diabetic neuropathy are also associated with SC (5–7). In the present study, the most common CT findings of SC were evaluated. Definition of SC, diagnosis by CT and the importance of radiologic findings were studied along with a review of the literature.

The conglomeration of fecaloids occurs, most frequently in the rectosigmoid region, as this is the narrowest part of

**Table 3.** CT findings and mortality in patients with stercoral colitis

CT findings	Patients	Mortality	P
Length of affected colon segment >40 cm	7 (17)	4 (57.1)	0.010
Dilatation of affected colon segment >6 cm	41 (100)	10 (24.4)	N/A
Wall thickening of the affected colon segment >3 mm	41 (100)	10 (24.4)	N/A
Pericolonic fat stranding	41 (100)	10 (24.4)	N/A
Free air	6 (14.6)	1 (16.6)	1.000
Mucosal discontinuity	6 (14.6)	2 (33.3)	0.651
Free fluid	4 (9.7)	2 (50)	0.288
Pericolonic abscess	1 (2.4)	0	N/A

Data are presented as n (%).  
CT, computed tomography; N/A, not available.



**Figure 3. a, b.** Extraluminal free air in stercoral colitis. A 79 year-old male presented with abdominal pain and shortness of breath with suspicion of accompanying mesenteric vascular compromise. Axial (a) and coronal (b) CT images show free air (arrows) secondary to perforation surrounding left posterolateral wall of the rectum.

the entire colon. Also prolonged passage from cecum leads to fecaloid material to become more solid and dehydrated resulting in hard stool fecaloma. Stone hard fecaloma causes distention and increased pressure on the colon wall and decreases vascular supply of the colon wall, particularly at the antimesenteric site, which is a vulnerable region known as Sudeck's point (1). Prolonged pressure and vascular compromise lead to ulceration, unless treated with tube placement, enemas, or digital disimpaction. SC has a clinical course ranging from noncomplicated fecaloid impaction to colonic perforation. If diagnosed early, relief of the colon can be established via nonsurgical procedures. In noncomplicated simple fecaloma impaction, CT reveals dilatation of the affected colon segment with fecaloid material within the lumen without associated wall thickening or pericolonic fat stranding. Thickening of the colon wall suggesting acute edema or inflammation was observed on CT in 100% of the patients in this study. When the in-

flammation affects beyond the colon wall, CT reveals pericolonic fat stranding. Thickening of the colon wall with accompanying pericolonic fat stranding is the most helpful imaging finding in the diagnosis of SC.

The conglomeration of multiple fecaloids gives rise to the possibility of multiple ulcers/perforation sites (8). Huang et al. (7) proved this possibility by visualization of multiple stercoral ulcers during intraoperative colonoscopy. The accompanying ulcers may result in extended colectomies. Limited surgeries may be associated with inferior clinical outcomes, since residual affected colonic segments carry the risk of recurrent perforations. In the literature, several studies suggest that in patients with stercoral perforation of the colon optimal outcome can be achieved by resection of the whole affected colon segment with an end colostomy (mucous fistula/Hartmann's procedure) (7–9). Our results tend to agree with these studies. In the present study, the finding most related to mortality was

the length of the involved colon segment >40 cm, as increased length of the affected colon results in multiple possible perforation sites.

Perforation as a consequence of stercoral ulcer was a rare entity when first described by Berry in 1894 (10). From 1894 to 2011, fewer than 150 cases with stercoral perforation of the colon have been reported (4, 6). In a different study, the incidence of stercoral perforation of the colon was determined as 0.5% of all surgical colorectal procedures through laparotomy, 1.2% of all emergency colorectal procedures, and 3.2% of all colonic perforations (8). Perforation of the colon resulting from stercoral colitis has been reported to be associated with a 35% mortality rate (1, 5). Stercoral colonic perforation is an infrequent cause of acute abdominal pain. Perforations frequently occur due to a diverticular disease, ulcerative colitis, infectious colitis, malignancy, and trauma, particularly in elderly patients who constitute the majority of SC patients. Therefore, the incidence of SC may be underestimated due to lack of suspicion.

Presence of free fluid in SC can be revealed by CT; however, this finding is nonspecific because of other common accompanying causes such as malnourished bedridden condition, diabetes, or liver-kidney failure. Definitive etiology of free fluid cannot be determined when such conditions are present. In the present study, four of 41 of patients (9.7%) presented with free fluid. Although not statistically significant, free fluid was associated with increased mortality risk compared with other CT findings (Table 3).

Dense mucosa sign and mucosal sloughing can also be seen with SC but were not observed in any of our patients. In a recently published article, Wu et al. (3) reported that dense mucosa sign had a significant correlation with fatal SC. They evaluated dense mucosa sign in unenhanced CT images and concluded that mucosal sloughing sign and pericolonic abscess have high specificity (100% and 93%, respectively) for the diagnosis of fatal SC. However, this result did not reach statistical significance in diagnosing fatal SC (3). Since we performed unenhanced CT only on five patients, dense mucosa sign was not evaluated in our study.

In the present study, the finding most related to mortality was the length of involved colon segment, as 57.1% of patients with >40 cm colon involvement died due to sepsis and deteriorated clinical course

(Table 3). Deaths were attributed to SC in patients who died in the same hospitalization period with the diagnosis of SC; physicians were also consulted to confirm the association. CT findings with associated high mortality rates were free fluid (50%) and mucosal discontinuity (33%). Free air was revealed in six patients and one died from sepsis secondary to SC. No significant association was found between mortality and free air; instead, accompanying free fluid seemed to be associated with mortality in our study. We acknowledge that this is confusing. Although our small patient group may be responsible for this finding, we hypothesize that small and limited perforation sites, which are responsible for simple extraluminal air bubbles, may be sealed with stool material. In the absence of large perforation sites that cause protrusion of fecaloid material through the abdominal cavity, small millimetric limited perforation sites may induce free simple extraluminal air bubbles and may be sealed with fecaloid material without protruding. Administration of conservative treatments in these patients such as enema and rectal tube placement may provide enough time for secondary healing, if diagnosed at early stages. On the other hand, presence of free fluid or abscess indicates a more complicated incident, since presence of fluid may suggest associated infection with or without accompanying leakage from the colon. Wu et al. (3) reported that the incidence of CT signs of dense mucosa, perfusion defect, free fluid, and abnormal gas was statistically different between fatal and nonfatal SC. In addition to these CT features, we found affected colon segment length >40 cm to be associated with increased mortality in SC. Although statistical association could not be achieved due to small patient group and small percentage of CT findings in our

study, these results suggest that sepsis and death may occur secondary to SC even in the absence of perforation, ulceration, or necrosis. A further study with larger number of patients is required to confirm the value of these CT findings.

Stercoral perforation may be mimicked by perforation from acute diverticulitis. There are some imaging features, which may be helpful to differentiate stercoral perforation from perforated diverticulitis as we observed in our study. Stercoral ulcers and perforated sites are often multiple as opposed to diverticulitis. Presence of fecal loading proximal to the stercoral perforation site and inflammatory involvement of the colon beyond the area of perforation, rather than only at the perforation site as in diverticulitis, may differentiate stercoral perforation from diverticular perforation (11).

Our study had some limitations. First, number of patients was not large enough for statistical assessment of CT findings and their association with sepsis and death. Second, histopathologic diagnosis of SC was absent in most cases, as a consequence of successful conservative treatments. Moreover, invasive interventions were avoided as much as possible as they carry their own mortality risk due to underlying comorbidities. Third, the nature of the study was retrospective.

In conclusion, fecal impaction with colitis seems to present more frequently than known by clinicians. Patients presenting with SC commonly have comorbid diseases and advanced age. Therefore, complications of SC and emergent surgery constitute risk factors of mortality. As laboratory test results and physical examination findings have limited value, CT remains the most helpful modality for diagnosing and differentiating SC from other causes of abdominal pain. Awareness of CT findings is

important since late diagnosis may result in fatal complications. Increased length of the involved colon segment in SC is associated with mortality.

#### Conflict of interest disclosure

The authors declared no conflicts of interest.

#### References

1. Serpell JW, Nicholls RJ. Stercoral perforation of the colon. *Br J Surg* 1990; 77:1325–1329. [\[CrossRef\]](#)
2. Haddad R, Bursle G, Piper B. Stercoral perforation of the sigmoid colon. *ANZ J Surg* 2005; 75:244–246. [\[CrossRef\]](#)
3. Wu CH, Huang CC, Wang LJ, et al. Value of CT in the discrimination of fatal from non-fatal stercoral colitis. *Korean J Radiol* 2012; 13:283–289. [\[CrossRef\]](#)
4. Wu CH, Wang LJ, Wong YC, et al. Necrotic stercoral colitis: importance of computed tomography findings. *World J Gastroenterol* 2011; 17:379–384. [\[CrossRef\]](#)
5. Heffernan C, Pachter HL, Megibow AJ, Macari M. Stercoral colitis leading to fatal peritonitis: CT findings. *AJR Am J Roentgenol* 2005; 184:1189–1193. [\[CrossRef\]](#)
6. Hsiao TF, Chou YH. Stercoral perforation of colon: a rare but important mimicker of acute appendicitis. *Am J Emerg Med* 2010; 28:112.e1–2. [\[CrossRef\]](#)
7. Huang WS, Wang CS, Hsieh CC, Lin PY, Chin CC, Wang JY. Management of patients with stercoral perforation of the sigmoid colon: report of five cases. *World J Gastroenterol* 2006; 12:500–503. [\[CrossRef\]](#)
8. Maurer CA, Renzulli P, Mazzucchelli L, Egger B, Seiler CA, Büchler MW. Use of accurate diagnostic criteria may increase incidence of stercoral perforation of the colon. *Dis Colon Rectum* 2000; 43:991–998. [\[CrossRef\]](#)
9. Guyton DP, Evans D, Schreiber H. Stercoral perforation of the colon. Concepts of operative management. *Am Surg* 1984; 51:520–522.
10. Berry J. Dilatation and rupture of sigmoid flexure short report. *Br Med J* 1894; 1:301.
11. Kumar P, Pearce O, Higginson A. Imaging manifestations of faecal impaction and stercoral perforation. *Clin Radiol* 2011; 66:83–88. [\[CrossRef\]](#)