



# Electron Microscopy Pathology of ADSSL1 Myopathy

Hyung Jun Park<sup>a</sup>  
Jee Eun Lee<sup>a</sup>  
Gyeong Seon Choi<sup>a</sup>  
Heasoo Koo<sup>b</sup>  
Soo Jeong Han<sup>c</sup>  
Jeong Hyun Yoo<sup>d</sup>  
Young-Chul Choi<sup>e</sup>  
Kee Duk Park<sup>a</sup>

<sup>a</sup>Departments of Neurology,

<sup>b</sup>Pathology, <sup>c</sup>Rehabilitation Medicine, and <sup>d</sup>Radiology, Mokdong Hospital, Ewha Womans University School of Medicine, Seoul, Korea

<sup>e</sup>Department of Neurology, Yonsei University College of Medicine, Seoul, Korea

Dear Editor,

Inherited muscular disorder is a heterogeneous group of genetic disorders that primarily affect skeletal muscle fibers. We have recently reported compound heterozygous mutations in *ADSSL1* in two Korean families with adolescent-onset distal myopathy.<sup>1</sup> However, ultrastructural changes associated with adenylosuccinate synthetase-like 1 (*ADSSL1*) myopathy have not been demonstrated previously. Here we report a third Korean family with *ADSSL1* mutations and describe the ultrastructural features of *ADSSL1* myopathy.

A 15-year-old girl (Supplementary Fig. 1A and B in the online-only Data Supplement, II-2) presented with gait disturbance. She was the second child of healthy, nonconsanguineous parents. She had first noticed difficulty running when aged 8 years, and the muscle weakness had progressed very slowly. When we examined her at an age of 15 years, she could still ambulate independently. A neurological examination revealed diffuse muscle weakness, predominantly in the leg muscles. She did not exhibit facial weakness, sensory deficits, joint contractures, or a high-arch palate. Her serum creatine kinase (CK) level was 281 IU/l (reference value <185 IU/l). The findings of needle electromyography were compatible with generalized myopathy. Her electrocardiography findings were normal. Lower-limb MRI showed subtle fatty replacement of the tibialis anterior and gastrocnemius muscles (Supplementary Fig. 1C-G in the online-only Data Supplement).

The vastus lateralis muscle was biopsied when she was 15 years old. The myofibers showed marked size and shape variations along with frequent internalization of the sarcolemmal nuclei and splitting; vacuolization of the sarcoplasm, degenerating myofibers, and abnormal (whorled) arrangement of the myofibrils were also noted (Fig. 1A and B). In addition, focal endomysial fibrosis and fatty infiltration were present. Periodic acid-Schiff and Oil Red O staining did not produce abnormal positive reactions. Modified Gomori trichrome and nicotinamide adenine dinucleotide-tetrazolium reductase staining revealed whorled fibers and occasional rimmed vacuoles without ragged red fibers, cytoplasmic bodies, or nemaline rods (Fig. 1C and D). The ATPase reaction with preincubations at different pH values and immunostaining with myosin heavy chain (fast), myosin heavy chain (slow), and myosin IIa revealed a predominance of type I fibers. An electron microscopy examination showed myofibers with varying degrees of disorganization, and disorientation of the myofibrils with loss of their normal striation pattern (Fig. 1E). The myofibers showing diffuse or localized myofibrillar destruction contained remnants of the myofibrils, irregular electron-dense material of Z-line origin, and rounded and swollen mitochondria (Fig. 1F). In addition, various abnormalities of the Z-disc (including thickening) were noted, as well as displaced and replicated triads.

To identify the genetic cause, exome sequencing was performed on the proband (Supplementary Table 1 in the online-only Data Supplement). Screening of myopathy-related genes revealed 27 functionally significant variants (Supplementary Table 2 in the online-only Data Supplement). We subsequently identified compound heterozygous c.910G>A (p.D340N) and

**Received** April 29, 2016

**Revised** June 10, 2016

**Accepted** June 13, 2016

## Correspondence

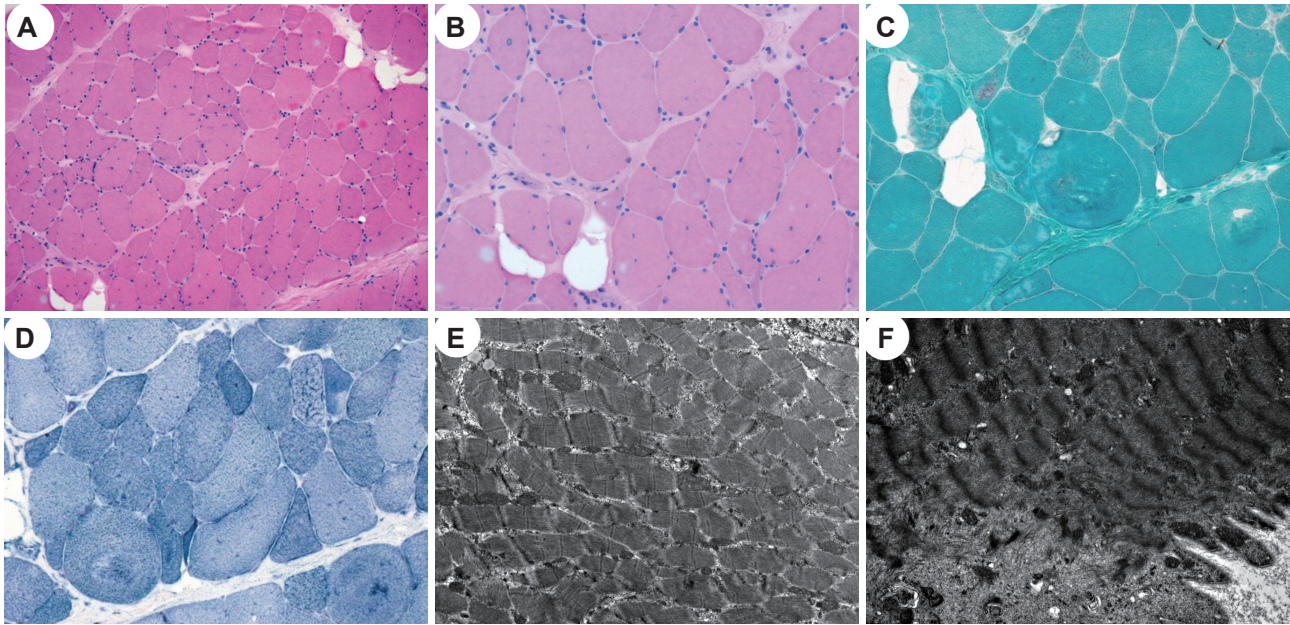
Kee Duk Park, MD, PhD  
Department of Neurology,  
Ewha Womans University  
College of Medicine, 1071  
Anyangcheon-ro, Yangcheon-gu,  
Seoul 07985, Korea

**Tel** +82-2-2650-6010

**Fax** +82-2-2650-2652

**E-mail** pkd1165@ewha.ac.kr

© This is an Open Access article distributed under the terms of the Creative Commons Attribution Non-Commercial License (<http://creativecommons.org/licenses/by-nc/3.0>) which permits unrestricted non-commercial use, distribution, and reproduction in any medium, provided the original work is properly cited.



**Fig. 1.** Histopathological findings of vastus lateralis muscle biopsy. A and B: Hematoxylin and eosin staining revealed marked variations of the fiber size and shape with frequent internalization of sarcolemmal nuclei and splitting; vacuolization of the sarcoplasm, focal endomysial fibrosis, and fatty infiltration were also occasionally noted. C: Modified Gomori trichrome staining showed whorled myofibers and occasional rimmed vacuoles. D: Nicotinamide adenine dinucleotide-tetrazolium reductase staining revealed a disorganized myofibrillar arrangement. E and F: An electron microscopy examination showed varying degrees of disorganization of the myofibrils with loss of their normal striation pattern (E). Myofibers showing localized myofibrillar destruction contained remnants of the myofibrils, irregular electron-dense material of Z-line origin, and swollen mitochondria (F) (A,  $\times 100$ ; B, C, and D:  $\times 200$ ; E:  $\times 10,000$ ; F:  $\times 15,000$ ).

c.1048delA (p.I350fs) mutations in *ADSSL1*, which we recently reported to be the underlying cause of distal myopathy.<sup>1</sup> Subsequent capillary analysis showed that the *ADSSL1* mutations cosegregated completely with the affected status (Supplementary Fig. 1A and B in the online-only Data Supplement).

This study identified compound heterozygous *ADSSL1* mutations in a Korean patient with congenital myopathy. The *ADSSL1* protein encoded by *ADSSL1* is a muscle-specific enzyme that has a role in purine nucleotide interconversion by catalyzing the initial reaction in the conversion of inosine monophosphate to adenosine monophosphate.<sup>2</sup> Although a previous study using cell and zebra-fish models demonstrated the damaging effect on *ADSSL1*, the pathogenesis of *ADSSL1* myopathy has remained unclear.<sup>1</sup> The mutational, clinical, and pathological manifestations of the present patient showed both similarities with and differences from those in previously reported cases of *ADSSL1* myopathy (Supplementary Table 3 in the online-only Data Supplement). Identical *ADSSL1* mutations have been identified in three Korean families, which suggests that the c.910G>A and c.1048delA mutations are founder *ADSSL1* mutations in the Korean population. Clinically the patients show normal early motor milestones, very slow disease progression, and mild CK elevation. However, the patient in the present study showed diffuse muscle weakness without facial involvement. The

muscle biopsy similarly demonstrated myopathic changes with rare rimmed vacuoles. The present study is the first to reveal pathology findings at the electron microscopy level, including irregular electron-dense material of Z-line origin, and rounded and swollen mitochondria. However, these findings are nonspecific for inherited muscular disorders.

In conclusion, this is the first report on the ultrastructural pathology of *ADSSL1* myopathy and it extends the known clinical and pathological features.

### Supplementary Materials

The online-only Data Supplement is available with this article at <https://doi.org/10.3988/jcn.2017.13.1.105>.

### Conflicts of Interest

The authors have no financial conflicts of interest.

### Acknowledgements

The authors would like to thank the patients and their families for their essential help with this work.

### REFERENCES

1. Park HJ, Hong YB, Choi YC, Lee J, Kim EJ, Lee J, et al. *ADSSL1* mutation relevant to autosomal recessive adolescent onset distal myopathy. *Ann Neurol* 2016;79:231-243.
2. Lipps G, Krauss G. Adenylosuccinate synthase from *Saccharomyces cerevisiae*: homologous overexpression, purification and characterization of the recombinant protein. *Biochem J* 1999;341(Pt 3):537-543.