

Global Aesthetics Consensus: Avoidance and Management of Complications from Hyaluronic Acid Fillers—Evidence- and Opinion-Based Review and Consensus Recommendations

Massimo Signorini, M.D.

Steven Liew, F.R.A.C.S.

Hema Sundaram, M.D.

Koenraad L. De Boulle,

M.D.

Greg J. Goodman, M.D.

Gary Monheit, M.D.

Yan Wu, M.D.

Ada R. Trindade de

Almeida, M.D.

Arthur Swift, M.D., C.M.

André Vieira Braz, M.D.

Global Aesthetics Consensus

Group

Milan, Italy; Sydney, New South Wales, and Carlton, Victoria, Australia; Rockville, Md.; Aalst, Belgium; Birmingham, Ala.; Beijing, People's Republic of China; São Paulo and Rio de Janeiro, Brazil; and Montreal, Quebec, Canada

Background: Although the safety profile of hyaluronic acid fillers is favorable, adverse reactions can occur. Clinicians and patients can benefit from ongoing guidance on adverse reactions to hyaluronic acid fillers and their management.

Methods: A multinational, multidisciplinary group of experts in cosmetic medicine convened the Global Aesthetics Consensus Group to review the properties and clinical uses of Hylacross and Vycross hyaluronic acid products and develop updated consensus recommendations for early and late complications associated with hyaluronic acid fillers.

Results: The consensus panel provided specific recommendations focusing on early and late complications of hyaluronic acid fillers and their management. The impact of patient-, product-, and technique-related factors on such reactions was described. Most of these were noted to be mild and transient. Serious adverse events are rare. Early adverse reactions to hyaluronic acid fillers include vascular infarction and compromise; inflammatory reactions; injection-related events; and inappropriate placement of filler material. Among late reactions are nodules, granulomas, and skin discoloration. Most adverse events can be avoided with proper planning and technique. Detailed understanding of facial anatomy, proper patient and product selection, and appropriate technique can further reduce the risks. Should adverse reactions occur, the clinician must be prepared and have tools available for effective treatment.

Conclusions: Adverse reactions with hyaluronic acid fillers are uncommon. Clinicians should take steps to further reduce the risk and be prepared to treat any complications that arise. (*Plast. Reconstr. Surg.* 137: 961e, 2016.)

Nonsurgical techniques with hyaluronic acid fillers to rejuvenate and/or address disharmonies deliver safe, effective, and reproducible aesthetic results. They allow for the correction of rhytides, folds, and volume deficits in response to age-related changes or disease. Since their addition to the American Society for Aesthetic Plastic Surgery survey of clinicians (i.e., dermatologists, otolaryngologists, and plastic surgeons) in 2004, hyaluronic acid injections have become the second most popular nonsurgical cosmetic procedure after botulinum toxin treatment. In 2014, over 1.6 million procedures were performed with hyaluronic acid fillers.¹

Received for publication July 28, 2015; accepted January 21, 2016.

The faculty of the Global Aesthetics Consensus Group is listed in the Appendix.

Copyright © 2016 by the American Society of Plastic Surgeons

DOI: 10.1097/PRS.0000000000002184

The market size for these products is expanding dramatically. Although the safety profile of hyaluronic acid fillers is very favorable, adverse reactions can occur, and their number may rise as the numbers of indications and procedures increase and treatment paradigms evolve, including the use of larger volumes and layering techniques, new classes of products, and long-term repeated treatment.

CONSENSUS OBJECTIVES AND METHODOLOGY

The evolution in aesthetic medicine necessitates updated clinical recommendations to guide patient assessment and treatment with hyaluronic acid fillers. Specific areas to be addressed in this consensus include the following:

- Diagnosis and classification of hyaluronic acid filler reactions.

Disclosure: *André Vieira Braz, M.D., states that he is a consultant and speaker with Allergan, Galderma, and Palomar. Jean D. A. Carruthers, M.D., states that she is a consultant and researcher with Allergan, Merz, and Kythera. Koenraad L. De Boulle, M.D., states that he is a consultant, member of the speaker's board, and recipient of honoraria and grants for studies and lectures for Allergan; a consultant for Kythera and Genévrier; and a consultant and member of the speaker's bureau for Johnson & Johnson. Steven Fagien, M.D., states that he is a consultant/investigator for Allergan, Galderma, Merz, Kythera, and Aquavit. Greg J. Goodman, M.D., states that he has no financial interests that would conflict with the article; he serves on advisory boards and speaker panels for Allergan, Galderma, and Merz that may be seen to have an interest in the outcome of a consensus document. Soo-Keun Lee, M.D., states that he is a consultant for Allergan. Steven Liew, F.R.A.C.S., states that he serves on advisory boards for Allergan, Galderma, and Kythera and has received honoraria from Allergan and Galderma for delivering local and international workshops and lectures and trials. Gary Monheit, M.D., states that he is a consultant and clinical investigator for Allergan Corporation (Juvéderm), Ipsen/Medicis (Dysport), MELA Sciences, Inc. (MelaFind), Revance, Kythera, Galderma, Mentor, and Merz; a consultant for Myoscience and Qmed; and a clinical investigator for Dermik Laboratories (Sculptra) and Contura (Aquamid). Hervé Raspaldo, M.D., states that he is a consultant for Allergan. Rod J. Rohrich, M.D., states that he is an expert for Allergan Medical and receives book royalties from Quality Medical Publishing and Taylor and Francis Publishing and instrument royalties from Eriem Surgical, Inc. Gerhard Sattler, M.D., states that he is a clinical investigator for Allergan, Galderma, Merz, Regeneron, and Novartis; a participant in advisory board meetings for Allergan, Galderma, and Merz; and a speaker for Allergan, Galderma, and Merz. Massimo Signorini, M.D., states that he is a medical expert for and has taken part in advisory boards and workshops for Allergan and Galderma. Hema Sundaram, M.D., states that she serves as a clinical investigator and/or consultant for Allergan, CosmoFrance, Croma, Evolus/Strathspey Crown, Galderma, HaoHai Healthcare, Kythera, Merz, and Teoxane. Arthur Swift, M.D., states that he is a speaker, clinical researcher, and advisor to Allergan, Galderma, and Merz. Ada R. Trindade de Almeida, M.D., states that she is an advisor for Allergan, Merz, Galderma, Roc, and Mantecorp and has participated in clinical trials for Allergan. Dr. Trindade is also a speaker for Allergan and Theraskin. Yan Wu, M.D., states that she serves as a clinical investigator for Allergan, GlaxoSmithKline, Lanzhou Biological Products Institute, and Freda Biopharm (Shandong hyaluronic acid filler).*

- Strategies to avoid and mitigate associated undesirable sequelae.
- Treatment of established complications.
- Factors affecting the occurrence of adverse reactions.

In January of 2014, a multinational, multidisciplinary group of 16 experts in aesthetic medicine, including plastic surgery, dermatology, facial plastic surgery, and oculoplastic surgery (the “consensus panel”), convened the Global Aesthetics Consensus Group to review the properties and clinical uses of onabotulinumtoxinA (Botox Cosmetic; Allergan, Inc., Irvine, Calif.) and hyaluronic acid fillers, with a focus on Hylacross and Vycross products (Allergan), and to develop updated consensus recommendations for early and late complications associated with hyaluronic acid fillers (Table 1). The methodology for determining consensus involved grading statements and opinions developed during the conference (i.e., grade A = recommended, grade B = reasonable choice, grade C = not fully established, and grade D = not recommended), with consensus defined as two-thirds of polled panel members selecting a specific consensus grade. The minimum number of polled faculty was 11 (constituting a quorum). If no statement/opinion grade reached the two-thirds level, results were reported as “no consensus reached.” In addition, statements and expert opinion supported by a majority (but less than two-thirds) of the panel were framed as “position statements.”

The specific recommendations and position statements presented in this article represent the panel's expert opinion based on their collective

Table 1. Classification of Soft-Tissue Filler Complications by Onset of Adverse Event

Early reactions
Vascular infarction/soft-tissue necrosis
Inflammatory reactions (acute/chronic)
Infection
Allergic reactions/ hypersensitivity
Injection-related events
Pain
Ecchymosis
Erythema
Bruising
Bleeding
Inappropriate/superficial placement
Distant spread
Late reactions
Inflammatory reactions (acute/chronic)
Infection
Granuloma (typically chronic)
Differential diagnosis
Nodules
Dyspigmentation
Displacement of hyaluronic acid filler material

clinical experience and published data regarding adverse reactions with hyaluronic acid fillers in the cosmetic setting.

COMPLICATION MANAGEMENT IS THE LARGEST UNMET NEED WITH HYALURONIC ACID FILLERS

When used appropriately, hyaluronic acid fillers are associated with a very low rate of adverse reactions.²⁻⁵ However, these can arise, ranging from minor and self-limited to severe complications requiring prompt treatment and close follow-up. Therefore, in addition to having a clear understanding of potential reactions caused by the products, clinicians should know when and how to intervene to manage the entire spectrum of complications. Optimal complication management remains an unmet need in the field of aesthetic medicine.

Patient-, Product-, and Technique-Related Factors

Clinicians must be mindful of patient-, product-, and technique-related factors that can impact the occurrence of adverse reactions. Some anatomical areas, such as glabella, alar base, nose, and temple are known to be associated with higher risks of vascular complications.⁶⁻⁹ In addition, patient history may be a pertinent factor in the emergence of adverse reactions.

Relevant product-related factors include the concentration and rheologic properties of the filler, and the manufacturing processes (e.g., purification). The clinician has control over injection technique—specifically, the depth, volume, speed, and accuracy of injection. In this context, the panel stressed that all clinicians performing injections should have a thorough knowledge of facial anatomy.

Impact of a Changing Treatment Landscape

The injection of larger volumes of hyaluronic acid may affect the occurrence of foreign-body reactions (e.g., in response to filler components, bacterial proteins). Hyaluronic acid is derived from a fermentation of bacteria, which may be a source of impurities. Breakdown products of hyaluronic acid fillers in vivo could likewise elicit hypersensitivity reactions, and differences in water-binding capacity among products could be relevant to localized reactions such as pain and swelling. The potential introduction of impurities during production argues in favor of obtaining hyaluronic acid fillers from reputable “mainstream” manufacturers that ensure the quality of

source material and practice high manufacturing standards.

The panel noted that long-term repeated treatment with hyaluronic acid fillers is increasing in clinical practice. Theoretically at least, this poses a possible increased risk of antibody formation. However, hyaluronic acid is a naturally occurring polysaccharide that exhibits no species or tissue specificity,^{10,11} and clinical experience and study data support the safety of retreatment.¹² Biocompatibility data provide some reassurance regarding long-term exposure to the cross-linker 4-butanedioldiglycidyl ether in some hyaluronic acid filler products.^{13,14}

Increased risk of biofilm formation is another potential consequence of long-term treatment. Biofilms consist of densely packed communities of bacteria surrounded by secreted polymers.^{15,16} These quiescent communities may become activated on repeated treatment. The surface area of product (large bolus), longevity of product,^{16,17} and inadequate sterile technique are other factors hypothesized to play a role in biofilm development. In the panel’s opinion, hyaluronic acid fillers have a low incidence of biofilm formation, although the relative risk may vary by filler, and the risk may be increased if the product is placed in the presence of a previously injected permanent filler.

AVOIDING AND MINIMIZING COMPLICATIONS

Patients should know that a small risk of complications exists with all dermal fillers. Written, informed consent should always be obtained before treatment. Although the risk of adverse reactions cannot be eliminated, the panel identified a number of steps that may decrease their occurrence (Table 2). The panel further advised injectors to assemble a “tool kit” for the management of complications should they arise (Table 3).

General Principles

Insufficient experience is a contributory factor in the development of complications.¹⁸ Clinicians should seek appropriate product selection and practice proper techniques to minimize adverse reactions. Clinicians performing injections should have a thorough knowledge of injection-related anatomy and, before treatment, elicit a full history of previous cosmetic procedures to determine whether relative or absolute contraindications exist. Specifically, the clinician should query the patient regarding previous complications with

Table 2. Strategies to Minimize the Risk of Adverse Reactions with Hyaluronic Acid Fillers

Know injection anatomy
Beware of “danger” areas
Aspirate before injecting
Slowly inject with the least amount of pressure possible
Move tip with delivery of product
Incrementally inject 0.1 to 0.2 ml of product
Use small syringe to deliver precise aliquots
Use small needle to slow injection speed
When indicated, use blunt microcannulas
Carefully consider the patient’s medical history
Stop injecting if resistance is encountered or the patient experiences pain/discomfort
Always monitor the patient

Table 3. Components of the Tool Kit for Managing Hyaluronic Acid Filler Complications

Hyaluronidase*
Steroids
Oral
Intralesional
Antibiotics†
Antiviral agents
Topical nitroglycerin (1%)
Antihistamines
Aspirin 325 mg orally
Warm compresses
Bacterial culture kit
Phone numbers of prearranged referrals (e.g., ophthalmologists, hyperbaric oxygen)

*See Figures 2 and 3 for recommended hyaluronidase schemas.

†See Figure 3 for recommended antibiotic schemas.

dermal fillers, significant allergy, or other significant medical conditions. The list of the patient’s medications should be reviewed.

Product selection is important, as the safety profiles of dermal fillers may vary.¹⁹ Importantly, the physical and rheologic properties of the filler should fit the intended intervention. For example, products with a higher elastic modulus (G') are not recommended in delicate areas such as the tear trough.

Hyaluronic acid fillers can be delivered safely and efficaciously by either cannula or needle if used appropriately. However, the panel recommended that needles be used with caution in areas prone to vascular complications. The use of blunt cannulas may be more appropriate in these regions. However, the panel stressed that no single injection technology is completely safe. Operator technique is more important with regard to safety (Table 2).

The validity of anterograde and retrograde injections was recognized by the panel, and it was strongly recommended that clinicians aspirate with a needle or cannula before injection, especially in high-risk areas. However, although positive aspiration is sufficient reason to remove the

instrument and reposition, clinicians should not rely on negative aspiration to rule out the risk of intravascular injection.

PREVENTION AND TREATMENT OF EARLY COMPLICATIONS

Pretreatment Antisepsis and Prophylaxis

The panel recommended that the treatment area be cleansed with appropriate antiseptic and the patient’s skin be free of makeup, which should also be avoided following treatment. Evidence supporting specific skin preparation is lacking, and alcohol swab preparation pads are commonly used. General guidelines for reduction of health care–associated infection include effective skin antisepsis using 2% chlorhexidine gluconate in 70% isopropyl alcohol.^{20,21} Disposable nonsterile gloves and sterile dressing trays and drapes²² are inexpensive and contribute to a hygienic work area as well.

To avoid triggering recurrent herpetic outbreaks, the panel recommended antiviral prophylaxis in patients with a history of herpes infection when injections into vulnerable areas are planned. Injections should be delayed in patients with active herpes lesions until their complete resolution (Table 4).

Vascular Infarction and Compromise

Intravascular injection of filler substances can lead to devastating side effects, such as tissue necrosis and vision loss. (Note: vascular infarction can resemble herpetic outbreaks, and they may be confused.) Vascular accidents are best avoided with knowledge of vascular anatomy (Fig. 1), adequate training, and appropriate technique. Several sources in the literature describe strategies for diminishing this risk.^{6,7} Precautions include aspiration before injection, slow injection with minimal pressure, and delivery of material at different points and in small volumes per pass. It is important to keep the needle moving. Use of small needles have been advocated by some members of the panel and blunt microcannulas have been advocated by others.

An algorithm for the treatment of intravascular injection is presented in Figure 2. The consensus includes immediate cessation of the injection, hyaluronidase, and massage (with warm compresses if appropriate). Hyaluronidase should be injected immediately and used daily in liberal doses where signs and symptoms are present (e.g., livedo reticularis–like appearance, pustulation, well-demarcated

Table 4. Global Aesthetics Consensus Group Recommendations and Position Statements for Management of Complications with Hyaluronic Acid Fillers

Statement	Recommendation or Position Statement
Hyaluronic acid fillers have an extremely good safety profile compared with other types of fillers; however, the treatment landscape is changing, which may impact the risk of reactions.	PS
Techniques are evolving with the use of larger volumes and new products, which has implications for patient selection, operator technique, and product selection.	PS
Patients should be made fully aware that a small risk of complications exists with hyaluronic acid fillers.	CR
Clinicians should elicit a full history of previous cosmetic surgery and procedures and determine whether relative or absolute contraindications exist based on clinical judgment.	CR
The patient's skin should be free of makeup before treatment with hyaluronic acid filler and the treatment area should be cleansed with appropriate antiseptic. It is generally advisable not to apply makeup to the treatment area following treatment with hyaluronic acid filler.	CR
Patients with active infection in the treatment region should not be treated.	CR
Herpes prophylaxis with an antiviral agent is recommended in patients with a history of herpes infection.	CR
Patients with a history of severe cold sores (HSV) should be prescribed antiherpes medication prophylactically before treatment when injections in vulnerable areas are planned.	
Practitioners should use clinical judgment in advising patients to temporarily discontinue immune modulators, anticoagulants, and/or drugs or supplements with anticoagulant properties before treatment with hyaluronic acid fillers. Anticoagulation should not be ceased without consultation with the treating physician.	CR
Following treatment with a hyaluronic acid filler, it is generally advisable to avoid strenuous exercise (heart rate >100 bpm) for 24 hr to reduce the risk of posttreatment complications.	CR
No single injection technology (needle, cannula) ensures complete safety.	PS
The applicability and validity of antegrade and retrograde injection techniques are recognized.	CR
Blunt cannulas were more recommended by the panelists in vascular complication areas.	PS
Aspiration before injection has been suggested as a strategy to prevent vascular occlusion, especially in high-risk areas (e.g., glabella). However, clinicians should not rely on negative aspiration to rule out the risk of intravascular injection.	CR
Hyaluronic acid fillers should be injected slowly under low pressure with the needle or cannula constantly moving.	CR
Strategies to minimize the risk of complications with hyaluronic acid fillers include the following:	CR
Know injection anatomy	
Aspirate before injecting in higher risk areas	
Slowly inject with the least amount of pressure	
Move tip with delivery of product	
Incrementally inject 0.1–0.2 ml of product	
Use a small syringe to deliver precise aliquots	
Use a small needle to slow injection speed	
Use blunt microcannulas	
Apply proper patient selection criteria	
Stop injecting if resistance is encountered or the patient experiences pain/discomfort	
Always monitor the patient	
In cases of intravascular occlusion, hyaluronidase should be injected where signs and symptoms are present (e.g., livedo reticularis-like appearance) and where the vasculature appears compromised.	CR
In cases of intravascular occlusion, a minimum of 200–300 U of hyaluronidase spread over the entire area of impending necrosis should be injected and repeated daily (minimum of 2 days) until signs of permanent necrosis or reestablished blood flow appear. A larger dose should be used if needed (doses of 500–1500 U were suggested), because the consequence of inadequate dosing is tissue necrosis. Reassess every 24 hr.	CR
Use of topical nitroglycerin (1%) paste may be an advantage in cases of arterial obstruction.	CR
Appropriate hyaluronidase dosage in cases of nonintravascular obstruction include:	CR
<2.5 mm area: 10–20 U, single injection point; repeat injection if required.	
2.5 mm–1 cm: 2–4 injection points with 10–20 U per injection point; repeat injection if required.	
If clinical indications of infection are present, hyaluronidase should not be injected unless the patient is on antibiotic treatment already or intravascular occlusion is suspected, in which case hyaluronidase should be started immediately.	CR
The incidence of biofilm creation is low with hyaluronic acid fillers.	PS
Antibiotic therapy should be prescribed initially in the presence of signs/symptoms of acute infection, and clinical judgment should inform subsequent decision to save the implant for aesthetic correction or inject hyaluronidase to avoid recurrence of infection.	CR
Overt and covert infection should be ruled out before injection of steroids.	CR
For acute early infections, appropriate empiric antibiotic treatment can include amoxicillin plus clavulanate, or cephalexin, or ciprofloxacin (in case of penicillin allergy).	CR
For late inflammatory nodules or granuloma, possible empiric antibiotic therapy includes clarithromycin plus moxifloxacin, or ciprofloxacin, or minocycline.	CR
Practitioners may consider use of an oral steroid when medically appropriate (e.g., after antibiotic treatment in cases of multiple chronic cold nodules).	CR

CR, Consensus Recommendation (agreed on by at least two-thirds of panel members); PS, Position Statement (agreed on by a majority, but less than two-thirds, of panel members); HSV, herpes simplex virus.

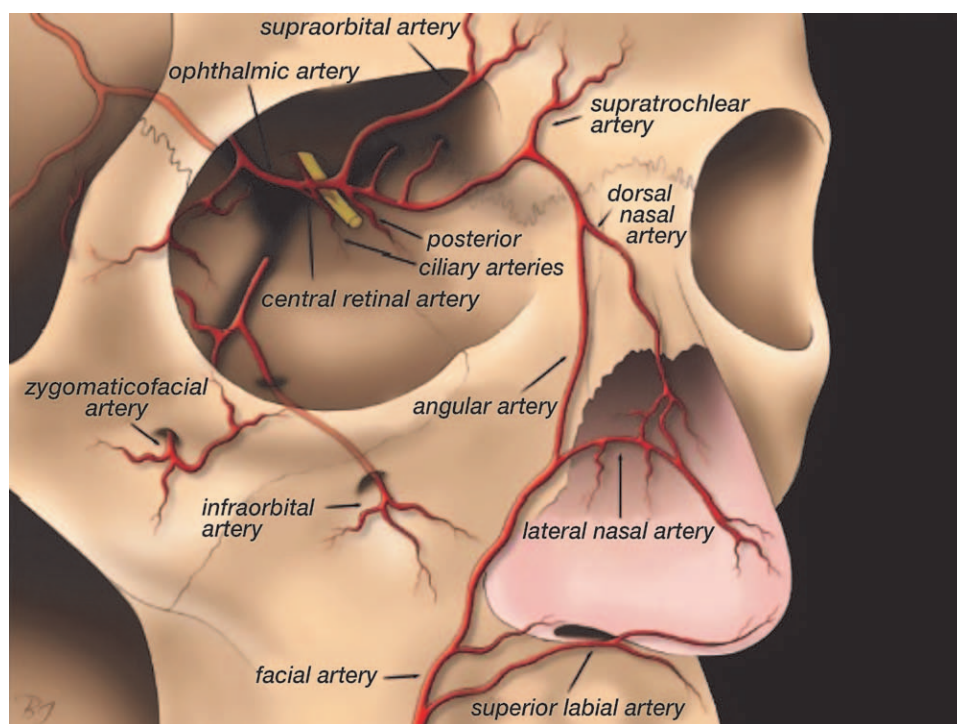


Fig. 1. Schematic drawing of anatomy, distribution, and connections between the ophthalmic and facial arterial systems. (Used with permission from Lazzeri D, Agostini T, Figus M, Nardi M, Pantaloni M, Lazzeri S. Blindness following cosmetic injections of the face. *Plast Reconstr Surg.* 2012;129:995–1012.)

erythema, pain on injection or in the days following) and wherever the vasculature appears compromised, not only at the site of injection (“flood the field”). A recent bench study supports injection of hyaluronidase diffusely into ischemic tissue.²³ As hyaluronidase is useful in the management of many complications that may arise from hyaluronic acid fillers, clinicians should always have it readily available if permitted by local regulatory or legal statutes. However, injectors should always bear in mind the possibility of allergic reactions following its use.²⁴

For intravascular infarction, the panel recommended injection of a minimum of 200 to 300 U of hyaluronidase (spread over the entire area of impending necrosis), repeated daily for a minimum of 2 days until signs of permanent necrosis or reestablished blood flow appear. Doses up to 1500 U were suggested if needed, because the consequence of inadequate dosing is tissue necrosis. The patient should be reassessed every 24 hours. If infection arises, antibiotic therapy should be started immediately. Use of topical nitroglycerin (1%) paste is also recommended in cases of obstruction (Table 4). Other strategies (without proven efficacy) include systemic or topical steroids, aspirin, low-molecular-weight heparin, hyperbaric oxygen, and intravenous

prostaglandins. Measures to improve retinal perfusion described in the literature (albeit with limited success) include immediate ophthalmologic consultation, ocular massage, timolol eye drops, hyperbaric therapy/oxygen, diuretics, systemic and topical corticosteroids, anticoagulation, and needle decompression of the anterior chamber.⁶

Allergic Reactions/Hypersensitivity

Treatment of hyaluronic acid filler–related hypersensitivity depends on severity. In many cases, it may be self-limiting and resolve spontaneously after a few hours or days. Swelling may respond to antihistamines if mast cell–mediated. Oral steroids are the mainstay of treatment for persistent edema or edema that does not respond to antihistamines. Rapidly progressing angioedema should be considered a medical emergency because of possible airway obstruction. Delayed hypersensitivity reactions usually resolve without sequelae, but depending on the presentation, oral steroid treatment may be required.^{5,7} If possible, the allergen should be removed.

Early Acute Infection

The panel recommended a hierarchy or sequence of treatment options for early acute

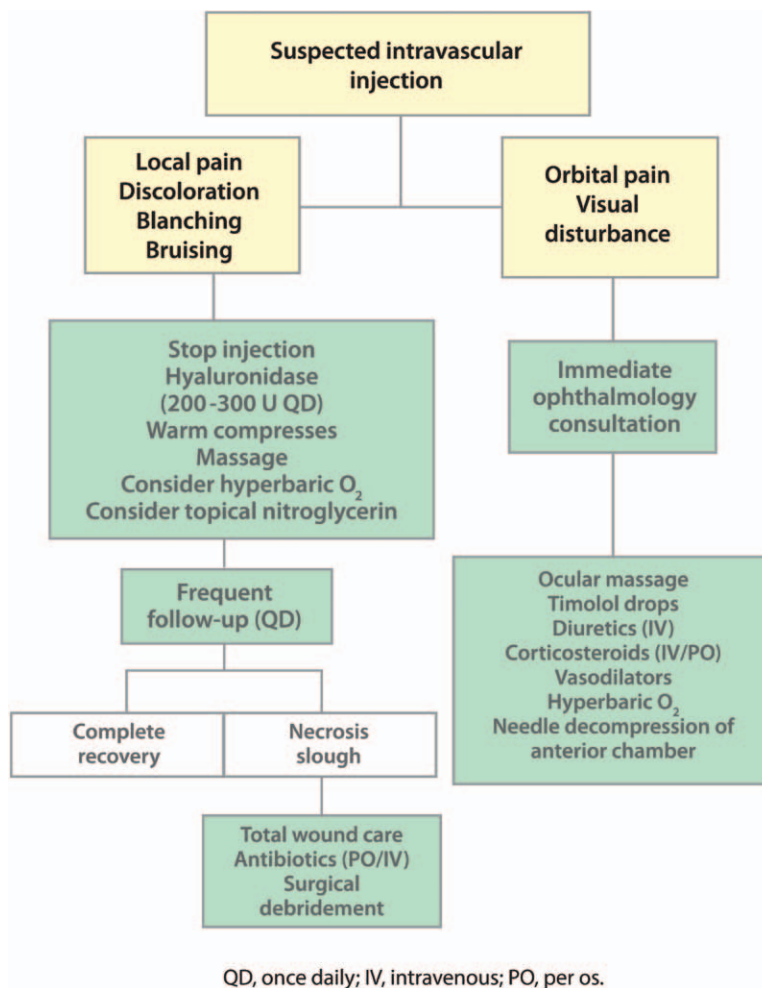


Fig. 2. Algorithm for treatment of suspected intravascular injection with dermal filler. QD, every day; O₂, oxygen; IV, intravenous; PO, per os (orally).

infections, as follows: antibiotics (empiric), then consider hyaluronidase, then consider steroids. An algorithm for the treatment of mild to moderate early and late complications is presented in Figure 3.

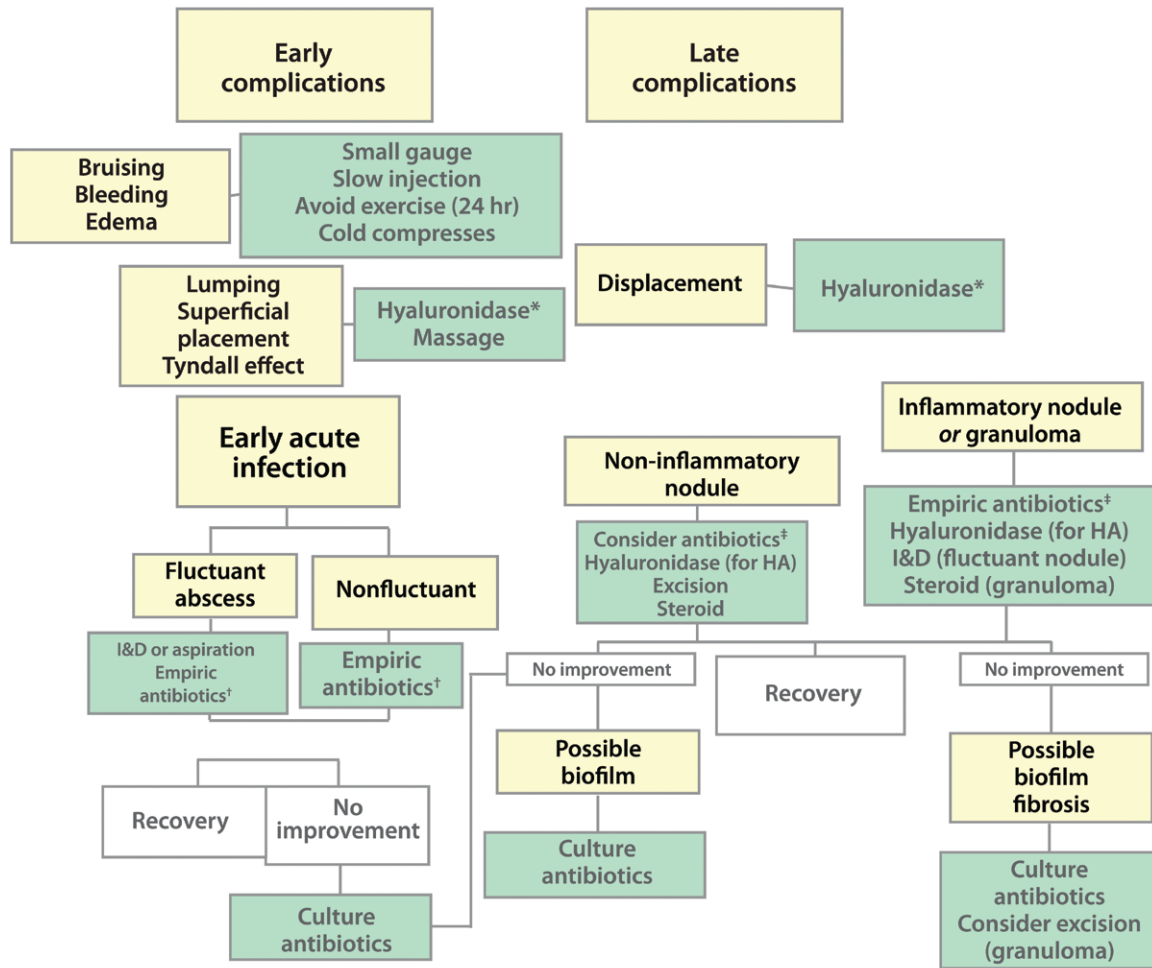
Antibiotic therapy should be prescribed if signs or symptoms of acute bacterial infection are present; clinical judgment should guide subsequent decisions to save the implant for aesthetic correction or inject hyaluronidase to avoid recurrence of infection. A multiprong approach using both antibiotics and antiviral agents is reasonable when the cause is uncertain and laboratory support is lacking.²²

Culture-directed antibiotic selection is impractical for initial therapy. The recommended initial empiric therapy for both fluctuant and nonfluctuant infections includes amoxicillin plus clavulanate, or cephalexin, or in the case of penicillin allergy, ciprofloxacin. For abscesses, incision and drainage or aspiration

remains the tenet of proper surgical treatment. If empiric antibiotic therapy is unsuccessful, culture-directed therapy should be considered. Subsequent use of hyaluronidase may be considered when the infection is quiescent. If infection is clinically present, hyaluronidase should only be injected in association with antibiotic treatment to avoid spreading the infected material. Overt and covert infection should be ruled out before injection of intralesional steroids is considered for inflammatory nodules.

Injection-Related Events

Appropriate injection techniques help limit the risk of adverse reactions and contour irregularities.⁸ Increased dissection of the subepidermal plane may be related to local adverse events²⁵; however, in the panel's opinion, there is insufficient evidence to conclude that a specific modality is associated with more complications.



HA, hyaluronic acid; I&D, incision and drainage.

<p>*Recommended hyaluronidase schema:</p> <ul style="list-style-type: none"> • <2.5 mm area: 10 to 20U single injection; repeat injection if required • 2.5 mm to 1 cm: 2 to 4 injection points with 10 to 20 U per injection point; repeat injection if required 	<p>†Recommended empiric antibiotic therapy:</p> <ul style="list-style-type: none"> • Amoxicillin + clavulanate <i>or</i> • Cephalexin <i>or</i> • Ciprofloxacin 750 mg twice daily for 1 week (if penicillin allergy) <p>Both antibiotic and antiviral therapy are reasonable options when etiology is uncertain</p>	<p>‡Recommended empiric antibiotic therapy:</p> <ul style="list-style-type: none"> • Clarithromycin 500 mg + moxifloxacin 400 mg twice daily for 10 days <i>or</i> • Ciprofloxacin 500 to 750 mg twice daily for 2 to 4 weeks <i>or</i> • Minocycline 100 mg once daily for 6 months
--	---	---

Fig. 3. Algorithm for treatment of early and late mild to moderate complications following dermal filler injections. HA, hyaluronic acid; I&D, incision and drainage. (Algorithm based on Global Aesthetics Consensus Group recommendations and literature sources: Ozturk CN, Li Y, Tung R, Parker L, Piliang MP, Zins JE. Complications following injection of soft-tissue fillers. *Aesthet Surg J.* 2013;33:862–877; Funt D, Pavicic T. Dermal fillers in aesthetics: An overview of adverse events and treatment approaches. *Clin Cosmet Investig Dermatol.* 2013;6:295–316; and Bailey SH, Cohen JL, Kenkel JM. Etiology, prevention, and treatment of dermal filler complications. *Aesthet Surg J.* 2011;31:110–121.)

To help minimize bruising and bleeding, practitioners should use clinical judgment in advising patients to temporarily discontinue immune modulators, anticoagulants, and/or drugs or supplements with anticoagulant properties before treatment. (Note: anticoagulation should not be discontinued without consultation with the treating physician.) Injections are only relatively contraindicated in patients taking therapeutic anticoagulants, as meticulous slow-injection technique using small needles/cannulas and immediate prolonged pressure will limit bruising.

Following treatment, it is generally advisable to avoid strenuous exercise for 24 hours to reduce the risk of bruising and swelling. Other steps include using the smallest gauge needle practicable or blunt cannulas, slow injection of small aliquots, avoiding reinjections in the same areas to avoid lidocaine-induced vasodilatation, and limiting the number of transcutaneous puncture sites. Immediate application of pressure rather than cold therapy remains the mainstay of bruising prevention; however, cold compresses may be used.¹⁵ Some panel members noted use of pulse dye laser if bruising appears.²⁶

Inappropriate Placement

Lumps, asymmetries, or contour deformities occurring in the early posttreatment period may respond to massage. Needle aspiration or minimal stab wound incision with evacuation may be options. A benefit of hyaluronic acid fillers is that irregularities can be reversed with hyaluronidase, a feature that fillers of other types do not share.^{5,7,9,22} However, considering the risk of possible allergic reactions, its use should be limited. Appropriate technique will allow use of the enzyme in emergencies only. The panel recommended the following hyaluronidase schema:

- Less than 2.5-mm area: 10 to 20 U single injection; repeat injection if required.
- Area of 2.5 mm to 1 cm: two to four injection points with 10 to 20 U per injection point; repeat injection if required.

However, the panel indicated that physicians should use clinical judgment while the dosage is titrated to effect. Indeed, the units of hyaluronidase required to dissolve a given amount of hyaluronic acid also depend on the product itself. Not all hyaluronic acids on the market respond equally to hyaluronidase.²⁷ Treatment of edema and of the Tyndall effect, which may follow lower eyelid applications, consists of injecting hyaluronidase

into the surrounding tissue followed by gentle massage. The schema above can guide dosing. Only modest pressure should be applied to disperse hyaluronidase over the area.

TREATMENT OF LATE COMPLICATIONS

Displacement

Displacement of hyaluronic acid filler products, mainly caused by intramuscular placement, can also be treated with hyaluronidase using the same schema above.²⁸

Late Chronic Infections

In the opinion of the panel, a sequence of treatment options similar to that in early acute infection should be followed: antibiotics (empiric), then hyaluronidase, then steroids. Appropriate antibiotic treatment includes a third- or fourth-generation cephalosporin (e.g., cefixime).

Inflammatory Nodules or Granuloma

Sclafani and Fagien advise incision and drainage and antibiotic treatment of fluctuant nodules,⁹ and empiric antibiotic therapy followed by reevaluation for nonfluctuant nodules; if there is no improvement, biopsy and culture are indicated. The panel recommended the following empiric antibiotic schema: clarithromycin 500 mg plus moxifloxacin 400 mg twice daily for 10 days, or ciprofloxacin 500 to 750 mg twice daily for 2 to 4 weeks, or minocycline 100 mg once daily for 6 months.

Culture should guide subsequent antibiotic selection. If no diagnosis is made, addition of a macrolide should be considered for an additional 2 to 4 weeks. Once signs of infection subside, consider hyaluronidase and a steroid.

Granulomatous reactions to hyaluronic acid fillers can be treated with hyaluronidase with the dosing described as above. Empiric antibiotic therapy should be considered. Granulomas may respond to oral or intralesional steroids after infection is ruled out or quiescent. An intralesional steroid may be used in combination with hyaluronidase. In cases of repeated failure of other therapies, surgical excision is the treatment of choice for foreign-body granuloma. The literature also contains description of laser-assisted evacuation of filler material and inflammatory and necrotic debris of granulomata.²⁹

Noninflammatory Nodules

Strategies for the treatment of noninflammatory nodules include removal of the causative

agent and consideration of empiric antibiotic treatment. Short-term temporary measures such as a steroid may be appropriate in limited clinical circumstances.

The panel stressed the importance of clinical judgment in selecting suitable treatment approaches. For example, hyaluronidase was considered an appropriate option for a single cold nodule of 3 months' duration. For multiple cold nodules of similar duration, the panel considered a course of antibiotic therapy for several weeks followed by hyaluronidase as the most appropriate approach. Use of short-term systemic steroids was also discussed by some panelists.

OVERALL SUMMARY AND CONCLUSIONS

Because hyaluronic acid fillers are minimally immunogenic and can be enzymatically degraded by hyaluronidase, they have become the most common of the temporary fillers on the market. Hyaluronic acid dermal fillers are today established as the preferred material for minimally invasive cosmetic interventions. However, early and late complications ranging from minor to severe can occur with hyaluronic acid fillers, and the risk profile may be changing as the treatment landscape evolves. Optimal complication management remains an unmet need in the field of aesthetic medicine. The cosmetic physician should be suitably experienced to select and use hyaluronic acid fillers. As such, they should have a detailed understanding of facial anatomy, practice appropriate patient and product selection, and possess knowledge of correct preparation and injection techniques. Most adverse events are avoidable with proper planning and technique. Should adverse reactions occur, the clinician should have the tools available and be prepared to confidently treat them. Proper preparations for emergencies should reduce the severity of adverse outcomes associated with injection of hyaluronic acid fillers in the cosmetic setting.

Massimo Signorini, M.D.
Via Solferino 22
Milano 20121, Italy
maxplast@libero.it

ACKNOWLEDGMENT

The authors express their deep appreciation to John F. Kross, M.Sc., D.M.D., of Educational Awareness Solutions, for editorial support.

APPENDIX: GLOBAL AESTHETICS CONSENSUS GROUP

The Global Aesthetics Consensus Group comprises the following faculty members: André Vieira Braz, M.D., dermatology, Rio de Janeiro, Brazil; Jean D. A. Carruthers, F.R.C.S.(C), F.R.C.Ophth., ophthalmology, Vancouver, British Columbia, Canada; Koenraad L. De Boule, M.D., dermatology, Aalst, Belgium; Steven Fagien, M.D., ophthalmic plastic surgery, Boca Raton, Fla.; Greg J. Goodman, M.D., dermatology, Carlton, Victoria, Australia; Soo-Keun Lee, M.D., Ph.D., dermatology, Seoul, Republic of Korea; Steven Liew, M.B.B.S., plastic surgery, Sydney, New South Wales, Australia; Gary Monheit, M.D., dermatology, Birmingham, Ala.; Hervé Raspaldo, M.D., facial plastic surgery, Cannes, France; Rod J. Rohrich, M.D., plastic surgery, Dallas, Texas; Gerhard Sattler, M.D., dermatology, Darmstadt, Germany; Massimo Signorini, M.D., plastic surgery, Milan, Italy; Hema Sundaram, M.D., dermatology, Rockville, Md.; Arthur Swift, M.D., C.M., plastic surgery, Montreal, Quebec, Canada; Ada R. Trindade de Almeida, M.D., dermatology, Sao Paulo, Brazil; and Yan Wu, M.D., Ph.D., dermatology, Beijing, People's Republic of China.

REFERENCES

1. American Society for Aesthetic Plastic Surgery (ASAPS). 2014 Cosmetic Surgery National Data Bank statistics. Available at: <http://www.surgery.org/sites/default/files/2014-Stats.pdf>. Accessed June 21, 2015.
2. Alam M, Dover JS. Management of complications and sequelae with temporary injectable fillers. *Plast Reconstr Surg*. 2007;120(Suppl):98S-105S.
3. Friedman PM, Mafong EA, Kauvar AN, Geronemus RG. Safety data of injectable nonanimal stabilized hyaluronic acid gel for soft tissue augmentation. *Dermatol Surg*. 2002;28:491-494.
4. Narins RS, Jewell M, Rubin M, Cohen J, Strobos J. Clinical conference: Management of rare events following dermal fillers. Focal necrosis and angry red bumps. *Dermatol Surg*. 2006;32:426-434.
5. Ozturk CN, Li Y, Tung R, Parker L, Piliang MP, Zins JE. Complications following injection of soft-tissue fillers. *Aesthet Surg J*. 2013;33:862-877.
6. Lazzeri D, Agostini T, Figus M, Nardi M, Pantaloni M, Lazzeri S. Blindness following cosmetic injections of the face. *Plast Reconstr Surg*. 2012;129:995-1012.
7. Glaich AS, Cohen JL, Goldberg LH. Injection necrosis of the glabella: Protocol for prevention and treatment after use of dermal fillers. *Dermatol Surg*. 2006;32:276-281.
8. Bailey SH, Cohen JL, Kenkel JM. Etiology, prevention, and treatment of dermal filler complications. *Aesthet Surg J*. 2011;31:110-121.
9. Sclafani AP, Fagien S. Treatment of injectable soft tissue filler complications. *Dermatol Surg*. 2009;35(Suppl 2):1672-1680.
10. Bogdan Allemann I, Baumann L. Hyaluronic acid gel (Juvéderm) preparations in the treatment of facial wrinkles and folds. *Clin Interv Aging* 2008;3:629-634.
11. Stocks D, Sundaram H, Michaels J, Durrani MJ, Wortzman MS, Nelson DB. Rheological evaluation of the physical

- properties of hyaluronic acid dermal fillers. *J Drugs Dermatol*. 2011;10:974–980.
12. Baumann LS, Shamban AT, Lupo MP, et al.; Juvederm vs. Zyplast Nasolabial Fold Study Group. Comparison of smooth-gel hyaluronic acid dermal fillers with cross-linked bovine collagen: A multicenter, double-masked, randomized, within-subject study. *Dermatol Surg*. 2007;33(Suppl 2):S128–S135.
 13. Boogaard PJ, Denneman MA, Van Sittert NJ. Dermal penetration and metabolism of five glycidyl ethers in human, rat and mouse skin. *Xenobiotica* 2000;30:469–483.
 14. De Boulle K, Glogau R, Kono T, et al. A review of the metabolism of 1,4-butanediol diglycidyl ether-crosslinked hyaluronic acid dermal fillers. *Dermatol Surg*. 2013;39:1758–1766.
 15. Funt D, Pavicic T. Dermal fillers in aesthetics: An overview of adverse events and treatment approaches. *Clin Cosmet Investig Dermatol*. 2013;6:295–316.
 16. Rohrich RJ, Monheit G, Nguyen AT, Brown SA, Fagien S. Soft-tissue filler complications: The important role of biofilms. *Plast Reconstr Surg*. 2010;125:1250–1256.
 17. Alhede M, Er Ö, Eickhardt S, et al. Bacterial biofilm formation and treatment in soft tissue fillers. *Pathog Dis*. 2014;70:339–346.
 18. De Boulle K. Management of complications after implantation of fillers. *J Cosmet Dermatol*. 2004;3:2–15.
 19. Zielke H, Wölber L, Wiest L, Rzany B. Risk profiles of different injectable fillers: Results from the Injectable Filler Safety Study (IFS Study). *Dermatol Surg*. 2008;34:326–335; discussion 335.
 20. Yokoe DS, Mermel LA, Anderson DJ, et al. A compendium of strategies to prevent healthcare-associated infections in acute care hospitals. *Infect Control Hosp Epidemiol*. 2008;29(Suppl 1):S12–S21.
 21. Pratt RJ, O'Malley B. Supporting evidence-based infection prevention and control practice in the National Health Service in England: The NHS/TVU/Intuition Approach. *J Hosp Infect*. 2007;65(Suppl 2):142–147.
 22. DeLorenzi C. Complications of injectable fillers, part I. *Aesthet Surg J*. 2013;33:561–575.
 23. DeLorenzi C. Transarterial degradation of hyaluronic acid filler by hyaluronidase. *Dermatol Surg*. 2014;40:832–841.
 24. Cohen JL, Biesman BS, Dayan SH, et al. Treatment of hyaluronic acid filler-induced impending necrosis with hyaluronidase: Consensus recommendations. *Aesthet Surg J*. 2015;35:844–849.
 25. Glogau RG, Kane MA. Effect of injection techniques on the rate of local adverse events in patients implanted with nonanimal hyaluronic acid gel dermal fillers. *Dermatol Surg*. 2008;34(Suppl 1):S105–S109.
 26. Morton LM, Smith KC, Dover JS, Arndt KA. Treatment of purpura with lasers and light sources. *J Drugs Dermatol*. 2013;12:1219–1222.
 27. Jones D, Tezel A, Borrell M. In vitro resistance to degradation of hyaluronic acid fillers by ovine testicular hyaluronidase. *Dermatol Surg*. 2010;36:804–809.
 28. Lemperle G, Rullan PP, Gauthier-Hazan N. Avoiding and treating dermal filler complications. *Plast Reconstr Surg*. 2006;118(Suppl):92S–107S.
 29. Cassuto D, Marangoni O, De Santis G, Christensen L. Advanced laser techniques for filler-induced complications. *Dermatol Surg*. 2009;35(Suppl 2):1689–1695.