

## Pregnancy and delivery in a patient with a Studer orthotopic ileal neobladder

Anna Kołodziej<sup>1</sup>, Wojciech Krajewski<sup>1</sup>, Krzysztof Tupikowski<sup>1</sup>, Bartosz Małkiewicz<sup>1</sup>, Janusz Dembowski<sup>1</sup>, Mariusz Zimmer<sup>2</sup>, Tomasz Szydełko<sup>3</sup>, Romuald Zdrojowy<sup>1</sup>

<sup>1</sup>Urology and Urologic Oncology Department, Wrocław Medical University, Wrocław, Poland

<sup>2</sup>2<sup>nd</sup> Department and Clinic of Gynaecology, and Obstetrics, Wrocław Medical University, Wrocław, Poland

<sup>3</sup>Department of Palliative Care Nursing, Wrocław Medical University, Wrocław, Poland

**Citation:** Kołodziej A, Krajewski W, Tupikowski T, et al. Pregnancy and delivery in a patient with a Studer orthotopic ileal neobladder. Cent European J Urol. 2016; 69: 431-433.

### Article history

Submitted: June 27, 2016

Accepted: Sept. 26, 2016

Published online: Nov. 30, 2016

### Corresponding author

Wojciech Krajewski

Department of Urology  
and Oncological Urology  
213, Borowska Street

50-556 Wrocław, Poland

phone: +48 71 733 10 10

wk@softstar.pl

Pregnancies in patients after cystectomy with urinary diversion, especially after the construction of a continent urinary reservoir, are rare. Experience in this field is limited and mainly concerns patients with congenital disorders, neurogenic diseases or trauma.

In this paper, we report the outcome of pregnancy, delivery and the postpartum period in a 27-year old woman with a Studer ileal orthotopic neobladder after radical cystectomy, performed after the diagnosis of a malignant tumor at the age of 14.

**Key Words:** cesarean section ◊ ileal orthotopic neobladder ◊ cystectomy

## INTRODUCTION

Over the last three decades, orthotopic bladder substitution has become a commonly performed procedure following radical cystectomy. However, to our knowledge, only one case of pregnancy and child-birth has been described in a patient with an orthotopic ileal neobladder (Hautmann modification) and there are only two reports of patients who have had radical cystectomy and urinary diversion performed due to malignant tumors [1, 2, 3].

Experience with pregnancy after urinary diversion, especially after the construction of a continent urinary reservoir, is still limited and is related mainly to patients with congenital disorders, neurogenic diseases or trauma. Most patients received wet ileal conduits, enterocystoplasty, ureterosigmoidostomy or an intestinal urinary reservoir (Kock

pouch, Mainz pouch, Indiana pouch). We are the first to report the pregnancy, delivery and postpartum period in a patient with a Studer ileal orthotopic neobladder, who had undergone radical cystectomy due to a malignant tumor.

## CASE PRESENTATION

Signed informed consent for case report publication was obtained from the patient. A 27-year old female underwent radical cystectomy and the creation of a Studer orthotopic ileal neobladder [4], as a result of rhabdomyosarcoma diagnosed at the age of 14. Two additional surgical procedures (transabdominal and transvaginal repairing-operations of fistulae between the orthotopic neobladder and vagina) were performed shortly after the patient had undergone cystectomy. After said operations, the patient

was under constant urologic outpatient department surveillance. She had a continent neobladder with normal capacities. Renal function was normal. Pre-conception consultation was provided to the patient regarding the potential problems associated with pregnancy and delivery in her specific case. Since the confirmation of pregnancy, she had been under close urological and obstetric observation.

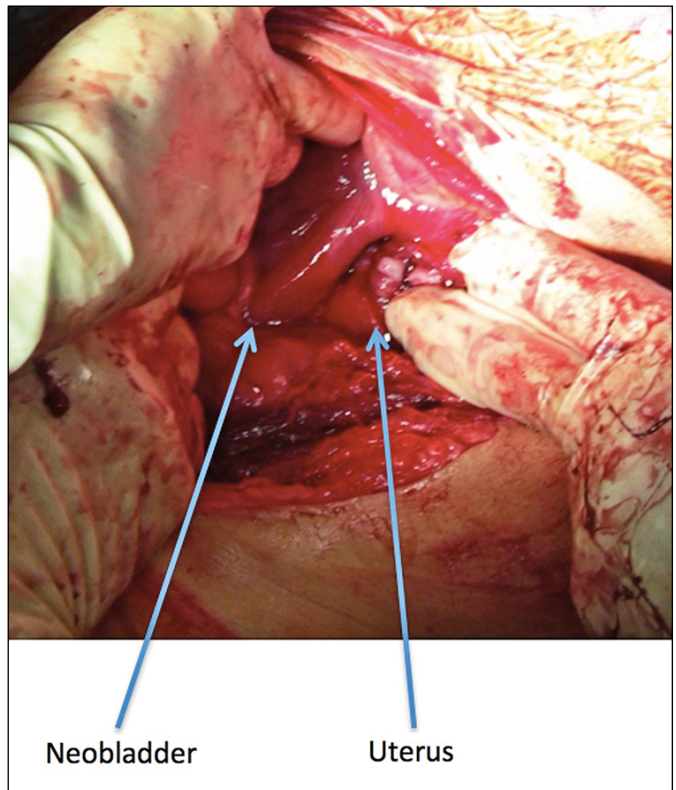
During the pregnancy, difficulties with neobladder emptying were observed. At the 16<sup>th</sup> week of pregnancy, slight upper and right side dislocation of the ileal bladder was identified during ultrasonography (USG). As a result of which, the patient started performing Clean Intermittent Self-Catheterisation (CIC).

Mild left renal dilatation was first noticed during USG examination two weeks later.

At the 21<sup>st</sup> week, flank pain and fever occurred, with high-grade left ureterohydronephrosis. On account of suspected pyelonephritis, we were forced to insert a left nephrostomy catheter and to administer antibiotics intravenously. Clinical improvement was achieved within a few days.

During the second and the third trimester of pregnancy, the patient had several urinary tract infections, successfully treated in accordance with antibiogram results. Neither disturbances in acid-base balance nor bowel abnormalities were observed. Renal function remained stable until the conclusion of pregnancy. With the appearance of regular uterine contractions at the 37<sup>th</sup> week of gestation, the decision was made to perform an elective Cesarean section under continuous epidural anesthesia. In order to access the uterus, a lower midline incision was performed and the rectus fascia opened. As priorly expected, following the separation of the rectus muscle, it was noted that the lower uterine segment, a typical site of access during a cesarean section, was completely covered by the neobladder. Therefore, to avoid neobladder impairment, the section at the lower segment was abandoned, performing an upper segment cesarean section instead. After delivering the fetus and removing the placenta, the uterus was closed using single layer suturing (Figure 1).

As a result of the significantly altered anatomy in the abdominal cavity and potential problems with hemostasis control, it was decided to occlude temporarily the internal iliac arteries. Before the operation, introducer catheters Flexor Check-Flo (COOK Inc. Bloomington IN USA) 6F were introduced bilaterally into the internal iliac vessels by inguinal access. Next, embolectomy catheters (HAGMED – Poland) with balloon size consistent with the diameter of the vessels were introduced into the anterior branches of the internal iliac arteries. The balloons were ex-



**Figure 1.** Intraoperative view of the displaced neobladder

panded just before the section. After having performed the section, the balloons were emptied and catheters removed. This procedure was performed by endovascular radiologists. The surgery, conducted by two obstetricians and two urologists, lasted 125 minutes, with blood loss totalling 500 ml. The child was of appropriate birthweight and received 9 and 10 APGAR in the first and fifth minute respectively. One point was deducted from the 1<sup>st</sup> minute APGAR score due to slight cyanosis. No maternal nor neonatal complications were reported during puerperium observation. Normal voiding returned 3 weeks after delivery and the nephrostomy tube was removed one week later, when the symptoms of obstructive uropathy had disappeared.

## DISCUSSION

The first reports of pregnant patients with urinary diversion began to appear in the sixties [5, 6, 7]. These reports concerned mainly patients with wet urinary diversion, enterocystoplasty or ureterosigmoidostomy due to a neurogenic bladder (e.g. myelomeningocele) and bladder extrophy. In 2007, a literature review by Hautmann et al. described 252 pregnancies in 188 women after urinary diversion [1]. Among the pregnant cases, the authors

reported 64 patients with ureterosigmoidostomy, 47 with enterocystoplasty and 57 with an ileal or colon conduit. Akerlund et al. described 3 pregnancies in patients with a Kock reservoir, Kennedy et al. described 4 pregnancies in women with an Indiana Pouch and Schumacher et al. described 6 females with a continent ileocecal reservoir and catheterizable stoma (Mainz Pouch) [5, 8, 9].

Complications and patient care difficulties in pregnancies after continent urinary diversion and catheterizable stoma are rarely described in the literature, currently related to only a several dozen of cases. In our patient, the necessity for CIC arose at a comparable time as in the other reports. Ureterohydronephrosis, symptomatic pyelonephritis, and the need for nephrostomy also occurred at a similar period as in the other papers. Recommendations for antibiotic therapy vary with different authors. In our patient, bacteriuria occurred multiple times during the progression of pregnancy; however, antibiotic therapy was introduced only when other symptoms of infection appeared (fever, elevation of CRP level). Hautman et al. shows that up to 10% of patients may have bowel movement abnormalities due to altered anatomy and multiple adhesions. Our patient did not present with any bowel movement abnormalities or metabolic complications, which are possible after any method of urinary diversion.

Since we expected to find the lower uterine segment to be covered in adhesions to the lower part of the neobladder, and in order not to damage the neobladder, a cesarean section at a higher uterine segment was performed. To prevent bleeding during the procedure, it was decided to occlude the inter-

nal iliac arteries with balloon catheters. Comparably to the other authors, we observed that the elongated mesentery of the neobladder is located more laterally to the right side. Furthermore, the upper part of the uterus extended to the ventral abdominal wall, pushing the neobladder laterally to the right. Consequently, the lower uterine segment was completely covered by the neobladder.

As a result of physiological, long uterus involution, CIC was discontinued 3 weeks after delivery. The nephrostomy tube was removed 4 weeks after delivery, when the involuting uterus stopped exerting pressure on the anastomosis between the ureters and the ileal loop, allowing unimpeded urine flow.

Pregnancy and delivery in patients having undergone continent urinary diversion can be successfully achieved, likewise in patients with a Studer ileal orthotopic neobladder. There are a number of possible complications, however, but the majority of them do not jeopardize the pregnancy and, as such, pregnancy in these patients should not be contraindicated. Such patients should remain under the close surveillance of an interdisciplinary team, comprised of a gynecologist, urologist and a neonatologist. Additionally, genitourinary tract ultrasound examination should be performed at least once a month during the progression of pregnancy.

#### CONFLICTS OF INTEREST

The authors declare no conflicts of interest.

This article does not contain any studies conducted on human or animal subjects performed by any of the authors.

Informed consent was obtained from all individual participants included in the study.

#### References

- Hautmann RE, Volkmer BG. Pregnancy and urinary diversion. *Urol Clin North Am.* 2007; 34: 71-88.
- Kuczkowski KM, Hay B. Peripartum care of the parturient with Indiana continent urinary diversion: a need for a multidisciplinary approach. *Ann Fr Anesth Reanim.* 2004; 23: 927-928.
- Barrett RJ, 2<sup>nd</sup>, Peters WA, 3<sup>rd</sup>. Pregnancy following urinary diversion. *Obstet Gynecol.* 1983; 62: 582-586.
- Studer UE, Ackermann D, Casanova GA, Zingg EJ. Three years' experience with an ileal low pressure bladder substitute. *Br J Urol.* 1989; 63: 43-52.
- Schumacher S, Fichtner J, Stein R, Wiedemann A, Hohenfellner R. Pregnancy after Mainz pouch urinary diversion. *J Urol.* 1997; 158: 1362-1364.
- Asif S, Uehling DT. Successful pregnancy following ureteroileostomy. *Am J Obstet Gynecol.* 1969; 105: 641-642.
- Pedlow PR. Pregnancy associated with uretero-sigmoid anastomosis. *J Obstet Gynaecol Br Emp.* 1961; 68: 822-826.
- Akerlund S, Bokstrom H, Jonsson O, Kock NG, Wennergren M. Pregnancy and delivery in patients with urinary diversion through the continent ileal reservoir. *Surg Gynecol Obstet.* 1991; 173: 350-352.
- Kennedy WA, 2<sup>nd</sup>, Hensle TW, Reiley EA, Fox HE, Haus T. Pregnancy after orthotopic continent urinary diversion. *Surg Gynecol Obstet.* 1993; 177: 405-409. ■