

Interventricular membranous septal aneurysm incidentally diagnosed during computed tomographic angiography in a patient with infrequent supraventricular tachycardia

Munish Sharma,¹ Farhad Elmi²

¹Department of Internal Medicine, Easton Hospital, Easton, PA;

²Department of Cardiology, Easton Hospital and Drexel University College of Medicine, Easton, PA, USA

Abstract

Interventricular membranous septal (IVMS) aneurysm is a rare condition with no accurate incidence. It is known to be associated with 0.3 % of congenital heart disease and 19 % of ventricular septal defects. IVMS aneurysm is often asymptomatic but can be complicated with right ventricular obstruction, rupture, thromboembolism, and conduction defects. Clinicians and radiologist should be aware about this rare clinical entity and evaluation of any possible underlying cardiac abnormalities should be performed. Conservative management with close follow up is the mainstay of management in the absence of complication.

Introduction

IVMS aneurysm is a rare condition with no accurate incidence rate. It is known to be associated with 0.3 % of congenital heart disease and 19 % of ventricular septal defects.¹ IVMS aneurysm is often asymptomatic but can be complicated with right ventricular obstruction, rupture, thromboembolism, and conduction defects.¹ We present an incidental finding of IVMS aneurysm in a patient with supraventricular tachycardia (SVT).

Case Report

A 69-year-old physically active lady with history of SVT for 16 years with infrequent episodes of palpitations managed medically by metoprolol underwent echocardiography because of more frequent episodes of her symptoms. She had refused ablation in the past, as her episodes have been infrequent. She has no history of coro-

nary artery disease and several stress tests have been unremarkable. Echocardiography showed a new aneurysm like area near the right coronary cusp consistent with a possible sinus of Valsalva aneurysm. A subsequent CT angiography revealed an aneurysm measuring 2.2×1.5×1.7 cm arising from the membranous part of interventricular septum. It was found to be extending into the right ventricle without any outflow tract obstruction (Figures 1 and 2). This IVMS aneurysm was determined to be an incidental finding, as it cannot be the cause of long standing SVT in the patient. In absence of complications we decided to manage the patient conservatively. She has remained asymptomatic since its detection 4 months ago except infrequent episodes of SVT. She has been managed with Metoprolol and aspirin. A follow up has been planned for every 6 months.

Discussion

Interventricular septum consists of the membranous part, the inlet, infundibular part and the muscular portion. The greater portion of it is thick and muscular and constitutes the muscular interventricular septum. The mid septal portion, which lacks myocardium, is called membranous septum. It is upper and posterior part of the interventricular septum and separates the aortic vestibule from the lower part of the right atrium and upper part of the right ventricle. The inlet is trabeculated and lies over the inferoposterior portion of the septum. The infundibular septum is located between right and left ventricular tracts.²

Embryological origin of ventricular septum starts during the 5th week of gestation. The muscular part of the interventricular septum derives from the bulboventricular flange, which is developed due to differential growth of primitive ventricle and bulbus cordis. Membranous part has a neural crest origin, which connects the upper free margin of the bulboventricular flange and anterior and posterior endocardial cushions of atrio ventricular canal.³ Absence of myocardium in the membranous region makes it vulnerable to develop IVMS when predisposed to high pressure gradient.¹

Demographics

IVMS is a rare disease, most notably associated with other cardiac anomalies. It occurs in 0.3 % of patients with congenital heart disease, in up to 19-22.4 % with ventricular septal defects and in 20 % with perimembranous ventricular septal defects.^{1,4}

Correspondence: Munish Sharma, 2040 Lehigh Street, apt 506, Easton, PA, USA, 18042.

Tel.: 610.250.4000 (office).

E-mail: munishs1@hotmail.com

Key words: Interventricular membranous septal aneurysm; computed tomographic angiography; supraventricular tachycardia.

Received for publication: 22 October 2016.

Accepted for publication: 30 November 2016.

This work is licensed under a Creative Commons Attribution NonCommercial 4.0 License (CC BY-NC 4.0).

©Copyright M. Sharma and F. Elmi, 2017

Licensee PAGEPress, Italy

Clinics and Practice 2017; 7:921

doi:10.4081/ep.2017.921

Etiology

Etiology of IVMS is poorly understood. It may develop spontaneously or may develop due to spontaneous closure, partial or complete, of a ventricular septal defect.¹ Previous episode of infection or trauma have been reported as well. Allwork *et al.* found IVMS aneurysm in 25 % of the 32 autopsy specimens of congenitally corrected Transposition of great arteries (TGA). Congenitally abnormal positioning of aorta makes it susceptible to the high pressure of the left ventricle with subsequent development of aneurysm.

Types of interventricular membranous septal aneurysm

These aneurysms can be divided as true, false and pseudoaneurysm. Those with regular contours and a wide base are termed true AMS while those with a narrow base and irregular shape are termed false. A pseudo-aneurysm is a generally a complication of ischemic insults or complication of transaortic septal myotomy.

Clinical presentation

Clinical features in IVMS hinge on three main factors: morphology of the bulging aneurysm, associated defects and complications arising from the aneurysm. Most prominent features are fatigue and exertional dyspnea. These symptoms are mainly related to right ventricular dysfunction or left-to-right shunt across VSD may contribute to it. Symptoms such as palpitation may be related to arrhythmia. On examination, due to the bulging of the aneurysmal sac into the right ventricular outflow tract, a cardiac murmur may be heard.⁵ Sub pulmonic stenosis manifest as

right axis deviation, right ventricular hypertrophy and right atrial enlargement in the EKG.

Diagnostic techniques

Conventional left ventriculography: it is a widely used method but it is invasive in nature. It cannot also be beneficial in detecting a thrombus.

Echocardiogram: most often incidentally found in an echocardiography. Detailed morphology cannot be obtained with this modality. It carries a highest sensitivity of 87.5 % in the long axis view but it is as much sensitive in other views. Unfavorable body habitus also poses a hindrance to proper imaging with echocardiogram.

Cardiac magnetic resonance (CMR) imaging: It is non-invasive and is relatively safe and effective. Morphological and functional assessment can be done with this modality. Associated cardiac abnormalities can be effectively determined. It can also be used after surgery to determine the integrity of the patch and also to identify any residual defect.⁶

Multislice CT is a useful diagnostic tool as evidenced by our case. It has similar advantages in terms of morphological and functional assessment of the aneurysm as compared to CMR. Significant exposure to radiation is a drawback of this modality though.

Differential diagnoses

Anatomically related aneurysms and aneurysmal-like structures arising in and around the left ventricular outflow tract like sinus of Valsalva aneurysm are major differentials. In our case also we had initially suspected sinus of Valsalva aneurysm but it did not have its origin above the aortic annulus and there was not a normal dimension of the adjacent aortic root and ascending aorta. Angiography is invaluable in diagnosing aneurysm of sinus of Valsalva. Color Doppler echocardiography is very useful as well.¹

Treatment

Surgical intervention is the mainstay of treatment. It is indicated when there is a concomitant heart disease, hemodynamic abnormalities or complications related to aneurysm. Anticoagulation should be initiated in case of finding a mass in the aneurysm suggestive of thrombus. Surgical resection of the aneurysm is recommended in patients in whom cerebral emboli occur despite optimal anticoagulation. Direct surgical ablations in patients with associated ventricular arrhythmias have shown good results. Direct suture closure of the VSD

with IVMS has not yielded satisfactory results.⁷

Complications

Aortic valve (AV) incompetence occurs mainly because membranous septum and AV are embryologically linked. There may be malformed or mal-adherent aortic valve leaflets in patients with IVMS or there may also be acquired impingement of the IVMS on the septal leaflet. This may also facilitate

tricuspid regurgitation and left-ventricle-to-right-atrium shunt.

Subpulmonic stenosis is the most frequent complication. The stenosis relates to the protrusion of the aneurysm into the right ventricle or the right atrium.

Arrhythmias and complete atrioventricular block is common. Anatomically, the membranous septum lies on an important electric circuit of the heart. Any stretching of the conducting system at the base of the

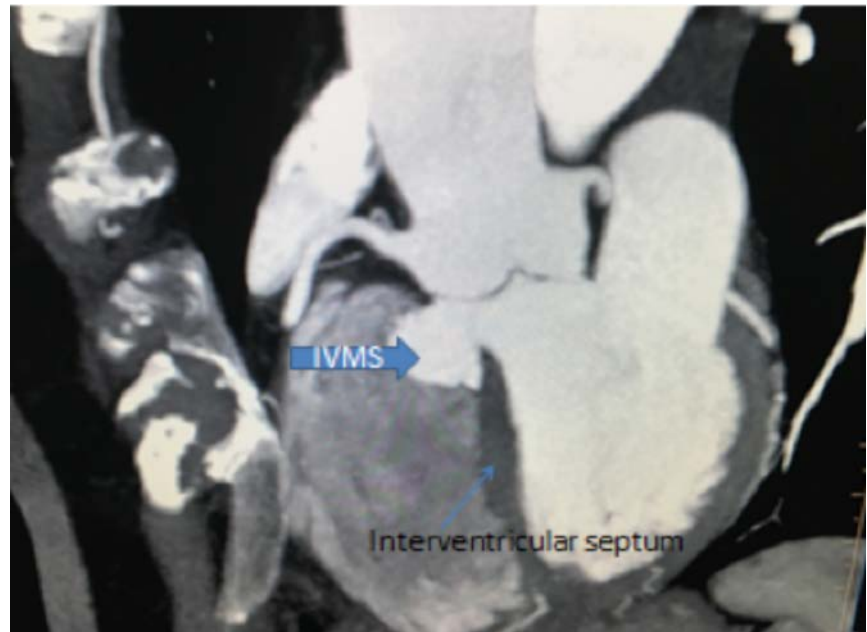

Figure 1. Computed tomographic angiography showing interventricular membranous septal (IVMS) aneurysm (blue arrow): lateral view.

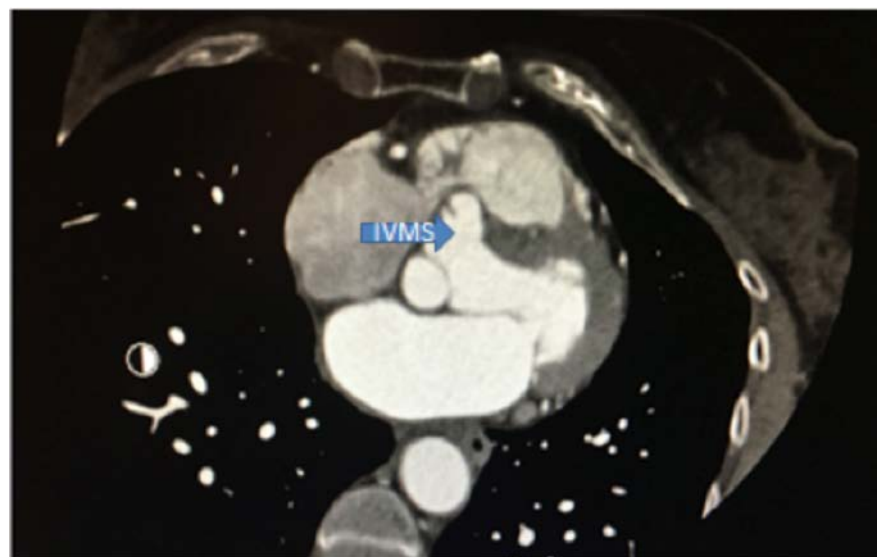


Figure 2. Computed tomographic angiography showing interventricular membranous septal (IVMS) aneurysm (blue arrow): frontal view.

aneurysm can give rise to arrhythmias. Most common arrhythmias are Ventricular tachycardia, bundle branch block and Atrioventricular block.

Thromboembolism occurs due to abnormal movement of the ventricular wall, which predisposes to turbulent flow implicated in thrombosis.

Bacterial endocarditis: high velocity jet of blood streaming through a defect in aneurysm generally predisposes to sterile thrombus, which can host microorganisms.^{1,4,7}

Conclusions

Incidental finding of IVMS aneurysm prompts evaluation for cardiac abnormalities. In absence of complications conservative management with timely follow up along with patient education about potential

complications seems to be the mainstay of management. Clinicians and radiologist should be aware about this rare and clinically obscure entity due to its potential complications.

References

1. Naidu A, Ricketts M, Goela A, et al. Incidental discovery of a membranous ventricular septal aneurysm in two dissimilar patients. *Case Rep Cardiol* 2012;2012:324326.
2. Carcano C, Kanne JP, Kirsch J. Interventricular membranous septal aneurysm: CT and MR manifestations. *Insights Imaging* 2016;7:111-7.
3. Espinoza J, Kalache K, Gonçalves LF, et al. Prenatal diagnosis of membranous ventricular septal aneurysms and their association with absence of atrioventricular valve ‘offsetting’.” *Ultrasound Obstetr Gynecol* 2004;24:787-92.
4. Yilmaz T, Özal E, Arslan M, et al. Aneurysm of the membranous septum in adult patients with perimembranous ventricular septal defect. *Eur J Cardiothor Surg* 1997;11:307-11.
5. Linhart JW, Razi B. Late systolic murmur: a clue to the diagnosis of aneurysm of the membranous ventricular septum. *Chest* 1971;60:283-86.
6. Di Cesare E, Di Sibio A, Lanni G, et al. Magnetic resonance imaging of AMS (aneurysm of the membranous septum), review of the literature and case report. *J Radiol Case Rep* 2014;8:9-15.
7. Yilmaz AT, Ertugrul O, Arslan M, et al. Aneurysm of the membranous septum in adult patients with perimembranous ventricular septal defect. *Eur J Cardiothor Surg* 1997;11:307-11.