

Chikungunya and Myositis: A Case Report in Brazil

HUGO ANDRE MARTINS¹, SILVYA NERY BERNARDINO², CAMILA CORDEIRO SANTOS³, VALDENILSON RIBEIRO RIBAS⁴

ABSTRACT

Chikungunya Virus (CHIKV) is a well-described alpha virus that causes infection in humans. The main symptoms are fever, rash and arthralgia and recently neurological disorders have been reported, in particular encephalitis. It is uncertain whether neurological symptoms are due to persistence of the virus or an ineffective immune response. One rarely described neurologic syndrome is myositis. In this paper, we report the case of a 19-year-old woman with mental confusion and aggressiveness two days after complaints of fever and arthralgia. On clinical evaluation, the patient had power 5/5 in the upper limbs and 3/5 in the lower limbs. Electromyography revealed the presence of myogenic potentials with reduced amplitudes and early recruitment predominantly in the proximal muscle. Two weeks later, she complained of muscle weakness of the lower limbs that started 15 days after acute Chikungunya infection. The patient improved within two months with only supportive care.

Keywords: Arthralgia, Fever, Muscle weakness, Neurological disorder

CASE REPORT

A 19-year-old woman presented to the neurology department with mental confusion and aggressiveness. The mental condition started two days after complaints of fever and arthralgia. The patient lived in a region in which there was a major outbreak of Chikungunya Virus (CHIKV) infection. Five days after receiving supportive measures and anti-psychotic medication (risperidone 2mg), the patient recovered completely from her mental confusion, but two weeks later, she complained of weakness in her legs. The patient walked with some difficulty and was unable to climb stairs or get up from the floor.

On clinical evaluation, the patient had power 5/5 in the upper limbs and 3/5 in the lower limbs. Deep tendon reflexes were slightly reduced but sensory perception was normal.

Serological studies by Enzyme-Linked Immunosorbent Assay (ELISA) were positive for chikungunya IgM antibodies and negative for dengue antibodies. Brain Magnetic Resonance Imaging (MRI) was normal. The patient refused to permit Cerebrospinal Fluid (CSF) tests.

Electromyography revealed the presence of myogenic potentials with reduced amplitudes and early recruitment predominantly in the proximal muscle [Table/Fig-1]. The aldolase, Creatine Phosphokinase (CPK) and Lactate Dehydrogenase (LDH) enzymes were elevated.

The patient improved within two months with only supportive care; weekly evaluations were carried out using the Medical Research Council Scale for muscle strength.

DISCUSSION

CHIKV is a mosquito-borne alphavirus and a very important human pathogen responsible for a disease that is characterised by the triad: fever, arthralgia and rash [1]. Since the Reunion Island outbreak in 2005-2006, many neurologic cases have been reported, mostly of patients with encephalitis [1-3]. Involvement of the peripheral nervous system has been reported less frequently [4]. In 2016, Choudhary et al., reported a case of an 18-year-old who developed myelitis and myositis two weeks after the onset of CHIKV infection [5].

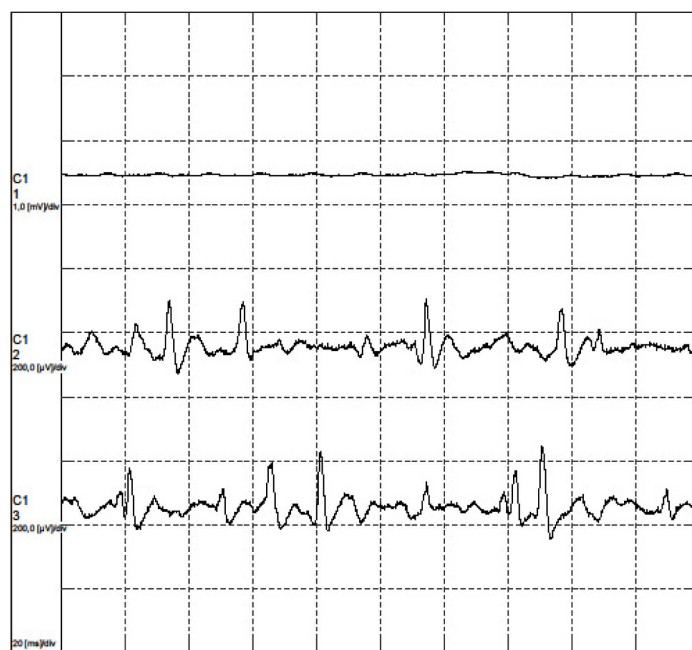
Neurologic manifestations of CHIKV are not as rare as previously thought [1]. Many series reports have been published in the last five years, mostly describing cases of encephalitis, myelitis and more seldom neuritis [1-3].

To the best of our knowledge, this is the first report of the combination of encephalitis and myositis in a patient with CHIKV infection in Brazil. Although the disease is well known, in particular in Asia and Africa, it arrived only relatively recently in South America [1]. An important issue would be how to treat these patients, since, there are no double blind, placebo-controlled studies to suggest the best therapeutic approach to these cases.

The most common neurological manifestations of CHIKV infection, such as encephalitis, seem to have a spontaneous resolution, although older patients have a higher risk of mortality [1].

There are not enough studies to reliably determine the evolution of muscle involvement associated with CHIKV, although it appears that viral myositis in general has a tendency to remission.

The current report describes two phases of infection. In the first, CHIKV caused encephalitis, suggesting a direct attack of the central nervous system by the virus. Subsequently, the muscles were affected suggesting a post-viral reaction. This is very interesting as it is these two mechanisms that are always used to explain



[Table/Fig-1]: Electromyography showing myositis.

neurological involvement in CHIKV infection. The patient had an excellent recovery in respect to both phases of infection.

Choudhary et al., reported a case of the combination of myelitis and myositis in a patient with CHIKV infection two weeks after the onset of fever. The patient was prescribed injectable methylprednisolone followed by oral steroids and there was a slow partial recovery of motor power. Compared to the current patient, it seems the patient described by Choudhary et al., developed more severe neurological impairment as he had symptoms that were more serious and a slower recovery [5].

The chance of large outbreaks of CHIKV around the world is high; especially in developing countries due to the abundance of vectors. Even developed countries such as Italy and France suffered outbreaks at the end of the last decade. The great increase in intercontinental travel and the effects of climate change have helped to spread the virus to regions other than its native areas of Africa and Asia [5-8].

It is important that physicians are aware of all the neurological symptoms of Chikungunya, including the most unusual such as myositis.

CONCLUSION

Neurologic manifestations due to CHIKV infection are not as rare as previously thought. Myositis is a rare manifestation of the disease and in general similar to encephalitis, resolves spontaneously.

REFERENCES

- [1] Martins HAL, Bernardino SN, Ribas KH, Santos CC, Antunes T, Ribas VR, et al. Outbreak of neuro-chikungunya in Northeastern Brazil. *Journal of Neuroinfectious Diseases*. 2016;7(2):1-3.
- [2] Borgherini G, Poubeau P, Staikowsky F, Lory M, Le Moullec N, Becquart JP, et al. Outbreak of chikungunya on reunion island: Early clinical and laboratory features in 157 adult patients. *Clin Infect Dis*. 2007;44(11):1401-07.
- [3] Sane J, Kurkela S, Vapalahti O. Chikungunya, a new global epidemic? *duodecim*. 2011;127(5):457-63.
- [4] Wielanek A, De Monredon J, El Amrani M, Roger J, Serveaux J. Guillain-Barré Syndrome complicating a Chikungunya virus infection. *Neurology*. 2007;69(22):2105-07.
- [5] Choudhary N, Makhija P, Puri V, Khwaja GA, Duggal A. An unusual case of myelitis with myositis. *J Clin Diagn Res*. 2016;10(5):OD19-20.
- [6] Taraphdar D, Roy B, Chatterjee S. Chikungunya virus infection amongst the acute encephalitis syndrome cases in West Bengal, India. *Indian J Med microbiol*. 2015;33(5):153.
- [7] Burt FJ, Rolph MS, Rulli NE, Mahalingam S, Heise MT. Chikungunya: A re-emerging virus. *Lancet*. 2012;379(9816):662-71.
- [8] Bank AM, Batra A, Colorado RA, Lyons JL. Myeloradiculopathy associated with Chikungunya virus infection. *J Neuro Virol*. 2016;22(1):125-28.

PARTICULARS OF CONTRIBUTORS:

1. Professor, Department of Neuropsiquiatria, University Federal of Pernambuco, Recife, Pernambuco, Brazil.
2. Professor, Department of Neuropsiquiatria, University Federal of Pernambuco, Recife, Pernambuco, Brazil.
3. Professor, Department of Neuropsiquiatria, Faculdade Estácio do Recife Recife, Pernambuco, Brazil.
4. Professor, Department of Neuropsiquiatria, University Federal of Pernambuco, Recife, Pernambuco, Brazil.

NAME, ADDRESS, E-MAIL ID OF THE CORRESPONDING AUTHOR:

Dr. Hugo Andre Martins,
Professor, Department of Neuropsiquiatria, University Federal of Pernambuco, Recife, Pernambuco-55750-000, Brazil.
E-mail: hugomt2001@yahoo.com.br

Date of Submission: **Aug 23, 2016**
Date of Peer Review: **Sep 20, 2016**
Date of Acceptance: **Oct 06, 2016**
Date of Publishing: **Dec 01, 2016**

FINANCIAL OR OTHER COMPETING INTERESTS: None.