

# Tuberculosis of Glans Penis- A Rare Presentation

C. GANGALAKSHMI<sup>1</sup>, SANKARAMAHALINGAM<sup>2</sup>

## ABSTRACT

Tuberculosis (TB) of penis is a very rare entity, even in developing countries. It may present as primary or secondary to Pulmonary TB (PTB). Penile TB mimics carcinoma penis, granulomatous penile ulcer, genital herpes simplex, granuloma inguinale and HIV infection. We, hereby, present the case of a 57-year-old male patient who presented to us with ulcerative growth over glans penis and was clinically diagnosed as carcinoma penis, however biopsy of the lesion showed evidence of tuberculosis which was supported by chest X-ray.

**Keywords:** Anti-tuberculous therapy, Penile tuberculosis, Secondary tuberculosis

## CASE REPORT

A 57-year-old male patient presented with complaint of ulcerative growth over his glans penis for duration of six months. It initially started as a small ulcer over dorsal aspect of glans penis measuring around 0.5x0.5cm. It was associated with pain, dysuria and burning micturition. There was no history of trauma, surgery, weight loss, fever, cough or other constitutional symptoms. Patient had history of cough with expectoration and low-grade fever, which was diagnosed as pulmonary tuberculosis. One year back, he was kept on Anti-Tuberculous Therapy (ATT), which was taken for two months only. No history of extramarital contact. On physical examination, an irregular ulcero-proliferative growth of size 3x3 cm was seen occupying both dorsal and ventral surface of glans penis [Table/Fig-1]. Urethral meatus was hidden by the ulcero-proliferative growth. On palpation, tenderness was present, edge and base was indurated. Rest of the genital examination was normal. Bilateral inguinal lymph nodes were enlarged, which were discrete, firm, mobile and non-tender. Patient had bilateral rhonchi and wheeze. Muco-cutaneous examination was normal. Patient's wife was also screened for genital tract infections and found to be normal. Clinically diagnosed as carcinoma penis and biopsy was taken.

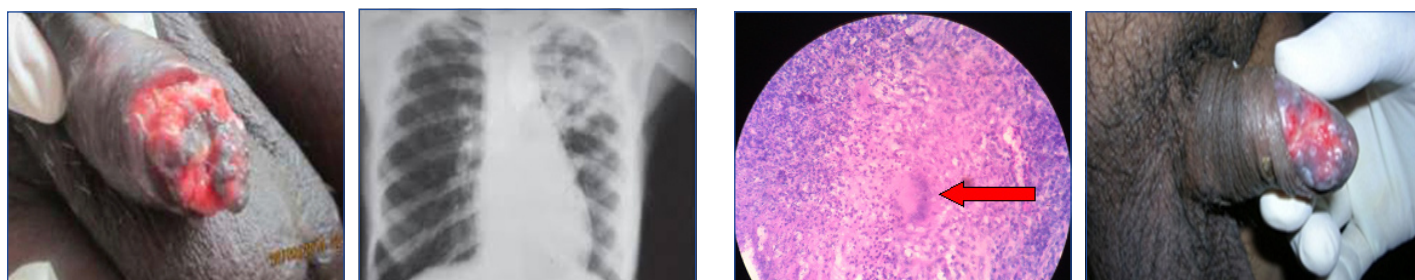
On investigation, complete blood count was normal. ESR was raised (76mm/hr). Blood sugar, serum urea and creatinine were normal. Urine culture showed no growth. Patient was nonreactive for HIV ELISA. Dark field microscopy, *Treponema pallidum* Hemagglutination Assay (TPHA) and Rapid Plasma Reagin (RPR) for *Treponema pallidum* was negative. Tzanck smear for herpes simplex virus was negative. X-ray chest PA view showed left apical fibrosis suggestive of PTB sequelae [Table/Fig-2]. Sputum for AFB and tuberculin test were negative. CT abdomen and pelvis showed bilateral intra renal calculi, ulcerative lesion at the tip of penis without urethral involvement and few reactive inguinal nodes. Initial biopsy from the ulcerative growth showed only inflammatory cells. Repeat biopsy showed epithelioid cell granuloma and Langhan's giant cells suggestive of tuberculoid

granuloma [Table/Fig-3]. FNAC of the lymph node was nonspecific. The patient was registered under RNTCP and put on anti-tubercular treatment, category-II, 2H3R3Z3E3S3 + 1H3R3Z3E3 + 5H3R3E3 H:Isoniazid-600 mg, R:Rifampicin-450 mg, Z:Pyrazinamid-1500 mg, E:Ethambutol-1200 mg, S:Streptomycin-500 mg. Within 3 weeks, patient showed signs of healing [Table/Fig-4]. Follow-up after 2 months showed 60% healed ulcer.

## DISCUSSION

Tuberculosis is still a major cause of morbidity in developing countries like India. An extremely rare form of genitourinary tract tuberculosis will present as tuberculosis of glans penis [1] constituting less than 1% of reported cases worldwide. Epididymis (42%) followed by seminal vesicle (23%), prostate (21%), testis (15%) and vas deferens (12%) are the common sites of presentation [2]. Penile tuberculosis in adults is either primary or secondary. Primary penile tuberculosis are usually acquired either through violent intercourse with female partners with active genital tuberculosis or infected patients own ejaculates or through fomite spread by contact with infected cloths [2]. Few authors also reported primary penile tuberculosis occurred following immunotherapy by BCG vaccination for urinary bladder carcinoma [3]. The secondary form is due to the subsequent complication of lung tuberculosis or TB of other parts of urogenital tract extended through urethra or through haematogenous route. Tuberculosis of penis may affect the skin, glans penis or cavernous bodies. TB affecting the glans penis can be tuberculous chancre, papulo-necrotic tuberculid, tuberculosis cutis orificialis or tuberculous gumma. In most cases, the lesion takes the form of an ulcer, which is difficult to differentiate from malignant tumors. The lesion can be extensive, with the involvement of urethra and corpus cavernosum. Since young adults are affected, their female partner should always be evaluated for genital tuberculosis [4].

Rarely, it may present as a hardened nodule or papulo-necrotic tuberculide. Tuberculide is hypersensitivity reactions to



**[Table/Fig-1]:** Ulcerative lesion over the glans penis. **[Table/Fig-2]:** Chest X-ray showing left apical fibrosis. **[Table/Fig-3]:** H&E stain x40. Microscopic picture of biopsy specimen showing langhans giant cell (red arrow) and epithelioid giant cell granulomas. **[Table/Fig-4]:** Photograph showing healing lesion after 3 weeks of ATT.

*Mycobacterium tuberculosis* or its products in individuals with good immunity. Papulo-necrotic tuberculids are characterized by recurrent eruptions of asymptomatic, dusky red papules, which ulcerate, crust, and heal after a few weeks with varioliform scarring [5]. Penile TB, sometimes, may present as multiple erythematous lesions [6]. Other rare clinical types can be scrofulous gumma and phagedenic infection with destruction of the penis [7]. Papulonecrotic tuberculides are mostly extragenital. These occur symmetrically and predominantly over extensor aspects (legs, knees, elbows, hands and feet) of the extremities. Other areas that may be rarely affected are the ears, face, buttocks, and penis [8].

Our case responded well to ATT. Early institution of ATT in genitourinary TB shows very good response to treatment. A single case of drug-resistant penile TB was reported in spite of aggressive treatment [9].

## CONCLUSION

TB of glans penis is a rare presentation. This case is reported to increase awareness of this curable condition. Though incidence is rare, tuberculosis of glans penis must be excluded if any patient presented with unhealthy, non-healing ulcer in penis. Histopathological examination is essential to differentiate it from carcinoma penis. To

determine whether a TB of glans penis is a primary or a secondary disease, intravenous pyelography and chest X-ray must be done. Antitubercular drugs are the mainstay of treatment.

## REFERENCES

- [1] Sekhon GS, Lal MM, Dhall JC. Tuberculosis of the penis. *J Indian Med Assoc.* 1971;56:316-18.
- [2] Merchant SA. Tuberculosis of the genitourinary system. *Indian J Radiol Imaging.* 1993;3:275-86.
- [3] Sharma VK, Sethy PK, Dogra PN, Singh U, Das P. Primary tuberculosis of glans penis after intravesical Bacillus Calmette Guerin immunotherapy. *Indian J of Dermatol Venerol Leprol.* 2011;77:47-50.
- [4] Pal DK, Kundu AK, Chakraborty S, Das S. Tuberculosis of penis: Report of two cases. *Indian J Tuberculosis.* 1996;43:203-04.
- [5] Jordaan HF, Schneider JW, Schaff HS, Victor TS, Geiger DH, Van Helden PD, et al. Papillonecrotic tuberculoid in children. A report of eight patients. *Am J Dermatopathol.* 1996;18(2):172-85.
- [6] Deb S, Mukherjee S, Seth J, Samanta AB. Nodulo-ulcerative tuberculosis of the glans penis—a case report and a discussion on nomenclature of genital tuberculosis. *Indian Journal of Dermatology.* 2015;60(5):506-08.
- [7] Ramesh V, Ramam M, Pahwa P, Malhotra S. The clinical presentations of penile tuberculosis. *Int J Dermatol.* 2013;52:759-61.
- [8] Alka D, Sunil KG, Anita B. Papulonecrotic tuberculid of the glans penis—a case report. *Journal of Pakistan Association of Dermatologists.* 2005;15:285-87.
- [9] Baveja CP, Vidyandhi G, Jain M, Kumari T, Sharma VK. Drug-resistant genital tuberculosis of the penis in a human immunodeficiency virus non-reactive individual. *J Med Microbiol.* 2007;56(pt 5):694-95.

### PARTICULARS OF CONTRIBUTORS:

1. Assistant Professor, Department of Surgery, Madurai Medical College, Madurai, Tamil Nadu, India.
2. Professor, Department of Surgery, Madurai Medical College, Madurai, Tamil Nadu, India.

### NAME, ADDRESS, E-MAIL ID OF THE CORRESPONDING AUTHOR:

Dr. Sankaramahalingam,  
Professor, Department of Surgery, Dr. M.G.R Medical University,  
Madurai Medical College, Madurai, Tamil Nadu India.  
E-mail: deptofsurgery2013@gmail.com, c-gangalakshmi@yahoo.com

**FINANCIAL OR OTHER COMPETING INTERESTS:** None.

Date of Submission: **Jan 30, 2016**  
Date of Peer Review: **Mar 30, 2016**  
Date of Acceptance: **Oct 04, 2016**  
Date of Publishing: **Dec 01, 2016**