



Contents lists available at ScienceDirect

International Journal of Surgery Case Reports

journal homepage: www.casereports.com

Case report of ovary and fallopian tube as content of a Spigelian hernia – a rare entity



Pralaya Khadka*, Sunil K. Sharma Dhakal

Om Hospital and Research Centre, Nepal

ARTICLE INFO

Article history:

Received 30 November 2016
 Received in revised form 8 January 2017
 Accepted 8 January 2017
 Available online 28 January 2017

Keywords:

Hernia
 Ovary
 Fallopian tube
 Spigelian
 Case report

ABSTRACT

INTRODUCTION: Spigelian hernia is a rare entity, comprising 1–2% of all hernias. Various abdominopelvic viscera herniate through the defect in the Spigelian fascia and become incarcerated. Specifically in females, the ovary and/or the fallopian tube can herniate through this defect. This is the third reported case of such a hernia.

PRESENTATION OF CASE: We report here a young lady aged 30 years with right-sided ovarian Spigelian hernia. She presented with a painful lump in the right lower quadrant of abdomen for 2 weeks. On examination, she had a tender irreducible lump below and to the right lateral to the umbilicus. CECT revealed a right-sided ovarian Spigelian hernia. The finding was confirmed at exploration and herniorrhaphy performed. She was discharged on the 3rd postoperative day.

DISCUSSION: Diagnosing Spigelian hernia clinically is challenging but radiologic investigations like computed tomography help establish the diagnosis and clarify the contents.

CONCLUSION: Spigelian hernia itself is a rare entity and to add to that, herniation of ovary and fallopian tube through Spigelian fascial defect is very rare and a possibility in females.

© 2017 The Author(s). Published by Elsevier Ltd on behalf of IJS Publishing Group Ltd. This is an open access article under the CC BY-NC-ND license (<http://creativecommons.org/licenses/by-nc-nd/4.0/>).

1. Introduction

Spigelian hernias constitute 1–2% of all hernias [1]. The abdominal and/or pelvic organs that can herniate through the Spigelian fascial defect are more likely to become incarcerated [2]. Spigelian hernia, or lateral ventral hernia, is a defect of the anterior abdominal wall located along the semilunar line. It extends through the aponeurotic fascia of the transversus abdominis muscle close to the arcuate line of Douglas³.

By far, there have only been two cases of Spigelian hernia reported where ovary was the content [6,7]. In that regard our case is only the third ovarian Spigelian hernia to be reported.

Though rare, ovary and fallopian tube are possible organs that can herniate through a defect in the Spigelian fascia. Elusive clinically and diagnosable by CT scan, Spigelian hernia as other hernias can be managed through laparoscopic and open approaches. This case was managed in a private practice setting.

2. Case presentation

A right-handed housewife aged 30 years walked into our clinic, accompanied by her husband, bothered by a small mass at the right lower quadrant of her abdomen for 2 weeks. It had increased in

size and become painful for 4 days. Her surgical history was significant for a lower-segment Caesarean section done 2 years back to terminate her pregnancy at 7-month gestational age due to preeclampsia. Her low-birth child succumbed 10 days after delivery. Prior to that, she had two spontaneous abortions. She was nonhypertensive, nondiabetic, and nonsmoker and not on any regular medication. Family history was non-contributory.

At the time of examination, her BMI was 24.9 kg/m². Physical exam revealed a 4 cm x 3 cm firm irreducible tender mass 4 cm lateral and inferior to the right of the umbilicus along the lateral border of the rectus abdominis. CECT abdomen revealed an oblong heterogeneously enhancing structure measuring 5.4 cm x 2.0 cm in the right parauterine region extending across right iliac fossa and herniating through a defect (17 mm wide) between rectus abdominis and transverse/oblique muscles, suggestive of right ovarian Spigelian hernia (Fig. 1).

Since the defect was small, we planned her for herniorrhaphy on the presenting day, after the patient was deemed fit by pre-anesthetic checkup. Intraoperatively, the right ovary and fallopian tube were seen to protrude through a 2cm-defect in the Spigelian fascia and showed no signs of vascular compromise (Fig. 2). The contents were reduced and anterior herniorrhaphy performed in supine position under spinal anesthesia using 1-0 prolene suture. The procedure was performed by the co-author of this article with 18 years of experience in general and GI surgery.

She was managed with fluids and analgesics in the postoperative ward overnight, started on oral diet the next day and was

* Corresponding author.

E-mail address: pralayakhadka@gmail.com (P. Khadka).

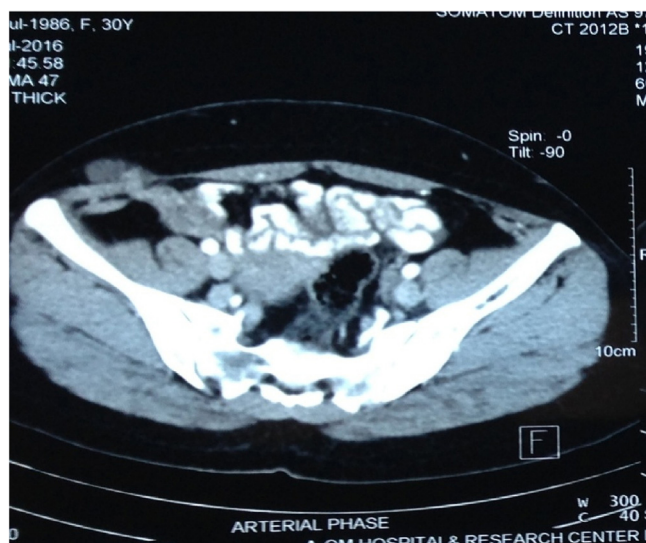


Fig. 1. CT scan showing herniation of right ovary and Fallopian tube.

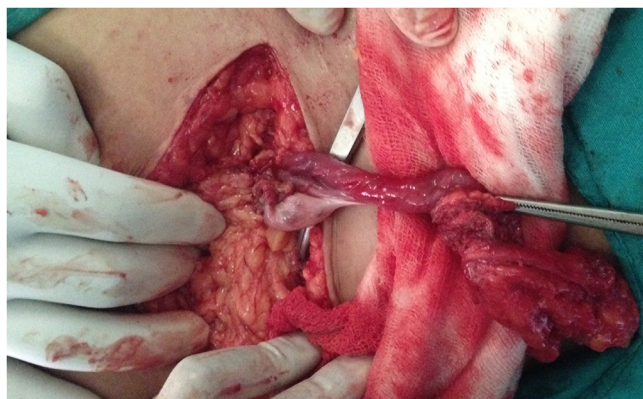

Fig. 2. CT finding confirmed at operation.

discharged on the 3rd postoperative day. No adverse perioperative events occurred.

During her follow-up at 1 week and 2 months, the patient had no complications from surgery including recurrence, as assessed clinically and she did not report any difficulty.

3. Discussion

Spigelian hernia occurs through a defect in the Spigelian fascia which lies between the rectus abdominis medially and the linea semilunaris laterally. Spigelian hernia was first reported by Klinkosch in 1764 although the semilunar line was first described by Belgian anatomist Adriaan van den Spiegel in 1645 [3].

Spigelian hernia most frequently affects people in their sixth decade, is more prevalent in women, and occurs twice as often on the right side. The hernia can occur anywhere along the semilunar line, but most occur in the Spigelian hernia belt, a 6 cm wide transverse zone above the interspinal plane [4].

The cause of Spigelian hernia is unknown, but the occurrence has been attributed to some factors including collagen disorders, aging, obesity, rapid weight loss, multiple pregnancies, chronic obstructive pulmonary diseases, trauma, surgical history, and congenital diseases [5]. In our case, there was a surgical history 2 years prior

to presentation. Literature reveals that almost half of all cases have a surgical history.

The clinical diagnosis of Spigelian hernia can be challenging owing to its rarity and the absence of classic symptoms. There are various differentials to be considered like abdominal wall abscess, hematoma and neoplasms. The performance of a diagnostic imaging can help differentiate these conditions. The strength of our approach in this case lies in the use of computed tomography, the findings of which were confirmed at operation.

Though laparoscopic repair is emerging as a promising treatment for such hernias claiming less morbidity and early discharge, open meshed or mesh-free repair is still an established treatment. Our patient opted for mesh-free repair, due to nonaffordability of laparoscopic surgery and the mesh required thereof. However, she was discharged early with no perioperative morbidity.

4. Conclusion

Spigelian hernia is a rare entity and to add to that, herniation of ovary and fallopian tube as content of such a hernia is very rare. Though difficult to diagnose clinically, it can be located with the aid of computed tomography and managed with either open or laparoscopic methods. This case has been reported in line with the SCARE criteria for case reports [8].

Consent

Written informed consent was obtained from the patient for publication of this case report and accompanying images. A copy of the written consent is available for review by the Editor-in-Chief of this journal on request.

Conflicts of interest

There is no financial and personal relationships with other people or organization that could inappropriately influence this work.

Funding

There are no sponsors involved in the study.

Ethical approval

As this is a case report, informed consent has been taken from the patient.

Author contribution

Pralaya Khadka: Information collection and writing the paper.
Sunil K. Sharma: Study concept.

Guarantor

Pralaya Khadka

Disclosure

There is no financial or personal relationship with people or organizations and no conflicts of interest.

References

- [1] T.J. Houlihan, A review of Spigelian hernias, *Am. J. Surg.* 131 (1976) 734–735.
- [2] J.L. Cameron, *Current Surgical Therapy*, ninth ed., Mosby Elsevier, Philadelphia, 2008.

- [3] D. Yoshida, Laparoscopic intraperitoneal mesh repair of Spigelian hernia: a case report, *Asian J. Endosc. Surg.* 8 (November (4)) (2015) 477–479.
- [4] P.N. Skandalakis, O. Zoras, J.E. Skandalakis, et al., Spigelian hernia: surgical anatomy, embryology, and technique of repair, *Am. Surg.* 72 (2006) 42–48.
- [5] I.S. Montes, M. Deysine, Spigelian and other uncommon hernia repairs, *Surg. Clin. North Am.* 83 (2003) 1235–1253.
- [6] S.H. Ciaran, et al., Ovarian Spigelian hernia: a radiological diagnosis, *Radiography* 18 (2012) 137–139.
- [7] J.M. Walton, et al., Spigelian hernias in infants: report of two cases, *Can. J. Surg.* 38 (February (1)) (1995) 95–97.
- [8] R.A. Agha, A.J. Fowler, A. Saetta, I. Barai, S. Rajmohan, Orgill DP, for the SCARE group. The SCARE statement: consensus-based surgical case report guidelines, *Int. J. Surg.* (2016) (article in press).

Open Access

This article is published Open Access at sciedirect.com. It is distributed under the [IJSCR Supplemental terms and conditions](#), which permits unrestricted non commercial use, distribution, and reproduction in any medium, provided the original authors and source are credited.