

Received: 2016.08.21
Accepted: 2016.11.15
Published: 2017.02.07

Innumerable Liver Masses in a Patient with Autoimmune Hepatitis and Primary Sclerosing Cholangitis Overlap Syndrome




DE **Alireza Gharibpoor**
D **Fariborz Mansour-Ghanaei**
B **Mahboobe Sadeghi**
F **Faeze Gharibpoor**
EF **Farahnaz Joukar**
E **Sara Mavaddati**

Gastrointestinal and Liver Diseases Research Center (GLDRC), Guilan University of Medical Sciences, Rasht, Iran

Authors' Contribution:
Study Design A
Data Collection B
Statistical Analysis C
Data Interpretation D
Manuscript Preparation E
Literature Search F
Funds Collection G

Corresponding Author: Fariborz Mansour-Ghanaei, e-mail: ghanaei@gums.ac.ir, ghanaei@yahoo.com
Conflict of interest: None declared

Patient: Male, 26
Final Diagnosis: AIH-PSC overlap syndrome
Symptoms: Palpable liver more than 5 cm below the costal margin and both firm and nodular • 8-kg weight loss during the last 2 months • clay-colored stool • dark urine • general fatigue • generalized icterus • light abdominal tenderness in the right upper quadrant with isolated hepatomegaly • loss of appetite • neither spider angioma nor stigmata • no clinical evidence of ascites or lymphadenopathy • non-specific abdominal discomfort • normoactive bowel sound • pruritus
Medication: —
Clinical Procedure: Lab tests • MRCP • Pathological analysis
Specialty: Gastroenterology and Hepatology
Objective: Challenging differential diagnosis
Background: In patients with the diagnosis of autoimmune hepatitis (AIH), the presence of cholestatic features raise the possibility of an overlap syndrome with primary sclerosing cholangitis (PSC). Here, we present a unique case with AIH-PSC overlap syndrome and innumerable liver masses.
Case Report: A 26-year-old man presented with generalized icterus. Based on the serological findings of hypergammaglobulinemia and positive anti-nuclear antibody tests, together with an abnormal cholangiogram, he was diagnosed with overlap syndrome (AIH-PSC). Liver imaging revealed innumerable liver masses with a benign appearance in the pathological evaluation. To rule out the colon abnormalities that usually coexist with such liver masses, colonoscopy was performed and showed no significant changes. The liver masses were nonmalignant and were resolved after immunosuppressant therapy.
Conclusions: Because AIH-PSC overlap syndrome is rare, it is suggested that radiological evaluation of the biliary tree should be performed routinely in adults diagnosed with AIH to reduce the missed diagnosis of overlap syndrome and liver masses.
MeSH Keywords: Cholangitis, Sclerosing • Hepatitis, Autoimmune • Liver
Full-text PDF: <http://www.amjcaserep.com/abstract/index/idArt/901153>

 1545  1  4  17



Background

Autoimmune hepatitis (AIH) is a chronic liver disease that rarely occurs with either primary sclerosing cholangitis (PSC) or primary biliary cirrhosis (PBC) as an overlap syndrome [1]. Primary sclerosing cholangitis (PSC) is a progressive, cholestatic disorder characterized by chronic inflammation and stricture formation of the biliary tree [2]. Symptoms include pruritus, fatigue, and ascending cholangitis in advanced cases, cirrhosis, and end-stage hepatic failure. Patients might additionally develop dominant, stenotic lesions of the biliary tree, which may be difficult to differentiate from cholangiocarcinoma. The usual treatment for AIH-PSC overlap syndrome is immunosuppressive drugs [3]. As this syndrome is not prevalent [4] and the presentation of liver masses is not routine, we report a case of AIH-PSC overlap syndrome with hypovascular innumerable liver masses, which is the second such case reported [5].

Case Report

A 26-year-old Iranian industrial worker man with generalized icterus was admitted in the Internal Medicine Department of Razi Hospital in Rasht (a city in northern Iran). About 5 months ago, icterus appeared in the sclera and then gradually became generalized. The other main symptoms were non-specific abdominal discomfort, clay-colored stool, dark urine, pruritus, general fatigue, loss of appetite, and 8-kg weight loss during the last 2 months. He declared a history of mild icterus that subsided spontaneously 2 years ago. There was no history of underlying disease, domestic animals contact, or taking medications, herbal remedies, or un-prescribed supplements. He was a 3-pack/year smoker and irregular alcohol drinker.

Clinical examinations revealed slight abdominal tenderness in the right upper quadrant with isolated hepatomegaly; the liver was palpable more than 5 cm below the costal margin and was both firm and nodular. Neither spider angioma nor stigmata were observed. He had normoactive bowel sound and no clinical evidence of ascites or lymphadenopathy were noted.

Initial blood laboratory tests revealed deranged liver function and normal coagulation test results: total bilirubin 16.2 mg/dl (0.1–1.2 mg/dl), alanine aminotransaminase (ALT) 755 IU/L (5–40 IU/L), aspartate amino transaminase (AST) 635 IU/L (5–40 IU/L), alkaline phosphatase (ALP) 712 IU/L (80–306 IU/L), prothrombin time (PT) 12.4 (11–13.5), partial thromboplastin time (PTT) 39 (25–40), and international normalized ratio (INR) 1.3.

Full blood count, electrolytes, and renal function were normal. Viral marker tests such as hepatitis A, B, and C were negative. Immunological tests demonstrated positive smooth muscle

antibody (ASMA) and positive anti-nuclear antibody (ANA) at a titer of 1 in 640. Anti-mitochondrial antibody (AMA), double-stranded DNA antibody (dsDNA), liver kidney microsomal antibodies (LKM-1), and soluble liver antigen antibody (SLA) tests were normal. There was an accompanying hypergammaglobulinemia with elevated IgG level at 2523 mg/dl (700–1600 mg/dl).

Other potential causes of hepatitis, such as drug-induced liver injury, Wilson's disease, and hereditary hemochromatosis, were excluded. Based on the serological findings, a high titer of ANA and high serum level of IgG, the AIH syndrome diagnosed. Using the simplified criteria for the diagnosis of AIH [6], the score was 7 and definite AIH was concluded (Table 1).

At the next step, ultrasonography revealed slight heterogeneous liver parenchyma with isoechoic masses in the left lobe. Dynamic (triphasic) computed tomography (MDCT) revealed remarkable hepatomegaly with a destruction of architecture (especially in the left lobe). Magnetic resonance cholangiopancreatography (MRCP) showed remarkable hepatomegaly with the destruction of architecture (especially left lobe) due to the presence of innumerable hypovascular masses without discrete margins or significant enhancement. The largest of them measured about 12×10 cm within the left lobe, and the stomach was displaced and compressed. A few adenopathies (SAD ≤10 mm) within paraceliac and gastrohepatic ligament were observed (Figure 1).

A liver biopsy of the left lobe masses was then performed. Pathological analysis of the biopsy sample (Figure 2) showed liver tissue with preserved architecture, moderate infiltration of mixed inflammatory cells in all portal tracts, and moderate periportal interface hepatitis. No confluent necrosis was observed. Expansion of most portal tracts with fibrous septa was also noted. No evidence of malignancy or granulomatous inflammation was observed. The presence of malignant cells was also ruled out by immunohistochemical staining.

Because of the cholestatic signs (e.g., pruritus), high level of serum alkaline phosphatase, and the biopsy results, MRCP was performed to rule out PSC (Figure 3). The position, caliber, and intralaminar signal intensity within the common bile duct were normal and no evidence of choledocholithiasis was seen. Based on the abnormal cholangiogram and biopsy results, he was given the diagnosis of AIH-PSC overlap syndrome.

To exclude colon abnormalities, which are usually the main origin of such liver masses, colonoscopy was performed and showed loss of vascularity, mucosal atrophy, and fragility in the descending colon and sigmoid. Fragility was also seen in the rectum. Due to the poor preparation, the screening was stopped in the transverse colon. Colonoscopy suggested ulcerative colitis but it was not confirmed by colon biopsy.

Table 1. Simplified scoring system for the diagnosis of AIH for our patient.

Clinical features		Score
ANA or SMA	>1: 40 (1+)	1
	>1: 80 (2+)	
LKM-1 >1: 40 (2+)		---
SLA-positive (2+)		---
Antibodies absent (0)		---
Serum globulin (IgG)	Above upper normal limit (1+)	2
	>1.1 upper normal limit (2+)	
	Normal (0)	
Hepatitis viral markers	Positive (0)	2
	Negative (2+)	
Liver history (evidence of hepatitis in a necessary condition)	Compatible with AIH (1+)	2
	Typical AIH (2+)	
	Incompatible AIH (0)	
Interpretation of aggregate scores	Probable AIH >6	7
	Definite AIH >7	

IgG – immunoglobulin G; ANA – anti-nuclear antibodies; SMA – smooth muscle antibodies; LKM-1 – type-1 liver kidney microsomal antibodies; SLA – soluble liver antigen antibodies.

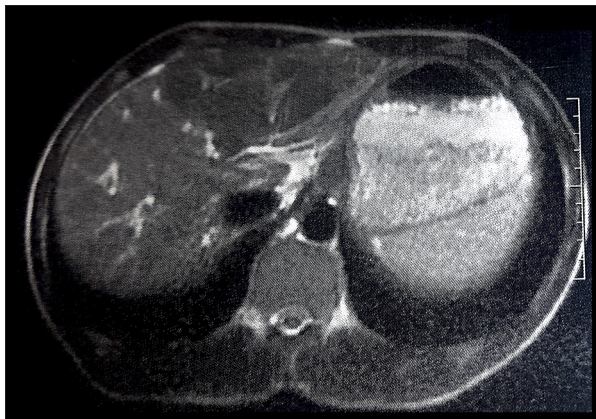


Figure 1. Hepatomegaly and innumerable hypovascular masses within the left lobe (largest: 12×10 cm).

Finally, the treatment of AIH-PSC overlap syndrome began and he was started on Azathioprine 50 mg/daily, Ursodeoxycholic acid (UDCA) and Prednisolone 30 mg/daily with a planned taper. After a couple of weeks of corticosteroid medication, the liver biochemistry improved. The 2-month lab report showed a decline in aminotransferase and bilirubin level and the patient's jaundice was completely resolved. A CT scan confirmed that all liver masses were resolved after the immunosuppressant therapy (Figure 4).

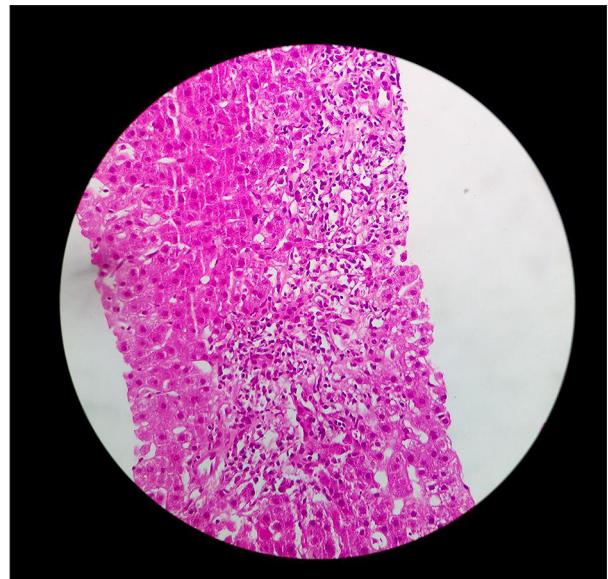


Figure 2. Liver tissue with preserved architecture, moderate infiltration of mixed inflammatory cells in all portal tracts, and moderate periportal interface hepatitis.

Discussion

Autoimmune hepatitis (AIH), first described in the 1950s by Waldenström [7], is a combination of an underlying genetic predisposition with an unknown environmental trigger; it

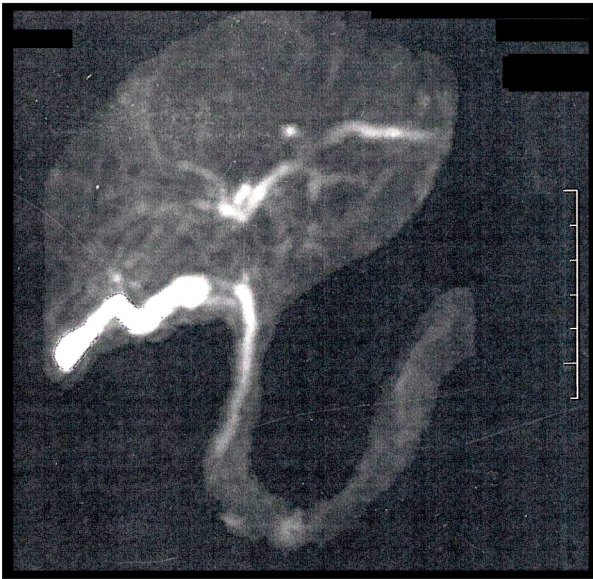

Figure 3. Implementation of PSC with MRCP.

leads to a cell-mediated attack on certain liver antigens [7,8]. Elevated liver function test results, high level of autoimmune antibodies, and high levels of immunoglobulins are the main laboratory findings in AIH [9]. Also, liver biopsy samples in AIH have characteristic histological findings of a chronic mononuclear infiltrate typically involving the limiting plate, usually with a rich plasma cell infiltrate [8, 9]. In the present patient, a high titer of ANA (1/640 titer), the high serum level of IgG (2523 mg/dl), negative viral markers, and liver biopsy results led us to the diagnosis of AIH.

Overlap syndrome, which is a combination of AIH with primary sclerosing cholangitis (PSC) or primary biliary cirrhosis (PBC), should be suspected in patients with clinical and serologic features of autoimmune hepatitis, together with cholestatic presentations. The cholestatic presentations include pruritus, chronic ulcerative colitis, bile duct abnormalities on histology (e.g., portal edema, cholestasis, and fibrous or obliterative cholangitis), cholestatic laboratory changes, high levels of immunoglobulin G, no response to corticosteroid therapy, and an abnormal cholangiogram [10]. In our patient, the high titer of liver function tests and MRCP result confirmed AIH-PSC overlap syndrome. Because imaging of the biliary tree is not performed routinely in AIH patients, often the overlap syndrome is often not diagnosed [11]. Therefore, magnetic resonance cholangiography (MRC) is recommended as a low-risk imaging method for these patients [11,12].

The most important point in our patient's presentation was the results of liver imaging studies, which showed innumerable iso-echoic masses. Nowadays, liver masses are increasingly being identified due to the widespread use of imaging, such as ultrasonography (US), computed tomography (CT), and

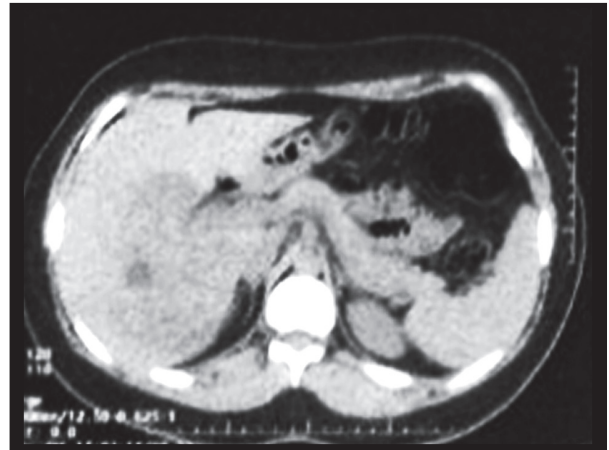

Figure 4. All liver masses resolved after the immunosuppressant therapy.

magnetic resonance imaging [13]. Most of these lesions are detected incidentally in asymptomatic patients, which shows the importance of careful physical examination. In our case, the firm and nodular liver surface led us to use ultrasonography and find the liver masses.

In many countries, metastatic liver tumors are the most common malignant hepatic neoplasia; therefore, the presence of an extrahepatic malignancy should be suspected in patients with a characteristic liver lesion on imaging studies [13]. However, our liver biopsy showed liver tissue with preserved architecture, moderate infiltration of mixed inflammatory cells in all portal tracts, and moderate periportal interface hepatitis with no confluent necrosis. The presence of malignant cells was ruled out by using immunohistochemical staining.

The last unique feature of our case was a normal colon biopsy result. Trivedi et al. [14] reported that more than 80% of northern European patients with PSC suffer from inflammatory bowel disease (IBD) with higher frequency of ulcerative colitis (UC). Also, they mentioned that IBD commonly presents before the onset of PSC and is characteristically mild and frequently involves the whole colon. In our case, colonoscopy suggested ulcerative colitis, but it was not confirmed by colon biopsy.

Studies suggest that patients with AIH-PSC overlap have a better prognosis compared to those with PSC alone [15] and have a worse prognosis compared to those with AIH alone [1,15,16]. Also, it was reported that the individual risk factor for post-liver transplantation biliary complications is less common in AIH-PSC patients in comparison to each of them [17].

There have been various reports about the prognosis of AIH-PSC overlap syndrome [1,15,16]. Although some studies found AIH has a poor prognosis, overlap syndrome has a better prognosis [15].

Our patient showed a good prognosis and was treated successfully, and all liver masses resolved during the immunosuppressant therapy.

Conclusions

Although in our case the colonoscopy findings were normal and liver masses were nonmalignant, use of the overall diagnostic methods lead us to suspect overlap syndrome. We suggest that radiological evaluation of the biliary tree should be done

References:

1. Parker R, Oo YH, Adams DH: Management of patients with difficult autoimmune hepatitis. *Therap Adv Gastroenterol*, 2012; 5(6): 421–37
2. Chandok N, Hirschfield GM: Management of primary sclerosing cholangitis: conventions and controversies. *Can J Gastroenterol*, 2012; 26(5): 261–68
3. Bunchorntavakul C, Reddy KR: Diagnosis and management of overlap syndromes. *Clin Liver Dis*, 2015; 19(1): 81–97
4. Silveira MG: Overlap syndromes of autoimmune liver disease. *J Clin Cell Immunol*, 2013; 4: 4
5. Thakker A, Karande S: Overlap syndrome: Autoimmune sclerosing cholangitis. *Indian Pediatr*, 2010; 47(12): 1063–65
6. Liberal R, Grant CR, Longhi MS et al: Diagnostic criteria of autoimmune hepatitis. *Autoimmun Rev*, 2014; 13(4): 435–40
7. Waldenstrom J: The diagnostic importance of ACTH. *Acta Endocrinol (Copenh)*, 1950; 5(3): 235–42
8. Vergani D, Choudhuri K, Bogdanos DP, Mieli-Vergani G: Pathogenesis of autoimmune hepatitis. *Clin Liver Dis*, 2002; 6(3): 727–37
9. Liberal R, Mieli-Vergani G, Vergani D: Autoimmune hepatitis: From mechanisms to therapy. *Rev Clin Esp*, 2016; 216(7): 372–83
10. Trivedi P, Hirschfield G: Review article: Overlap syndromes and autoimmune liver disease. *Aliment Pharmacol Ther*, 2012; 36(6): 517–33
11. Boberg KM, Chapman RW, Hirschfield GM et al: Overlap syndromes: The International Autoimmune Hepatitis Group (IAIHG) position statement on a controversial issue. *J Hepatol*, 2011; 54(2): 374–85
12. Aguilar-Najera O, Velasco-Zamora J, Torre A: Overlap syndromes of autoimmune hepatitis: Diagnosis and treatment. *Rev Gastroenterol Mex*, 2015; 80(2): 150–59
13. Schwartz MJ, Kruskal JB: Solid liver lesions: Differential diagnosis and evaluation. In Post TW, Rutgeerts P, Grover S (eds.), *UptoDate*. 2014
14. Trivedi P, Chapman R: PSC, AIH and overlap syndrome in inflammatory bowel disease. *Clin Res Hepatol Gastroenterol*, 2012; 36(5): 420–36
15. Floreani A, Rizzotto ER, Ferrara F et al: Clinical course and outcome of autoimmune hepatitis/primary sclerosing cholangitis overlap syndrome. *Am J Gastroenterol*, 2005; 100(7): 1516–22
16. Lüth S, Kanzler S, Frenzel C et al: Characteristics and long-term prognosis of the autoimmune hepatitis/primary sclerosing cholangitis overlap syndrome. *J Clin Gastroenterol*, 2009; 43(1): 75–80
17. Kobryń K, Kozieł S, Porečka M et al: Endoscopic treatment of early biliary complications in liver transplant recipients. *Ann Transplant*, 2014; 20: 741–46

routinely in adults diagnosed with AIH to reduce the missed diagnosis of overlap syndrome and liver masses.

Acknowledgment

We thank Dr. Zahra Haghparast Ghadim Limudahi for critical reading of the manuscript and for insightful suggestions.

Conflict of interest

There is no conflict of interest.