

CASE REPORT

Ectopic Cushing syndrome in small cell lung cancer: A case report and literature reviewHang-yu Zhang¹ & Jun Zhao²

1 Department of Interventional Therapy, Key Laboratory of Carcinogenesis and Translational Research (Ministry of Education), Peking University Cancer Hospital and Institute, Beijing, China

2 Department of Thoracic Medical Oncology, Key Laboratory of Carcinogenesis and Translational Research (Ministry of Education), Peking University Cancer Hospital and Institute, Beijing, China

Keywords

Ectopic Cushing's syndrome; paraneoplastic syndromes; small-cell lung cancer.

Correspondence

Jun Zhao, Department of Thoracic Medical Oncology, Peking University Cancer Hospital, No. 52 Fucheng Road, Haidian District, Beijing 100142, China.

Tel: +86 135 2146 9355

Fax: +86 10 8819 6562

Email: ohjerry@163.com

Received: 8 September 2016;

Accepted: 4 October 2016.

doi: 10.1111/1759-7714.12403

Thoracic Cancer **8** (2017) 114–117

Abstract

Small cell lung cancer (SCLC) is a neuroendocrine tumor with the potential to secrete various peptides or hormones that can lead to paraneoplastic syndromes, such as Ectopic Cushing syndrome (ECS). Because of the aggressive nature of the syndrome and its atypical features, ECS in small-cell lung cancer is difficult to diagnose and has a poor prognosis. We report a case of a 74-year-old male patient who presented with severe hypokalemia, proximal muscle weakness, peripheral edema, metabolic alkalosis, and worsening hyperglycemia. The patient was eventually diagnosed with stage IV primary small-cell lung cancer and survived three months after diagnosis. We reviewed published articles to determine any new diagnostic techniques or advantages in the treatment regimen.

Introduction

Ectopic Cushing's syndrome (ECS) is the second most common paraneoplastic syndrome that occurs with small cell lung cancer (SCLC) (1–5% of cases).¹ Up to 50% of ECS cases are lung tumors, including carcinoid tumors (30–46% ECS cases) and SCLC (8–20% ECS cases).^{2–4} SCLC patients with ECS have a poorer prognosis because of their advanced stage, poor response to chemotherapy, increased susceptibility to severe infections, and greater incidence of thromboembolic phenomena.^{5,6} Most patients present electrolyte disturbances and muscle weakness rather than the typical clinical features of Cushing's syndrome (CS). Studies have suggested that SCLC patients with adrenal metastases may also tend to develop ECS as a result of their location, as corticosteroids are synthesized more abundantly in the areas adjacent to the adrenal metastasis.⁷ We report a case of SCLC with Cushing's syndrome and bilateral adrenal metastases in a 74-year-old man presenting with severe hypokalemia, proximal muscle weakness, peripheral edema, metabolic alkalosis, and worsening

hyperglycemia. Clinical features, diagnosis, treatment, and new developments in ECS are discussed.

Case report

A 74-year-old man with a history of 20 pack-years smoking and 18 years of type 2 diabetes mellitus (T2DM) suffered general weakness and worsening hyperglycemia for a month. His initial blood pressure was 135/70 mmHg, his respiratory rate 20 breaths per minute, heart rate 81 beats per minute, and he had a normal temperature. He was categorized as Eastern Cooperative Oncology Group (ECOG) grade 2.

A laboratory examination revealed the following: white blood cell count, $10.42 \times 10^9/L$; neutrophil, 90.74%; hemoglobin, 14.3 g/dL; platelet count, $203 \times 10^9/L$; potassium, 2.95 mmol/L; calcium, 1.91 mmol/L; serum alanine aminotransferase, 93 IU/L; aspartate aminotransferase, 43 IU/L; D-dimer, 8.18 $\mu g/mL$; and C-reactive peptide, 3.7 mg/L. Arterial blood gas analysis resulted in pH 7.511, pCO_2 37.3 mmHg, pO_2 67.3 mmHg, Glu 13.1 mmol/L, Lac 3.6 mmol/L, BE

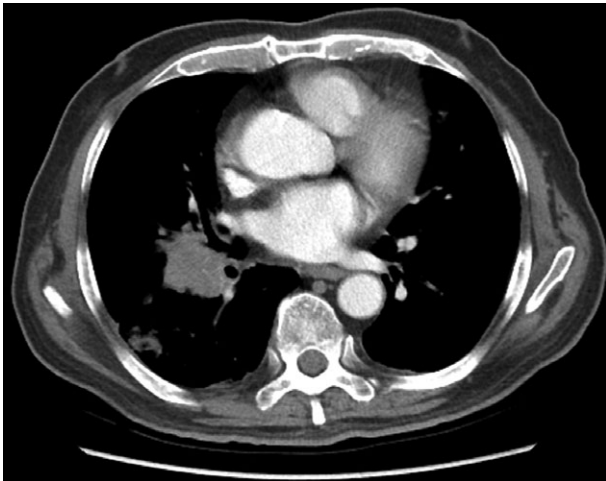


Figure 1 Right lower lobe mass conforms to malignant features with mediastinal and right hilar lymph node metastasis.

5.95 mmol/L and oxygen saturation of 95.8%, which indicated metabolic alkalosis. The patient's adrenocorticotrophic hormone level was 299.10 PG/MI (7.2–63.3 PG/mL) and serum cortisol level was >63.44 µg/dL (4.4–19.9 µg/dL), which indicated CS.

Chest enhanced computed tomography (CT) scans showed a right lower lobe mass, conformed to malignant features with mediastinal and right hilar lymph node metastasis and double lung metastases (Fig 1). Abdominal enhanced CT scans showed multiple occupied lesions in the liver, considered as metastases. Bilateral adrenal nodules were also considered as metastases (Figs 2–3). Pituitary imaging was normal. A biopsy was performed with CT-guided lung puncture and the pathology confirmed small cell carcinoma.

After confirmation of the diagnosis, the patient received spironolactone and intravenous potassium supplementation to treat the refractory hypokalemia. Considering the poor performance status of this patient, we suggested oral etoposide in the first cycle at 50 mg per day, days 1–10, every three weeks. Treatment was ceased on the eighth day because of diarrhea (Common Terminology Criteria for Adverse Events grade 2). In the second cycle, the patient received etoposide via intravenous infusion. During treatment his electrolyte imbalances were corrected, the target lesions in the lung were slightly reduced, and his general state was much better. However, systemic chemotherapy was ceased because of the onset of herpes zoster. The patient died of liver failure three months after diagnosis.

The limitations faced in this case included the lack of availability of 24-hour urine cortisol and inferior petrosal sinus sampling (IPSS). However, the diagnosis was based on strong clinical grounds, firm laboratory findings of hypercortisolism,

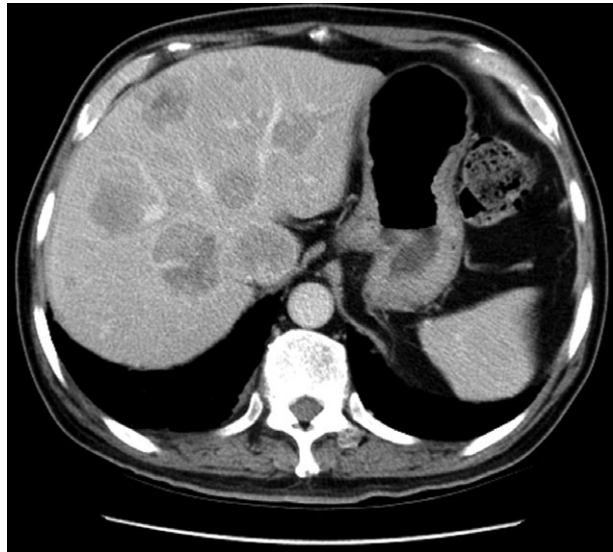


Figure 2 Multiple occupied lesions in the liver, considered metastases.

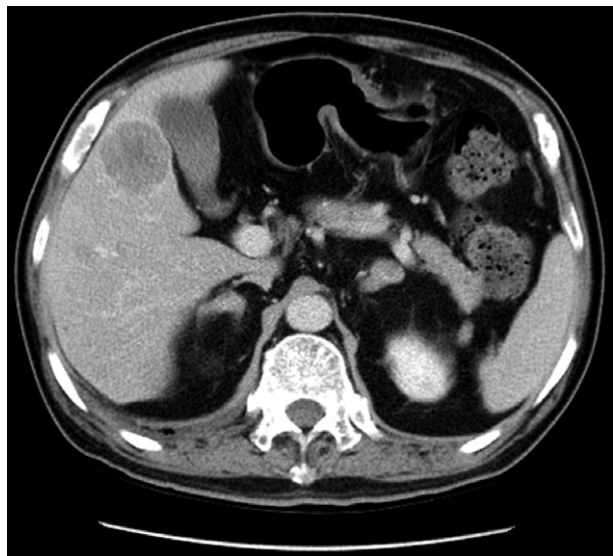

Figure 3 Bilateral adrenals nodules, considered metastases.

the exclusion of other causes of CS, histopathologic findings, and clinical improvement after chemotherapy.

Discussion

Ectopic Cushing's syndrome secondary to lung cancer is rare and limited papers have reported this syndrome since it was first described by Brown in 1928.⁴ ECS in SCLC does not usually exhibit the classic signs of CS and CS could also appear during effective chemotherapy.^{8,9} The wide variety of clinical manifestations make it more difficult to diagnose ECS in SCLC, especially at early clinical stages.

Table 1 Reports of ECS in SCLC

Author	Year	Patient no.	Clinical presentation	Treatment	Survival	Follow-up
Shepherd ¹³	1992	23	Edema (83%) Muscle weakness (61%)	Chemotherapy	3.5 months	
Ilias ³	2005	3	Muscle weakness (82%) Hypertension (78%)	Chemotherapy with/without endocrine therapy		1–48 months
Hadem ¹⁴	2007	1	Muscle weakness Hyperglycemia Hypokalemia	Ketoconazole Chemotherapy	2 months	
Suyama ⁹	2011	1	Hypokalemia Diabetes Hypertension	Mitotane Chemotherapy	5 months	
Jeong ¹²	2015	1	Hypokalemia metabolic alkalosis Hypertension	Ketoconazole Spironolactone Chemotherapy	15 months	
Ghazi ⁴	2015	4	Muscle weakness Hyperglycemia Hypokalemia	Not mentioned	2 weeks to 3 months	
Aoki ¹⁵	2016	1	Hypertension Hypokalemia Muscle weakness	Chemotherapy	6 months	

ECS, Ectopic Cushing's syndrome; SCLC, small-cell lung cancer.

Small-cell lung cancer patients with ECS have a very poor prognosis, living only three to six months. This makes early diagnosis much more important. IPSS is the most reliable examination for ECS, but it may not be feasible in many institutes.^{3,10} Complete imaging examination, related blood and urine tests, low dose and high dose dexamethasone tests, immunohistochemical characteristics, and cell proliferation potential (Ki-67) should be considered when suspicious of ECS. If a lesion cannot be located on CECT, then ostroscan will also not be effective for detection.^{3,11}

Jeong *et al.* suggested that controlling the high cortisol level and then administering systemic chemotherapy may achieve longer survival.¹² With the exception of systemic chemotherapy, ketoconazole, metyrapone, etomidate, mitotane, and mifepristone can be used to reduce circulating glucocorticoids.⁵ Previous reports have shown that there is a tendency to prolong survival when the high level of cortisol is controlled before initiating treatment (Table 1). Ketoconazole has been widely accepted for the treatment of ECS since first reported in 1985 because of patient tolerance in spite of moderate toxicity, such as nausea and liver injury.¹⁶ However, ketoconazole may increase the risk of chemotherapy toxicity because it is a strong inhibitor of cytochrome P450 3A4. Thus, metyrapone has been reported to be a better choice. For severe adrenocorticotrophic hormone-dependent CS, metyrapone and ketoconazole combination or mitotane, metyrapone, and ketoconazole combination therapy could be an alternative to control the cortisol level earlier. Chemotherapy remains the basic treatment for such patients; however, when the clinical manifestation of CS is so severe that the

patient cannot tolerate chemotherapy, metyrapone should be administered.

In conclusion, SCLC with ECS is a rare disease with a poor prognosis. Early diagnosis is challenging but important. SCLC patients with muscle weakness, new onset or worsening hyperglycemia, severe hypokalemia, and bilateral adrenal metastasis should receive adequate attention and extensive examination should be conducted to confirm a diagnosis. Systemic chemotherapy with steroidogenesis inhibitors or glucocorticoid receptor antagonist represents a new treatment regimen. Control of severe hypercortisolism before administering systemic chemotherapy may achieve longer survival.

Acknowledgments

Author contributions are as follows: Dr. Zhang contributed to data collection, manuscript drafting and literature research. Dr. Zhao contributed to clinical treatment and manuscript revision for important intellectual content. The authors thank the patient who participated in this study.

Disclosure

No authors report any conflict of interest.

References

- 1 Mayer S, Cypess AM, Kocher ON *et al.* Uncommon presentations of some common malignancies:

- Case 1. Sequential paraneoplastic endocrine syndromes in small-cell lung cancer. *J Clin Oncol* 2005; **23**: 1312–4.
- 2 Isidori AM, Kaltsas GA, Pozza C *et al*. The ectopic adrenocorticotropin syndrome: Clinical features, diagnosis, management, and long-term follow-up. *J Clin Endocrinol Metab* 2006; **91**: 371–7.
 - 3 Ilias I, Torpy DJ, Pacak K, Mullen N, Wesley RA, Nieman LK. Cushing's syndrome due to ectopic corticotropin secretion: Twenty years' experience at the National Institutes of Health. *J Clin Endocrinol Metab* 2005; **90**: 4955–62.
 - 4 Ghazi AA, Abbasi Dezfooli A, Amirbaigloo A *et al*. Ectopic Cushing's syndrome secondary to lung and mediastinal tumours -- report from a tertiary care centre in Iran. *Endokrynol Pol* 2015; **66**: 2–9.
 - 5 Kanaji N, Watanabe N, Kita N *et al*. Paraneoplastic syndromes associated with lung cancer. *World J Clin Oncol* 2014; **5**: 197–223.
 - 6 von Stempel C, Perks C, Corcoran J, Grayez J. Cardio-respiratory failure secondary to ectopic Cushing's syndrome as the index presentation of small-cell lung cancer. *BMJ Case Rep* 2013; **2013**: pii: bcr2013009974.
 - 7 Satoh H, Saito R, Hisata S *et al*. An ectopic ACTH-producing small cell lung carcinoma associated with enhanced corticosteroid biosynthesis in the peritumoral areas of adrenal metastasis. *Lung Cancer* 2012; **76**: 486–90.
 - 8 Imura H, Matsukura S, Yamamoto H, Hirata Y, Nakai Y. Studies on ectopic ACTH-producing tumors. II. Clinical and biochemical features of 30 cases. *Cancer* 1975; **35**: 1430–7.
 - 9 Suyama K, Naito Y, Yoh K *et al*. Development of Cushing's syndrome during effective chemotherapy for small cell lung cancer. *Intern Med* 2011; **50**: 335–8.
 - 10 Kolesnikova GS, Lapshina AM, Voronkova IA *et al*. Comparative analysis of clinical, hormonal and morphological studies in patients with neuroendocrine ACTH-producing tumours. *Int J Endocrinol* 2013; **2013**: 659232.
 - 11 Alexandraki KI, Grossman AB. The ectopic ACTH syndrome. *Rev Endocr Metab Disord* 2010; **11**: 117–26.
 - 12 Jeong C, Lee J, Ryu S *et al*. A case of ectopic adrenocorticotropin hormone syndrome in small cell lung cancer. *Tuberc Respir Dis (Seoul)* 2015; **78**: 436–9.
 - 13 Shepherd FA, Laskey J, Evans WK, Goss PE, Johansen E, Khamsi F. Cushing's syndrome associated with ectopic corticotropin production and small-cell lung cancer. *J Clin Oncol* 1992; **10**: 21–7.
 - 14 Hadem J, Cornberg M, Länger F *et al*. Making sense of muscle fatigue and liver lesions. *Z Gastroenterol* 2007; **45**: 609–11.
 - 15 Aoki M, Fujisaka Y, Tokioka S *et al*. Small-cell lung cancer in a young adult nonsmoking patient with ectopic adrenocorticotropin (ACTH) production. *Intern Med* 2016; **55**: 1337–9.
 - 16 Shepherd FA, Hoffert B, Evans WK, Emery G, Trachtenberg J. Ketoconazole. Use in the treatment of ectopic adrenocorticotropin hormone production and Cushing's syndrome in small-cell lung cancer. *Arch Intern Med* 1985; **145**: 863–4.