

Observational Study

Feasibility of imaging superficial palmar arch using micro-ultrasound, 7T and 3T magnetic resonance imaging

Alison N Pruzan, Audrey E Kaufman, Claudia Calcagno, Yu Zhou, Zahi A Fayad, Venkatesh Mani

Alison N Pruzan, Audrey E Kaufman, Claudia Calcagno, Yu Zhou, Zahi A Fayad, Venkatesh Mani, Translational and Molecular Imaging Institute, Department of Radiology, Icahn School of Medicine at Mount Sinai, New York, NY 10029, United States

Author contributions: Pruzan AN, Kaufman AE and Mani V designed the study and performed the research; Zhou Y helped perform the research and helped acquire ultrasound data; Calcagno C provided her imaging expertise and helped with MRI acquisition; Pruzan AN and Kaufman AE drafted the article and made critical revisions related to the intellectual content of the manuscript; Fayad ZA and Mani V helped with data analysis and interpretation; all authors reviewed and approved the manuscript content; Pruzan AN and Kaufman AE contributed equally to this research.

Institutional review board statement: This study was conducted in conformance with institutional policies with regard to human subject protections after informed consent and ethical permission were obtained.

Conflict-of-interest statement: There are no conflicts of interest to disclose.

Data sharing statement: No additional data are available.

Open-Access: This article is an open-access article which was selected by an in-house editor and fully peer-reviewed by external reviewers. It is distributed in accordance with the Creative Commons Attribution Non Commercial (CC BY-NC 4.0) license, which permits others to distribute, remix, adapt, build upon this work non-commercially, and license their derivative works on different terms, provided the original work is properly cited and the use is non-commercial. See: <http://creativecommons.org/licenses/by-nc/4.0/>

Manuscript source: Invited manuscript

Correspondence to: Venkatesh Mani, PhD, Translational and Molecular Imaging Institute, Department of Radiology, Icahn School of Medicine at Mount Sinai, 1470 Madison Avenue New York, NY 10029, United States. venkatesh.mani@mssm.edu
Telephone: +1-212-8248538

Received: October 8, 2016

Peer-review started: October 10, 2016

First decision: December 13, 2016

Revised: December 17, 2016

Accepted: January 11, 2017

Article in press: January 14, 2017

Published online: February 28, 2017

Abstract

AIM

To demonstrate feasibility of vessel wall imaging of the superficial palmar arch using high frequency micro-ultrasound, 7T and 3T magnetic resonance imaging (MRI).

METHODS

Four subjects (ages 22-50 years) were scanned on a micro-ultrasound system with a 45-MHz transducer (Vevo 2100, VisualSonics). Subjects' hands were then imaged on a 3T clinical MR scanner (Siemens Biograph MMR) using an 8-channel special purpose phased array carotid coil. Lastly, subjects' hands were imaged on a 7T clinical MR scanner (Siemens Magnetom 7T Whole Body Scanner) using a custom built 8-channel transmit receive carotid coil. All three imaging modalities were subjectively analyzed for image quality and visualization of the vessel wall.

RESULTS

Results of this very preliminary study indicated that vessel wall imaging of the superficial palmar arch was feasible with a whole body 7T and 3T MRI in comparison with micro-ultrasound. Subjective analysis of image quality (1-5 scale, 1: poorest, 5: best) from B mode, ultrasound, 3T SPACE MRI and 7T SPACE MRI indicated that the image quality obtained at 7T was superior to both 3T MRI and micro-ultrasound. The 3D SPACE sequence at both 7T and 3T MRI with isotropic voxels allowed for multi-planar

reformatting of images and allowed for less operator dependent results as compared to high frequency micro-ultrasound imaging. Although quantitative analysis revealed that there was no significant difference between the three methods, the 7T Tesla trended to have better visibility of the vessel and its wall.

CONCLUSION

Imaging of smaller arteries at the 7T is feasible for evaluating atherosclerosis burden and may be of clinical relevance in multiple diseases.

Key words: Superficial Palmar Arch; 7T and 3T magnetic resonance imaging; Micro-ultrasound; Atherosclerosis; Cardiovascular disease

© **The Author(s) 2017.** Published by Baishideng Publishing Group Inc. All rights reserved.

Core tip: The evaluation of smaller arteries in the hand may be clinically useful in a variety of vascular diseases. Imaging the vessel wall of such small caliber arteries (2.5 mm to 3.1 mm) requires very high spatial resolution and the use of either high frequency micro-ultrasound or 7 Tesla magnetic resonance imaging (MRI) would be the ideal tool to acquire these images. We sought to demonstrate feasibility of vessel wall imaging of the superficial palmar arch using 7T and 3T MRI in comparison with very high frequency micro-ultrasound.

Pruzan AN, Kaufman AE, Calcagno C, Zhou Y, Fayad ZA, Mani V. Feasibility of imaging superficial palmar arch using micro-ultrasound, 7T and 3T magnetic resonance imaging. *World J Radiol* 2017; 9(2): 79-84 Available from: URL: <http://www.wjgnet.com/1949-8470/full/v9/i2/79.htm> DOI: <http://dx.doi.org/10.4329/wjr.v9.i2.79>

INTRODUCTION

A variety of pathological processes can affect the hand, including atherosclerosis, scleroderma, thromboangiitis obliterans (TO), hypothenar hammer syndrome and acute arterial thrombosis related to intraarterial injection^[1].

Atherosclerosis is a chronic complex process involving multiple factors including inflammation, oxidative stress, endothelial dysfunction, smooth muscle cell proliferation, platelet activation, and thrombosis, all leading to pathologic changes in the arterial wall with plaque formation^[2]. The plaque is primarily composed of inflammatory cells, lipids, and calcium^[3]. Chronic atherosclerosis can cause peripheral vascular occlusive disease in the extremities. In the upper extremity, atherosclerosis is more prevalent in the proximal subclavian artery but can occur in smaller distal vessels with resultant morbidity^[4]. For example, young diabetics who have diffuse distal atherosclerosis, end-stage

renal disease and are on renal dialysis are at high risk for developing finger gangrene^[5]. In the autoimmune disorder scleroderma, ultrasound evaluation has shown that the ulnar artery proximal to the wrist is specifically targeted^[6]. The vasculopathy of scleroderma can cause secondary Raynaud's phenomenon, as well as digital ulcers. Doppler sonography has proven useful in assessing palmar and digital arteries in these cases^[7,8]. TO also known as Buerger's disease, is a panarteritis of unknown origin, which demonstrates a strong concurrence with tobacco use. It affects both small and medium-sized vessels of the extremities. The thrombotic and inflammatory changes associated with TO cause vascular changes with associated arteriographic findings^[9-11]. Hypothenar hammer syndrome, a post-traumatic pathology arising from repetitive hitting of the hypothenar region of the hand, can cause ulnar artery occlusive disease with thromboembolism and resulting ischemia to the digits^[12,13]. The thrombosis secondary to TO and hypothenar hammer syndrome may be relatively localized, whereas diffuse arterial thrombosis of the hand may occur secondary to intraarterial injection of medications or illegal substances^[14]. Visualizing atherosclerotic changes in small arteries such as the superficial palmar arch may provide valuable clinical insights into the progression of these disease states.

Imaging the vessel wall of smaller caliber arteries requires higher resolution imaging when compared to imaging larger vessels such as the aorta and carotid arteries. For this purpose we conducted MR evaluation of the superficial palmar arch using 7T and 3T whole body MR scanners and compared the images acquired with high frequency micro-ultrasound imaging. The superficial palmar arch is the continuation of the ulnar artery as it passes distal to the flexor retinaculum in the hypothenar region of the palm. We chose to focus on the superficial palmar arch because it is easily and consistently visualized using the modalities employed. We hypothesize that 7T MRI will provide better delineation of the vessel wall as compared to 3T and may be a suitable method to visualize small arteries in the hand. We also believe that ultrasound may be a convenient alternative compared to 3T and 7T due to its image acquisition speed and wide availability. But, conventional clinical ultrasound (about 3-7 MHz) may lack resolution, so the use of a high frequency (45-MHz) micro-ultrasound typically used in animal models may be better suited for superficial structures such as the palmar arch.

MATERIALS AND METHODS

Study population

Four subjects (ages 22-50 years) were scanned on a micro-ultrasound system with a 45-MHz transducer (Vevo 2100, VisualSonics, Toronto, Canada) (Figure 1A). While this system is primarily used in animal studies, it has been successfully and safely used in

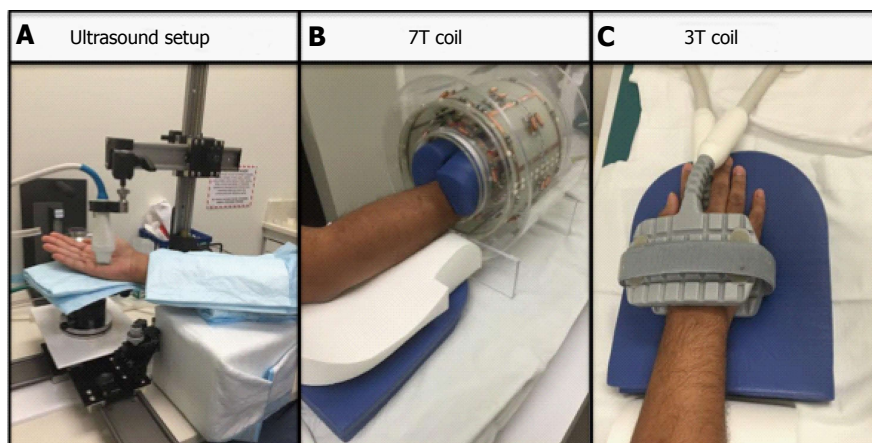


Figure 1 The figure shows the set up for the ultrasound (A), the 7T (B) and the 3T (1) respectively.

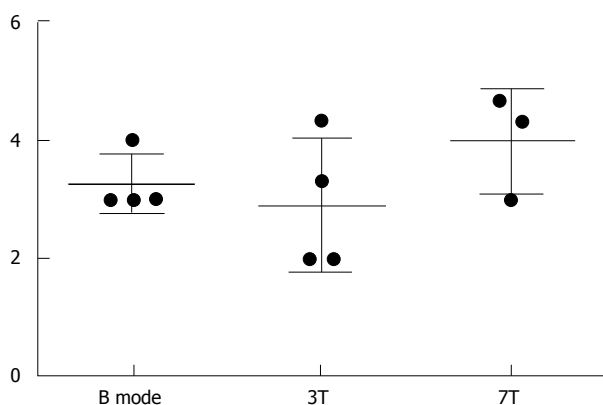


Figure 2 Data from 3 subjective analyses of image quality (1-5 scale). Error bars included.

clinical studies, which include infants and children.^[15,16] Subjects' hands were then imaged on a 3T clinical MR scanner (Siemens Biograph MMR) using an 8-channel special purpose phased array carotid coil (Figure 1C). Lastly, subjects' hands were imaged on a 7T clinical MR scanner (Siemens Magnetom 7T Whole Body Scanner) using a custom built 8-channel transmit receive carotid coil (Figure 1B).

Micro-ultrasound imaging and protocol

The Vevo Imaging Station (Vevo 2100, VisualSonics, Toronto, Canada) was used for mounting the transducer and for stabilizing the position of the hand. The subject was seated during the scan with the hand in supine position with slight rotation toward neutral. Padding was also used under the hand and arm for stabilization and comfort purposes (Figure 1A). With this positioning, images in B mode, Power mode, Doppler mode and M mode of the superficial palmar arch were obtained. Images were then subjectively analyzed for image quality. Three readers rated the images on a score: (1) is a non-visible vessel with non-visible walls and poor image quality; (2) represents a vessel with indistinct vessel walls and poor image quality; (3) is a vessel with adequate image quality with walls moderately well seen; (4) represents a vessel with

Table 1 Imaging protocol for both 3T and 7T magnetic resonance imaging

Parameter	7T T2 SPACE	3T T2 SPACE	7T TOF	3T TOF
TE	101	77	2.81	3.23
TR	1500	1600	60	21
Slice thickness	625.00 μ m	630.00 μ m	160.00 mm	1.00 mm
Pixel size	0.600/0.600	0.625/0.625	0.3125/0.3125	0.234/0.234
Number of averages	2	4	1	1
Field of view	136 \times 160	100 \times 160	160 \times 160	107 \times 120

distinct vessel walls and good image quality; and (5) is excellent visualization of the vessel and image quality. Results from the three readers were averaged. Criteria used for subjective evaluation were the overall image quality, visualization of the vessel wall, adequate flow suppression and absence of artifacts. We also obtained measures of average peak Doppler velocity, intima media thickness, wall thickness, lumen diameter, and total vessel diameter.

MR imaging and protocol

Subjects' hands were imaged on a 3T clinical MR scanner (Siemens Biograph MMR) using an 8-channel special purpose phased array carotid coil (Figure 1C). Subjects' hands were imaged on a 7T clinical MR scanner (Siemens Magnetom 7T Whole Body Scanner) using a custom built 8-channel transmit receive carotid coil (Figure 1B). Subjects were imaged in a head first prone position with hand extended above the head. The imaging protocols between 3T and 7T were matched as closely as possible. Total scan time was approximately 20 min each. We acquired a localizer, a 3D time-of-flight (TOF) MR angiography sequence followed by a 3D T2 weighted Sampling Perfection with Application optimized Contrasts using different flip angle Evolution (SPACE) sequence^[1,17,18] and a 0.6 mm isotropic resolution in all dimensions (Table 1). MR images were also subjectively analyzed for image quality and visualization of the vessel wall. The imaging criteria used were similar to that for the ultrasound. Furthermore, we also measured

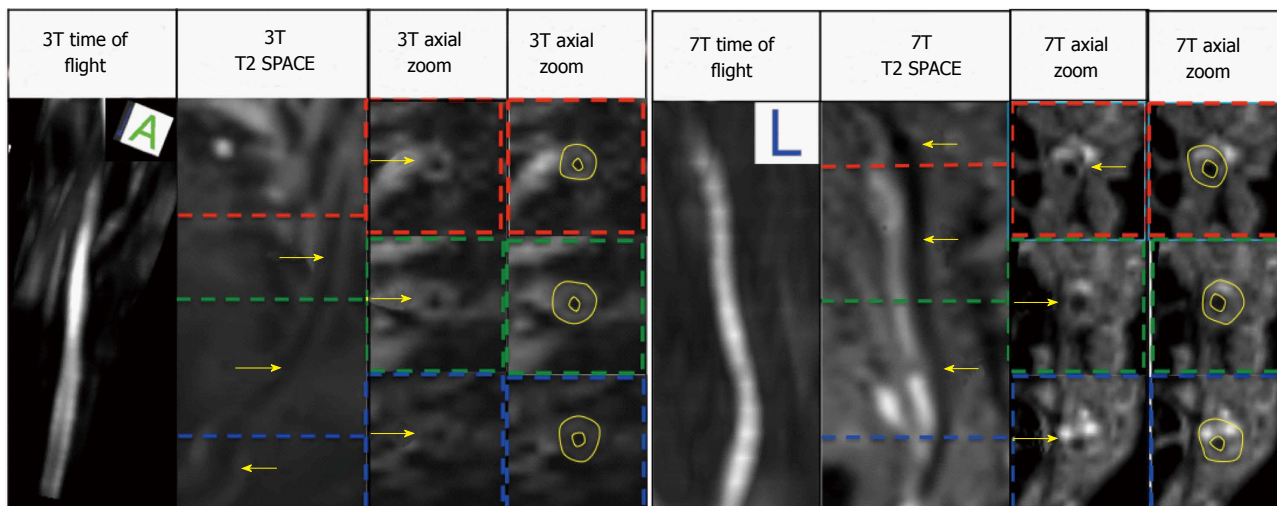


Figure 3 Displays the 3T images (Left) and the 7T images (Right) the arrows point to vessel wall.

Table 2 Data from 3 subjective analyses of image quality with average and standard deviation

Subject	B mode	3T	7T
1	3.00	3.33	3.00
2	3.00	2.00	Not available
3	3.00	4.33	4.67
4	4.00	2.00	4.33
Average	3.25	2.92	4.00
Standard deviation	0.50	1.13	0.882

Table 3 RM one-way ANOVA and Tukey’s multiple comparisons test

Vessel wall measurements	P value
Lumen area	0.3152
Wall area	0.0628
Total vessel area	0.0573
Normalized wall index	0.0362 ^a
Wall thickness	0.0519

^aP < 0.05, significant.

wall thickness, lumen and outer diameters from the MR images. The order of the imaging tests was randomized.

Statistical analysis

The data were expressed as the mean ± SD. For the statistics, a RM one-way ANOVA and Tukey’s multiple comparisons test were used. P < 0.05 was considered as statistically significant.

RESULTS

Subjective analysis of image quality was performed (1-5 scale, 1: Vessel non-visible, 5: Clearly visible vessel wall) from B mode, ultrasound, 3T SPACE MRI and 7T SPACE MRI. These results are shown in Table 2 and Figure 2.

In addition, lumen area, wall area, total vessel area, and wall thickness were automatically calculated by a MatLab script (MATLAB and Statistics Toolbox Release 2012b, The MathWorks, Inc., Natick, Massachusetts, United States) for the manually drawn contours on the 3T and 7T images using a customized software program (Vessel Mass Software, Leiden University Medical Center, The Netherlands) (Figure 3). Sonographic images were analyzed on the micro-ultrasound machine using the software on the B and M Mode photos (Figure 4) and data was extracted and used to calculate the aforementioned measurements by hand in Microsoft Excel.

DISCUSSION

Qualitative analysis indicated that the image quality obtained at 7T trended to be superior to both 3T MRI and micro-ultrasound (Figure 2 and Table 2). Compared to the 3D Time of Flight, the 3D SPACE sequence with isotropic voxels allowed for multi-planar reformatting of images and allowed for less operator dependent results as compared to high frequency micro-ultrasound imaging. Although there was no significant difference between the three methods (P = 0.5647, One-Way ANOVA), the 7T Tesla trended to have better visibility of the vessel and its wall (Table 2, Figures 2 and 3).

The One-Way ANOVA between all 3 imaging modalities showed that 7T, 3T and micro-ultrasound imaging are all comparable imaging methods with no statistical difference between extracted values, (lumen area, wall area, total vessel area, wall thickness)^[19,20] [P > 0.05 (Table 3)]. *Post hoc* test using Tukey’s correction however showed significant differences when comparing 3T and micro-ultrasound for wall thickness.

Results of this very preliminary study indicated that vessel wall imaging of the superficial palmar arch was feasible with a whole body 7T MRI with subjective evaluations indicating that the image quality obtained at 7T is superior to both 3T MRI and micro-ultrasound. The 3D SPACE sequence with isotropic voxels allowed

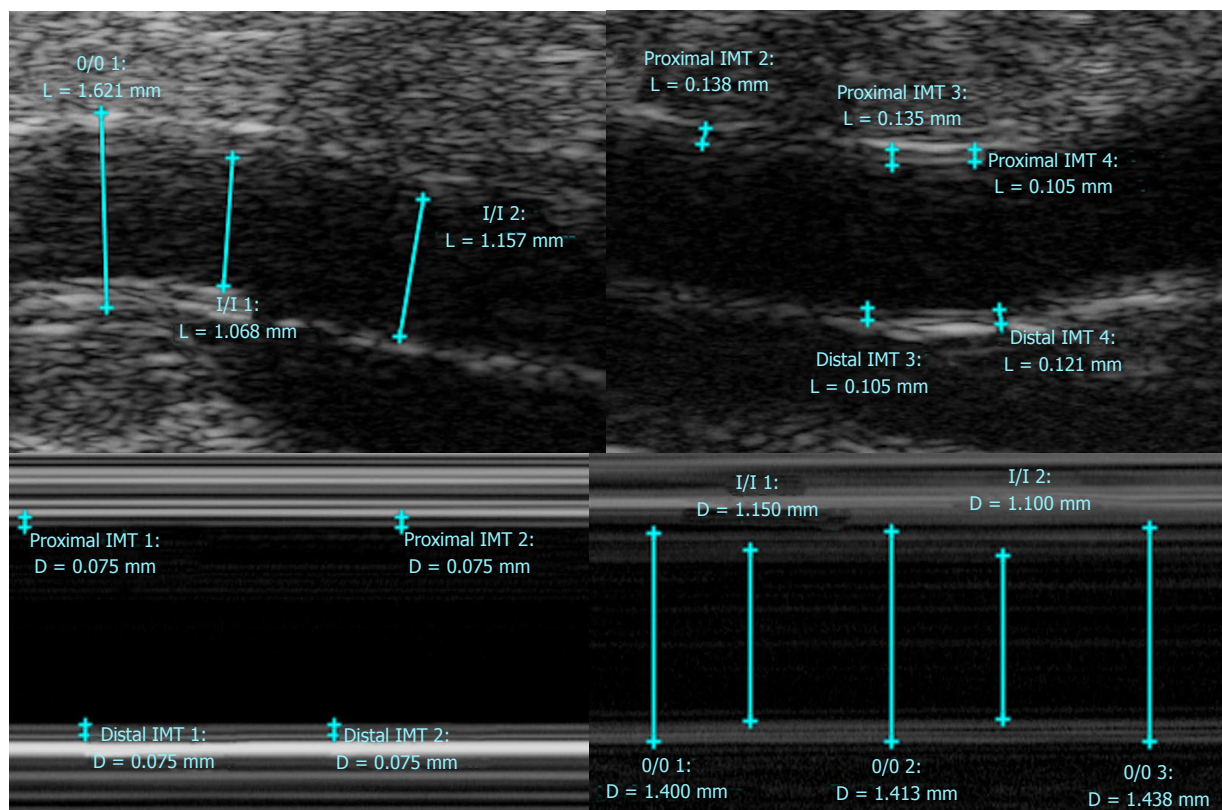


Figure 4 Ultrasound Images (B mode, M mode).

multi-planar reformatting of images and allows for less operator dependent results as compared to ultrasound imaging. Scanning time for the micro-ultrasound portion of the study approached that of the MR scan times, however with more operator experience the micro-ultrasound scan time could improve. The time spent on post-processing image analysis was similar across all modalities. Limitations of this study include a very small sample size and the fact that only healthy individuals without any atherosclerotic disease were examined. Future investigation should study individuals with diseased conditions in a larger sample size. Additionally, methods to optimize image quality could include warming the region of interest prior and during imaging to dilate the vessel and provide better contrast between the lumen and the vessel wall structures. This technique has been shown to optimize image quality in peripheral 2D TOF MRA evaluation^[21].

In conclusion, imaging of the superficial palmar arch at the 7T is feasible with high frequency micro-ultrasound, 3T and 7T MRI and should be considered for evaluating arterial pathology. This may be of clinical relevance in specific disease conditions such as atherosclerosis, scleroderma, diabetes, TO, hypothenar hammer syndrome and acute arterial thrombosis related to intraarterial injection. Future studies need to be performed in diseased individuals and in a larger number of subjects to better establish clinical feasibility of the approach.

COMMENTS

Background

Imaging the vessel wall of smaller caliber arteries requires higher resolution imaging when compared to imaging larger vessels such as the aorta and carotid arteries. For this purpose the authors conducted MR evaluation of the superficial palmar arch using 7T and 3T whole body MR scanners and compared the images acquired with high frequency ultrasound imaging. The author chose to focus on the superficial palmar arch because it is easily and consistently visualized using the modalities employed.

Research frontiers

A variety of pathological processes can affect the hand, including atherosclerosis, scleroderma, thromboangiitis obliterans, hypothenar hammer syndrome and acute arterial thrombosis related to intraarterial injection. These diseases are currently evaluated using sonography, arteriography, and standard 1.5 or 3T MRI. The intent of the investigation is to improve and potentially advance imaging techniques for evaluation of these diseases.

Innovations and breakthroughs

A thorough search of medical literature shows few if any prior investigations related to imaging the superficial palmar arch on a 7T MRI and therefore this is a novel application.

Applications

Future evaluation for atherosclerosis and other diseases may involve non-invasive 3T or 7T MR as well as micro-ultrasound imaging of the superficial palmar arch.

Peer-review

Imaging of smaller artery is feasible using micro-ultrasound and 3T and 7T MRI. Interesting and good study enough for publication.

REFERENCES

- 1 **Wong SK**, Mobolaji-lawal M, Arama L, Cambe J, Biso S, Alie N, Fayad ZA, Mani V. Atherosclerosis imaging using 3D black blood TSE SPACE vs 2D TSE. *World J Radiol* 2014; **6**: 192-202 [PMID: 24876923 DOI: 10.4329/wjr.v6.i5.192]
- 2 **Faxon DP**, Fuster V, Libby P, Beckman JA, Hiatt WR, Thompson RW, Topper JN, Annex BH, Rundback JH, Fabunmi RP, Robertson RM, Loscalzo J. Atherosclerotic Vascular Disease Conference: Writing Group III: pathophysiology. *Circulation* 2004; **109**: 2617-2625 [PMID: 15173044 DOI: 10.1161/01.CIR.0000128520.37674.EF]
- 3 **Alie N**, Eldib M, Fayad ZA, Mani V. Inflammation, Atherosclerosis, and Coronary Artery Disease: PET/CT for the Evaluation of Atherosclerosis and Inflammation. *Clin Med Insights Cardiol* 2014; **8**: 13-21 [PMID: 25674025 DOI: 10.4137/CMC.S17063]
- 4 **Zimmerman NB**. Occlusive vascular disorders of the upper extremity. *Hand Clin* 1993; **9**: 139-150 [PMID: 8444972]
- 5 **Yeager RA**, Moneta GL, Edwards JM, Landry GJ, Taylor LM, McConnell DB, Porter JM. Relationship of hemodialysis access to finger gangrene in patients with end-stage renal disease. *J Vasc Surg* 2002; **36**: 245-249; discussion 249 [PMID: 12170204]
- 6 **Stafford L**, Englert H, Gover J, Bertouch J. Distribution of macrovascular disease in scleroderma. *Ann Rheum Dis* 1998; **57**: 476-479 [PMID: 9797553]
- 7 **Lescoat A**, Coiffier G, Rouil A, Droitcourt C, Cazalets C, de Carlan M, Perdriger A, Jégo P. Vascular evaluation of the hand by Power Doppler Ultrasonography provides new predictive markers of ischemic digital ulcers in systemic sclerosis. *Arthritis Care Res (Hoboken)* 2016 Jul 7; Epub ahead of print [PMID: 27390194 DOI: 10.1002/acr.22965]
- 8 **Chikui T**, Izumi M, Eguchi K, Kawabe Y, Nakamura T. Doppler spectral waveform analysis of arteries of the hand in patients with Raynaud's phenomenon as compared with healthy subjects. *AJR Am J Roentgenol* 1999; **172**: 1605-1609 [PMID: 10350298 DOI: 10.2214/ajr.172.6.10350298]
- 9 **Rivera-Chavarría IJ**, Brenes-Gutiérrez JD. Thromboangiitis obliterans (Buerger's disease). *Ann Med Surg (Lond)* 2016; **7**: 79-82 [PMID: 27144003 DOI: 10.1016/j.amsu.2016.03.028]
- 10 **Gallagher KA**, Tracci MC, Scovell SD. Vascular arteritides in women. *J Vasc Surg* 2013; **57**: 27S-36S [PMID: 23522715 DOI: 10.1016/j.jvs.2012.10.119]
- 11 **Fazeli B**, Rezaee SA. A review on thromboangiitis obliterans pathophysiology: thrombosis and angiitis, which is to blame? *Vascular* 2011; **19**: 141-153 [PMID: 21652666 DOI: 10.1258/vasc.2010.ra0045]
- 12 **Marie I**, Hervé F, Primard E, Cailleux N, Levesque H. Long-term follow-up of hypothenar hammer syndrome: a series of 47 patients. *Medicine (Baltimore)* 2007; **86**: 334-343 [PMID: 18004178 DOI: 10.1097/MD.0b013e31815c95d3]
- 13 **Carpentier PH**, Biro C, Jiguet M, Maricq HR. Prevalence, risk factors, and clinical correlates of ulnar artery occlusion in the general population. *J Vasc Surg* 2009; **50**: 1333-1339 [PMID: 19837535 DOI: 10.1016/j.jvs.2009.07.076]
- 14 **Iannuzzi NP**, Higgins JP. Acute Arterial Thrombosis of the Hand. *J Hand Surg Am* 2015; **40**: 2099-2106 [PMID: 26408378 DOI: 10.1016/j.jhssa.2015.04.015]
- 15 **Ymalay R**, Sadanala U, Tinney JP, Kriss V, Keller BB. Initial Observations and Limitations of Vevo 2100 High Resolution Ultrasound Imaging in Neonates. *J Invest Med* 2012; **60**: 379
- 16 **Kaufman CL**, Ouseph R, Blair B, Kutz JE, Tsai TM, Scheker LR, Tien HY, Moreno R, Ozyurekdoglu T, Banegas R, Murphy E, Burns CB, Zaring R, Cook DF, and Marvin MR. Graft Vasculopathy in Clinical Hand Transplantation. *Am J Transplant* 2012; **12**: 1004-1016 [DOI: 10.1111/j.1600-6143.2011.03915]
- 17 **Mihai G**, Chung YC, Merchant A, Simonetti OP, Rajagopalan S. T1-weighted-SPACE dark blood whole body magnetic resonance angiography (DB-WBMRA): initial experience. *J Magn Reson Imaging* 2010; **31**: 502-509 [PMID: 20099365 DOI: 10.1002/jmri.22049]
- 18 **Zhang Z**, Fan Z, Carroll TJ, Chung Y, Weale P, Jerecic R, Li D. Three-dimensional T2-weighted MRI of the human femoral arterial vessel wall at 3.0 Tesla. *Invest Radiol* 2009; **44**: 619-626 [PMID: 19692844 DOI: 10.1097/RLI.0b013e3181b4c218]
- 19 **Fayad ZA**, Mani V, Woodward M, Kallend D, Abt M, Burgess T, Fuster V, Ballantyne CM, Stein EA, Tardif JC, Rudd JH, Farkouh ME, Tawakol A. Safety and efficacy of dalcetrapib on atherosclerotic disease using novel non-invasive multimodality imaging (dal-PLAQUE): a randomised clinical trial. *Lancet* 2011; **378**: 1547-1559 [PMID: 21908036 DOI: 10.1016/S0140-6736(11)61383-4]
- 20 **Balu N**, Chu B, Hatsukami TS, Yuan C, Yarnykh VL. Comparison between 2D and 3D high-resolution black-blood techniques for carotid artery wall imaging in clinically significant atherosclerosis. *J Magn Reson Imaging* 2008; **27**: 918-924 [PMID: 18383253 DOI: 10.1002/jmri.21282]
- 21 **Blackband SJ**, Buckley DL, Knowles AJ, Gibbs P, Turnbull LW, Horsman A. Improved peripheral MR angiography with temperature regulation in healthy patients. *Radiology* 1996; **198**: 899-902 [PMID: 8628890 DOI: 10.1148/radiology.198.3.8628890]

P- Reviewer: Chow J, Gumustas OG, Tang GH **S- Editor:** Qi Y
L- Editor: A **E- Editor:** Wu HL





Published by **Baishideng Publishing Group Inc**

8226 Regency Drive, Pleasanton, CA 94588, USA

Telephone: +1-925-223-8242

Fax: +1-925-223-8243

E-mail: bpgoffice@wjgnet.com

Help Desk: <http://www.wjgnet.com/esps/helpdesk.aspx>

<http://www.wjgnet.com>

