

Case report

Mantle cell lymphoma presenting as multiple lymphomatous polyposis of the gastrointestinal tract



Cláudio Martins*, Cristina Teixeira, Élia Gamito, Ana Paula Oliveira

Centro Hospitalar de Setúbal, Setúbal, Portugal

ARTICLE INFO

Article history:

Received 4 October 2016

Accepted 7 November 2016

Available online 31 December 2016

Introduction

The gastrointestinal (GI) tract is the most common extranodal site affected by lymphoma, accounting for 5–20% of all cases.¹ The incidence and location of primary GI lymphoma varies around the world. Overall, the most commonly involved sites are the stomach followed by the small bowel and ileocecal region.² Concerning histological subtypes, mucosa-associated lymphoid tissue lymphoma is more common in the stomach, mantle cell lymphoma (MCL) in the terminal ileum, jejunum and colon, enteropathy-associated T-cell lymphoma in the jejunum, and follicular lymphoma in the duodenum with a geographic variation in its distribution.³ MCL is a rare and distinct subtype of B-cell neoplasm, comprising approximately 6–9% of all malignant lymphoma in Western Europe, with an incidence of 1–2 cases/10⁵ people/year.⁴

Endoscopic features of GI lymphomas are heterogeneous, encompassing ulcers, erosions, polyps and so on. GI polyposis

occurs in up to 10% of cases, including conditions such as multiple lymphomatous polyposis (MLP) and immunoproliferative small-intestinal disease. MLP is a rare entity characterized by the presence of numerous GI polypoid lesions involving several digestive tract segments. Typical lymphoma presenting with MLP is MCL although other tumors can have this feature.⁵

MCL as MLP occurs more commonly in older adults and has a male predominance.⁶ The etiopathogenesis is unknown but a susceptible genetic background, a previous chemotherapeutic regimen or ionized radiation could contribute to the development of MCL. The clinical course is heterogeneous. The majority of patients (>90%) present with advanced disease (Ann Arbor stage III–IV) which comprises lymphadenopathy, hepatosplenomegaly and bone marrow involvement.

Diagnosis can usually be made based on endoscopic findings and histopathological analysis of their biopsy specimens. Immunohistochemistry to detect cyclin D1 overexpression is mandatory. In the rare cyclin D1-negative cases, detection of Sox-11 may help to establish the diagnosis.⁷

* Corresponding author at: Department of Gastroenterology, Setúbal Hospital Center – São Bernardo Hospital, 2910-446, Setúbal, Portugal. Tel.: +351 265549000.

E-mail address: cmartins1@campus.ul.pt (C. Martins).

<http://dx.doi.org/10.1016/j.bjhh.2016.11.005>

1516-8484/© 2016 Associação Brasileira de Hematologia, Hemoterapia e Terapia Celular. Published by Elsevier Editora Ltda. This is an open access article under the CC BY-NC-ND license (<http://creativecommons.org/licenses/by-nc-nd/4.0/>).

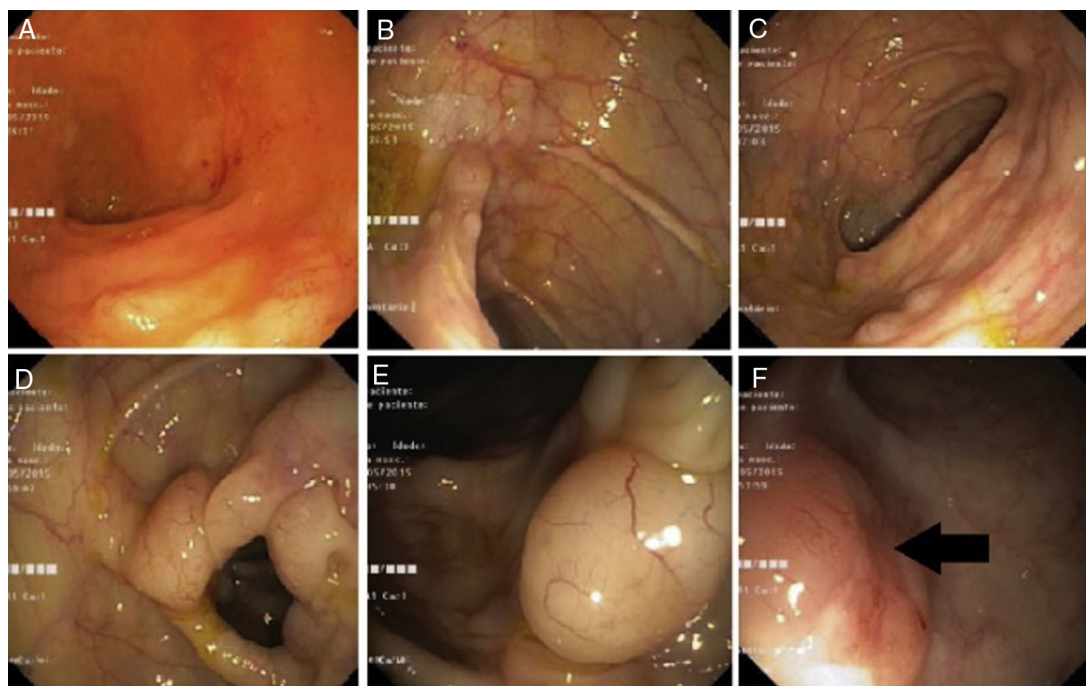


Figure 1 – Endoscopic findings. (A) Small pseudopolypoid lesions on the duodenal bulb; (B-F) Multiple sessile polypoid lesions of different sizes throughout the colon; (F) Polypoid lesion with ulcerated surface.

Systemic immunochemotherapy is the treatment of choice. The management of MCL is challenging because it has the worst features of both high and low grade non-Hodgkin lymphoma (NHL) – an aggressive clinical course but with a pattern of resistant and relapsing disease rendering it incurable with standard therapy.

Herein, we report an uncommon case of MCL presented with diffuse GI tract involvement, mesenteric lymphadenopathies, hepatosplenomegaly and bone marrow infiltration, emphasizing its endoscopic features.

Case report

A 62-year-old Caucasian female was referred to our department due to anemia and a positive fecal occult blood test. The patient presented with a two-month clinical picture of mild diffuse abdominal pain, change in bowel habits

including loose stools, significant involuntary weight loss, anorexia and asthenia. The remaining patient's history was uneventful. She reported no history of smoking, alcohol or drug consumption and denied any history of systemic diseases. There was an important family history of gastric cancer in first-degree relatives, namely three brothers with gastric adenocarcinoma diagnosed at 30, 50 and 60 years old. The physical examination showed pallor, painless splenomegaly and a palpable mass in the right iliac fossa. Superficial lymphadenopathies were absent.

Laboratory tests showed microcytic and hypochromic anemia (hemoglobin 7.6 g/dL, MCV 78 fL), normal total white blood cell count ($7.3 \times 10^9/L$), mild thrombocytopenia ($125 \times 10^9/L$) and high lactate dehydrogenase (399 U/L; normal range: 125–200). The erythrocyte sedimentation rate, C-reactive protein, total protein, albumin, and liver and kidney tests were normal. Laboratory study of anemia revealed a multifactorial etiology with ferropenic (low serum iron level, ferritin and

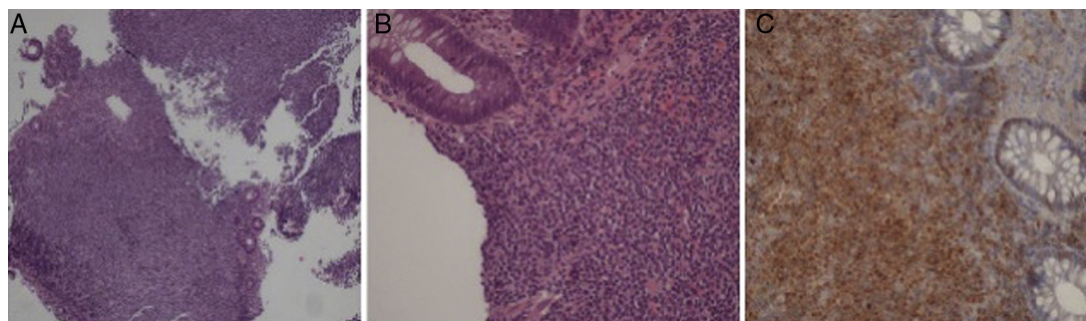


Figure 2 – Histopathological features of the lymphoma. (A, B) Diffuse intestinal mural infiltration of tumor cells (A – hematoxylin & eosin stain: magnification $\times 40$; B – hematoxylin & eosin stain: magnification $\times 100$); (C) Neoplastic cells were strongly positive for Cyclin D1 (immunohistochemistry stain: magnification $\times 100$).

transferrin saturation) and non-autoimmune hemolytic components (reticulocytosis, polychromatophilia, elevated lactate dehydrogenase and unconjugated bilirubin and very low haptoglobin).

Upper endoscopy showed small pseudopolypoid lesions on the duodenal bulb (Figure 1A). Total colonoscopy revealed multiple sessile polypoid lesions, ranging from 4 to 25 mm in the largest dimension, some with subepithelial appearance and others with surface ulceration, along the entire length (Figure 1B-F).

Endoscopic biopsy samples of duodenal and colonic lesions showed diffuse infiltration of the intestinal wall by atypical small-to-medium sized lymphocytes (Figure 2A and B). Immunohistochemical analysis demonstrated positive staining for CD20, CD5, Bcl-2 and cyclin D1 (Figure 2C) and negative for CD3 and CD10; 75% of tumor cells were positive for Ki-67. Therefore, these findings supported a diagnosis of mantle cell lymphoma presenting as multiple lymphomatous polyposis. The subsequent workup included a thoraco-abdominopelvic computed tomography (CT) scan that revealed thickening of several segments of the small and large intestinal walls, most prominent in the terminal ileum, multiple mesenteric adenopathies and homogeneous hepatosplenomegaly; there were no superficial and intrathoracic lymphadenopathies. Bone marrow biopsy showed lymphomatous involvement.

The biologic MCL International Prognostic Index (IPI) score was 7.8 and the disease was classified as stage IVB according to the Ann Arbor staging system.

The patient underwent immunochemotherapy with rituximab, cyclophosphamide, doxorubicin, vincristine and prednisone (R-CHOP). So far, she completed eight cycles with good tolerance. Mild oral mucositis was the main complication reported during treatment. There was a significant improvement in her clinical status with progressive weight recovery. Follow-up upper and lower endoscopic examinations after eight cycles revealed complete remission with absence of all polypoid lesions in the GI tract. Likewise, thoraco-abdominopelvic CT scan showed no hepatosplenomegaly, remarkable regression of her bowel wall thickening, and disappearance of most enlarged mesenteric lymph nodes.

Discussion

MLP, first described by Cornes et al.⁸ in 1961, is characterized by the presence of diffuse proliferation of atypical lymphocytes presenting as multiple polypoid lesions in different GI sites.

B-cell GI lymphomas are more frequent than T-cell GI lymphomas with this being due to the fact that, histologically, these polyps originate from the mantle zone of the lymphoid follicle of the mucosa-associated lymphoid tissue (MALT). Therefore, typical lymphoma presenting with MLP is MCL, which has been reported with a frequency of up to 9% of all GI B-cell lymphomas. However, other tumors can have this feature and, additionally, multiple histological types of lymphomas can be simultaneously present in a context of MLP. Therefore, the biopsy of more than one polyp and of different types of lesions is always advisable.

Major sites of GI MCL involvement are the ileocecal region (35.7%), ileum (20.3%), rectum (9.1%) and duodenum (7.7%).

Regional lymph node involvement is not uncommon. Other possible extra-digestive tract sites include bone marrow, peripheral lymph nodes, Waldeyer's ring, spleen and liver.

MCL usually occurs in the male population (65%) with a mean age of 63 years. A recently published population-based study revealed that 91% of MCL cases found were ethnically white, 4% were black and almost 4% were Asian/Pacific Islander.⁹ These ethnic differences may be a result of genetic or other environmental and lifestyle factors.

The clinical picture of GI MCL is heterogeneous. Based on the largest study series by Ruskone-Fourmestreaux et al.¹⁰, the main presenting symptoms of GI MCL are abdominal pain, diarrhea and hematochezia. Weight loss, night sweats and fatigue are commonly found. The differential diagnosis of GI MCL include adenomatous polyps, hereditary polyposis syndromes, colorectal carcinoma, GI lipomatosis, lymphoid nodular hyperplasia with hypogammaglobulinemia, among others.

Diagnosis can be made based on endoscopic findings and histopathological analysis. The typical endoscopic features are small nodular or polypoid lesions ranging from two millimeters to several centimeters in diameter, along the entire GI tract, with or without normal intervening mucosa.

Staging is carried out according to the Ann Arbor classification system. For prognostic purposes, a MCL IPI has been established.¹¹ The evaluation of the Ki-67 proliferative antigen is the most applicable method to evaluate cell proliferation, and is considered the most established biological risk factor in MCL.

The current therapeutic approach is based on clinical risk factors, symptoms, patient characteristics and stage of disease. In advanced disease, the major clinical trials of the last decade focused on improvement of the front-line treatment of MCL, leading to the definition of a 'gold standard' therapy for young and fit patients (< 66 years and transplant eligible) consisting of a dose-intensified immunochemotherapy, followed by autologous stem-cell transplantation (ASCT).^{12,13} Based on several studies, particularly the recent European MCL Network Younger Phase III trial, a R-CHOP induction regimen and high dose of cytarabine followed by high dose consolidation and ASCT is recommended.¹⁴ For the group of elderly patients not eligible for ASCT, conventional immunochemotherapy (e.g. R-CHOP) followed by maintenance with rituximab, appears to be the 'gold standard'.

In this report, we describe an uncommon case of MCL presenting as MLP involving the entire intestine with remarkable endoscopic findings. In our case, the patient presented with disseminated disease with involvement of mesenteric lymph nodes, bone marrow, liver and spleen. Due to this fact, it is difficult to speculate where the primary location of the disease was. The MCL IPI score was 7.8 (high risk) and the disease was classified as stage IVB according to the Ann Arbor staging system. The prognosis of MCL patients at this stage is very poor with an overall survival of 37 months, and fewer than 8% of patients are alive at 10 years.

In conclusion, although GI lymphomatous polyposis is a rare disease, we emphasize that this entity should be included in the differential diagnosis of multiple polyposis of the GI. Furthermore, current therapeutic protocols cannot definitively cure patients with GI tract MCL. Early diagnosis with

further studies integrating novel agents are still required to determine the optimal treatment with less toxicity.

Conflicts of interest

The authors declare no conflicts of interest.

REFERENCES

1. Freeman C, Berg JW, Cutler SJ. Occurrence and prognosis of extranodal lymphomas. *Cancer*. 1972;29(1):252-60.
2. Herrmann R, Panahon AM, Barcos MP, Walsh D, Stutzman L. Gastrointestinal involvement in non-Hodgkin's lymphoma. *Cancer*. 1980;46(1):215-22.
3. Rizvi MA, Evens AM, Tallman MS, Nelson BP, Rosen ST. T-cell non-Hodgkin lymphoma. *Blood*. 2006;107(4):1255-64.
4. Dreyling M, Geisler C, Hermine O, Kluin-Nelemans HC, Le Gouill S, Rule S, et al. Newly diagnosed and relapsed mantle cell lymphoma: ESMO Clinical Practice Guidelines for diagnosis, treatment and follow-up. *Ann Oncol*. 2014;25 Suppl. 3:iii83-92.
5. Burke JS. Lymphoproliferative disorders of the gastrointestinal tract: a review and pragmatic guide to diagnosis. *Arch Pathol Lab Med*. 2011;135(10):1283-97.
6. Remes-Troche JM, De-Anda J, Ochoa V, Barreto-Zuñiga R, Arista-Nasr J, Valdovinos MA, et al. A rare case of multiple lymphomatous polyposis with widespread involvement of the gastrointestinal tract. *Arch Pathol Lab Med*. 2003;127:1028-30.
7. Fu K, Weisenburger DD, Greiner TC, Dave S, Wright G, Rosenwald A, et al. Cyclin D1-negative mantle cell lymphoma: a clinicopathologic study based on gene expression profiling. *Blood*. 2005;106(13):4315-21.
8. Cornes JS. Multiple lymphomatous polyposis of the gastrointestinal tract. *Cancer*. 1961;14:249-57.
9. Ambinder AJ, Shenoy PJ, Nastoupil LJ, Flowers CR. Using primary site as a predictor of survival in mantle cell lymphoma. *Cancer*. 2013;119(8):1570-7.
10. Ruskoné-Fourmesttraux A, Audouin J. Primary gastrointestinal tract mantle cell lymphoma as multiple lymphomatous polyposis. *Best Pract Res Clin Gastroenterol*. 2010;24(1):35-42.
11. Hoster E, Dreyling M, Klapper W, Gisselbrecht C, van Hoof A, Kluin-Nelemans HC, et al. A new prognostic index (MIP1) for patients with advanced-stage mantle cell lymphoma. *Blood*. 2008;111(2):558-65.
12. Dreyling M, Lenz G, Hoster E, Van Hoof A, Gisselbrecht C, Schmits R, et al. Early consolidation by myeloablative radiochemotherapy followed by autologous stem cell transplantation in first remission significantly prolongs progression-free survival in mantle-cell lymphoma: results of a prospective randomized trial of the European MCL Network. *Blood*. 2005;105(7):2677-84.
13. Hoster E, Metzner B, Forstpointner R, Pfreundschuh M, Trümper L, Hallek M, et al. Autologous stem cell transplantation and addition of rituximab independently prolong response duration in advanced stage mantle cell lymphoma. (ASH Annual Meeting Abstracts) *Blood*. 2009;114(22):880.
14. Hermine O, Hoster E, Walewski J, Ribrag V, Brousse N, Thieblemont C, et al. Alternating courses of 3x CHOP and 3x DHAP plus rituximab followed by a high dose ARA-C containing myeloablative regimen and autologous stem cell transplantation (ASCT) increases overall survival when compared to 6 courses of CHOP plus rituximab followed by myeloablative radiochemotherapy and ASCT in mantle cell lymphoma: final analysis of the MCL Younger Trial of the European Mantle Cell Lymphoma Network (MCL net). (ASH Annual Meeting Abstracts) *Blood*. 2012;120(21):151.