

Systematic Review

Regenerative potential of leucocyte- and platelet-rich fibrin. Part B: sinus floor elevation, alveolar ridge preservation and implant therapy. A systematic review

Ana B. Castro¹, Nastaran Meschi²,
Andy Temmerman¹, Nelson Pinto^{1,3},
Paul Lambrechts², Wim Teughels¹
and Marc Quirynen¹

¹Department of Oral Health Sciences, Periodontology, KU Leuven & Dentistry, University Hospitals Leuven, Leuven, Belgium; ²Department of Oral Health Sciences, Endodontology, KU Leuven & Dentistry, University Hospitals Leuven, Leuven, Belgium; ³Faculty of Dentistry, Postgraduate Implant Program, University of the Andes, Santiago, Chile

Castro AB, Meschi N, Temmerman A, Pinto N, Lambrechts P, Teughels W, Quirynen M. Regenerative potential of leucocyte- and platelet-rich fibrin. Part B: sinus floor elevation, alveolar ridge preservation, and implant therapy. A systematic review. *J Clin Periodontol* 2017; 44: 225–234. doi: 10.1111/jcpe.12658

Abstract

Aim: To analyse the effect of leucocyte- and platelet-rich fibrin (L-PRF) on bone regeneration procedures and osseointegration.

Materials and Methods: An electronic and hand search was conducted in three databases (MEDLINE, EMBASE and Cochrane). Only randomized clinical trials, written in English where L-PRF was applied in bone regeneration and implant procedures, were selected. No follow-up restrictions were applied.

Results: A total of 14 articles were included and processed. Three subgroups were created depending on the application: sinus floor elevation (SFE), alveolar ridge preservation and implant therapy. In SFE, for a lateral window as well as for the trans-alveolar technique, histologically faster bone healing was reported when L-PRF was added to most common xenografts. L-PRF alone improved the preservation of the alveolar width, resulting in less buccal bone resorption compared to natural healing. In implant therapy, better implant stability over time and less marginal bone loss were observed when L-PRF was applied. Meta-analyses could not be performed due to the heterogeneity of the data.

Conclusions: Despite the lack of strong evidence found in this systematic review, L-PRF might have a positive effect on bone regeneration and osseointegration.

Key words: alveolar ridge preservation; guided bone regeneration; implant therapy; leucocyte- and platelet-rich fibrin; sinus floor elevation

Accepted for publication 18 November 2016

Conflict of interest and source of funding statement

The authors have stated explicitly that there are no conflicts of interest in connection with this article.

The study was self-funded by the authors and their institution.

After tooth extraction, a marked resorption of the alveolar ridge occurs due to the tooth-bundle bone-dependent relationship (Araujo & Lindhe 2005), both horizontally and vertically. A more recent study (Chappuis et al. 2013), with analysis of the alveolar ridge after tooth

extraction via CBCT, reported even 3.5 times more severe bone resorption than the findings described in the existing literature. These changes in the alveolar ridge after tooth extraction have to be taken into account when implants are planned. Farmer & Darby (2014) concluded

that the majority of the implants placed in aesthetic zones required simultaneous bone augmentation due to the resorption in the mid-buccal aspect.

Several bone substitutes and/or procedures have been described in the literature but no specific technique neither for sinus augmentation nor for guided bone regeneration (GBR) procedures have been strongly recommended (McAllister & Haghighat 2007, Vignoletti et al. 2014). The use of growth factors has also been proposed as adjuvant of bone grafting. Jung et al. (2008) concluded that bone morphogenetic proteins (BMP-2, BMP-7), growth-differentiation factor-5 (GDF-5), platelet-derived growth factor (PDGF) and parathyroid hormone (PTH) might stimulate local bone augmentation during ridge preservation procedures. For sinus augmentation, also BMP-2 has been proposed as adjuvant of conventional techniques (Lin et al. 2015).

Platelet concentrates were suggested for bone augmentation procedures because of their constant release of growth factors. Platelet concentrates were initially used as fibrin glue to improve wound healing (Matras 1970). Later, the first generation of platelet concentrates, which included platelet-rich plasma (PRP) (Marx 2001) and plasma rich in growth factors (PRGF) (Anitua 1999), were developed. However, they had some disadvantages: expensive, operator dependent and extended production time. The second generation of platelet concentrates appeared to improve and ease the use of this technique (Choukroun 2001, Dohan et al. 2006a). Leucocyte- and platelet-rich fibrin (L-PRF) belongs to the second generation of platelet concentrates (Dohan et al. 2014). For its preparation, 9–10 ml blood is withdrawn from the patient in plastic/glass-coated tubes through venepuncture. No anticoagulants or additives are used. The blood is immediately centrifuged at 400 g during 10–12 min. After centrifugation, three layers are obtained: at the bottom, red blood corpuscles (RBC); at the top, platelet-poor plasma (PPP); and in the middle, a fibrin clot (L-PRF). L-PRF contains a dense fibrin fibre network where platelets and

leucocytes are enmeshed and it can serve as scaffold for other type of cells due to its favourable mechanical properties (Rowe et al. 2007, Khorshidi et al. 2016). Its content in leucocytes and platelets results in a constant release of growth factors such as PDGF, transforming growth factor (TGF), vascular endothelial growth factor (VEGF) and insulin-like growth factor (IGF) for 7–14 days (Dohan et al. 2006b, Schär et al. 2015). Its biological characteristics could also improve/facilitate the osseointegration process (Öncü et al. 2016).

The main aim of this systematic review was to analyse the capacity of L-PRF to promote bone regeneration in systemically healthy patients (ASA I). Its influence on potential adverse events after surgery was considered as a secondary aim.

Materials and Methods

This systematic review follows the guidelines of the Belgian Centre for Evidence-Based Medicine (CEBAM), Belgian Branch of the Dutch Cochrane Centre. It was conducted in accordance with the Transparent Reporting of Systematic Reviews and Meta-analyses (Moher et al. 2009, PRISMA statement).

Focused PICO question

The following statements were used to conduct the systematic search:

-Population (P) = systemically healthy humans (ASA I) with lack of alveolar bone and/or with need of implant therapy.

-Intervention (I) = use of L-PRF (protocol 2700 r.p.m./12 min. or 3000 r.p.m./10 min.) as biomaterial (alone or in combination with a graft material) in guided bone regeneration techniques and implant surgery.

-Comparison (C) = traditional techniques using bone substitute (xenograft, allograft, etc.) with/without collagen membrane or connective tissue graft.

-Outcome (O) = alveolar bone regeneration (reported as newly formed bone (%), soft tissue and bone healing (reported as healing index scores, bone resorption in mm and/or in technetium-99 m methylene

diphosphonate uptake) and implant osseointegration (reported as ISQ values and/or marginal bone loss in mm).

A PICO question was created to define the search strategy: *Does L-PRF promote regeneration in systemically healthy patients (ASA I) during guided bone regeneration techniques and implant surgery compared to traditional techniques?*

Search strategy

An electronic search was performed in three Internet databases: the National Library of Medicine, Washington, DC (MEDLINE-PubMed), EMBASE (Excerpta Medical Database by Elsevier), and Cochrane Central Register of Controlled Trials (CENTRAL). The search terms were defined by combining (Mesh Terms OR Key Words) from “Population” AND (Mesh Terms OR Key Words) from “Intervention”, as shown in Table S1.

No language or time restrictions were applied in the first search. However, only studies written in English were included for selection. The search was limited to human studies. The last electronic search was performed on the 31st of July 2015.

This search was enriched by hand searches, citation screening and expert recommendations. All reference lists of selected papers as well as related reviews were scanned for possible additional studies.

Screening and selection

Two reviewers (A.C., N.M.) screened independently the titles and abstract obtained from the first search. When publications did not meet the inclusion criteria, they were excluded upon reviewer’s agreement. Any disagreement between the two reviewers was resolved by discussion. All full texts of the eligible articles were examined by both reviewers. The articles that fulfilled all selection criteria were processed for data extraction. The two most accepted protocols for the preparation of L-PRF (2700 r.p.m./12 min. or 3000 r.p.m./10 min.) were included. The inclusion and exclusion criteria are summarized in Table S2.

Assessment of heterogeneity

The heterogeneity of the included studies was evaluated based on following factors: (1) study design and follow-up duration, (2) subject characteristics and smoking habits, and (3) surgical protocol: (a) centrifugation protocol (2700 r.p.m./12 min. or 3000 r.p.m./10 min.), (b) ml blood used to prepare L-PRF and (c) number of clots/membranes (if used).

Data extraction and quality assessment

Data extraction was performed for the included studies. All variables analysed in each study were processed. Where possible, a meta-analysis was performed.

Both reviewers (A.C., N.M.) independently performed the quality assessment using the Cochrane Collaboration's tool for assessing risk of bias. Six quality criteria were verified: (1) sequence generation or randomization component, (2) allocation concealment, (3) blinding of participants, personnel and outcome assessors, (4) incomplete/missing outcome data, (5) selective outcome reporting and (6) other sources of bias. In case of any doubt, the authors were contacted for clarification or to provide missing information. Each study was classified into the following groups: low risk of bias if all quality criteria were judged as "present", moderate risk of bias if one or more key domains were "unclear", and high risk of bias if one or more key domains were "absent".

Results

Search and selection

As a result of the electronic and hand search, 603 articles were obtained, of which 154 were duplicate and consequently removed (Fig. 1). A total of 449 articles were included for title and abstract screening. From those, 26 articles were included for full text review. Twelve articles were excluded after full text screening, which was conducted independently by two reviewers (A.C., N.M.) (Table S3). Fourteen randomized control trials (RCTs) fulfilled the inclusion criteria and were included for analysis.

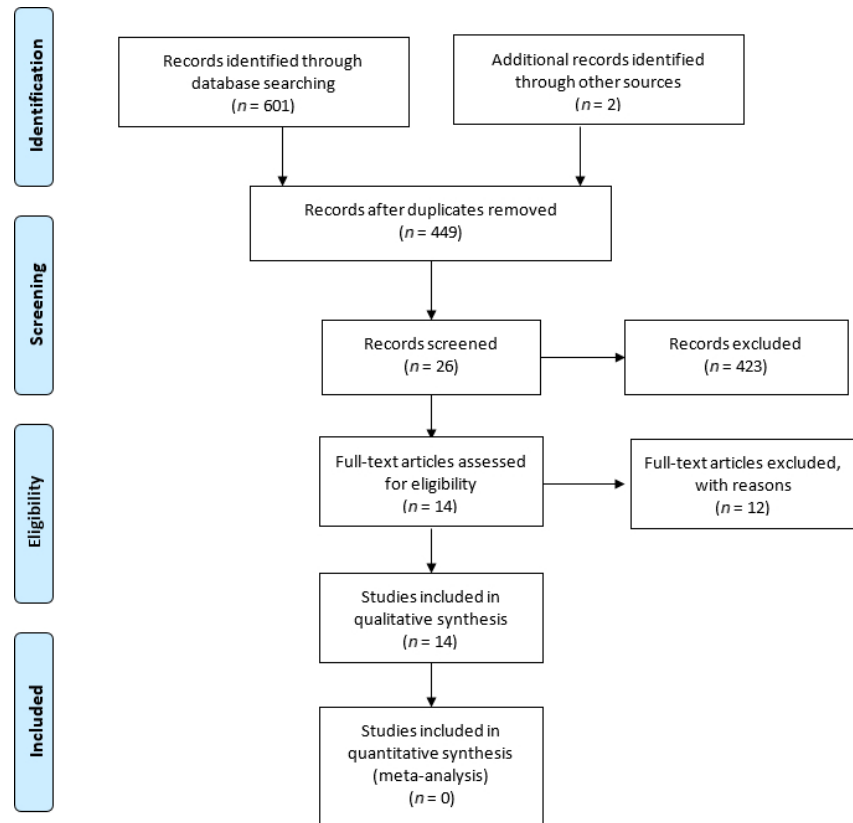


Fig. 1. PRISMA flow diagram.

The included articles were classified into three subgroups, depending on the indication for the use of L-PRF (Tables 1–3):

- 1 Sinus floor elevation procedures (SFE): $n = 3$, Tatullo et al. (2012), Zhang et al. (2012) and Gassling et al. (2013).
- 2 Alveolar ridge preservation: $n = 8$, Gürbüz et al. (2010), Singh et al. (2012), Hauser et al. (2013), Suttapreyasri & Leepong (2013), Baslarli et al. (2015), Marenzi et al. (2015), Kumar et al. (2015) and Yelamali & Saikrishna (2015).
- 3 Implant therapy: $n = 3$, Boora et al. (2015), Hamzacebi et al. (2015) and Öncü & Alaadinöglu (2015).

Assessment of heterogeneity

Study design and evaluation period

All studies were RCTs and often a split-mouth design was applied. The following articles fulfilled both study designs: SFE 1/3 (Gassling et al.

2013), ridge preservation 4/8 (Gürbüz et al. 2010, Singh et al. 2012, Marenzi et al. 2015, Yelamali & Saikrishna 2015), and implant therapy 0/3. The follow-up ranged considerably (SFE 5–6 months, ridge preservation 7 days to 4 months, implant therapy 1–6 months).

Subject characteristics and smoking habits

Healthy subjects with no active periodontal disease were included in all the studies. The articles that exclude the smokers are the following: SFE 1/3 (Tatullo et al. 2012), ridge preservation 4/8 (Gürbüz et al. 2010, Singh et al. 2012, Baslarli et al. 2015, Marenzi et al. 2015), and implant therapy 0/3. However, in alveolar ridge preservation and implant therapy, most of the studies did not mention the smoking status (ridge preservation 4/8 (Hauser et al. 2013, Suttapreyasri & Leepong 2013, Kumar et al. 2015, and Yelamali & Saikrishna 2015), and implant therapy 2/3 (Boora et al. 2015, Hamzacebi et al. 2015).

Table 1. L-PRF for sinus floor elevation. Papers have been arranged by sub-applications (L-PRF as coverage of lateral window and L-PRF bone quality)

Authors (year)	Study design, Duration	No. of participants baseline (end), gender, age (mean/range), smoking (?; No, Yes)	Groups C: control T: test	L-PRF preparation	Surgical protocol	Results
L-PRF as coverage of lateral window						
Gassling et al. (2013)	RCT Split-mouth Single-blind 5 months	6 – (6) Gender: ? Mean age: 61 Range: 54–69 Smoking: ?	C: <i>n</i> = 6, Bio-Oss® + Bio-Guide® membrane T: <i>n</i> = 6, Bio-Oss® + L-PRF membrane	Hardware: ? Setting: 400 g/12 min.	1 L-PRF membrane + Bio-Oss® LW no imm. impl. 10 ml blood/clot	L-PRF as coverage of lateral window NSSD in mean new-formed bone 17.0% and 17.2% for L-PRF and collagen sites respectively. NSSD in mean residual bone-substitute (15.9% and 17.3% respectively).
L-PRF bone quality						
Zhang et al. (2012)	RCT Parallel Not blind 6 months	10 – (10) 2 ♀, 8 ♂ Mean age: C: 46, T: 43 Range: C: 37–53, T: 30–49 Smoking: ?	C: <i>n</i> = 5, SL + Bio-Oss® T: <i>n</i> = 6, SL + Bio-Oss® + L-PRF	Hardware: ^a Setting: 300 g/10 min.	1 L-PRF membrane + Bio-Oss® LW no imm. impl. 10 ml blood/clot	L-PRF bone quality NSSD in bone morphological characteristics in both groups. L-PRF group had 1.4 times higher percentage of newly formed bone than control group (18.3 ± 5.6% versus 12.95 ± 5.3%).
Tatullo et al. (2012)	RCT Parallel Single-blind 5 months	60 – (60) 48 ♀, 12 ♂ Mean age: ? Range: 43–62 Smoking: No	*Early implant surgery: <i>n</i> = 20 - <i>n</i> = 6: SL + Bio-Oss® - <i>n</i> = 10: SL + Bio-Oss® + L-PRF - <i>n</i> = 4: bilateral atrophy: • Bio-Oss® • Bio-Oss® + L-PRF *Intermediate: <i>n</i> = 20, idem *Late: <i>n</i> = 20, idem	Hardware: ? Setting: 3000 r.p.m./10 min.	2 L-PRF membranes + Bio-Oss® TT + piezosurgery no imm. impl. 10 ml blood/clot	L-PRF bone quality NSSD in ISQ mean values. L-PRF showed histologically faster bone formation (106 days compared to 120–150 days)

V: 10 participants but 1 subject received two sinus floor elevations; ^aLabofuge 300, Kendro Laboratory Products GmbH, Osterrode, Germany. C, control group; imm. impl., immediate implant; ISQ, implant stability quotient; L-PRF, leucocyte- and platelet rich fibrin; LW, Lateral window; NSSD, no statistical significant different; RCT, randomized control trials; SL, sinus lift; T, test group; TT, Transalveolar technique.

Table 2. L-PRF for alveolar ridge preservation. Papers have been arranged by sub-applications (L-PRF *versus* "natural healing": bone quality, L-PRF *versus* PRP, L-PRF pain, L-PRF uptake technetium-99 m methylene diphosphonate)

Authors (year)	Study design, Duration	No. of participants baseline (end), gender, age (mean/range), smoking (Y, No, Yes)	Groups C: control T: test	L-PRF preparation	Surgical protocol	Results
L-PRF <i>versus</i> natural healing: bone quality Singh et al. (2012)	RCT	20 – (20) 10 ♀, 10 ♂ Mean age: 32 Range 18–50 Smoking: No	20 bilateral impacted 3rd molar: C: <i>n</i> = 20, no filling T: <i>n</i> = 20, L-PRF filling	Hardware: ? Setting: 3000 r.p.m./ 10 min.	1 L-PRF clot 0 L-PRF membrane 5–10 ⁹ ml blood/clot	L-PRF <i>versus</i> natural healing SS better Healing Index scores for L-PRF group (at 7th day <i>p</i> = 0.0015) NSSD in trabecular bone formation SS higher bone density at 12 weeks for L-PRF group
	RCT Parallel Double-blind 8 weeks	23 – (22) 14 ♀, 9 ♂ Mean age: 47 Range: 22–75 Smoking: ?	Premolar extractions: C: <i>n</i> = 7 T ₁ : <i>n</i> = 9, L-PRF filling T ₂ : <i>n</i> = 6, L-PRF filling + flap	Hardware: ? Setting: 2700 r.p.m./ 12 min.	1 L-PRF clot ? L-PRF membrane 8 ml blood/clot	L-PRF <i>versus</i> natural healing Mean crestal bone loss: control group 0.43 ± ? mm, L-PRF group 0.06 ± ? mm, and L-PRF + flap 0.42 ± ? mm (<i>p</i> < 0.05) L-PRF + Flap: invasive surgical procedure seemed to neutralize advantages of L-PRF
Suttapreyasri & Leepong (2013)	RCT	8 – (8) 5 ♀, 3 ♂ Mean age: 22 ± 2 Range 20.3–27.6 Smoking: ?	10 bilateral premolar extractions: C: <i>n</i> = 10, no filling T: <i>n</i> = 10, L-PRF filling	Hardware: ^a Setting: 3000 r.p.m./ 10 min.	1 L-PRF clot 0 L-PRF membrane 10 ml blood/clot	L-PRF <i>versus</i> natural healing NSSD between both groups for soft-tissue healing (<i>p</i> > 0.05) less buccal/lingual resorption for L-PRF group (1.9 ± 1.1 mm <i>versus</i> 2.6 ± 0.7 mm, <i>p</i> < 0.05) NSSD for radiographic evaluation (at mesial and distal site): L-PRF 0.7 mm/1.23 mm, control 1.33 mm/1.1 mm.
	RCT Parallel Split-mouth 8 weeks	31 – (31) Gender: ? Mean age: 26.1 Range: ? Smoking: ?	3rd molar extractions: C: <i>n</i> = 15, no filling T: <i>n</i> = 16, L-PRF filling	Hardware: ? Setting: 3000 r.p.m./ 10 min.	1 L-PRF clot 0 L-PRF membrane 5 ml blood/clot	L-PRF <i>versus</i> natural healing SS more PD reduction (distal 2nd molar) in L-PRF group (1.5 ± ? mm <i>versus</i> 0.5 ± ? mm). NSSD for bone density after 3 months (<i>p</i> > 0.05) SS less adverse events recorded in L-PRF group (pain, <i>p</i> = 0.01; swelling, <i>p</i> = 0.02).
L-PRF <i>versus</i> PRP Yelamali & Saikrishna (2015)	RCT	20 – (20) 8 ♀, 12 ♂ Mean age: ? Range: 21–27 Smoking: ?	20 bilateral impacted 3rd molar: C: PRP: <i>n</i> = 20, PRP filling T: L-PRF: <i>n</i> = 20, L-PRF filling	Hardware: ? Setting: 3000 r.p.m./ 10 min.	1 L-PRF clot 0 L-PRF membrane 6 ml blood/clot	L-PRF <i>versus</i> PRP SS better soft tissue healing for L-PRF group (<i>p</i> < 0.05).
	RCT Split-mouth Not blind 4 months	20 – (20) 8 ♀, 12 ♂ Mean age: ? Range: 21–27 Smoking: ?	20 bilateral impacted 3rd molar: C: PRP: <i>n</i> = 20, PRP filling T: L-PRF: <i>n</i> = 20, L-PRF filling	Hardware: ? Setting: 3000 r.p.m./ 10 min.	1 L-PRF clot 0 L-PRF membrane 6 ml blood/clot	L-PRF <i>versus</i> PRP SS better soft tissue healing for L-PRF group (<i>p</i> < 0.05).

Table 2. (continued)

Authors (year)	Study design, Duration	No. of participants baseline (end), gender, age (mean/range), smoking (? , No, Yes)	Groups C: control T: test	L-PRF preparation	Surgical protocol	Results
L-PRF pain Marenzi et al. (2015)	RCT Split-mouth Single-blind 7 days	26 – (26) 17 ♀, 9 ♂ Mean age: 53 ± 4 Range: ? Smoking: No or light smokers (<5/day)	26 bilateral canine/premolar/molar: C: n = 26, no filling T: n = 26, L-PRF filling	Hardware: ^b Setting: 2700 r.p.m./12 min.	2–6 L-PRF clot 0 L-PRF membrane 9 ml blood/clot	L-PRF pain SS better and faster healing for L-PRF group at 3 and 7 days (<i>p</i> < 0.05). SS less post-extraction pain for L-PRF group (<i>p</i> < 0.05).
L-PRF uptake technetium-99 m methylene diphosphonate Gürbüzler et al. (2010)	RCT Split-mouth Not blind 4 weeks	20 – (14) 7 ♀, 7 ♂ Mean age: 24 ± 4 Range: ? Smoking: No	14 bilateral impacted 3rd molar: C: n = 14, no filling T: n = 14, L-PRF filling	Hardware: ^c Setting: 400 g/10 min.	1 L-PRF clot 0 L-PRF membrane 10 ml blood/clot	L-PRF scintigraphic analysis NSSD in technetium-99 m methylene diphosphonate uptake (as indicator of enhanced bone healing): L-PRF 4.5 ± 1.0 versus control 4.6 ± 1.0)
Baslarli et al. (2015)	RCT Parallel Single-blind 3 months	20 – (20) 13 ♀, 7 ♂ Mean age: 23 Range: 10–34 Smoking: No	20 bilateral impacted 3rd molar: C: n = 20, no filling T: n = 20, L-PRF filling	Hardware: ? Setting: 3000 r.p.m./10 min.	0 L-PRF clot 1 L-PRF membrane 9 ml blood/clot	L-PRF scintigraphic analysis NSSD in technetium-99 m methylene diphosphonate uptake (as indicator of enhanced bone healing) at 3 months: L-PRF 4.1 ± 1.0 versus 3.9 ± 1.1).

C, control group; L-PRF, leucocyte- and platelet rich fibrin; NSSD, no statistically significant difference; PD, Pocket depth; RCT, randomized control trials; SS, statistically significant; T, test group.

^aEBA 20, Hettich GmbH&Co, KG, Tuttlingen, Germany.

^bIntra-Spin L-PRF kit, Intra-Lock, Boca-Raton, FL, USA.

^cUniversal 320 Hettich, Tuttlingen, Germany.

Surgical protocol

This heterogeneity in the surgical protocols is shown in Tables 1–3.

Data extraction

The variables processed as primary outcome were mean newly formed bone (%) for the SFE subgroup; soft tissue and bone healing (reported as healing index scores, bone resorption in mm and/or in technetium-99 m methylene diphosphonate uptake) for alveolar ridge preservation; and peri-implant bone stability (ISQ values and/or marginal bone loss in mm) for implant therapy. Post-operative pain was considered as secondary outcome. All the data presented a high heterogeneity, so a meta-analysis was impossible. The follow-up also differed substantially, therefore a comparison between studies was difficult.

Sinus floor elevation

All included studies used L-PRF in combination with a xenograft material and compared it to the xenograft alone (Table 1). One study compared, in a split-mouth set-up, an L-PRF membrane with a collagen membrane to cover a lateral window and reported a similar outcome in terms of percentage of mean vital bone formation and residual xenograft (Gassling et al. 2013). Zhang et al. (2012) evaluated the addition of L-PRF to the xenograft during a lateral window sinus augmentation. They observed 1.4 times more percentage of newly formed bone in the L-PRF group. Also, when L-PRF was used in a trans-alveolar approach, histologically, a faster bone healing was observed (Tatullo et al. 2012). Due to the heterogeneity of the data, meta-analysis could not be conducted.

Alveolar ridge preservation

In general, L-PRF improved the preservation of the alveolar ridge and resulted in less buccal bone resorption compared to the natural healing (Singh et al. 2012, Hauser et al. 2013, Suttapreyasri & Leepong 2013, Kumar et al. 2015). A better soft tissue healing and less post-extraction pain was frequently reported (Singh et al. 2012, Hauser et al. 2013, Kumar et al. 2015,

Table 3. L-PRF for implant therapy. Papers have been arranged by sub-applications (L-PRF at implant placement, L-PRF in peri-implant defects)

Authors (year)	Study design, Duration	No. of participants baseline (end), gender, age (mean/range), Smoking (? , No, Yes)	Groups C: control T: test	L-PRF preparation	Surgical protocol	Results
L-PRF at implant placement						
Boora et al. (2015)	RCT Parallel Not blind 3 months	20 – (20) 5 ♀, 15 ♂ Mean age: 25 ± ? Range: 18–33 Smoking: ?	C: n = 10, no L-PRF T: n = 10, L-PRF	Hardware: ? Setting: 3000 r.p.m./ 10–12 min.	1 L-PRF membrane Adin Dental Implant System (Israel) 10–14 days non-functional prov. crown 10 ml blood/clot	L-PRF at implant placement SS less initial marginal bone loss for L-PRF group at mesial and distal site (L-PRF 0.3 ± 0.06 mm, 0.3 ± 0.02 mm control 0.6 ± 0.02 mm, 0.7 ± 0.08 mm) ($p < 0.001$). NSSD for PD ($p > 0.05$) and BoP ($p > 0.05$).
Öncü & Alaadinöglu (2015)	RCT Parallel Not blind 1 month	20 – (20) 6 ♀, 14 ♂ Mean age: 44 ± 12 Range: ? Smoking: <10cig/day	C: n = 33, no L-PRF T: n = 31, L-PRF	Hardware: ^a Setting: 2700 r.p.m./ 12 min.	1 L-PRF membrane + exudate Ankylos Implant System (Dentsply) no imm. function 10 ml blood/clot	L-PRF at implant placement SS higher ISQ values for L-PRF group by the end of the 1st week (69 versus 64) ($p < 0.05$) and 4th week (77 versus 70.5) ($p = 0.001$). Mean ISQ values in L-PRF group increased continuously.
L-PRF in peri-implant defects						
Hamzacebi et al. (2015)	RCT Parallel Not blind 6 months	19 – (19) 8 ♀, 11 ♂ Mean age: 61 ± 12 Range: ? Smoking: ?	C: n = 19, OFD T: n = 19, OFD + L-PRF	Hardware: ? Setting: 3000 r.p.m./ 10 min.	1 L-PRF clot >1 L-PRF membrane Type implant not mentioned imm. function 10 ml blood/clot	L-PRF in peri-implant defects SS more PD reduction for L-PRF group (2.8 ± 1.0 mm versus 2.0 ± 0.7 mm) and CAL gain (3.3 ± 1.1 versus 1.8 ± 0.8 mm).

BoP, bleeding on probing; C, control group; CAL, clinical attachment level; imm. function, immediate function; ISQ, implant stability quotient; L-PRF, leucocyte- and platelet-rich fibrin; PD, pocket depth; RCT, randomized control trials; SS, statistically significant; T, test group.
^aPC-02, Process Ltd.

Marenzi et al. 2015). However, scintigraphic analyses (after 4 and 8 weeks) did not show enhanced bone healing in L-PRF sites (Table 2). The wide variability of the data did not allow a meta-analysis. Most studies used only one L-PRF clot/membrane per extraction site, which might be insufficient.

The adverse events were only registered in four out of the eight articles within this group. Each article analysed the adverse events with a different scale, so no meta-analysis could be performed. In all of them, less pain for L-PRF sites compared to control sites was reported (Singh et al. 2012, Hauser et al. 2013, Kumar et al. 2015, Marenzi et al. 2015).

Implant therapy

The RCTs (Hamzacebi et al. 2015, Öncü & Alaadinöglu 2015) evaluated the benefits of the application of L-PRF on the osseointegration process (Table 3). Öncü & Alaadinöglu (2015) evaluated the impact of implant coating with L-PRF. Implant stability was measured through resonance frequency analysis with implant stability quotients (ISQ values). The use of L-PRF at implant insertion resulted in statistically significant higher ISQ values which increased continuously over time. Boora et al. (2015) recorded the early bone remodelling around implants coated or not with L-PRF at insertion. The L-PRF-coated implants showed 50% less initial bone loss. Both after 1 and 3 months, respectively, (at 3 months: L-PRF sites: 0.3 ± 0.6 mm mesially and 0.3 ± 0.7 mm distally, non-L-PRF site: 0.6 ± 0.2 mm mesially and 0.7 ± 0.3 mm distally). Hamzacebi et al. (2015) assessed the effectiveness of the application of L-PRF and conventional flap surgery for the treatment of peri-implantitis bone loss. They reported more PD reduction (at 3 and 6 months: L-PRF sites: 2.4 ± 1.1 mm and 2.8 ± 1.0 mm, non-L-PRF sites: 1.65 ± 1.0 mm and 2.0 ± 0.7 mm), and CAL gain (L-PRF sites: 2.9 ± 1.0 mm, non-L-PRF sites: 1.4 ± 1.0 mm).

Quality assessment

All articles on SFE and implant therapy showed a moderate risk of

bias. Six articles using L-PRF for alveolar ridge preservation had a moderate risk and two had a high risk of bias. Appendix S1 shows the quality assessment for the included studies.

For the groups of SFE and alveolar ridge preservation, a good inter-rate agreement or weighted kappa was found (0.67, 95% CI, 0.4–0.9, and 0.63, 95% CI, 0.5–0.8 respectively). A fair inter-rate agreement (0.55, 95% CI, 0.2–0.9) was observed for the group of implant therapy. In the latest, the most disagreement was on the “incomplete outcome data” and “selective outcome reporting”.

Discussion

In recent years, L-PRF has been used in sinus floor elevation (SFE) either as a sole filling material or in combination with other graft materials. As mentioned in the results section, when L-PRF was used in combination with a graft material, better results were often obtained. However, no RCT or controlled clinical trial (CCT) could be retrieved in which L-PRF was used as the sole filling material or in combination with autologous bone grafts. The use of L-PRF as sole filling material has been analysed in several case series and case reports. In these studies, L-PRF was always used in combination with implant placement so that the implants could maintain the sinus membrane in an elevated position. Using the lateral window technique, Mazor et al. (2009), Simonpieri et al. (2011) and Tajima et al. (2013) evaluated the effectiveness of L-PRF as a sole graft material in SFE with simultaneous implant placement. In the first two articles, a bone gain of 7.5 mm (SD not mentioned) and 10.1 mm \pm 0.9 mm, respectively, at 6 months was reported. Tajima et al. (2013) found a bone gain of 10.4 mm \pm 1.2 at 1-year follow-up. They all concluded that L-PRF as a sole filling material could promote natural bone regeneration producing dense bone-like tissue, at least when implants are placed simultaneously. L-PRF has also been used as the sole filling material in a transalveolar approach. Using this approach, the case series of Diss et al. (2008) reported that a

healing period of 2–3 months was sufficient to resist a torque of 25 Ncm applied during abutment tightening. At 1-year follow-up, formation of a new recognizable bone structure delimiting the sinus floor was identified radiographically. Toffler et al. (2010) reported on 110 cases of osteotome-mediated SFE, with L-PRF as sole filling material during implant placement. The mean increase in the height at implant sites was 3–4 mm (range 2.5–5 mm), similar to the traditional osteotomes procedures. In a recent study (Kanayama et al. 2016), the mean bone gain around two different types of implant surfaces [hydroxyapatite (HA) and sandblasted acid-etched (SA)] was analysed using L-PRF as sole filling material in a transalveolar approach. Similar bone gain around both implant surfaces was reported (4.0 \pm 1.6 mm and 4.4 \pm 1.7 mm respectively) after 1-year follow-up. The main challenge in SFE procedures is to avoid the perforation of the Schneiderian membrane (Pjetursson & Lang 2014). It has been reported that L-PRF can be used to cover the perforation since it has a good intrinsic adherence to the Schneiderian membrane. Consequently, it can also be used preventively to reduce the risk of perforation during SFE procedures (Simonpieri et al. 2011).

L-PRF has been applied after tooth extraction to prevent bone resorption and alveolar ridge collapse. Most studies confirmed that L-PRF decreased the healing time as well as reduced the resorption of the buccal plate. However, five out of the eight studies evaluated the use of L-PRF in third molar extraction sites, which might have a distinct healing process when compared to extraction sites in the aesthetic region. Moreover, most of the studies used only one L-PRF clot or membrane to fill the extraction socket. One could question whether one clot or membrane is sufficient to completely fill the alveolus in order to create an adequate environment to stimulate the migration of osteoblasts and endothelial cells. The use of an L-PRF membrane on top, to close the alveolar socket, might have a significant influence on the outcome. Also, the amount of cells brought to the surgical site, as well

as the quantity of fibrin might be crucial for success.

Although the application of L-PRF during implant placement or for the treatment of peri-implant defects is quite new, several studies already showed clinical benefits (higher ISQ values, less marginal bone resorption). Lee et al. (2012) revealed in an animal study more bone-to-implant contact (39.4% \pm 7.4 *versus* 17.1% \pm 8.1) after the treatment of peri-implantitis defects with L-PRF.

Some limitations are needed to be taken into account regarding this systematic review. Most of the included articles showed a moderate risk of bias and some even a high risk. In this last case, the allocation concealment was not correctly applied what increased the risk of bias. In addition, no meta-analysis could be performed in any of the groups due to the heterogeneity of the data. Therefore, this systematic review can only analyse the included articles qualitatively. Consequently, the varied nature of the data resulted in a lack of strong evidence for this systematic review.

However, it is also worth to highlight the strengths. A total number of 296 participants were enrolled in the selected studies (161 in alveolar ridge preservation, 76 in sinus floor elevation and 59 in implant therapy). The surgical protocol of all these studies was examined, giving a detailed information about the use of L-PRF in each application. Consequently, we could observe that to use the correct protocol is extremely important to obtain an optimal effect.

L-PRF should be certainly distinguished from other types of platelet concentrates. The architecture of the fibrin matrix and its cellular content differ from the other products, as well as the biological activity.

Conclusion

Despite the lack of strong evidence found in the included articles, beneficial effects on bone regeneration and in implant surgery are suggested when L-PRF is applied. Given its ease of preparation, low cost and biological properties, L-PRF could be considered as a reliable option of treatment. However, standardization

of the protocol is required to obtain reproducible results. The use of enough L-PRF clots or membranes seems to be crucial to obtain an optimal effect.

Due to the lack in the standardization of the study design and variables analysed, further RCTs with long-term follow-up are needed to assess the beneficial effect of L-PRF on bone augmentation procedures and osseointegration.

Acknowledgements

We acknowledge GC Europe N.V. for the chair in bio-regeneration and Intra Lock International Inc. for the chair in optimized osseointegration.

References

- Anitua, E. (1999) Plasma rich in growth factors: preliminary results of use in the preparation of future sites for implants. *International Journal of Oral and Maxillofacial Implants* **4**, 529–535.
- Araujo, M. G. & Lindhe, J. (2005) Dimensional ridge alterations following tooth extraction. An experimental study in the dog. *Journal of Clinical Periodontology* **32**, 212–218.
- Baslarli, O., Tumer, C., Ugur, O. & Vatankulu, B. (2015) Evaluation of osteoblastic activity in extraction sockets treated with platelet-rich fibrin. *Medicina Oral Patologia Oral Cirurgia Bucal* **20**, e111–e116.
- Boora, P., Rathee, M. & Bhoria, M. (2015) Effect of platelet rich fibrin (PRF) on peri-implant soft tissue and crestal bone in one-stage implant placement: a randomized controlled trial. *Journal of Clinical and Diagnostic Research*, **9**, ZC18–ZC21.
- Chappuis, V., Engel, O., Reyes, M., Shahim, K., Nolte, L. P. & Buser, D. (2013) Ridge alterations post-extraction in the esthetic zone: a 3D analysis with CBCT. *Journal of Dental Research* **92**, 195S–201S.
- Choukroun, J. (2001) Une opportunité en parodontologie: le PRF. *Implantodontie*, **42**, 55–62. French.
- Diss, A., Dohan, D. M., Mouhyi, J. & Mahler, P. (2008) Osteotome sinus floor elevation using Choukroun's platelet-rich fibrin as grafting material: a 1-year prospective pilot study with microthreaded implants. *Oral surgery, Oral medicine, Oral pathology, Oral radiology, and Endodontics* **105**, 572–579.
- Dohan, D. M., Andia, I., Zumstein, M. A., Zhang, C. Q., Pinto, N. R. & Bielecki, T. (2014) Classification of platelet concentrates (Platelet-Rich Plasma-PRP, Platelet-Rich Fibrin-PRF) for topical and infiltrative use in orthopedic and sports medicine: current consensus, clinical implications and perspectives. *Muscles Ligaments Tendons Journal* **4**, 3–9.
- Dohan, D. M., Choukroun, J., Diss, A., Dohan, S. L., Dohan, A. J., Mouhyi, J. & Gigly, B. (2006a) Platelet-rich fibrin (PRF): a second-generation platelet concentrate. Part I: Technological concepts and evolution. *Oral Surgery, Oral Medicine, Oral Pathology, Oral Radiology, and Endodontics* **101**, E37–E44.
- Dohan, D. M., Choukroun, J., Diss, A., Dohan, S. L., Dohan, A. J., Mouhyi, J. & Gogly, B. (2006b) Platelet-rich fibrin (PRF): a second-generation platelet concentrate. Part II: platelet-related biologic features. *Oral Surgery Oral Medicine Oral Pathology Oral Radiology and Endodontics* **101**, e45–e50.
- Farmer, M. & Darby, I. (2014) Ridge dimensional changes following single-tooth extraction in the aesthetic zone. *Clinical Oral Implants Research* **25**, 272–277.
- Gassling, V., Purcz, N., Braesen, J. H., Will, M., Gierloff, M., Behrens, E., Acil, Y. & Wiltfang, J. (2013) Comparison of two different absorbable membranes for the coverage of lateral osteotomy sites in maxillary sinus augmentation: a preliminary study. *Journal of Craniomaxillofacial Surgery* **41**, 76–82.
- Gürbüz, B., Pikkoken, L., Tunalı, M., Urhan, M., Kucukodaci, Z. & Ercan, F. (2010) Scintigraphic evaluation of osteoblastic activity in extraction sockets treated with platelet-rich fibrin. *Journal of Oral and Maxillofacial Surgery* **68**, 980–989.
- Hamzacebi, B., Oduncuoglu, B. & Alaaddinoglu, E. E. (2015) Treatment of peri-implant bone defects with platelet-rich fibrin. *International Journal of Periodontics and Restorative Dentistry* **35**, 415–422.
- Hauser, F., Gaydarov, N., Badoud, I., Vazquez, L., Bernard, J. P. & Ammann, P. (2013) Clinical and histological evaluation of postextraction platelet-rich fibrin socket filling: a prospective randomized controlled study. *Implant Dentistry* **22**, 295–303.
- Jung, R. E., Thoma, D. S. & Hammerle, C. H. (2008) Assessment of the potential of growth factors for localized alveolar ridge augmentation: a systematic review. *Journal of Clinical Periodontology* **35**, 255–281.
- Kanayama, T., Horii, K., Senga, Y. & Shibuya, Y. (2016) Crestal approach to sinus floor elevation for atrophic maxilla using platelet-rich fibrin as the only grafting material: a 1-year prospective study. *Implant Dentistry* **25**, 32–38.
- Khorshidi, H., Raoofi, S., Bagheri, R. & Banihashemi, H. (2016) Comparison of the mechanical properties of early leukocyte- and platelet-rich fibrin versus PRGF/endoret membranes. *International Journal of Dentistry* **2016**, 1–7. doi:10.1155/2016/1849207.
- Kumar, N., Prasad, K., Ramanujam, L., K. R., Dexith, J. & Chauhan, A. (2015) Evaluation of treatment outcome after impacted mandibular third molar surgery with the use of autologous platelet-rich fibrin: a randomized controlled clinical study. *Journal of Oral and Maxillofacial Surgery*, **73**, 1042–1049.
- Lee, J. W., Kim, S. G., Kim, J. Y., Lee, Y. C., Choi, J. Y., Dragos, R., Rotatu, H. & Anyang, G. (2012) Restoration of a peri-implant defect with platelet-rich fibrin. *Oral Surgery, Oral Medicine, Oral Pathology, Oral Radiology, and Endodontics* **113**, 459–463.
- Lin, G. H., Lim, G., Chan, H. L., Giannobile, W. V. & Wang, H. L. (2015) Recombinant human bone morphogenetic protein 2 outcomes for maxillary sinus floor augmentation: a systematic review and meta-analysis. *Clinical Oral Implants Research* **00**, 1–11.
- Marenzi, G., Riccitiello, F., Tia, M., di Lauro, A. & Sammartino, G. (2015) Influence of leukocyte- and platelet-rich fibrin (L-PRF) in the healing of simple postextraction sockets: a split-mouth study. *BioMed Research International* **2015**, 1–6, In-Press. doi:10.1155/2015/369273.
- Marx, R. E. (2001) Platelet-rich plasma (PRP): What is PRP and what is not PRP? *Implant Dentistry* **10**, 225–228.
- Matras, H. (1970) Effect of various fibrin preparations on reimplantations in the rat skin. *Österreichische Zeitschrift für Stomatologie* **67**, 338–359.
- Mazor, Z., Horowitz, R. A., Del Corso, M., Prasad, H. S., Rohrer, M. D. & Dohan, D. M. (2009) Sinus floor augmentation with simultaneous implant placement using Choukroun's platelet-rich fibrin as the sole grafting material: a radiologic and histologic study at 6 months. *Journal of Periodontology* **80**, 2056–2064.
- McAllister, B. S. & Haight, K. (2007) Bone augmentation techniques. *Journal of Periodontology* **78**, 377–396.
- Moher, D., Liberati, A., Tetzlaff, J. & Altman, D. G. (2009) Preferred reporting items for systematic reviews and meta-analyses: the PRISMA statement. *PLoS Medicine* **6**, 1–6.
- Öncü, E. & Alaadinoglu, E. E. (2015) The effect of platelet-rich fibrin on implant stability. *International Journal of Oral and Maxillofacial Implants* **30**, 578–582.
- Öncü, E., Bayram, B., Kantarci, A., Gülsever, S. & Alaadinoglu, E. E. (2016) Positive effect of platelet rich fibrin on osseointegration. *Oral Surgery, Oral Medicine, Oral Pathology, Oral Radiology and Endodontics* **21**, 601–607, doi:10.4317/medoral.21026.
- Pjetursson, B. E. & Lang, N. P. (2014) Sinus floor elevation utilizing the transalveolar approach. *Periodontology 2000* **66**, 59–71.
- PRISMA statement. Preferred Reporting Items for Systematic Reviews and Meta-Analyses. Available at: <http://www.prisma-statement.org/> (accessed 04 augustus 2015).
- Rowe, S. L., Lee, S. Y. & Stegemann, J. P. (2007) Influence of thrombin concentration on the mechanical and morphological properties of cell-seeded fibrin hydrogels. *Acta Biomaterialia* **3**, 59–67.
- Schär, M. O., Diaz-Romero, J., Kohl, S., Zumstein, M. A. & Nestic, D. (2015) Platelet-rich concentrates differentially release growth factors and induce cell migration in vitro. *Clinical Orthopaedics and Related Research* **5**, 1635–1643.
- Simonpieri, A., Choukroun, J., Del Corso, M., Sammartino, G. & Dohan, D. M. (2011) Simultaneous sinus-lift and implantation using microthreaded implants and leukocyte- and platelet-rich fibrin as sole grafting material: a six-year experience. *Implant Dentistry* **20**, 2–12.
- Singh, A., Kohli, M. & Gupta, N. (2012) Platelet rich fibrin: a novel approach for osseous regeneration. *Journal of Maxillofacial and Oral Surgery* **11**, 430–434.
- Suttapreyasri, S. & Leepong, N. (2013) Influence of platelet-rich fibrin on alveolar ridge preservation. *Journal of Craniofacial Surgery* **24**, 1088–1094.
- Tajima, N., Ohba, S., Sawase, T. & Asahina, I. (2013) Evaluation of sinus floor augmentation with simultaneous implant placement using platelet-rich fibrin as sole grafting material. *International Journal of Oral and Maxillofacial Implants* **28**, 77–83.
- Tatullo, M., Marrelli, M., Cassetta, M., Pacifici, A., Stefanelli, L. V., Scacco, S., Dipalma, G., Pacifici, L. & Inchingolo, F. (2012) Platelet rich fibrin (P.R.F.) in reconstructive surgery of atrophied maxillary bones: clinical and histological evaluations. *International Journal of Medical Sciences* **9**, 872–880.

- Toffler, M., Toscano, N. & Holtzclaw, D. (2010) Osteotome-mediated sinus floor elevation using only platelet-rich fibrin: an early report on 110 patients. *Implant Dentistry* **19**, 447–456.
- Vignoletti, F., Nunez, J. & Sanz, M. (2014) Soft tissue wound healing at teeth, dental implants and the edentulous ridge when using barrier membranes, growth and differentiation factors and soft tissue substitutes. *Journal of Clinical Periodontology* **41** (Suppl.), S23–S35.
- Yelamali, T. & Saikrishna, D. (2015) Role of platelet rich fibrin and platelet rich plasma in wound healing of extracted third molar sockets: a comparative study. *Journal of Maxillofacial and Oral Surgery* **14**, 410–416.
- Zhang, Y., Tangl, S., Huber, C. D., Lin, Y., Qiu, L. & Rausch-Fan, X. (2012) Effects of Choukroun's platelet-rich fibrin on bone regeneration in combination with

deproteinized bovine bone mineral in maxillary sinus augmentation: a histological and histomorphometric study. *Journal of Craniomaxillofacial Surgery* **40**, 321–328.

Supporting Information

Additional Supporting Information may be found in the online version of this article:

Table S1. Search terms used for PUBMED, EMBASE and CENTRAL.

Table S2. Inclusion and exclusion criteria.

Table S3. Excluded articles and reason for exclusion.

Appendix S1. Quality assessment for the included studies. Cochrane tools for assessment of risk of bias for RCTs.

Address:

Ana B. Castro
 Department of Oral Health Sciences
 Periodontology
 UZ St Raphael
 Kapucijnenvoer 7, blok a – bus 07001
 B-3000 Leuven
 Belgium
 E-mail: anabelen.castrosarda@kuleuven.be

Clinical Relevance

Scientific rationale for the study: The aim of this systematic review was to analyse the effect of L-PRF on bone regeneration and osseointegration.

Principal findings: When L-PRF was added to a bone substitute

during sinus floor elevation bone healing occurred faster. L-PRF, alone or combined with bone substitutes, improved the preservation of the alveolar ridge compared to natural healing. In implant therapy, better implant stability over time and

less marginal bone loss were reported after the use of L-PRF.

Practical implications: Though there is a lack of strong evidence, these results showed favourable effects of L-PRF on bone regeneration and osseointegration.