

Comparison the percentage of detection of peri-arthritis in patients with rheumatoid arthritis using clinical examination or ultrasound methods

Hadi Karimzadeh, Zahra Seyedbonakdar, Maryam Mousavi, Mehdi Karami¹

Department of Rheumatology and ¹Department of Radiology, School of Medicine, Isfahan University of Medical Sciences, Isfahan, Iran

Background: This study aimed to compare the percentage of detection of peri-arthritis in patients with rheumatoid arthritis using clinical examination and ultrasound methods. **Materials and Methods:** This study is a cross-sectional study which was conducted in Al-Zahra Hospital (Isfahan, Iran) during 2014–2015. In our study, ninety patients were selected based on the American College of Rheumatology 2010 criteria. All patients were examined by a rheumatologist to find the existence of effusion, and the data were filled in the checklist. The ultrasonography for detecting effusion in periarticular structures was done by an expert radiologist with two methods, including high-resolution ultrasonography and power Doppler. The percentage of effusion existence found by physical examination was compared by sonography, and the Chi-square and *t*-tests were used for data analysis. **Results:** The percentage of effusion found in areas with physical examination by rheumatologist was lower than the frequency distribution of effusions found by sonography (8.3% VS 14.2%) ($P < 0.001$). In sonography, rotator cuff tendonitis is the most common peri-arthritis. Other findings in sonography were biceps tendinitis (10 cases), wrist tendonitis (13 cases), olecranon bursitis (9 cases), golfers elbow (4 cases), tennis elbow (4 cases), trochanteric bursitis (6 cases), anserine bursitis (6 cases), prepatellar bursitis (11 cases), and ankle tendonitis (7 cases). Tenderness on physical examination was found in 15% of the cases, and the evidence of peri-arthritis was found in 21/7% through sonography ($P < 0.001$) and 34% through Doppler sonography ($P < 0.001$). **Conclusion:** The percentage of peri-arthritis detection by ultrasonography and power Doppler sonography was higher than clinical examination. Hence, the ultrasonography is more accurate than physical examination.

Key words: Peri-arthritis, rheumatoid arthritis, ultrasonography

How to cite this article: Karimzadeh H, Seyedbonakdar Z, Mousavi M, Karami M. Comparison of the percentage of detection of peri-arthritis in patients with rheumatoid arthritis using clinical examination or ultrasound methods. *J Res Med Sci* 2016;21:134.

INTRODUCTION

Rheumatoid arthritis is the most common inflammatory arthritis affecting approximately 1% of the population. Although this disease primarily affects the joints, due to abnormal systemic immune response, it can produce various extra-articular manifestations. The disease is a chronic autoimmune inflammatory process that its main feature is extensive involvement of the synovium, joint inflammation, and destruction that in case of lack of control, lead to destruction of cartilage, bones, ligaments, bursa, and tendons, etc., which in some cases results in the disability of the patients.^[1,2] In addition to

the involvement of large and small joints symmetrically, it can lead to peri-arthritis, tenosynovitis, tendon injuries, bursitis, enthesitis, and finally the joint erosion.

Typically, the diagnosis and determination of the activity have been performed by clinical symptoms and laboratory findings. Therefore, clinical assessment is not completely acceptable. The best way to prevent debilitating complications and high cost of treatment is to control the symptoms and complications of the disease. High-frequency ultrasound (HFUS) as one of the imaging methods has many diagnostic applications and can improve musculoskeletal imaging in rheumatology. In this way, high-resolution images of the anatomic structures of more than 0.1 mm can be seen.

This is an open access article distributed under the terms of the Creative Commons Attribution-NonCommercial-ShareAlike 3.0 License, which allows others to remix, tweak, and build upon the work non-commercially, as long as the author is credited and the new creations are licensed under the identical terms.

For reprints contact: reprints@medknow.com

Access this article online	
Quick Response Code: 	Website: www.jmsjournal.net
	DOI: 10.4103/1735-1995.196616

Address for correspondence: Dr. Maryam Mousavi, Department of Rheumatology, School of Medicine, Isfahan University of Medical Sciences, Isfahan, Iran. E-mail: mousavi1241@yahoo.com

Received: 21-07-2016; **Revised:** 08-08-2016; **Accepted:** 07-09-2016

HFUS is also more sensitive than clinical examination in the diagnosis of peri-arthritis, and it can be done repeatedly and can improve clinical assessment. Sonography is well tolerated by patients and has no side effects. We can find specific findings using ultrasound that cannot be found by simple physical examination and history taking. Power Doppler sonography (PDUS) is a new imaging method that results in improved sensitivity for blood flow in small vessels and blood flow of low velocity. With this method, we can find indirectly the signs of increased vascularization in inflammatory processes and diseases.^[3] Naredo *et al.* in 2005 reported that ultrasonography in the diagnosis of peri-arthritis in the glenohumeral joint, sternoclavicular, acromioclavicular, knees, elbows, and hands was a more sensitive method than clinical examination. The ultrasound findings are more relevant to paraclinical tests.^[4]

In a study by Schmit in 2014, ultrasonography was mentioned as a complementary tool to assess rheumatoid arthritis including peri-arthritis.^[5] In another study by McAlindon *et al.* at the American College of Rheumatology, patients with mechanical symptoms of pain and swelling without obvious clinical signs underwent sonography examination of glenohumeral, sternoclavicular, acromioclavicular, elbows, knees, ankles, and hips. In this study, sonography was considered as an alternative method for examination with a high sensitivity.^[6] In a study by Hermann *et al.* which was carried out on the shoulder joint, sonography has been proposed as an alternative method in the evaluation of the shoulder joint, especially in the early diagnostic stages.^[7] In 2001, guidelines in musculoskeletal sonography were proposed as an alternative of early diagnosis of upper extremity peri-arthritis, and treatment has been proposed.^[8] In another study conducted in 2006 by Naredo *et al.*, peri-articular sonography has been proposed as a good interventional method for diagnosis.^[9] In a study by Boutry *et al.*, sonography has been proposed as an early diagnostic method.^[10] Despite the cited cases, the current use of sonography in the evaluation of peri-arthritis in rheumatoid arthritis is controversial due to the lack of adequate studies and findings in the field. Given that sonography is more sensitive than clinical assessment in the diagnosis of peri-arthritis and also because the method is cheap, accessible, and without complications, it can be used as a supplement or even replace clinical methods used for diagnosis. This study aimed to compare peri-arthritis detection in patients with rheumatoid arthritis by two clinical and sonography methods because any study about peri-arthritis was not performed in Iran.

MATERIALS AND METHODS

This cross-sectional study was conducted in Al-Zahra Medical Center (Isfahan, Iran) during 2014–2015. The study

patients were those with confirmed rheumatoid arthritis who referred to the outpatient clinic.

Patients referred to the rheumatology clinic with defined rheumatoid arthritis based on a diagnosis by expert rheumatologist according to the American College of Rheumatology criteria (2010) were selected for the study. Exclusion criteria included a history of knee surgery 1 year ago, crystal peri-arthritis and traumatic peri-arthritis history in the past year, and a history of septic peri-arthritis (i.e., infective olecranon bursitis) in the last year.

Required sample size

The sample size of the study was calculated using sample size formula for prevalence studies and taking into account the 95% confidence level and the estimated error rate of 0/05; a total of ninety people were estimated that the sampling of these patients was done consecutively from patients with inclusion criteria and they were included in the study until the sample size was reached.

Methods

The diagnosis of rheumatoid arthritis was based on the American College of Rheumatology 2010 criteria by rheumatologist and clinical examination findings (such as tenderness, decreased passive range of motion). Demographic characteristics such as age, sex, disease duration, test results of anticyclic citrullinated peptide (Anti-CCP) and rheumatoid factor (RF) assayed by enzyme-linked immunosorbent assay, C-reactive protein (assayed by immunoassay), and erythrocyte sedimentation rate in the form of data collection were recorded. Furthermore, effusion, tenderness, and decreased passive range of motion are the manifestations of peri-arthritis in physical examination.

Before completing the questionnaire and sonography, informed consent forms were completed by patients. Sonography of peri-articular structures was done by an expert radiologist using two methods, i.e., high-resolution ultrasonography and power Doppler. Ultrasonography was done by linear probe with a frequency range of 7.5–15 MHz (this probe was selected because of the broad superficial field of view and near resolution). The aim of applying two methods of ultrasonography was to determine the sensitivity on the methods. Both radiologist and rheumatologist were blinded to each other. Hyperechoic, band-like, ligament, diffuse thickening and enlargement of tendon, and fluid-filled collection with a well-defined margin are signs of bursitis. Evaluated peri-articular structures include the shoulder (long head of biceps tendon, supra and infraspinatus, subscapularis, subacromial tendons and scapularis bursa, and rotator cuff), elbow (olecranon bursa to review bursitis, flexor

and extensor tendons binding to internal and external epicondyle including tennis elbow and golfers elbow), wrist (flexor carpi ulnaris and flexor carpi radialis tendon to review tendinitis), hips (trochanteric bursa to check out the trochanteric bursitis), knee (anserine and prepatellar bursa to review bursitis), and ankle (anterior extensor tendon to investigate tendinitis).

Data analysis

The collected data were analyzed with Statistical Package for Social Sciences software (SPSS) version 23 manufactured in International Business Machines Corporation, USA. To describe the data, mean (\pm standard deviation) and percentage (frequency) were used, and to analyze the data, Chi-square and *t*-tests were used. Because both clinical examination and ultrasonography were done on the same patients, any bias was controlled in our study.

RESULTS

In this study, ninety patients referred to the rheumatology clinic of AlZahra Hospital were studied. The mean age of patients was 49.79 ± 4.5 years with a range of 25–72. Thirteen (14/4%) patients were male and 77 (85/6%) were female. Mean duration of disease was 10 years. Joints morning stiffness duration was 46 min on average. RF in 77% and Anti-CCP in 66/7% patients were positive. In this study, except for the wrist, the percentage of effusion found in areas with physical examination by rheumatologist was lower than the percentage of effusions found by sonography (8/3% vs. 14.2%) ($P < 0.001$). However, in the left and right wrists, the reported effusion volume by the examiner was greater than ultrasonographic method [Table 1].

In Figure 1, the frequency of peri-arthritis found in sonography has shown that rotator cuff tendonitis is the most common peri-arthritis. Others were biceps tendinitis (10 cases), wrist tendonitis (13 cases), olecranon bursitis (9 cases), golfers elbow (4 cases), tennis elbow (4 cases), trochanteric bursitis (6 cases), anserine bursitis (6 cases), prepatellar bursitis (11 cases), and ankle tendonitis (7 cases). Although tenderness on physical examination was found in 15% of the cases, peri-arthritis was found in 21/7% through sonography ($P < 0.001$) and in 34% through Doppler sonography ($P < 0.001$) [Table 2].

Peri-arthritis was found in 21/7% and 34% of the cases by high-resolution sonography and PDUS, respectively ($P < 0.001$).

DISCUSSION

The aim of this study was to compare peri-arthritis in patients with rheumatoid arthritis with clinical examination and

Table 1: Comparison of effusion in physical examination and sonography

Site	Physical examination, n (%)	Sonography, n (%)	P
Right shoulder	3 (3.3)	8 (8.9)	<0.001
Left shoulder	1 (1.1)	3 (3.3)	0.03
Right elbow	5 (5.6)	11 (12.2)	<0.001
Left elbow	7 (7.8)	7 (7.8)	<0.001
Right wrist	26 (28.9)	19 (21.1)	<0.001
Left wrist	19 (21.1)	14 (15.6)	<0.001
Right hip	0	2 (2.2)	<0.001
Left hip	0	1 (1.1)	<0.001
Right knee	16 (17.8)	42 (46.7)	<0.001
Left knee	11 (12.2)	34 (37.8)	0.02
Right ankle	1 (1.1)	6 (6.7)	0.001
Left ankle	1 (1.1)	7 (7.8)	<0.001

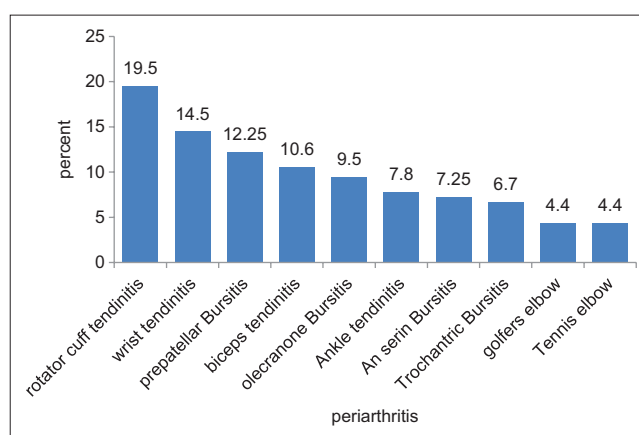


Figure 1: Frequency of peri-arthritis in sonography

sonography in Al-Zahra Hospital in 2014–2015. In this study, ninety patients referred to the rheumatology clinic in Al-Zahra underwent sonographic examination and then studied accordingly. In this study, the percentage of effusion found on examination in all areas other than the wrist was lower than percentage found through sonography which was in line with the study done by Nared *et al.* and McAlindon *et al.*^[4,6] The rheumatologist did not report specifically peri-arthritis in any of these areas, but sonography reported peri-arthritis. Tenderness as a positive point for the presence of peri-arthritis was found in only 15% of the cases, but evidence of peri-arthritis in sonography was seen in 21/7%; in the comparison of the two methods, sonography was more sensitive than clinical examination which indicates that it was consistent with the findings of Naredo *et al.* and McAlindon *et al.*^[4,6] It also found that tenderness on physical examination compared with the evidence of peri-arthritis in power Doppler ultrasound suggests more cases of peri-arthritis indicates higher sensitivity in the evaluation of power Doppler ultrasound for peri-arthritis that it was consistent with the findings of Boutry *et al.* and Hermann *et al.*^[7,10] The PDUS reported peri-arthritis in 34% of the cases and high-resolution sonography reported

Table 2: Comparison of peri-arthritis in physical examination and ultrasonography and Doppler sonography

Site	Peri-arthritis in physical examination and ultrasonography			Peri-arthritis in physical examination and power Doppler sonography		
	Physical examination, n (%)	Ultrasonography, n (%)	P	Physical examination, n (%)	Doppler sonography, n (%)	P
Right shoulder	9 (10)	27 (30)	0.003	9 (10)	27 (30)	0.003
Left shoulder	8 (8.9)	17 (19)	0.005	8 (8.9)	19 (21.1)	0.006
Right elbow	15 (16.7)	19 (21)	<0.001	15 (16.7)	35 (38.9)	0.004
Left elbow	12 (13)	13 (14.4)	<0.001	12 (13)	41 (45.6)	<0.001
Right wrist	15 (17)	42 (46.7)	<0.001	15 (17)	48 (53.3)	<0.001
Left wrist	10 (11)	30 (33.3)	0.014	10 (11)	49 (54.4)	<0.001
Right hip	7 (8)	8 (8.9)	0.001	7 (8)	8 (8.9)	0.001
Left hip	5 (6)	7 (7.8)	<0.001	5 (6)	6 (6.9)	<0.001
Right knee	22 (24)	30 (33.3)	0.001	22 (24)	60 (66.7)	<0.001
Left knee	13 (14)	22 (24.4)	0.014	13 (14)	52 (16.7)	<0.001
Right ankle	8 (9)	28 (31.1)	0.012	8 (9)	15 (16.7)	0.002
Left ankle	6 (7)	23 (25.6)	0.004	6 (7)	10 (11.1)	0.002

peri-arthritis in 21/7% of the cases, indicating a higher sensitivity of PDUS than high-resolution sonography. The above findings are consistent with Boutry *et al.* as well as Hermann *et al.* and also the musculoskeletal guidelines that had been introduced in 2001.^[7,8,10] Furthermore, in rheumatology reference books such as Kelley’s and Hochberg and Silman, sonography is introduced as a high-resolution method for peri-arthritis in early rheumatoid arthritis which is not visible on clinical examination.^[1,2] Evidence of peri-arthritis involving tendinitis and bursitis is found in the early stages of the disease, and sometimes more conflict areas were found in sonography than the clinical examination. As a result, physicians diagnose and start treatment sooner and prevent complications of the disease before symptoms appear during physical examination.^[11-13] Our study results confirmed the above-mentioned services. Considering the above results, the rate of detection of peri-arthritis by ultrasonography and was higher than clinical examination.

CONCLUSION

Long-term rheumatoid arthritis has high morbidity and mortality rates and can lead to disability of patients. It is recommended that sonography should be conducted for all patients with rheumatoid arthritis in the early stage of clinical diagnosis.

Financial support and sponsorship

This study was supported by Isfahan University of Medical Sciences, Isfahan, Iran (Research Project Number: 394665).

Conflicts of interest

There are no conflicts of interest.

AUTHORS’ CONTRIBUTION

Contributed in the conception of the work,conducting the study, revising the draft,approval of the final version

of the manuscript, and agreed for all aspects of the work. ZSB: contributed in the conception of the work,drafting and revising the draft,approval of the final version of the manuscript, and agreed for all aspects of the work. MM: contributed in the conception of the work,drafting and revising the draft,approval of the final version of the manuscript, and agreed for all aspects of the work. MK: contributed in the conception of the work,drafting and revising the draft,approval of the final version of the manuscript, and agreed for all aspects of the work.

REFERENCES

- Garys F, Ralph C. Kelleys Text Book of Rhomatology. 9th ed. Philadelphia: Elsevier Saunders Pub.; 2013. p. 1059-137.
- Hochberg MC, Silman A. Rheumatology. 5th ed. Philadelphia: Elsevier Mosby Pub.; 2014. p. 823-971.
- Andrea DS, Lucrezia R, Stefano B. Ultrasound in the diagnosis and management of rheumatic disease. Ch. 13., Vol. 18. 2008. p. 155-63.
- Naredo E, Bonilla G, Gamero F, Uson J, Carmona L, Laffon A. Assessment of inflammatory activity in rheumatoid arthritis: A comparative study of clinical evaluation with grey scale and power Doppler ultrasonography. *Ann Rheum Dis* 2005;64:375-81.
- Schmidt WA. Ultrasound in rheumatology. *Int J Rheum Dis* 2014;17:711-5.
- McAlindon T, Kissin E, Nazarian L, Ranganath V, Prakash S, Taylor M, *et al.* American College of Rheumatology report on reasonable use of musculoskeletal ultrasonography in rheumatology clinical practice. *Arthritis Care Res (Hoboken)* 2012;64:1625-40.
- Hermann KG, Backhaus M, Schneider U, Labs K, Loreck D, Zühlendorf S, *et al.* Rheumatoid arthritis of the shoulder joint: Comparison of conventional radiography, ultrasound, and dynamic contrast-enhanced magnetic resonance imaging. *Arthritis Rheum* 2003;48:3338-49.
- Backhaus M, Burmester GR, Gerber T, Grassi W, Machold KP, Swen WA, *et al.* Guidelines for musculoskeletal ultrasound in rheumatology. *Ann Rheum Dis* 2001;60:641-9.
- Naredo E, Möller I, Moragues C, de Agustín JJ, Scheel AK, Grassi W, *et al.* Interobserver reliability in musculoskeletal ultrasonography: Results from a ‘teach the teachers’ rheumatologist course. *Ann Rheum Dis* 2006;65:14-9.

10. Boutry N, Morel M, Flipo RM, Demondion X, Cotten A. Early rheumatoid arthritis: A review of MRI and sonographic findings. *AJR Am J Roentgenol* 2007;189:1502-9.
11. Pavlovic V, Dimic A, Milenkovic S, Krtinic D. Serum levels of IL-17, IL-4, and INF γ in Serbian patients with early rheumatoid arthritis. *J Res Med Sci* 2014;19:18-22.
12. Aryaeian N, Djalali M, Shahram F, Djazayeri A, Eshragian MR. Effect of conjugated linoleic acid, Vitamin E, alone or combined on immunity and inflammatory parameters in adults with active rheumatoid arthritis: A randomized controlled trial. *Int J Prev Med* 2014;5:1567-77.
13. Jafari Shapoorabadi Y, Vahdatpour B, Salesi M, Ramezani H. Effects of aerobic exercise on hematologic indices of women with rheumatoid arthritis: A randomized clinical trial. *J Res Med Sci* 2016;21:9.