

Therapeutic response to intravenous infusions of glucocerebrosidase in a patient with Gaucher disease

(enzyme replacement/anemia)

NORMAN W. BARTON*, F. SCOTT FURBISH†, GARY J. MURRAY, MARK GARFIELD, AND ROSCOE O. BRADY

Developmental and Metabolic Neurology Branch, National Institute of Neurological Disorders and Stroke, National Institutes of Health, Bethesda, MD 20892

Contributed by Roscoe O. Brady, November 17, 1989

ABSTRACT Enzyme replacement has been under consideration as a therapeutic strategy for patients with Gaucher disease for more than two decades. Previous studies indicated that single injections of purified glucocerebrosidase reduced the amount of storage material in the liver. It was important to determine whether administration of exogenous enzyme on a regular basis would be of clinical benefit. We report here that weekly i.v. infusions of a macrophage-targeted preparation of human placental glucocerebrosidase in a child with type 1 Gaucher disease increased hemoglobin from 6.9 ± 0.8 g/dl (± 1 SD) to 10.2 ± 0.4 g/dl (± 1 SD) over a 20-week period. The platelet count also increased from a pretreatment value of $30,000 \pm 7000/\text{mm}^3$ (± 1 SD) to $54,000 \pm 11,000/\text{mm}^3$ (± 1 SD). Phagocytic activity in the spleen decreased during the period of enzyme administration, and there was radiographic evidence of skeletal improvement. These observations document objective clinical responses to enzyme supplementation in a patient with a sphingolipid storage disorder.

Gaucher disease is the most prevalent lysosomal storage disorder. It arises from a deficiency of glucocerebrosidase activity with secondary accumulation of large quantities of a glycolipid, glucocerebroside, within the lysosomes of the phagocytic cells constituting the reticuloendothelial system (1). Clinically, the storage process produces a multisystem disease that includes progressive enlargement of the liver and spleen and gradual replacement of the bone marrow with distinctive lipid-laden macrophages. Many of these patients exhibit symptomatic anemia, thrombocytopenia, and skeletal involvement. Progressive neurological deterioration occurs in a minority of patients.

Enzyme replacement has been under consideration as a potential therapy for Gaucher disease for several years (2, 3). Initial clinical investigations with human placental glucocerebrosidase revealed significant reductions of hepatic glucocerebroside after single i.v. infusions of small quantities of the purified native enzyme (3, 4). Development of a large-scale purification procedure that provided homogeneous preparations of placental glucocerebrosidase was required to extend these early studies (5). However, replacement trials with the latter preparation gave inconsistent results (6). Laboratory investigations disclosed that the major portion of the injected enzyme was taken up by hepatocytes (7). Because hepatocytes do not accumulate glucocerebroside in patients with Gaucher disease, development of a macrophage-targeted enzyme preparation was considered necessary. Structural characterization of human placental glucocerebrosidase revealed that the native enzyme is a glycoprotein that contains 7% carbohydrate, primarily in the form of complex type oligosaccharide units (8, 9). Sequential deglycosylation of the native enzyme yields a mannose-terminated

preparation (10) that is specifically bound by a lectin on the plasma membrane of macrophages (11, 12). Bound enzyme is rapidly internalized and delivered to the lysosomal compartment of these cells (13). We now report objective clinical responses to repeated infusions of mannose-terminated human placental glucocerebrosidase in a child with Gaucher disease.

MATERIALS AND METHODS

Case Report. The patient was born on November 15, 1979, to Ashkenazic Jewish parents. He was the 7-lb 1-oz product of an uncomplicated pregnancy, labor, and delivery. Growth retardation and a protuberant abdomen were noted during infancy and early childhood. At 3 yr and 5 mo of age, hepatosplenomegaly was detected during a routine physical examination. A complete blood count disclosed a hemoglobin level of 7.4 g/dl, a hematocrit of 23.4%, a leukocyte count of $11,700/\text{mm}^3$, and a platelet count of $81,000/\text{mm}^3$. Bone marrow biopsy revealed storage cells consistent with Gaucher disease. The diagnosis was confirmed by analysis of leukocyte glucocerebrosidase activity (14) that was 18% of the control value. Over the ensuing 6 mo, exertional dyspnea, numerous bruises, and recurrent epistaxis were noted. Evaluation at the National Institutes of Health at age 4 revealed a chronically ill child with significant growth retardation. The weight was 13.6 kg (first percentile), and the height was 88.5 cm (less than first percentile). He was cooperative and alert. The respiratory rate was 25/min, and the chest was clear. The resting pulse rate was 120/min, and the precordium was hyperdynamic with a grade 3/6 systolic ejection murmur audible at the apex with radiation toward the sternum. There was no jugular venous distension. The abdomen was markedly protuberant. The liver was palpated 3 cm below the right costal margin, and the spleen occupied the entire left hemi-abdomen and extended well into the right lower quadrant. Soft tissue wasting was evident on examination of the extremities. Neurologic examination was entirely within normal limits, including detailed testing of ocular motility. Laboratory evaluation disclosed a hemoglobin of 7.8 g/dl (11-15; values in parentheses represent normal values), a hematocrit of 22.1% (33-42), a leukocyte count of $7800/\text{mm}^3$ (5-10,000), and a platelet count of $38,000/\text{mm}^3$ (150-450,000). The prothrombin time was 14.7 sec (9.4-13.7), and the partial thromboplastin time was 44.6 sec (22.5-34.8). Routine serum chemistry and urinalysis values were within normal limits with the following exceptions: creatinine 0.4 mg/dl (0.9-1.6), serum glutamic oxaloacetic transaminase 62 units/liter (8-31), cholesterol 120 mg/dl (150-250) and acid phosphatase 6.9 units/liter (0-0.4). An iron panel revealed a serum iron of 82 $\mu\text{g}/\text{dl}$ (50-150), total iron-binding capacity of 370 $\mu\text{g}/\text{dl}$

The publication costs of this article were defrayed in part by page charge payment. This article must therefore be hereby marked "advertisement" in accordance with 18 U.S.C. §1734 solely to indicate this fact.

*To whom reprint requests should be addressed at: Building 10, Room 3D04, National Institutes of Health, Bethesda, MD 20892.
†Present address: Genzyme Corporation, Inc., 75 Kneeland Street, Boston, MA 02111.

(250–400), and an iron saturation of 22% (15–45). Chest x-ray, electrocardiogram, and echocardiogram were within normal limits. The murmur audible on auscultation of the heart was secondary to severe anemia. Plain x-ray films of the long bones of the extremities disclosed prominent signs of Gaucher disease, consisting of poor mineralization, coarse trabeculation, and scalloping of the endosteal margins. A technetium sulfur colloid liver/spleen scan demonstrated marked splenomegaly. The liver measured 14 cm in its greatest vertical dimension (normal: ≤ 13 cm), and the spleen measured 23 cm (normal: < 7 cm).

After the initial evaluation, therapeutic options were carefully reviewed. Investigational treatment with glucocerebrosidase was chosen as the option with lower risk. Hematologic improvement obviating the need for splenectomy was selected as the therapeutic endpoint. The risks and potential benefits of i.v. glucocerebrosidase infusions were fully explained to the parents, and their consent was obtained under the guidelines of a protocol approved by the Institute Clinical Research Subpanel.

Treatment Protocol. Human placental glucocerebrosidase was isolated, and the oligosaccharide units were sequentially deglycosylated to yield a mannose-terminated preparation as described (5, 10, 15). The final preparation was formulated in 4% human serum albumin/155 mM sodium chloride/20 mM sodium dihydrogen phosphate adjusted to pH 5.0 with 0.3 M citric acid. Each preparation was rigorously tested for and found to be free of pyrogens and bacterial contamination. Mannose-terminated glucocerebrosidase was administered on a weekly basis by i.v. infusion at a dosage of 10,000,000 units (167 international units). For each infusion, the enzyme solution was injected over ≈ 5 min in a total volume of 5–10 ml. One unit of enzymatic activity hydrolyzes 1 nmol of glucocerebroside per hr. Expressed in international units, this amount corresponds to 1.67×10^{-5} μmol per min.

Enzyme infusions were begun at age 4 yr and 1 mo. Fourteen infusions were administered during the first 26 weeks of the treatment protocol due to limited availability of modified enzyme. Thereafter, infusions were administered without interruption until week 105 (age 4 yr and 7 mo to 6 yr and 1 mo). Subsequently, infusions were withheld until week 130 (age 6 yr and 1 mo to 6 yr and 7 mo) to determine whether the observed responses reverted to the baseline state. The complete blood count was monitored weekly during the period of active treatment and every 2 weeks afterwards. Routine serum chemistry values, acid phosphatase and prothrombin levels, and partial thromboplastin time were monitored every 3–6 mo, and liver/spleen scans and plain films of the long bones were monitored every 6–12 mo during the study period.

RESULTS

Substantial variation in hemoglobin was observed during the first 26 weeks of the treatment protocol. Potential salutary effects of the 14 enzyme infusions administered over this interval were obscured by recurrent epistaxis and viral infection of the upper respiratory tract. Thereafter, epistaxis ceased and the enzyme infusions were given without interruption between weeks 26 and 105. A gradual and progressive increase in hemoglobin from severely depressed to near normal values was seen (Fig. 1). The response became clearly evident between weeks 26 and 45. Upon withdrawal of the enzyme infusions between weeks 105 and 130, hemoglobin declined from a plateau of 10.2 ± 0.4 g/dl (± 1 SD) to pretreatment values of 6.9 ± 0.8 g/dl (± 1 SD). This reduction occurred in the absence of blood loss. As shown in Fig. 2, a rise in platelet count from a pretreatment value of $30,000 \pm 7,000/\text{mm}^3$ (± 1 SD) to $54,000 \pm 11,000/\text{mm}^3$ (± 1 SD) was

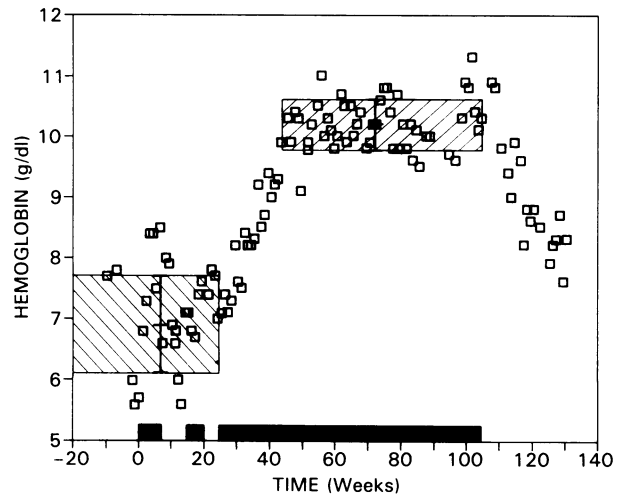


FIG. 1. Effect of weekly i.v. infusions of mannose-terminated glucocerebrosidase on hemoglobin in a child with Gaucher disease. Solid black bars along the abscissa represent the periods of enzyme administration. Hatched areas represent the mean pretreatment and maximum steady-state values seen during enzyme supplementation (± 1 SD).

also seen during enzyme supplementation. Although less striking than the hemoglobin response, this change is significant at the 99% level of confidence (16).

In concert with the hematological response, the patient appeared much more vigorous. The abdomen was less protuberant, and splenic size appeared to decrease on physical examination after several months of enzyme supplementation. Fig. 3 shows that the phagocytic activity of spleen decreased significantly during enzyme supplementation, as demonstrated by comparing the relative uptake of technetium sulfur colloid by liver and spleen (17). The pattern of colloid uptake reverted to the pretreatment state upon cessation of the enzyme infusions. Subtle evidence of improvement in the skeleton was also seen but was slower to develop. Plain films of the long bones revealed increased mineralization, decreased endosteal scalloping, and a finer trabecular pattern after 18 mo of enzyme supplementation (Fig. 4).

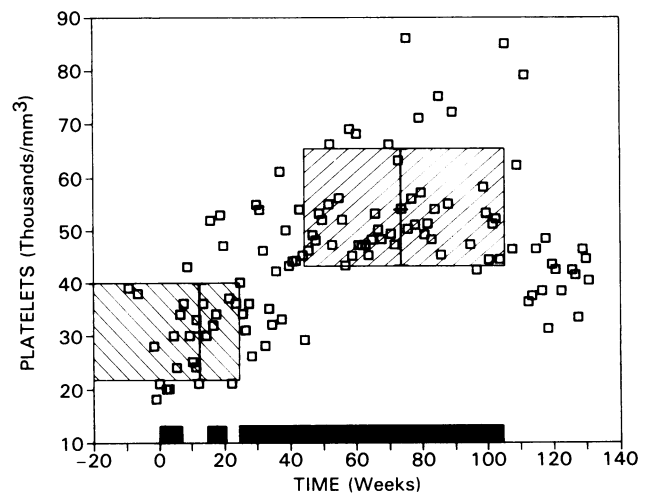


FIG. 2. Effect of weekly i.v. infusions of mannose-terminated glucocerebrosidase on platelet count in a child with Gaucher disease. Solid black bars along the abscissa represent the periods of enzyme administration. Hatched areas represent the mean pretreatment and maximum steady-state values seen during enzyme supplementation (± 1 SD).

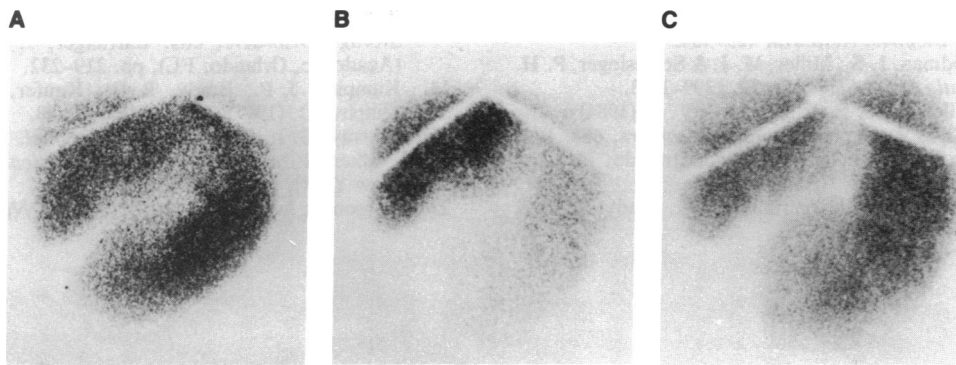


FIG. 3. Comparison of technetium sulfur colloid liver/spleen scans obtained before, during, and after enzyme administration. (A) Pretreatment. (B) Week 104. (C) Week 118. In each, liver is at left, and the spleen is at right. The relative activity of splenic phagocytes decreased during enzyme supplementation.

The enzyme infusions were well tolerated throughout the entire treatment protocol. No untoward reactions of any type were seen. No significant changes were observed in routine serum chemistry values or serum acid phosphatase activity during the study.

DISCUSSION

The observations reported here demonstrate clinical improvement in a patient with severe Gaucher disease after i.v. administration of human placental glucocerebrosidase. As anticipated a number of years ago (2), this effect appeared to require targeting of the exogenous enzyme to lipid-storing cells of the reticuloendothelial system. Patients with this disorder characteristically exhibit anemia, thrombocytopenia, and skeletal involvement at some point during the course of the disease. All these signs existed in the present case before enzyme supplementation. Improvement in each pa-

rameter was documented after several months of weekly injections of enzyme. The hematological response substantially preceded and developed more rapidly than the skeletal response. The most striking change was an increase in hemoglobin from severely anemic to near normal values. A less dramatic, but statistically significant, increase in platelet count was also seen. These responses were a consequence of enzyme supplementation. This interpretation is supported by the fact that the steady-state hemoglobin concentration and platelet count gradually reverted to pretreatment values over a 6-mo period of observation when enzyme was not administered. Hematological responses were mirrored by changes in the relative phagocytic activity of the spleen. Enzyme supplementation appeared to decrease the degree of hypersplenism.

The clinical responses reported here provide a foundation for continued investigation of enzyme replacement in Gaucher disease. Mannose-terminated glucocerebrosidase can be safely administered on a long-term basis without adverse side effects. The mechanism(s) that account(s) for hematologic improvement and the effects of enzyme supplementation on organ size and appearance will be the subject of future studies. Investigation of the effective dosage range for manose-terminated glucocerebrosidase is also essential.

We thank Dr. John Barranger for suggesting sequential deglycosylation to target enzyme to macrophages and for his participation in the initial phase of this project.

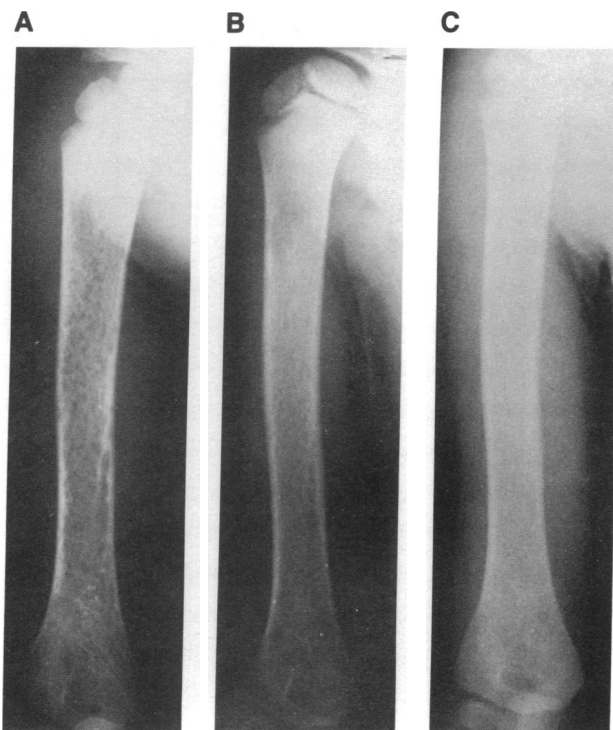

FIG. 4. Comparison of x-ray films of the right humerus before and during enzyme administration. (A) Pretreatment. (B) Week 80. (C) Week 104. Increased mineralization, decreased endosteal scalloping, and a finer trabecular pattern developed during enzyme supplementation.

1. Brady, R. O. & Barranger, J. A. (1983) in *The Metabolic Basis of Inherited Disease*, eds. Stanbury, J. B., Wyngaarden, J. B., Frederickson, D. S., Goldstein, J. L. & Brown, M. S. (McGraw-Hill, New York), pp. 842-856.
2. Brady, R. O. (1966) *N. Engl. J. Med.* **275**, 312-318.
3. Brady, R. O., Pentchev, P. G., Gal, A. E., Hibbert, S. R. & Dekaban, A. S. (1974) *N. Engl. J. Med.* **291**, 989-993.
4. Brady, R. O., Pentchev, P. G., Gal, A. E., Hibbert, S. R., Quirk, J. M., Mook, G. E., Kusiak, J. W., Tallman, J. F. & Dekaban, A. S. (1976) in *Current Trends in Sphingolipidoses and Allied Disorders*, eds. Volk, B. W. & Schneck, L. (Plenum, New York), pp. 523-531.
5. Furbish, F. S., Blair, H. E., Shiloach, J., Pentchev, P. G. & Brady, R. O. (1977) *Proc. Natl. Acad. Sci. USA* **74**, 3560-3563.
6. Brady, R. O. (1984) in *The Molecular Basis of Lysosomal Storage Disorders*, eds. Barranger, J. A. & Brady, R. O. (Academic, Orlando, FL), pp. 461-478.
7. Furbish, F. S., Steer, C. J., Barranger, J. A., Jones, E. A. & Brady, R. O. (1978) *Biochem. Biophys. Res. Commun.* **81**, 1047-1053.
8. Takasaki, S., Murray, G. J., Furbish, F. S., Brady, R. O., Barranger, J. A. & Kobata, A. (1984) *J. Biol. Chem.* **259**, 10112-10117.
9. Tsuji, S., Choudary, P. V., Martin, B. M., Winfield, S., Barranger, J. A. & Ginns, E. I. (1986) *J. Biol. Chem.* **261**, 50-53.

10. Furbish, F. S., Steer, C. J., Krett, N. L. & Barranger, J. A. (1981) *Biochim. Biophys. Acta* **673**, 425–434.
11. Stahl, P. D., Rodman, J. S., Miller, M. J. & Schlesinger, P. H. (1978) *Proc. Natl. Acad. Sci. USA* **75**, 1399–1403.
12. Stahl, P. D., Wileman, T. E. & Shepherd, V. L. (1984) in *The Molecular Basis of Lysosomal Storage Disorders*, eds. Barranger, J. A. & Brady, R. O. (Academic, Orlando, FL), pp. 209–218.
13. Furbish, F. S., Oliver, K. L., Zirzow, G. C., Brady, R. O. & Barranger, J. A. (1984) in *The Molecular Basis of Lysosomal Storage Disorders*, eds. Barranger, J. A. & Brady, R. O. (Academic, Orlando, FL), pp. 219–232.
14. Kampine, J. P., Brady, R. O., Kanfer, J. N., Feld, M. & Shapiro, D. (1967) *Science* **155**, 86–88.
15. Murray, G. J. (1987) *Methods Enzymol.* **149**, 25–42.
16. Walker, H. M. & Lev, J. (1953) *Statistical Inference* (Winston, New York), pp. 143–178.
17. Larson, S. M. & Nelp, W. B. (1966) *J. Nucl. Med.* **7**, 817–826.